

Thoracic & Lumbosacral Spine Surgery (TECHNIQUES)

Last updated: September 2, 2023

Table of Contents

GENERAL PRINCIPLES	3
COMPLICATIONS	23
SPECIAL CONDITIONS	26
POSTERIOR MIDLINE APPROACH	26
THORACIC SPINE APPROACHES	27
1. DORSAL-LATERAL	28
2. VENTRAL-LATERAL	33
THORACIC DISKECTOMY	40
LUMBAR INTERLAMINAR STABILIZATION (INTERSPINOUS SPACERS)	41
MILD (MINIMALLY INVASIVE LUMBAR DECOMPRESSION) / PILD (PERCUTANEOUS IMAGE-GUIDED LUMBAR DECOMPRESSION)	45
LUMBAR LAMINECTOMY	45
LUMBAR MICRODISKECTOMY	47
(FAR) LATERAL LUMBAR DISKECTOMY	54
LUMBAR MICRODISKECTOMY - REDO	57
LUMBAR MICRODISKECTOMY – MIS (TUBULAR RETRACTORS)	57
SYNOVIAL CYST EXCISION	58
FORAMINOTOMY	58
NONINSTRUMENTED FUSION	60
PEDICLE SCREWS & POSTEROLATERAL FUSION	60
DYNAMIC STABILIZATION	71
MIDLF (S. MIDLINE LUMBAR FUSION WITH CORTICAL BONE TRAJECTORY)	72
PLIF (POSTERIOR LUMBAR INTERBODY FUSION)	74
TLIF (TRANSFORAMINAL LUMBAR INTERBODY FUSION)	80
MIS-TLIF	84
ALIF (ANTERIOR LUMBAR INTERBODY FUSION)	86
AXIALIF	88
POSTERIOR LUMBAR CORPECTOMY	89
LATERAL APPROACH INTERBODY FUSION S. ANTEROLATERAL RETROPERITONEAL APPROACH TO LUMBAR SPINE	89
LATERAL LUMBAR CORPECTOMY	99
(SACRO)PELVIC FIXATION	100
OSTEOTOMIES	106
SPINE ROBOTICS – see p. Op40 >>	
LUMBAR TOTAL DISC REPLACEMENT (TDR) / ARTHROPLASTY – see p. Op225 >>	

Detailed Table of Contents

GENERAL PRINCIPLES	3
OUTCOMES, PATIENT SELECTION	4
Spine patient outcomes research trial (SPORT)	4
Age	4
NASS criteria for lumbar fusion	5
PATIENT AND OUTCOME OPTIMIZATION, INCL. ERAS PROTOCOL	6
Preoperative	6
Diabetes	6
Obesity	6
Smoking	7
Malnutrition	7
Osteoporosis	7
Pulmonary	8
Opioid use evaluation	8
Intraoperative	9
Postoperative	9
MINIMALLY INVASIVE SURGERY (MIS)	10
AXIS TABLE	10
LATERAL DECUBITUS POSITION	10
BONE GRAFTS	10
INTERBODY CAGES	10
DIFFERENT METALS	11
BROKEN SCREWS	11
HARDWARE REMOVAL	11
DEFINITION OF INSTABILITY, PRINCIPLES OF SPONDYLOLISTHESIS TREATMENT	11
SPINAL DEFORMITY	12
Pathophysiology	12
Etiology	12
Preop optimization	12
Imaging (scoliosis film, spine survey, 36-inch film)	12
Sagittal imbalance	13
Surgery	16
Scheuermann’s Kyphosis	17
Scoliosis (Coronal Deformity)	18
Postoperatively	19
ADJACENT LEVEL DISEASE	19
Proximal Junctional Kyphosis (PJK), Proximal Junctional Failure (PJF)	19
Prophylaxis	20
REDO CASES	21
INTRAOPERATIVE NEUROPHYSIOLOGICAL MONITORING	21
Free running EMG (s. NIM, Neural Integrity Monitoring)	21
O-ARM	22
Stealth Spine	22
DURAL SCAR PROPHYLAXIS	23
COMPLICATIONS	23
AVOIDANCE OF LITIGATION	23
CARDIAC ARREST (INTRAOP, PRONE)	23
UNABLE TO VENTILATE IN PRONE POSITION	23
LEVEL LOCALIZATION / WRONG LEVEL SURGERY	23
BLOOD VESSEL INJURY	24
Dorsal Approaches	24
Ventral Approaches	24
DUROTOMY	24
ISCHEMIC OPTIC NEUROPATHY (ION)	24
SURGICAL SITE INFECTION	25
Epidemiology	25
Prophylaxis	25
Treatment	25
NONFUSION / PSEUDOARTHROSIS	26
SPECIAL CONDITIONS	26
OSTEOPOROTIC SPINE	26
ANKYLOSING SPONDYLITIS (MARIE-STRÜMPELL DISEASE)	26
OSTEODISCITIS, OSTEOMYELITIS	26
PREGNANT PATIENT	26

POSTERIOR MIDLINE APPROACH.....	26
Medications	26
Positioning.....	27
Skin Incision.....	27
Fascial and Subfascial Dissection	27
Subperiosteal Dissection	27
Closure.....	27
THORACIC SPINE APPROACHES	27
Localization.....	28
1. DORSAL-LATERAL	28
LAMINECTOMY	29
TRANSPEDICULAR APPROACH	29
Transfacet Pedicle-Sparing Approach.....	29
COSTOTRANSVERSECTOMY	30
LATERAL EXTRACAVITARY APPROACH	32
2. VENTRAL-LATERAL.....	33
TRANSTHORACIC APPROACH.....	34
Postop	37
CSF-pleural fistula	37
RETROPLEURAL THORACOTOMY APPROACH	38
THORACIC (LATERAL) CORPECTOMY	38
Vessels.....	38
Technique	38
TRANSSTERNAL APPROACH	40
THORACIC DISKECTOMY.....	40
Approach selection	41
LUMBAR INTERLAMINAR STABILIZATION (INTERSPINOUS SPACERS).....	41
X-STOP	41
Coflex	42
MILD (MINIMALLY INVASIVE LUMBAR DECOMPRESSION) / PILD (PERCUTANEOUS IMAGE-GUIDED LUMBAR DECOMPRESSION).....	45
Vertos Medical	45
LUMBAR LAMINECTOMY.....	45
INDICATIONS	45
CONTRAINDICATIONS.....	45
PLANNING	45
PROCEDURE	46
Spinous Process removal.....	46
Laminectomy.....	46
COMPLICATIONS	46
LUMBAR MICRODISKECTOMY	47
TRIALS	47
INDICATIONS	47
Strategic Principles.....	47
CONTRAINDICATIONS.....	48
PLANNING	48
PROCEDURE	48
Posterior Approach.....	48
Removal of Ligamentum Flavum.....	48
Inferior Hemilaminotomy.....	49
Laminectomy.....	49
Nerve root mobilization.....	49
Discectomy.....	49
Aggressive discectomy vs. Conservative discectomy (s. Sequestrectomy).....	50
Local Steroids.....	51
Fat graft	51
Stabilization.....	51
Tips from masters.....	51
INTRAOPERATIVE COMPLICATIONS	51
POSTOPERATIVE COMPLICATIONS.....	52
POSTOPERATIVE REGIMEN	53
Follow up.....	53
Imaging postop	53
OUTCOMES.....	53
PEDIATRIC ASPECTS	54
(FAR) LATERAL LUMBAR DISKECTOMY.....	54
LUMBAR MICRODISKECTOMY - REDO	57
LUMBAR MICRODISKECTOMY – MIS (TUBULAR RETRACTORS).....	57
Incision	57
Targeting	57
Discectomy.....	57
Closure.....	57
Outcome trials	57
SYNOVIAL CYST EXCISION	58
FORAMINOTOMY.....	58
Lateral foraminotomy.....	58
MINIMALLY INVASIVE FORAMINOTOMY	58
Baxano iO-Flex® System	58
NONINSTRUMENTED FUSION	60
PEDICLE SCREWS & POSTEROLATERAL FUSION.....	60
Brief History.....	60
Biomechanics	60
Disadvantages.....	60
Indications	60
TECHNIQUE (PERCUTANEOUS, MIS).....	61
Globus – Creo MIS.....	61
Medtronic - Sextant	61
K2M.....	61
TECHNIQUE (OPEN)	62
Laminectomy.....	62
Screws	62
Dual-headed screws.....	62
Polymethylmethacrylate	63
Carbon	63
Starting point.....	64
Thoracic Spine.....	64
Lumbar Spine	65
Trajectory	66
Thoracic pedicles screw sagittal trajectories	66
Lumbar sagittal trajectory	67
Transverse pedicle angle	67
Triangulation	67
Depth	68
Tapping.....	68
Stimulation	69
Fusion	69
Rods.....	69
Rod contouring.....	69
Outrigger (Quad) rods	69

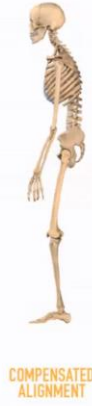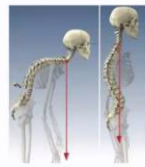Kickstand rod	69
Reducing spondylolisthesis	70
Fluoroscopy	70
FUSION REVISION / EXTENSION.....	70
(Rod) Connectors	70
COMPLICATIONS	71
POSTOPERATIVE.....	71
DYNAMIC STABILIZATION	71
Limiflex (Empirical Spine)	71
Dynesys (Zimmer Biomet).....	72
MIDLF (s. MIDLINE LUMBAR FUSION WITH CORTICAL BONE TRAJECTORY).....	72
PLIF (POSTERIOR LUMBAR INTERBODY FUSION)	74
Indications	74
Contraindications.....	74
TECHNIQUE.....	74
Position.....	74
Monitoring.....	74
Disk Preparation.....	74
Grafts / cages.....	76
Capstone (Medtronic).....	76
Wave D (Medtronic)	77
Elevate (Medtronic).....	80
TLIF (TRANSFORAMINAL LUMBAR INTERBODY FUSION)	80
Graft / Cages.....	82
Globus portfolio	82
Wave O (Medtronic)	82
Elevate (Medtronic).....	82
Concorde Bullet (DePuy)	84
ROI-T (LDR).....	84
MIS-TLIF	84
Entry point.....	84
Retractor	84
Drill facet joint	85
Outcomes.....	85
Hardware	86
Medtronic	86
ALIF (ANTERIOR LUMBAR INTERBODY FUSION)	86
Indications	86
Contraindications	86
Details.....	86
Cages	88
ROI-A ALIF cage (LDR)	88
AXIALIF.....	88
POSTERIOR LUMBAR CORPECTOMY.....	89
LATERAL APPROACH INTERBODY FUSION S. ANTEROLATERAL RETROPERITONEAL APPROACH TO LUMBAR SPINE.....	89
ADVANTAGES (OVER POSTERIOR APPROACH).....	89
SUITABLE LEVELS.....	89
INDICATIONS	89
COMPLICATIONS, CONTRAINDICATIONS.....	90
STAGES	92
POSITIONING	92
A. Lateral.....	92
B. Prone (aka Pro-LIF).....	93
APPROACHES	93
TECHNIQUE.....	94
Incision	94
A. Approach: Muscle-splitting	94
B. Approach: Open flank.....	96
Discectomy	96
Cage insertion.....	97
Closure.....	97
GRAFTS / CAGES	97
ELSA expandable (Globus).....	97
Clydesdale static (Medtronic)	97
Avenue L (LDR)	98
XLIF (eXtreme Lateral Interbody Fusion) - NuVasive.....	98
NAVIGATED LIF.....	98
LATERAL LUMBAR CORPECTOMY	99
PRONE POSITION	99
Approach	99
Corpectomy	100
Closure.....	100
(SACRO)PELVIC FIXATION	100
Indications	101
S2-ALAR-ILIAC (S2AI) SCREW	101
Double S2-AI screw	102
ILIAC SCREWS	102
Indications	103
Procedure.....	103
ILIOSACRAL SCREWS.....	104
OSTEOTOMIES.....	106
CLASSIFICATION #1.....	106
CLASSIFICATION #2.....	116
Grade 1 osteotomy (partial facet joint resection, s. Smith-Petersen osteotomy, opening wedge osteotomy, Chevron osteotomy, extension osteotomy)	117
Grade 2 osteotomy (complete facet joint resection).....	117
Grade 3 osteotomy (pedicle and partial body resection, s. pedicle subtraction osteotomy, PSO, closing wedge osteotomy, transpedicular wedge resection)	118
Grade 4 osteotomy (pedicle, partial body and disc resection)	119
Grade 5 osteotomy (complete vertebra and discs resection)	120
Grade 6 osteotomy (multiple adjacent vertebrae and discs resection)	120
SPINAL TUMORS – see p. Op260 >>	
FACET DISLOCATION REDUCTION – see p. TrS9 >>	

GENERAL PRINCIPLES

Surgical Goals

Goals of Spinal Surgery:

- Decompress neural elements to relieve symptoms
- Stabilize mobile segments if evidence of instability
- **Preserve alignment if maintained**
Restore alignment if deformity



OUTCOMES, PATIENT SELECTION

Diagnose **clinical syndrome** (not a **radiological diagnosis***) – look for **mechanical back pain** (deep and agonizing, increased by loading, decreased by unloading)
 **“Mankind would be better off without spine MRI”* – Prof. Edward Benzel

Rule out non-mechanical pain:

	True	False
I have low energy most days.		
Most of the times I do not get restful sleep.		
I spend more than 12 hours a day resting and /or sleeping.		
My pain causes me a great deal of suffering.		
I have pain in two or more parts of my body.		

Make sure patient exhausted all conservative measures:

1. Weight loss
2. Smoking cessation
3. Increase activity + Core strengthening + Core flexibility
4. Wean opioids (opiate-induced hyperalgesia)

Explain to patient that **pain is not harmful** – enough for some patients to get a peace of mind to continue conservative treatment.

Timed Up and Go (TUG) test – patient stands up from a sitting position, walks 10 feet, turns around, and walks back to chair, to sit down.

- patient is permitted to use an assistive device if needed and instructed to perform the test as fast as possible.
- **≥18.4 sec (15-20 sec)** = severe objective functional impairment (OFI) = frailty
 N.B. **frailty** is a different domain from **disability** and **comorbidity**
- frail patients have **5-fold increased risk of high-grade* complications** after elective thoracolumbar spine surgery within 6 wk of surgery.
 *grade > 1 using a modified Clavien-Dindo classification validated for neurosurgery patients
- consider **prehabilitation** in high-risk patients to improve postoperative clinical outcomes

Grade I	Any deviation from the normal postoperative course without the need for pharmacological treatment or surgical, endoscopic, and radiological interventions. Allowed therapeutic regimens are: drugs such as antiemetics, antipyretics, analgetics, diuretics, electrolytes, and physiotherapy. This grade also includes wound infections opened at the bedside.
Grade II	Requiring pharmacological treatment with drugs other than allowed for grade I complications. Blood transfusions and total parenteral nutrition are also included.
Grade IIIa	Surgical, endoscopic, or radiological intervention that is not under general anesthesia
Grade IIIb	Surgical, endoscopic, or radiological intervention that is under general anesthesia
Grade IVa	Life-threatening complication requiring intermediate care or intensive care unit management, single organ dysfunction (including dialysis, brain hemorrhage, ischemic stroke, and subarachnoidal bleeding)
Grade IVb	Life-threatening complication requiring intermediate care or intensive care unit management, multi-organ dysfunction (including dialysis)
Grade V	Death of a patient
Suffix “d”	If the patient suffers from a complication at the time of discharge, the suffix “d” (for “disability”) is added to the respective grade of complication. This label indicates the need for a follow-up to fully evaluate the complication

SPINE PATIENT OUTCOMES RESEARCH TRIAL (SPORT)

- \$13.5 million study (13 US centers) of symptomatic lumbar spinal stenosis
- study shortcomings:
 - 1) patients were **allowed to decline randomization** and were then entered into an observational cohort which may introduce bias into the groups
 - 2) **crossovers were allowed** between patients randomized to surgery and those randomized to nonsurgical treatment (degrading the “intention to treat” analysis)
 - 3) **no standardized surgical or nonsurgical technique**
 - 4) **low long-term follow-up** (52% at 8 years).
 - 5) change in paradigm from analyzing **intention-to-treat** to **as-treated** analysis.
- results indicated a **strong benefit of surgery at 4-year follow-up** that appeared to diminish by 8 years.
 N.B. **as-treated** analyses in **randomized group** showed that the **early benefit for surgery** out to 4 years converged over time, with **no significant treatment effect** of surgery seen **in years 6 to 8** for any of the primary outcomes! (vs. **observational group** showed a stable advantage for surgery in all outcomes between years 5 and 8)

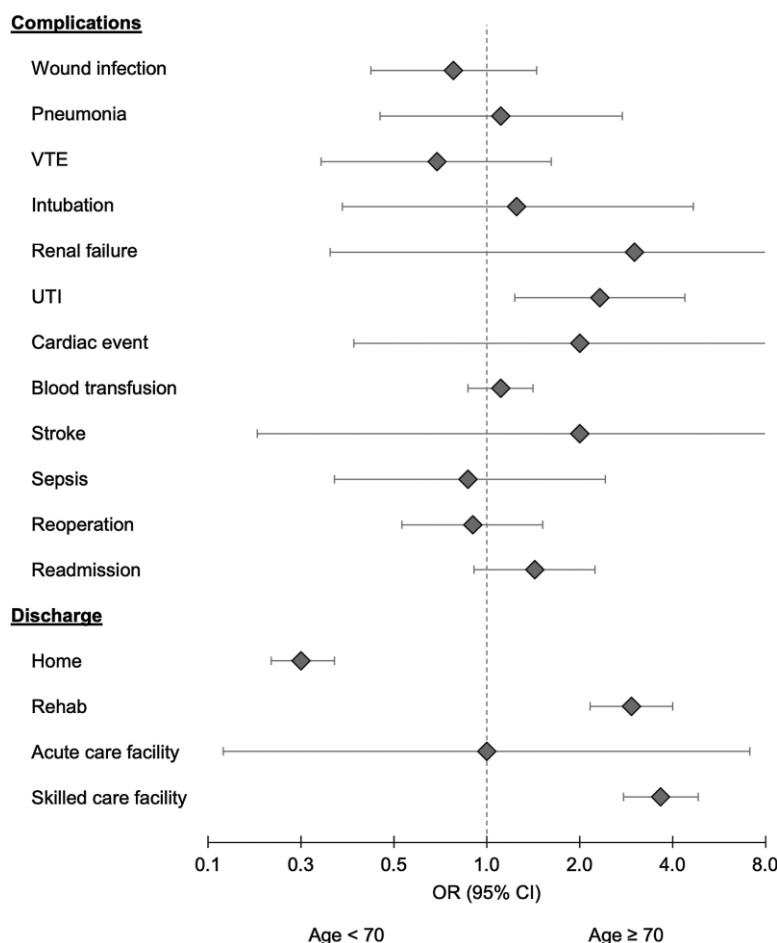
AGE

Jetan H. Badhiwala et al. The Effect of Older Age on the Perioperative Outcomes of Spinal Fusion Surgery in Patients With Lumbar Degenerative Disc Disease With Spondylolisthesis: A Propensity Score-Matched Analysis. Neurosurgery 87:672–678, 2020

- 2238 patients (n=1119, age < 70; n=1119, age ≥ 70) from National Surgical Quality Improvement Program datasets (2011 to 2015).
- outcomes (older vs younger patients): length of stay (mean 3.7 vs 3.5 d), wound infection (1.6% vs 2.1%), pneumonia (0.9% vs 0.8%), VTE (0.8% vs 1.2%), intubation (0.4% vs 0.4%), renal failure

(0.3% vs 0.09%), cardiac event (0.4% vs 0.2%), blood transfusion (14.4% vs 13.1%), stroke (0.2% vs 0.09%), sepsis (0.6% vs 0.7%), reoperation (2.4% vs 2.7%), readmission (4.3% vs 3.0%).

- 2 deaths (0.18%) in the older group and none in the younger group.



N.B. all complications were similar between younger and older age groups, except:

- UTI - more frequent in ≥ 70 age group (OR 2.32, P = .009).
- older age group were more likely to be discharged to a rehabilitation (OR 2.94, P < .001) or skilled care facility (OR 3.66, P < .001), rather than home (OR 0.25, P < .001).

N.B. it is likely that the phenotype associated with older age, namely greater comorbid status, is a driving factor in producing greater perioperative morbidity in this patient population (i.e. frailty is more important than the age).

NASS CRITERIA FOR LUMBAR FUSION

North American Spine Society. NASS Coverage Policy Recommendations: Lumbar Fusion. 2014. 7075 Veterans' Blvd. Burr Ridge, IL 60527

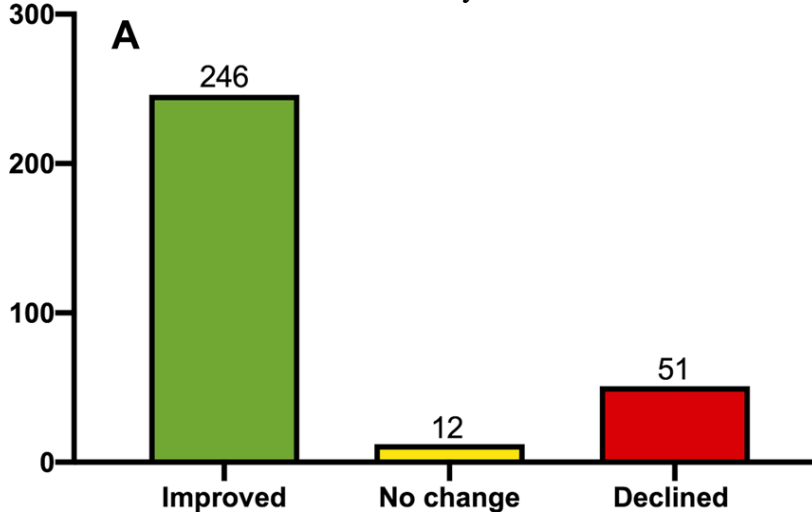
Spine fusion indications with grading of EBM from which these recommendations were made

1. Infection
"Based on what most practitioners would consider to be accepted practice patterns"
2. Tumor
"Based on what most practitioners would consider to be accepted practice patterns"
3. Trauma
"Based on what most practitioners would consider to be accepted practice patterns"
Wood et al: Prospective noted equivalence for operative versus nonoperative treatment.
4. Deformity
Level III: Schwab et al 2006³¹ (improved PCO treating SVA > 5 cm, 30 degrees
Level III: Glassman et al 2005³² (improved PCO < 4 cmSVA)
Level III: Glassman et al 2010³³ (worse PCO with nonoperative deformity)
5. Lumbar stenosis
Level I: Herkowitz (degenerative spondylolisthesis)
Level I: Weinstein SPORT data (stenosis and degenerative spondylolisthesis)
Level I: Möller and Hedlund (isthmic spondylolisthesis).
Level IV: Abumi (facet resection)
6. Discectomy
Level IV: McCulloch (L5-S1 facetectomy)
7. Synovial cyst
Level III: Xu (cysts and outcomes)
8. Axial back pain
Level I: Fairbank (axial LBP)
Level I: Fritzell (axial LBP)
9. Pseudarthrosis Level II: Cassinelli (pseudarthrosis)

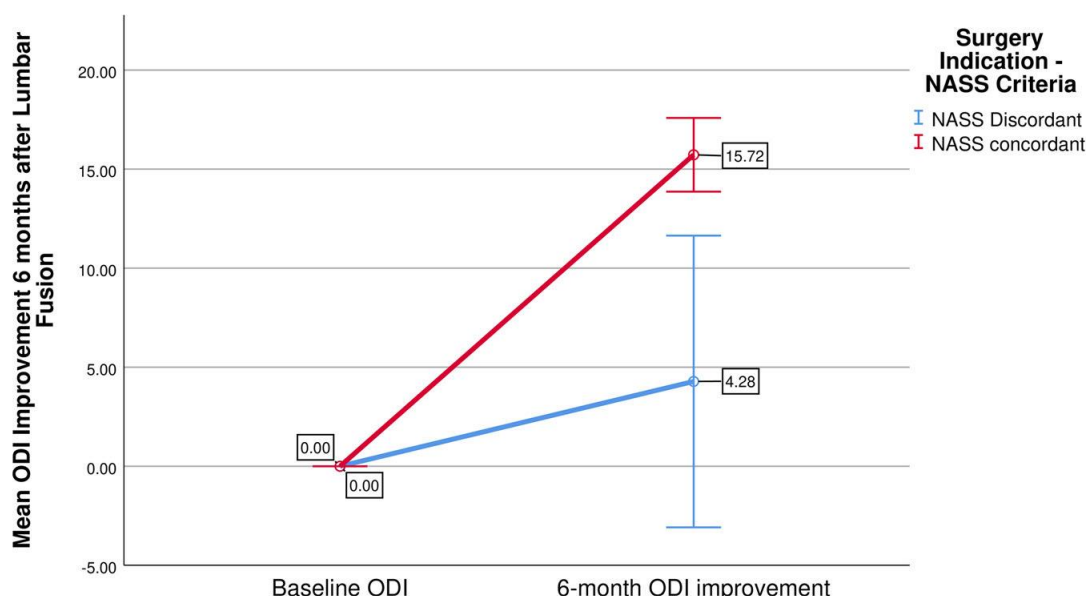
Impact of NASS guidelines

James Harrop et al. Are Guidelines Important? Results of a Prospective Quality Improvement Lumbar Fusion Project. Neurosurgery 89:77-84, 2021 DOI:10.1093/neuros/nyab062

- study population consisted of 93.2% (288/309) EBM concordant [with NASS guidelines] patients and 21 (6.8%) EBM discordant patients.
- outcomes of all elective lumbar fusions in the study:



- patients concordant with NASS guidelines had > 3 times improved outcome (Oswestry [ODI] improvement by ≥ 5 points) at 6 months compared to those not meeting fusion criteria. "discordant mean ODI improvement was only 2.14 points compared to 7.86 in the concordant patients, for a mean difference of 5.71 (95% CI: 2.15-9.28; P = .0018)"

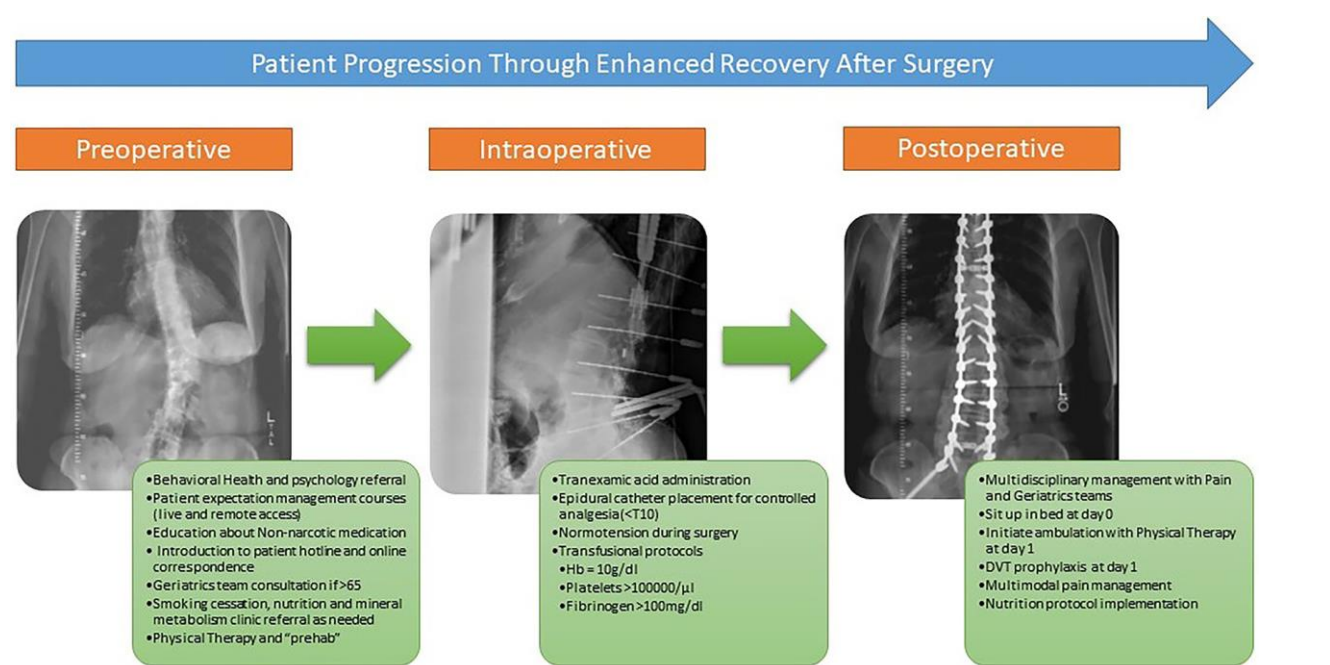


- **primary** lumbar fusion resulted in 2.58 higher odds of reaching MCID over **revision** surgeries.

PATIENT AND OUTCOME OPTIMIZATION, incl. ERAS protocol

Surgical risk calculator (based on ACS NSQIP database):

<https://riskcalculator.facs.org/RiskCalculator/PatientInfo.jsp>



N.B. components are optional – tailored to patient and type of surgery

PREOPERATIVE

1. Cardiopulmonary consult, pulmonary function tests
2. Diabetes control
3. Malnutrition correction (serum testing, nutritionist consult for nutritional support)
4. Obesity control (weight loss)
5. Osteoporosis testing and treatment
6. Anemia – Epopen, autologous blood donation, CellSaver, intraop TXA
7. Smoking cessation
8. Opioid use evaluation
9. Immunomodulator use (risk of pseudoarthrosis – use **autograft!**)
10. Assess frailty → TUG test (see above) preoperative physical therapy (PT), or “prehab”

Robinson TN, Walston JD, Brummel NE et al. Frailty for surgeons: review of a national institute on aging conference on frailty for specialists. J Am Coll Surg. 2015;221(6):1083-1092.

Preoperative Optimization	
Osteopathology: DEXA T-score -2.6 (BMD 0.62 g/cm²)	teriparatide
Cardiopulmonary: A-Fib/Pacemaker on coumadin (CHADS ₂ score:3)	Cardiology evaluation for perioperative anticoagulation management
History of prior CVA on aspirin	Hematology evaluation for usage of TXA
Nutritional: Obesity- BMI 37; Hypoalbuminemia (albumin 3.1 g/dL) Vitamin D deficiency (25-hydroxyD 16ng/mL)	prehabilitation with Aquatherapy/recumbent bike 3x/week (BMI 31); protein supplementation (1.5g/kg/day); cholecalciferol 2000IU BID
Thirteen drug allergies; depression	Behavioral health evaluation/management
Chronic pain; 90 Morphine milliequivalents/day	Pain Clinic; wean by 50% preop
Postoperative delirium	PreAnesthesia Clinic for perioperative pain control strategy; IV lidocaine
One year of preop optimization (ODI 50 → 62)	

DIABETES

CNS Systematic Review and Evidence-Based Guidelines for Perioperative Spine (2021)

Grade B recommendation: **HbA1c >7.5 mg/dL** is associated with an increased risk of **reoperation** or **infection**.

- **insufficient evidence** to support other preoperative diagnostic studies (e.g. preoperative blood glucose levels).

OBESITY

CNS Systematic Review and Evidence-Based Guidelines for Perioperative Spine (2021)

Insufficient evidence: if **BMI** correlates with greater risk of **reoperation** or **infection**.

- given the number of studies demonstrating a correlation between a **BMI > 30 kg/m²** and **SSI**, particularly with **lumbar surgery**, the task force recommends that clinicians counsel patients with elevated BMI regarding this possible risk.

Post hoc retrospective subgroup analysis of SPORT

Rihn JA et al. Does obesity affect outcomes of treatment for lumbar stenosis and degenerative spondylolisthesis? Analysis of the Spine Patient Outcomes Research Trial (SPORT). Spine. 2012;37(23):1933-46

- treatment outcomes for 376 lumbar stenosis and degenerative spondylolisthesis patients.
- incidence of **intraoperative complications** was significantly lower in the obese patient group;
- trend toward **increase rate of wound infection** in the obese patients (5% vs. 1%, p=0.051).
- at 4 year follow-up, there was a significantly **higher rate of reoperation** in the obese patient group (20% vs. 11%, p=0.013).

- at 4 year follow-up in the **nonoperative group**, obese patients had **SF-36 physical function scores that worsened** from baseline by a mean of 3.5 compared to a mean improvement of 13.9 points in the nonobese group (p<0.001).
- the **treatment effect for the SF-36 Physical Function score** was significantly higher for the obese surgical patient group (25.6 vs. 14, p=0.004) suggesting that **surgery has a significantly greater benefit (over nonsurgical treatment) of degenerative spondylolisthesis in obese patients.**

SMOKING

CNS Systematic Review and Evidence-Based Guidelines for Perioperative Spine (2021)

Grade B recommendation: Smoking is associated with increased risk of reoperation* in patients undergoing spinal fusion.

- **insufficient evidence** that cessation of smoking before surgery decreases risk, but it is suggested that patients be counseled to abstain from smoking before and after spinal fusion surgery.

*both for pseudoarthrosis and infection

- nicotine-free for 6 wk before planned surgery - nicotine levels drawn on the morning of surgery - smoking is ground for the cancellation of elective cases.
- **urine test** - positive cutoff:
 Nicotine 2 ng/mL
 Cotinine 5 ng/mL (< 100 ng/mL is used for surgery qualification)

MALNUTRITION

CNS Systematic Review and Evidence-Based Guidelines for Perioperative Spine (2021)

Grade B recommendation: serum albumin < 3.5 g/dL or prealbumin < 20 mg/dL* is associated with a higher rate of surgical site infections (SSIs), other wound complications, nonunions, hospital readmissions, and other medical complications after spine surgery. In at-risk individuals, clinicians should assess nutritional status preoperatively and counsel patients on the potential for adverse events.

- **insufficient evidence** to recommend non-serological assessments.**
- **multimodal nutrition management***** decreases albumin and electrolyte deficiencies in patients with normal preoperative nutritional status. It also improves overall complication rates but does not specifically impact SSIs.

Insufficient evidence: In patients with malnutrition, to support perioperative multimodal nutrition management (MNM) to decrease risks.

*other known serological parameters of malnutrition: low total protein, albumin/globulin, transferrin, and retinol-binding protein.
 **anthropometric measurement [arm or calf circumference, hip/waist ratio] or questionnaires [Mini Nutritional Assessment]
 ***e.g. protein and carbohydrate supplements, early feeding

OSTEOPOROSIS

CNS Systematic Review and Evidence-Based Guidelines for Perioperative Spine (2021)

Grade B recommendation: preoperative testing with one of tests - **DEXA (dual-energy X-ray absorptiometry) scan (T-score ≤ 2.5)**, **CT (Hounsfield units < 97.9)**, **serum vitamin D3 level (< 20 ng/mL)** - predicts increased risk of osteoporosis-related adverse events after spine surgery.

Grade B recommendation: preoperative osteoporosis treatment with **TERIPARATIDE** increases BMD, induces earlier and more robust fusion, and may improve select patient outcomes.

Insufficient evidence regarding preoperative treatment with bisphosphonates alone.

- DEXA scan in patients > 60 yo (do not operate if < 2.5).

SCORE (Simple Calculated Osteoporosis Risk Estimation) - screening questionnaire for osteoporosis - to screen patients to determine if DEXA is necessary.

Lydick E et al. "Development and validation of a simple questionnaire to facilitate identification of women likely to have low bone density." Am J Man Care 1998; 4:37-48.

Variable	Score	If Woman
Race	5	is NOT black
Rheumatoid Arthritis	4	HAS rheumatoid arthritis
History of Fractures	4	for EACH TYPE (wrist, rib, hip) of nontraumatic fracture after age 45 (maximum score = 12)
Age	3	times first digit of age in years
Estrogen	1	if NEVER received estrogen therapy
Weight	-1	times weight divided by 10 and truncated to integer

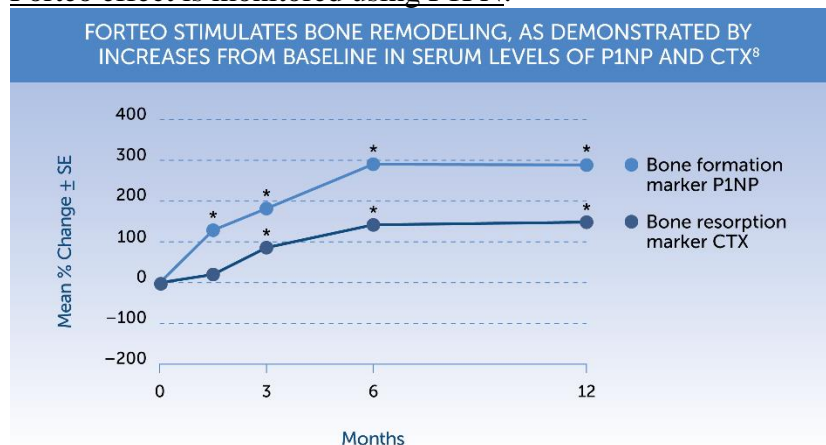
SCORE equals sum of above.
 EXAMPLE: A 126-pound, 67-year-old white woman with a history of rheumatoid arthritis, no history of fractures, and a history of estrogen therapy would have a SCORE of 15, or 5 (for race) + 4 (for rheumatoid arthritis) + (4 x 0) (for no history of fracture) + (3 x 6) (for age) + 0 (for previous estrogen therapy) - (1 x 12) (for weight). Since 15 is greater than the threshold score of 6, this woman should be referred for bone densitometry.

Score ≥ 6 (89% sensitivity and 50% specificity) → DEXA

TERIPARATIDE (Forteo) – **first (N-terminus) 34 amino acids of parathyroid hormone (PTH)** which is the bioactive portion of the hormone - effective anabolic (promoting bone formation) agent.

- should not be prescribed for **patients at increased baseline risk for osteosarcoma** (e.g. those with Paget's disease, unexplained AlkPhos elevations, pediatric and young adult patients with open epiphyses, prior radiation therapy involving skeleton)
- 20 mcg subQ daily for maximum 2 years.
- multi-dose prefilled delivery device (pen) containing 28 daily doses of 20 mcg – price 2500-4000 USD per month.

Forteo effect is monitored using P1PN:



P1NP=procollagen type 1 N-terminal propeptide.
 CTX= Carboxy-Terminal cross-linked telopeptide of type 1 collagen.

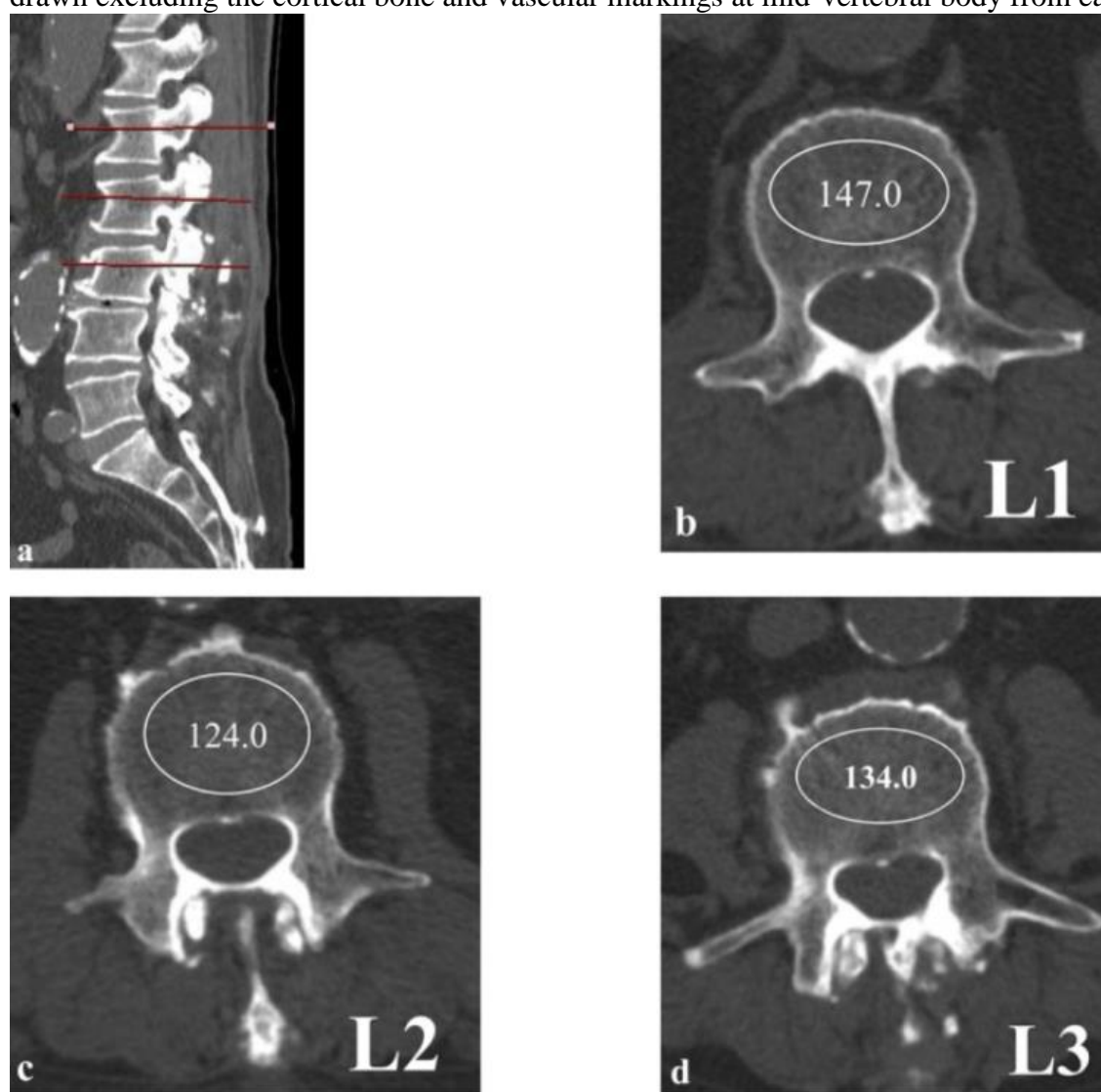
- Forteo / surgery timeline: **surgery after 6 mos of use** as Forteo is approved for 2 years – patient can continue postop.

Diagnosing osteoporosis on lumbar spine CT

Kyung Joon Kim et al. Hounsfield Units on Lumbar Computed Tomography for Predicting Regional Bone Mineral Density. Open Med (Wars). 2019; 14: 545–551. Published online 2019 Jul 19. doi: 10.1515/med-2019-0061

- HU obtained from lumbar CT showed a significant correlation with BMD (bone mineral density) based on quantitative CT and DEXA scan.
- **HU value threshold of 146** on lumbar CT was the most sensitive (94.3%) and specific (87.5%) single measurement for assessment of osteoporosis - might be useful for predicting osteoporosis before spine fusion surgery.

Hounsfield Units measurement by drawing elliptical ROI on lumbar CT scan. The largest ROI is drawn excluding the cortical bone and vascular markings at mid-vertebral body from each vertebra:



PULMONARY

CNS Systematic Review and Evidence-Based Guidelines for Perioperative Spine (2021)

Grade B recommendation: risk factors for postoperative pulmonary adverse events*:

- 1) **functional dependence** – risk 2-5 fold
- 2) **advanced age** [≥ 65 yr] – risk 1.06-9.5 fold
- 3) **weight loss** – risk 3-8 fold
- 4) **COPD** – risk 2.7-4 fold
- 5) **CHF** – risk 2.6-3 fold
- 6) **obstructive sleep apnea** – risk 3 fold
- 7) **coagulopathy** – risk 4-6 fold
- 8) **anemia** – risk 1.5-2 fold
- 9) **steroid use** – risk 1.6-2 fold
- 10) **obesity** – risk 2 fold
- 11) **smoking** – risk 1.5 fold
- 12) **myelopathy** – risk 3-4 fold**
- 13) **opioid use disorder** – risk 3-5 fold**

Insufficient evidence to support any specific preoperative **diagnostic test** for predicting the risk of postoperative pulmonary adverse events or any **treatment intervention***** that reduces risk.

*postoperative pulmonary complications: pneumonia, reintubation, prolonged (> 48 hrs) ventilation, venous thromboembolism [VTE].
 **results of only one study so insufficient evidence.
 ***examples: deep breathing exercise, inspiratory muscle training, preoperative incentive spirometry

OPIOID USE EVALUATION

CNS Systematic Review and Evidence-Based Guidelines for Perioperative Spine (2021)

Grade B recommendation: any preoperative **opioid use** and **longer duration** of use are associated with chronic postoperative opioid use, higher **complications**, increased **length of stay**, higher **costs**, and **worse outcome*** after spine surgery.

Insufficient evidence** of efficacy of **opioid wean** before spine surgery.

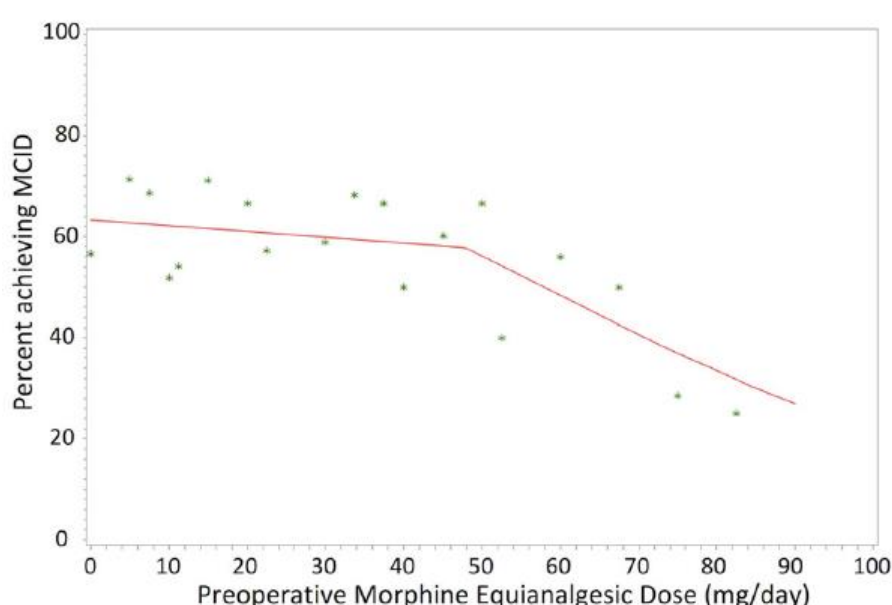
*incl. lower return to work rate
 **report of only single Level II study: patients were taken off opioids for a 3- to 489-mo prescription-free “drug holiday” before 1 or 2- level posterior lumbar fusion surgery and had risks of adverse outcomes (ED visits, readmissions, wound dehiscence and infection) similar to opioid-naïve patients, and lower than patients who had preoperative opioid prescriptions sustained for > 6 mo.

Importance of preoperative opioids on pain outcomes

JB Wick et al. “Is There a Preoperative Morphine Equianalgesic Dose that Predicts Ability to Achieve a Clinically Meaningful Improvement Following Spine Surgery?” Neurosurgery 83:245–251, 2018

- 543 cervical and 1293 lumbar patients (26% cases were revision surgeries)
- 55.5% patients used preoperative opioids.
- 50.3% of cervical and 61.9% of lumbar patients achieved MCID (minimum clinically important difference - 17.3% improvement for neck disability index for cervical patients / 14.9% improvement for Oswestry disability index for lumbar patients) at 12 mos postop.
- the best fit curve representing mean percentage of patients achieving minimum clinically important difference (MCID) on the Oswestry Disability Index or Neck Disability Index at 12 mo after lumbar or cervical surgery, respectively, vs preoperative morphine equianalgesic (MEA) dose in mg/d.
 - the change point occurred at an **MEA dose of 47.8 mg/d (with a 95% credible interval of 29.0 to 60.0 mg/d)** – for such patients, it may be appropriate to withhold surgery and instead refer to a pain management specialist or psychiatrist for preoperative opioid weaning; authors recommend as a cutoff to use 29 mg/d because it is roughly equivalent to commonly used regimens, such as **oxycodone 10 mg TID**.

Patients with preoperative MEA dose exceeding 47.8 mg/d are significantly less likely to achieve MCID



- preoperative opioid use is associated with decreased scores on postoperative patient-reported outcome (PRO) measures in spine surgery (worse outcomes are likely multifactorial, including concurrent psychiatric distress in those on opioids; plus, opioid-dependent individuals experience hyperalgesia due to altered cellular physiology and an abnormal pain response).
- total 30% of all spine surgery candidates use > 29 mg MEA/d preop!

Preoperative Opioid Use and Clinical Outcomes in Spine Surgery

Preoperative Opioid Use and Clinical Outcomes in Spine Surgery: A Systematic Review. Ketan Yerneni et al. Neurosurgery, Volume 86, Issue 6, June 2020, Pages E490–E507

In patients undergoing surgery for lumbar degenerative disease, preoperative opioid use was significantly associated with: higher inpatient narcotic consumption,¹³ higher postoperative opioid use,^{10·12·22·23·25·27·29·31·34·41·44} decreased opioid independence at 12 mo postoperatively,²² an increased chance of function failure postoperatively,¹⁴ worse patient-reported outcomes (12-Item Short Form Health Survey [SF-12], EuroQol-5D [EQ-5D], Oswestry Disability Index [ODI], Neck Disability Index [NDI], Numeric Rating Scale [NRS] scores),^{11·20} higher visual analog scale (VAS) scores for low back pain,⁴⁶ lower physical component score (PCS) and mental component summary (MCS) scores,⁴⁶ greater disability postoperatively,⁴⁶ higher preoperative Modified Somatic Perception Questionnaire [MSPQ] scores,²¹ decreased frequency of urinary retention,⁴² increased hospital length of stay,^{3·26·30·32·33} higher medical costs,^{3·10·26·33} gastrointestinal and urinary problems,²⁶ higher odds of not achieving meaningful improvements in function,³⁴ quality of life,³⁴ dissatisfaction,³⁴ 90-d complications,³⁴ extremity pain,³⁴ axial pain,³⁴ higher pain diagnoses,¹⁰ emergency department (ED) visits,¹⁰ readmission,¹⁰ 90-d wound complications,¹⁰ worse functional outcomes postoperatively,²⁹ increased patient mortality,³⁰ aggregate morbidity,³⁰ induced mental disorder,³⁰ respiratory failure,³⁰ surgical site infection,^{3·30} mechanical ventilation,³⁰ pneumonia,³⁰ myocardial infarction,³⁰ postoperative ileus,³⁰ nonroutine discharge,³⁰ failure to rescue,³⁰ device-related complications,³ hematoma- or seroma-related complications,³ acute posthemorrhagic anemia,³ and pulmonary insufficiency.³

In patients undergoing surgery for cervical degenerative disease, preoperative opioid use was significantly associated with: elevated inpatient narcotic consumption,¹³ higher postoperative opioid use,^{22·29·34·40·41} reduced overall clinical success,⁴⁷ higher hospitalization duration,^{30·33} higher medical costs,³³ worse patient-reported outcomes (SF-12, EQ-5D, ODI, NDI, NRS scores),^{11·20} worse functional outcomes after surgery,²⁹ increased donor site pain at 1 and 2 wk after harvest of tricortical anterior iliac crest bone graft (AICBG) for ACDF,⁴⁸ higher preoperative MSPQ scores,²¹ decreased opioid independence at 12-mo postoperatively,²² decreased frequency of urinary retention,⁴² higher odds of not achieving meaningful improvements in function,³⁴ quality of life,³⁴ dissatisfaction,³⁴ increased likelihood of 90-d complications,^{34·39} extremity pain,³⁴ axial pain,³⁴ higher risk of all-cause 90-d ED visits, higher pain-related ED visits, reoperation,³⁹ receiving epidural or facet joint infections within 1 yr postoperatively,³⁹ increased patient mortality,³⁰ aggregate morbidity,³⁰ induced mental disorder, respiratory failure, surgical site infection,^{3·30} mechanical ventilation,³⁰ pneumonia,³⁰ myocardial infarction,³⁰ postoperative ileus,³⁰ nonroutine discharge,³⁰ and failure to rescue.

INTRAOPERATIVE

1. Skip **Foley catheter**
2. Prefer **Monitored Anesthesia Care (MAC)**
3. **Blood loss control** - intraoperative **Hb target ≥ 10 g/dL**.
 - **FFP** is given after each 3 units of pRBC.
 - **platelets** are given after every 5 units of pRBC for a goal 100 000/microliter.
 - **cryoprecipitate** is administered for a goal concentration of fibrinogen of < 100 mg/dL.
 - **TXA** administration

Pernik MN, Dosselman LJ, Aoun SG et al. The effectiveness of tranexamic acid on operative and perioperative blood loss in long-segment spinal fusions: a consecutive series of 119 primary procedures. published online: January 24, 2020. J Neurosurg Spine.
4. **Epidural analgesia** for cases < T10 (not possible in patients undergoing fusion to the mid to high thoracic levels).
 - **motor block** - reversible bilateral lower extremity weakness that had no structural cause on imaging and resolves before discharge from the inpatient setting after epidural catheter is removed.

POSTOPERATIVE

1. **Early mobilization:**
 - 1) **Sit up** in bed on POD0, out of bed for every meal
 - 2) **Ambulate** with PT on POD1 - key element to ERAS
 - patients undergoing spine surgery experience fear of reinjury through exercise and movements (**kinesiophobia**), which is linked to fear-avoidance behavior and diminished postoperative activity.
2. **DVT prophylaxis** – SCD on POD0, chemical on POD1
3. **Pain management** team consult
4. **Geriatrics** consult

Michigan study - early (within 8 hours) postop ambulation – lumbar, cervical

Lim, Seokchun et al. Validation of the Benefits of Ambulation Within 8 Hours of Elective Cervical and Lumbar Surgery: A Michigan Spine Surgery Improvement Collaborative Study. Neurosurgery: September 2022 - Volume 91 - Issue 3 - p 505-512

- 7647 cervical and 17 616 lumbar cases were divided into 3 cohorts based on time to ambulate after surgery: (1) < 8 hours (68% patients), (2) 8-24 hours, and (3) > 24 hours.
 - ambulation = patient up and walking any distance (either assisted or unassisted); vs. any transfer to bed, chair, or bedside commode did not count as ambulation.
 - logistical challenges for implementation - cases may end late in the afternoon.

- minimally invasive approaches were not considered in analysis.
- **exclusion** - surgery for nondegenerative and complex pathology (ie, spinal cord injury, traumatic fracture, pre-existing infection, grade 3 or 4 spondylolisthesis, scoliosis greater than 25°, congenital anomalies, > 4 level fusion), intraoperative durotomy or suspected CSF leak.
- **complication rate (cervical cases)** - complication adjusted odds ratio [aOR] increased with delayed ambulation:
 - ambulated at 8-24 hours (aOR 1.38; 95% CI 1.11-1.70; P = .003)
 - ambulated at > 24 hours (aOR 2.20; 95% CI 1.20-4.03; P = .011)
- **complication rate (lumbar cases)** - complication adjusted odds ratio [aOR] increased with delayed ambulation:
 - ambulated at 8-24 hours (aOR 1.31; 95% CI 1.12-1.54; P < .001)
 - ambulated at > 24 hours (aOR 1.96; 95% CI 1.50-2.56; P < .001)
- **secondary outcomes:**
 - cervical cases, < 8-hour ambulation was associated with home discharge, shorter hospital stay, lower 90-day readmission, and lower urinary retention rate.
 - lumbar cases, <8-hour ambulation was associated with shorter hospital stay, satisfaction with surgery, lower 30-day readmission, home discharge, and lower urinary retention rate.
- **caveats:** patients who ambulated at > 24 hours had undergone generally more invasive surgeries; patients with less functional derangement / lower comorbidity burden could be expected to be able to ambulate earlier after surgery, if encouraged to do so (in multivariate model, study was able to account for factors available, in particular baseline PROMIS-PF).

MINIMALLY INVASIVE SURGERY (MIS)

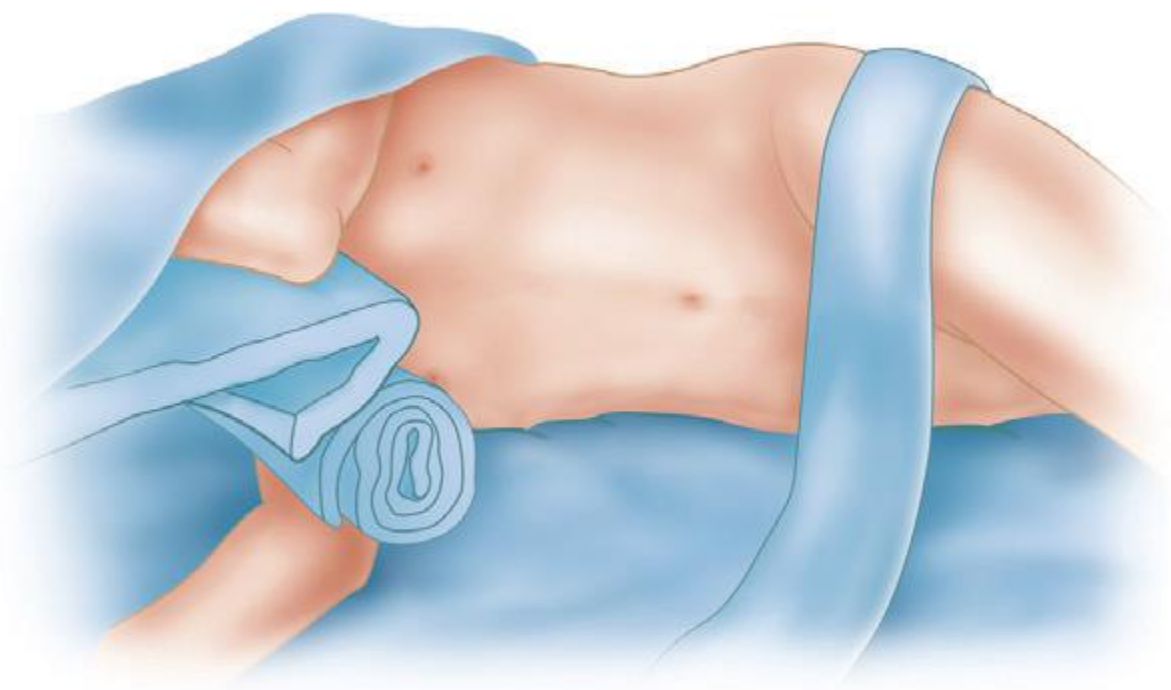
- posterior muscle sparing procedure; it is OK to make midline skin incision and then dissect skin flap of fascia → make stab lateral incisions in fascia.

AXIS TABLE

- see p. Op140 >>
Should be ideally used for every thoracolumbar fusion (shoot lateral XR after positioning)!

LATERAL DECUBITUS POSITION

- axillary roll underneath upper chest region - to protect brachial plexus.
- arms are gently flexed at elbow and supported on double arm rest (alternative - lower arm is extended on abducted regular arm board).



- elbows must be well padded (protecting the ulnar nerve)
- lower leg is positioned relatively straight on pillow (protecting peroneal nerve); upper leg is also positioned on pillow with knee and hip flexed and taped down so as to relax ipsilateral psoas muscle for easier retraction during surgery.
- desired level should be placed on break of bed, and table is flexed for optimal access to intercostal interval.
- make sure patient remains at 90 degrees to floor!

BONE GRAFTS

- see p. Op210 >>

INTERBODY CAGES

Ti vs PEEK in Interbody Fusion

Property	Titanium	Polyetheretherketone (PEEK)
Introduction to market	1980s	1990s
Elasticity	Higher	Lower
Radiodensity	Radiopaque	Radiolucent
Modulus	100–110 GPa	3.5 GPa
Promotion of osseointegration	Higher	Lower
Subsidence rates	Higher	Lower
Risk of metal allergy	Yes	No

Ti-coated PEEK spacers

- Possibly better integration in bone than PEEK implants.
- Ti-coating has been shown to detach significantly in experimental models
- Have not been compared to either PEEK or Ti spacers. Encouraging outcomes.

DIFFERENT METALS

- stainless steel (old hardware) should not contact with titanium but in certain circumstances it might be OK.

BROKEN SCREWS

- distal segments of broken screws are removed utilizing the **reamer** (to ream the cuff of bone void around screw shaft), then the **reverse-thread female screw driver** is applied to undo the screw shaft.

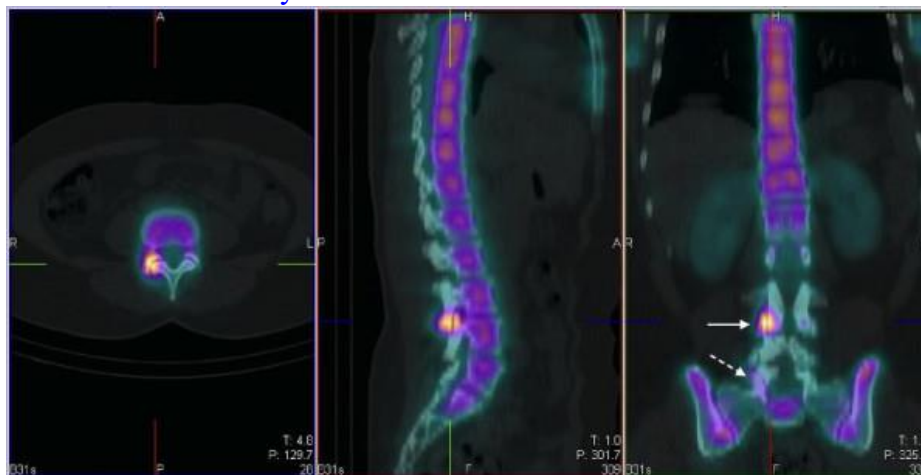
HARDWARE REMOVAL

- removal of rods with **laminar hooks**: make preop diagram which hooks are facing which direction; then drill lamina along heel of the hook, then rotate hook.

Definition of instability, Principles of spondylolisthesis treatment

Indication for fusion – features showing (**predisposition for**) instability!

- 1) unstable* on **dynamic imaging** (> 10 degrees of angulation or > 3-4 mm of relative motion)
 - ≥ 4 mm translation is criterion used by USA insurance companies.
 - it can be determined by:
 - a) dynamic (flexion-extension) XR
 - b) comparing upright standing XR with supine MRI
- 2) **facet-joint edema** - joints are likely to be unstable, even if they appear stable on dynamic imaging; **synovial cyst** – means instability (do dynamic XR!)
- 3) **tall disk***
- 4) **sagittally-oriented facets**
- 5) **back pain improved with facet blocks**
- 6) “hot” facets on SPECT study:



Spondylolisthesis should not be confused with “instability” - there are obvious differences between spondylolisthesis patients:

- a) **large disk***, **bulky fluid-filled sagittally-oriented facets**, and **dynamic instability*** → decompression with fusion.
 - *significant motion, large tall disc – strong indications to add *interbody graft* (if performing posterior fusion)
- b) **collapsed disk with fixed spondylolisthesis** – despite slip progression, a stable degenerative spondylolisthesis can be adequately treated with decompression alone, albeit with a 34%* rate of revision surgery due to development of instability (vs. 14%* or 22%** if fusion was used)
 - *Ghogawala Z et al. *Laminectomy plus fusion versus laminectomy alone for lumbar spondylolisthesis*. *N Engl J Med* 2016; 374: 1424-34.
 - **Försth P et al. *A randomized, controlled trial of fusion surgery for lumbar spinal stenosis*. *N Engl J Med* 2016; 374: 1413-23

N.B. the results of reoperation may be worse than the results of the original surgery, and the health care costs may be high, especially considering that most patients with lumbar stenosis are elderly!

N.B. flex–ex radiography has low accuracy (measurement errors of up to 4 mm)

Swedish school – decompress and do not fuse! If back pain gets worse, then do fusion!

N.B. every patient should get upright XR before simple decompression (not to miss instability)

- there is no clear evidence that radiologic instability is associated with pain and impaired function in the individual patient.
- **L4-5 spondylolisthesis** – some experts do *two-level fusion* L4-S1.

NASS Clinical Guidelines for Degenerative Lumbar Spondylolisthesis (2nd ed., 2014):

There is the *lack of uniform reference standards* to define instability.

Direct surgical decompression alone may be **considered** for symptomatic stenosis associated with **low grade degenerative lumbar spondylolisthesis** when symptoms have been recalcitrant to a trial of medical/interventional treatment (grade of recommendation: C).

- *insufficient evidence* for or against **indirect** surgical decompression (e.g. X-STOP device).
- **decompression with fusion** is **suggested** to **improve clinical outcomes** compared with decompression alone or compared to medical/ interventional treatment alone (grade of recommendation: B);
 - may be **considered** as a means to provide **satisfactory long-term (> 4 yrs) results** (grade of recommendation: C).
 - *insufficient evidence* for MULTILEVEL spondylolisthesis.
- for symptomatic **single-level** degenerative spondylolisthesis that is **low-grade (< 20%)** and **without lateral foraminal stenosis**, **decompression alone with preservation of midline structures provides equivalent outcomes** when compared to **surgical decompression with fusion** (grade of recommendation: B).

- addition of instrumentation is **suggested** to improve fusion rates but is **not suggested** to improve clinical outcomes for symptomatic spinal stenosis and degenerative lumbar spondylolisthesis (grade of recommendation: B).
- insufficient evidence for or against the use of spondylolisthesis reduction with fusion.
- insufficient evidence for or against the use of autogenous bone graft or bone graft substitutes in posterolateral fusions.
- conflicting evidence which technique leads to better outcomes - minimally invasive or open decompression and fusion, with or without instrumentation.
- insufficient evidence for or against decompression with posterolateral fusion vs. 360° fusion (vs. for isthmic spondylolisthesis).

(360° fusion = PLIF)

Indications for interbody fusion – see PLIF >>

NASS Clinical Guidelines for Adult Isthmic Lumbar Spondylolisthesis (2014):

Insufficient evidence for or against surgical treatment as compared to medical/ interventional alone. Fusion is suggested to provide long term clinical improvements (grade of recommendation: B). Insufficient evidence to indicate that fusion leads to improved long term outcomes as compared with a directed exercise program. Insufficient evidence to recommend one surgical fusion technique over another to improve long term outcomes. For low-grade isthmic spondylolisthesis, the addition of instrumentation to posterolateral fusion may not improve outcomes (grade of recommendation: B). 360° fusion is recommended to provide higher radiographic fusion rates compared to posterolateral fusion; there is conflicting evidence whether 360° fusion provides better clinical outcomes than posterolateral fusion alone. ALIF may be considered as option to indirectly decompress foraminal stenosis (grade of recommendation: C). Insufficient evidence to make a recommendation regarding which prognostic factors have been associated with good or poor surgical outcomes.

- when reducing spondylolisthesis, use free running EMG.
- if nerve root compression is far lateral, outside confines of spinal canal – simple decompression will not work – need radical decompression (Gill procedure) plus fusion

SPINAL DEFORMITY

NREF videos: <https://www.youtube.com/playlist?list=PLRrYUcBdtXzrIc-YauW4ZfvTFBPWfQLHU>

Scoliosis aspects – see p. Spin29 >>

SurgiMap – free planing software for download: <https://www.surgimap.com>

Every spine surgeon is a deformity surgeon – either correcting one or creating one!

Dr. Lenke tips:

- 1) ask patient to get onto the table unassisted and lay prone – if patient is unable to do it = unfit for deformity surgery.
- 2) keep spine flexible – do not fuse if you can! No surgery cures deformity – if patient lives long enough, spine will degenerate above and below.
- 3) deformity spine surgery always posterior approach (since year 2000).

Prevalence: up to 68% in patients > 50 yo.

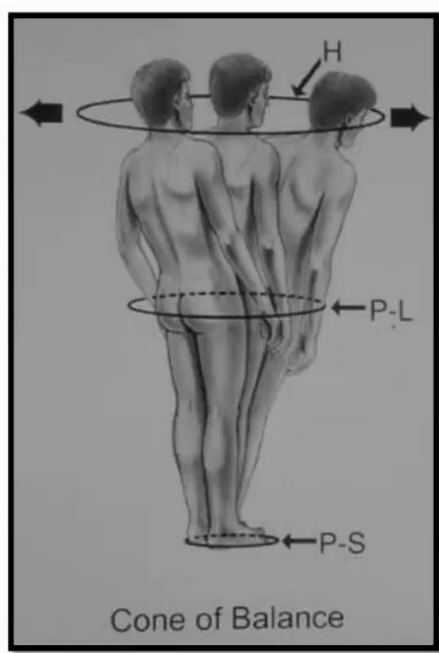
Plane:

- Coronal
- Sagittal

N.B. be aware of “functional” deformity on scoliosis (spine survey) XR – when patient, despite instructions, leans forward to rest on something due to pain from central stenosis* – such “deformity” may well correct after simple central decompression with laminectomy.

*compare to supine XR

PATHOPHYSIOLOGY



- Poor alignment = disability
- Must compensate for anatomic deformation
- Mechanical disadvantage challenges balance mechanisms

Deviation from stable zone = increase muscular / energy use

Dubousset, J. Three-dimensional analysis of the scoliotic deformity. *Pediatric spine: principles and practice*. Raven Press, New York 1994;15:1026-31.

ETIOLOGY

- Advanced degenerative disease
- Idiopathic scoliosis / kyphosis
- Sarcopenia
- Iatrogenic

PREOP OPTIMIZATION

- especially important! see above >>

IMAGING (SCOLIOSIS FILM, SPINE SURVEY, 36-INCH FILM)

Practically, every patient should be evaluated for sagittal imbalance before fusion (even single level) – **standing 36 inch lateral XR:**

- include femoral heads and C7

- hips and knees extended
- arms flexed at elbows and positioned at a 45° angle in front of the body with both hands resting on clavicles.
- if leg length discrepancy > 2 cm, use standing block to compensate.

EOS® imaging system (s. slot-scanning device or slit-beam digital radiography system) - technology that allows simultaneous acquisition of AP and lateral images of the entire body in a natural, erect position, and is also capable of performing 3D reconstructions from these images.

- unlike conventional x-ray systems, EOS utilizes a thin slit-beam x-ray source (eliminating the need for a grid) that moves superior-inferiorly concurrently in both planes (anterior-posterior and lateral) resulting in two acquisitions in one mechanical motion.
- scan takes longer than normal radiography (10-25 s) but lower radiation dose.
- shows **leg position – can verify that patient is not compensating** by hip extension, knee flexion, feet dorsiflexion, increasing pelvic tilt (that could give pseudo-normal images with normal SVA and PI)

Characteristics of deformity curves: Rigid vs Flexible – determined by:

- side bending XR** (placing bolsters trying to correct curves)
- simple **supine AP XR** – eliminates gravity and allows flexible curves to correct (less operator dependent than bending XR); also reflects patient position on OR table (some experts even try **prone XR** but many deformity patients do not tolerate it).

SAGITTAL IMBALANCE

Read about **Roussouly lumbar lordosis types!**

Classification of normal sagittal spine alignment: re-founding the Roussouly classification. Laouissat F, Sebaaly A, Gehrchen M, Roussouly P. Eur Spine J. 2018 Aug;27(8):2002-2011. doi: 10.1007/s00586-017-5111-x. Epub 2017 Apr 28.

Read about **SRS-Schwab classification** (Spine 2012)

Read about **Global Alignment and Proportion (GAP) score**

- new pelvic-incidence-based proportional method of analyzing the sagittal plane that predicts mechanical complications in patients undergoing surgery for adult spinal deformity.

Sagittal imbalance can be classified into two types:

Type 1 – segmental hyperlordotic or kyphotic segment (patient compensates for imbalance by hyperextension of segments above and below); **corrective osteotomy** is done at **involved segment**.

Type 2 – imbalance across significant segment of spine; spine is flat, and there is segmental loss of kyphosis and lordosis (patient is unable to compensate); more amenable to correction with osteotomy than segmental imbalances (**corrective osteotomy** is done at **lower spine** - greater lever arm correcting axis of view, there are fewer complications related to thoracic viscera and vascular structures, and correction is not hindered by ribs).

- spinopelvic alignment is important to postoperative outcome for adult spinal deformity and isthmic spondylolisthesis surgery.
- sagittal balance has been found to improve post-lumbar decompression in patients with isolated spinal stenosis.
- sagittal imbalance → pain (muscles work inefficiently) + horizontal gaze trouble (tries to compensate with cervical hyperextension) ← affects social independence.

Osteotomies

- multiple-level posterior osteotomies

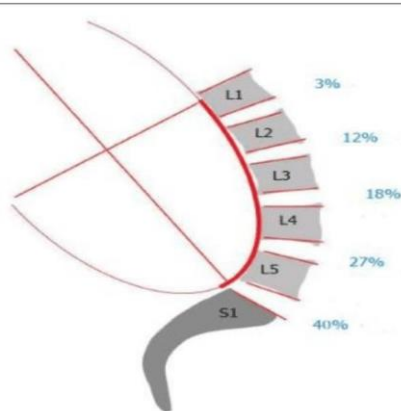
N.B. **corpectomies** and **pedicles subtraction osteotomies** are usually avoided in long-segment cases to mitigate excessive blood loss (+ **multilevel posterior osteotomies** are often sufficient for deformity correction).

Two alternatives:

- osteotomies**; best level is where normally lordosis should be – at L3, 4, 5. *see below >>*
 - ALIF, DLIF, XLIF** – may achieve impressive lordosis with large grafts (TLIF, PLIF cannot fit such grafts).
- extend fusion beyond where thoracic kyphosis begins (e.g. to T4 or 5).
 - most critical part is to mold rod; there are machines that can do it for you (e.g. NuVasive Bendini® Spinal Rod Bending System – 5000\$ disposable).

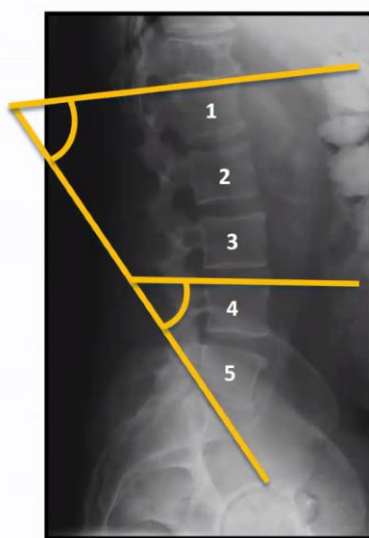
N.B. 60-70% of lumbar lordosis is normally at L4-S1

LORDOSIS DISTRIBUTION INDEX



2/3 of lordosis L4-S1

- Normal Average Lordosis 61° (Range 55° - 65°)
- L4/5 Lordosis 16.8°
- L5/S1 Lordosis 32.4°



Greenberg: normal LL is 20-40 degrees

Standard stop upper levels for posterior instrumentation – either T10 or T4.

TERMINOLOGY

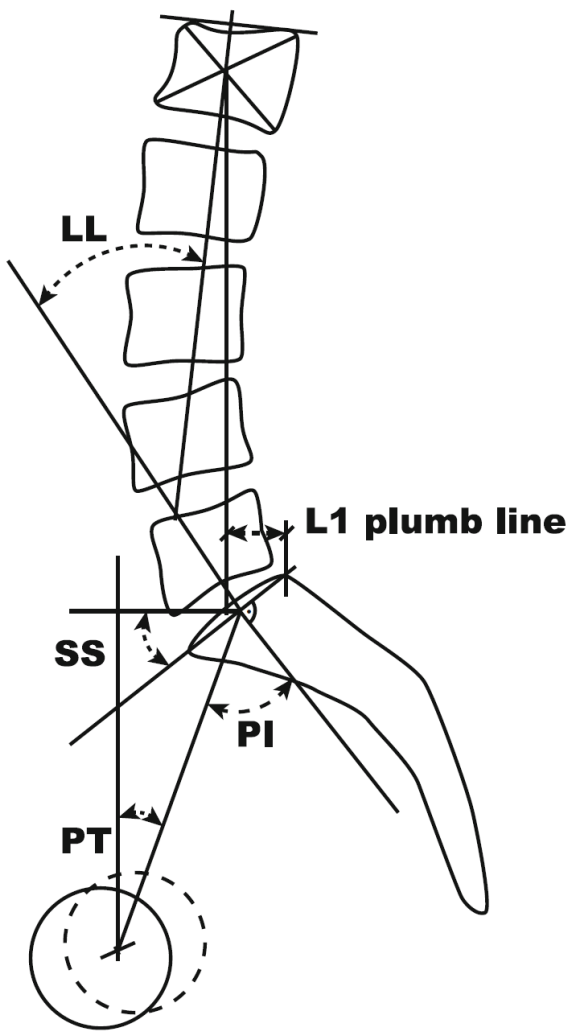
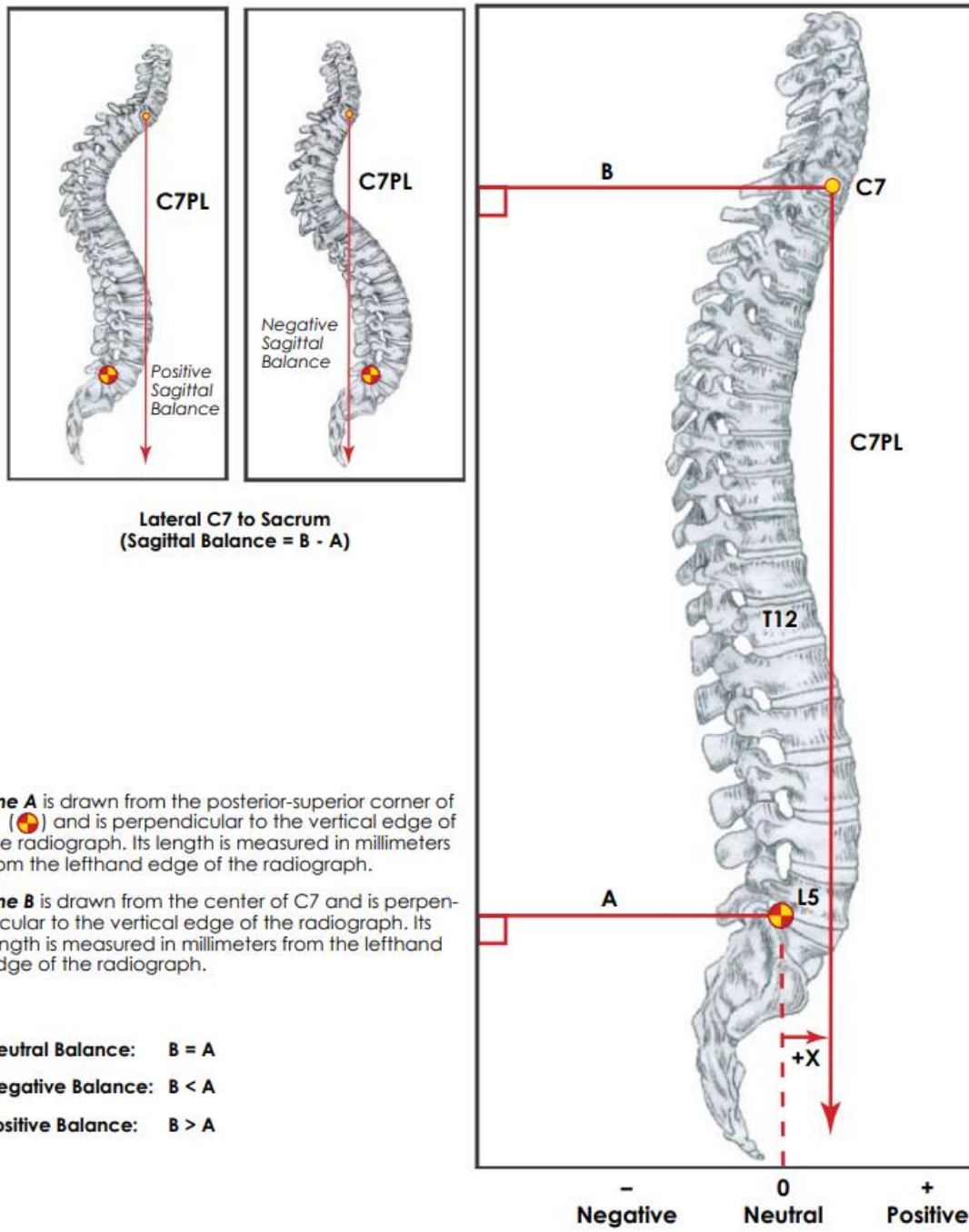
Odontoid-hip axis – most global evaluation of alignment.

Sagittal vertical axis (SVA)

- measured by extending a vertical plumb line from the midpoint of the C7 vertebral body and measuring the distance between this line and the posterosuperior corner of S1.

- general aim for < 50 mm
 N.B. there are studies that report significant unreliability of this goal (SVA < 50) when it comes to patient outcomes.
 Age-related goals:
 Age 50 yrs - SVA < 50 mm
 Age 60 yrs - SVA < 60 mm
 Age 70 yrs - SVA < 70 mm
- positive SVA following the correction of adult spinal deformity is correlated with suboptimal functional outcome and quality of life

Overall Sagittal Balance



Lumbar lordosis (LL) - the sagittal Cobb angle between the superior endplate of L1 and sacral plateau S1.
 Ideal LL = 0.62 x PI + 29

Pelvic incidence (PI) - angle between line perpendicular to S1 endplate at its midpoint and line connecting to midpoint of line connecting centers of femoral heads.

- it is indicator of innate reserve (patient cannot change it) – how much patient can compensate kyphotic tendency by pelvis retroversion (pelvis is like the first vertebra)
- when PI increases, more and more lordosis comes from upper lumbar spine (vs. usual L4-S1 level).
- smaller PI the better: patients with PI-LL mismatch > 10° have a 10-times higher risk of developing adjacent segment disease.

Pelvic Incidence

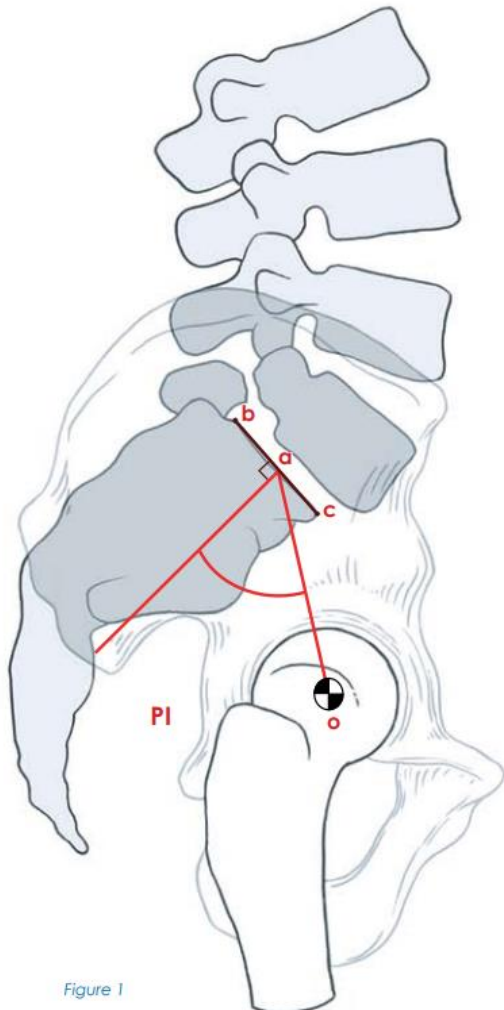


Figure 1

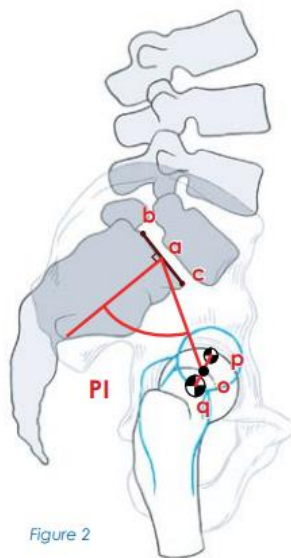


Figure 2

Pelvic Incidence (PI) is defined as an angle subtended by a line that is drawn from the center of the femoral head to the midpoint of the sacral end plate (\overline{oa}) and a line perpendicular to the center of the sacral end plate (a). The sacral end plate is defined by the line segment (\overline{bc}) constructed between the posterior superior corner of the sacrum and the anterior tip of the S1 end plate at the sacral promontory (see Figure 1).

When the femoral heads are not perfectly superimposed, the center of each femoral head is marked (crosshatched circles), and the line segment \overline{qp} will connect the centers of the femoral heads. The line \overline{oa} will be drawn from the center of the line \overline{qp} (o) to the center of the sacral end plate (a) (see Figure 2).

A complete loss of overlap between the femoral heads indicates an oblique view of the pelvis. Adequate sagittal radiographs of the pelvis should be obtained before making any of the proposed sagittal radiological measurements.

Pelvic tilt (PT) - angle between a vertical line through the midpoint of the centers of the femoral head and a line connecting to the midpoint of the endplate of S1.

Patient can change PT: increasing PT means patient is **trying to compensate for lack of lordosis by retroverting pelvis!** (PI is static – patient cannot change it; PT is position dependent)

Ideally, < 20-25 degrees

Pelvic Tilt

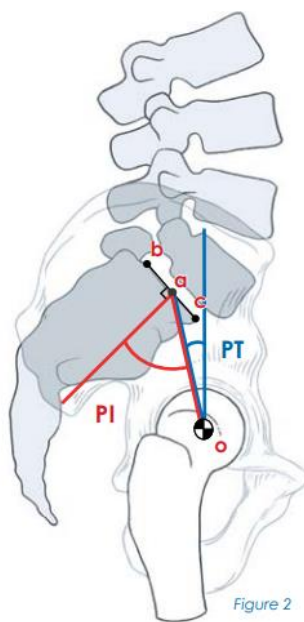
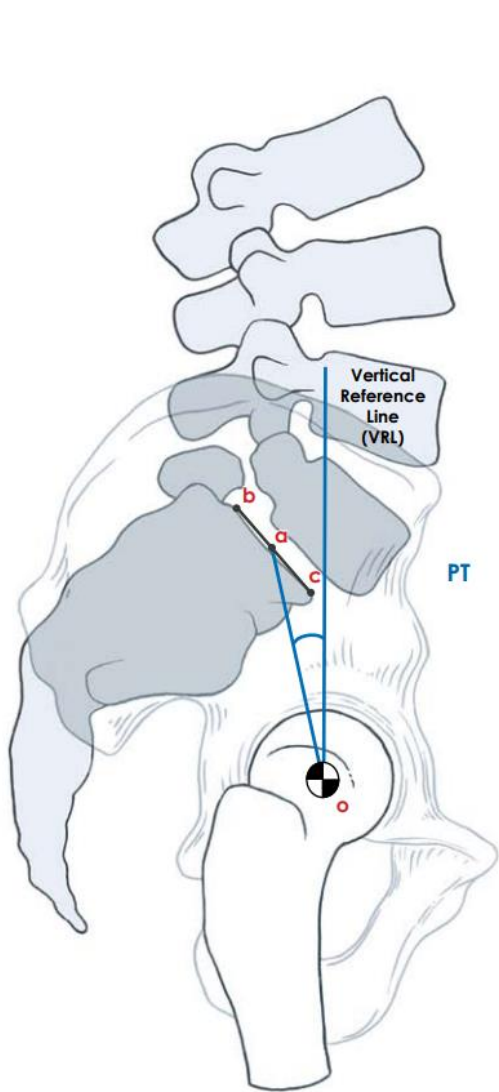


Figure 2

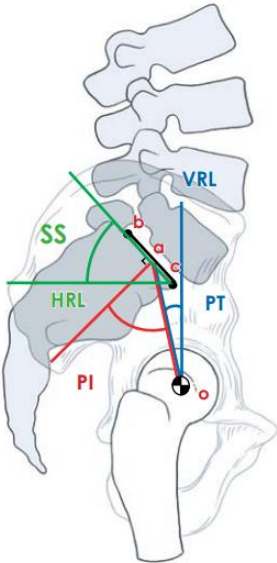
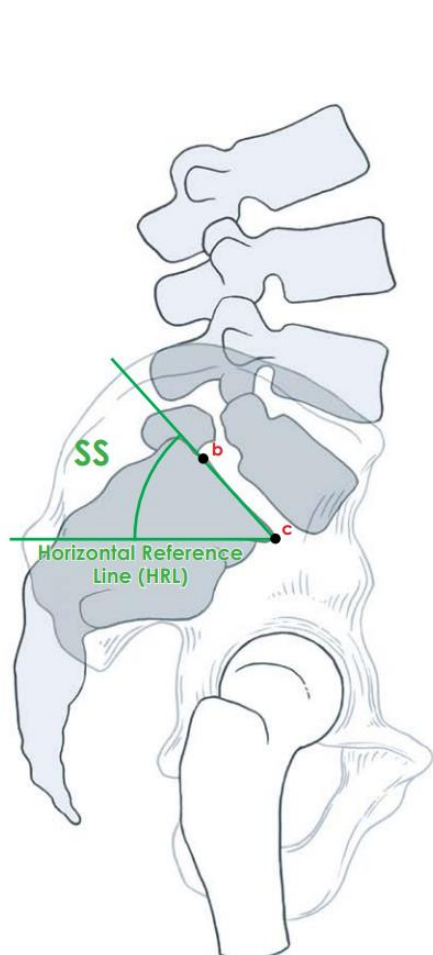
Pelvic Tilt (PT) is defined as the angle subtended by a vertical reference line (VRL) originating from the center of the femoral head (o) and the midpoint of the sacral end plate (a) (see Figure 1).

PT is influenced by PI since they share the line \overline{oa} and the sacral end plate as common reference lines (see Figure 2).

PT has a positive (+) value when line \overline{oa} is posterior to the VRL and a negative (-) value when line \overline{oa} is anterior to the VRL.

Sacral slope (SS) - the angle between a horizontal line and S1 endplate.

Sacral Slope



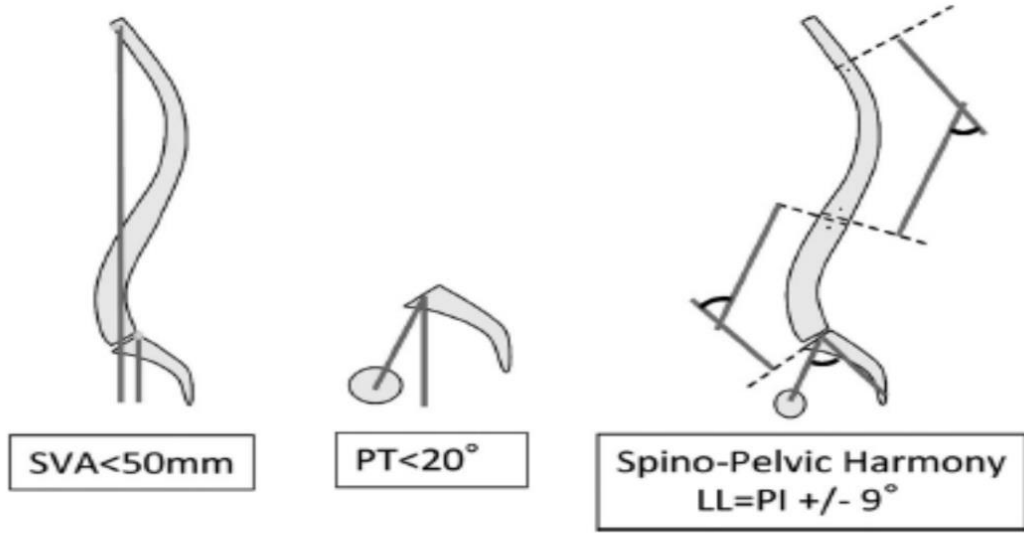
Sacral Slope (SS) is defined as the angle subtended by a horizontal reference line (HRL) and the sacral end-plate line (\overline{bc}) (see Figure 1).

Sacral Slope is related to PI and PT because it shares a common reference line (\overline{bc}) along the sacral end plate (see Figure 2).

It should be understood that PI is measured from static anatomic structures, PT and SS on the other hand are position dependent because they are dependent on the angular position of the sacrum/pelvis in relation to the femoral heads that changes with standing, sitting, and lying down. The relationship of PT and SS are also affected by lumbosacropelvic flexion and extension.

N.B. SVA is dynamic (patient can compensate with stance change), PI is constant

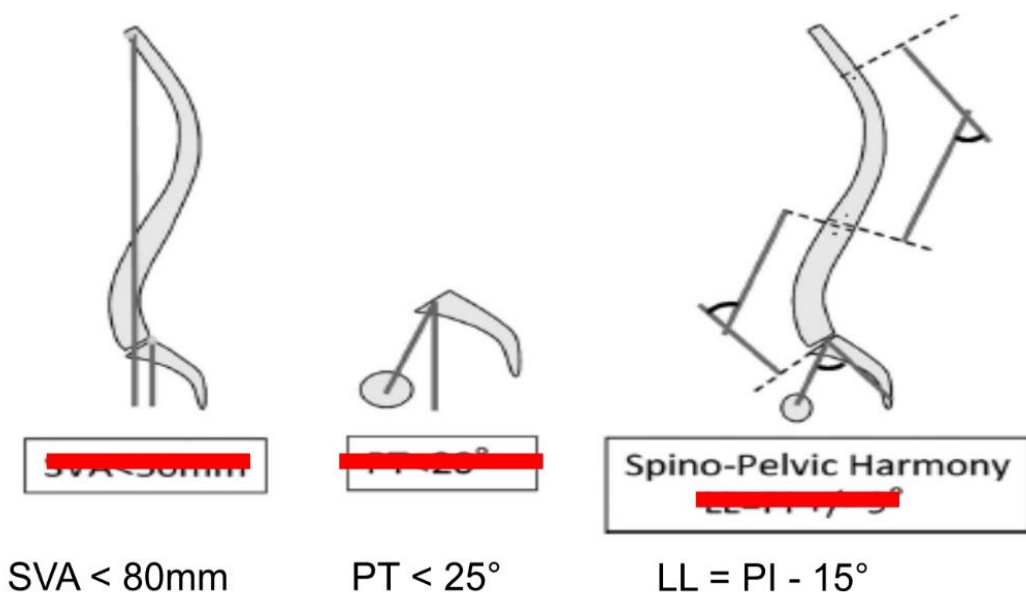
SPINOPELVIC HARMONY



TPA < 20°

Do not aim for ideal for elderly patients!

SPINOPELVIC HARMONY ELDERLY PATIENT



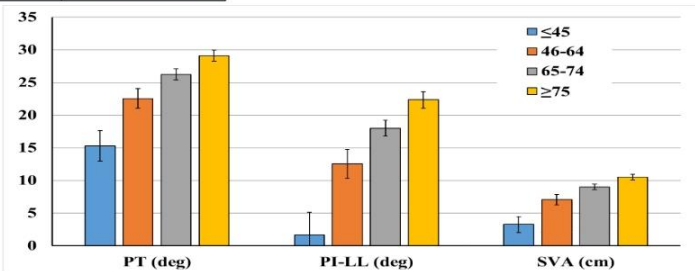
Defining Spino-Pelvic Alignment Thresholds

Should Operative Goals in Adult Spinal Deformity Surgery Account for Age?

Renaud Lafage, MS,* Frank Schwab, MD,* Vincent Chailier, MD,† Jensen K. Henry, BA,* Jeffrey Gum, MD,‡ Justin Smith, MD, PhD,§ Richard Hostin, MD,¶ Christopher Shaffrey, MD,§ Han J. Kim, MD,|| Christopher Ames, MD,** Justin Scheer, BS,** Eric Klineberg, MD,†† Shay Bess, MD,‡‡ Douglas Burton, MD,§§ and Virginie Lafage, PhD*, International Spine Study Group

Age group	Number	PT (deg)	PI-LL (deg)	SVA (cm)
≤45	218	15.3 ± 2.3	1.7 ± 3.5	3.3 ± 1.2
46-64	381	22.6 ± 1.5	12.5 ± 2.2	7.1 ± 0.8
65-74	172	26.2 ± 0.8	18 ± 1.2	9.0 ± 0.4
≥75	62	29.1 ± 0.8	22.4 ± 1.3	10.5 ± 0.4

Multivariate linear regressions identifying correlations between ODI and alignment by age



Thoracic kyphosis

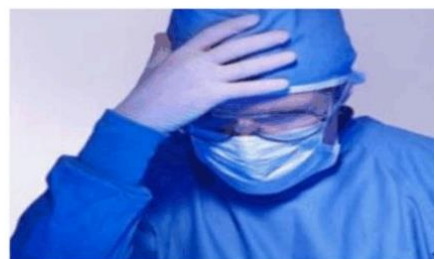T1-4 gives 8-10 degrees of kyphosis
Normal thoracic kyphosis = LL x 0.75

SURGERY

- ALIF (for L5-S1 but heavily dependent on access surgeon) or LLIF – they made PSO obsolete bloody procedures!
- TLIF is kyphosis inducing procedure (or at best – preserving status quo; best TLIF if bilateral with expandable cage, ALL release, and posterior compression)
- PSO traditionally done at L2-3 (below conus) but that is not where normal physiologic lordosis should be; best PSO at L4-5 levels.
- for long fusions extending distally to L5-S1 need extra support for S1 screws:
 - a) L5-S1 interbody cage.
 - b) iliac screws + small amount (≥ 4 mg BMP).

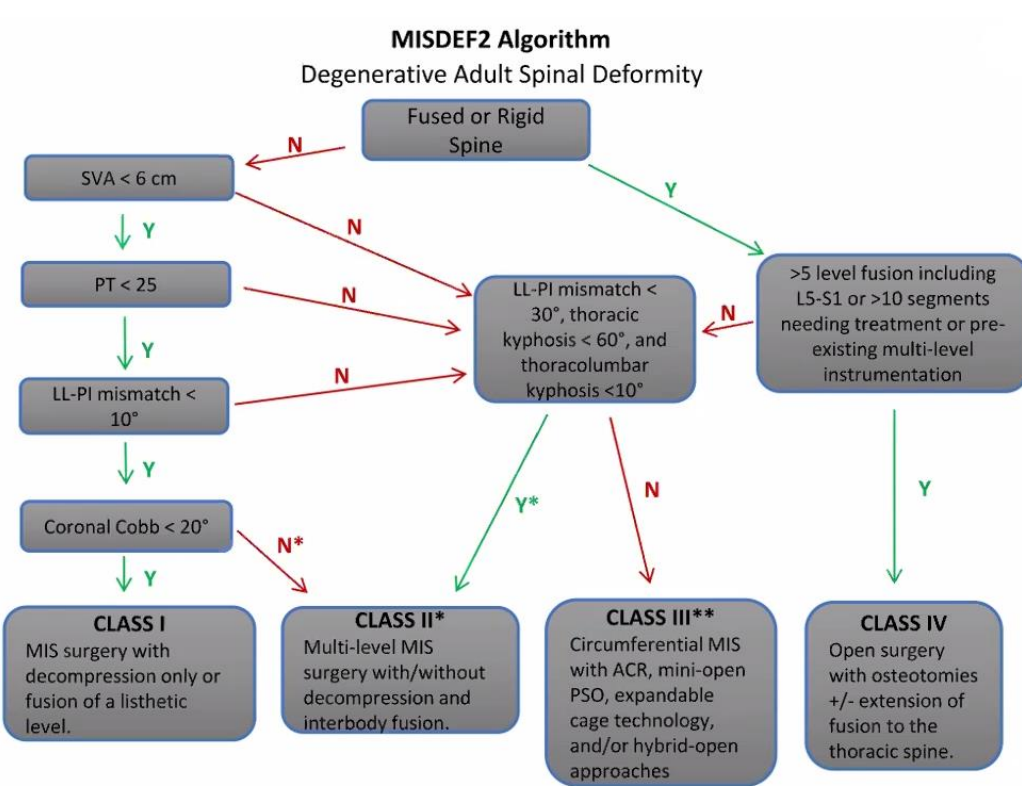
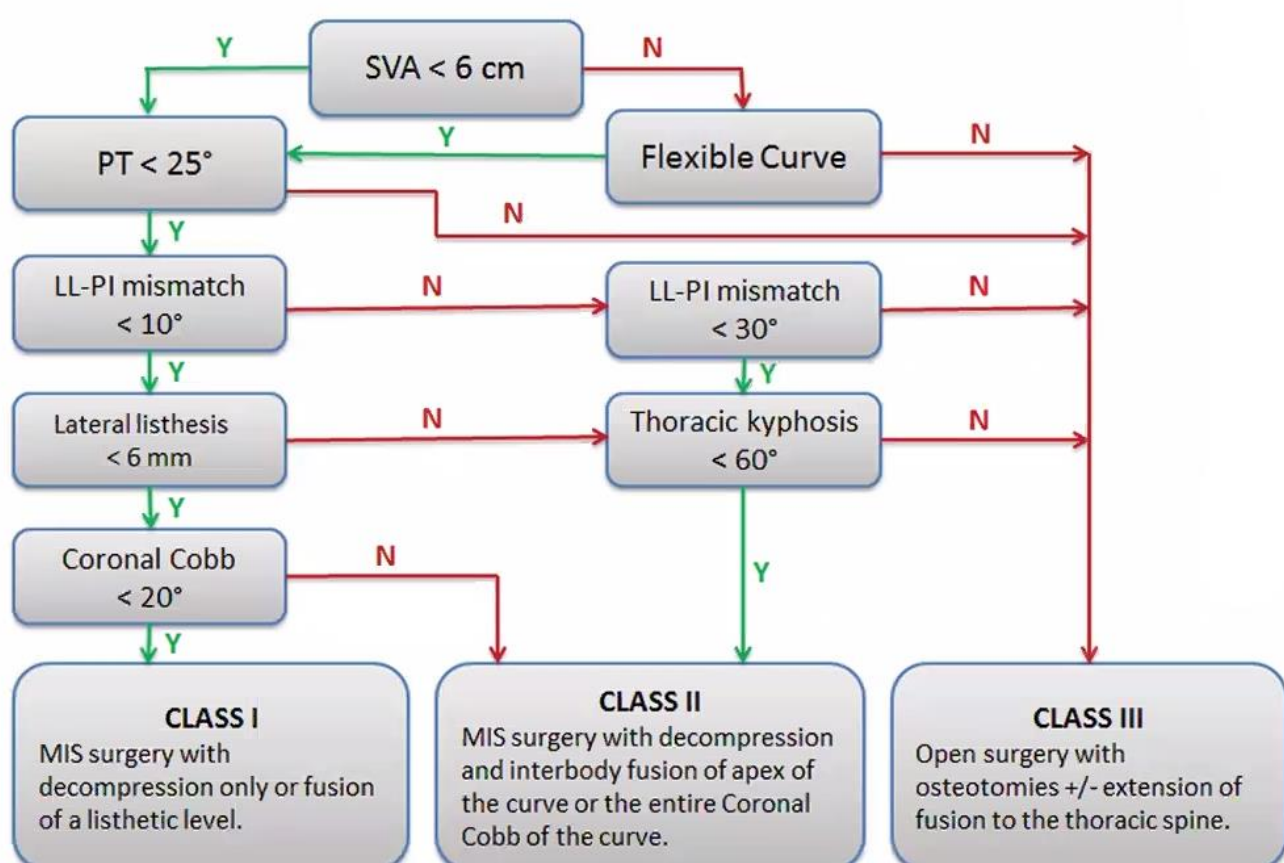
SURGEON ERRORS !

- **Failure of planning**
 - Understanding appropriate age-related alignment goals
 - Failure to address modifiable factors (osteoporosis, BMI, smoking, etc.)
- **Failure of execution**
 - Over or Under correction
 - Handling of soft tissues and PLC
 - Implant handling/choice
 - Choosing the wrong UIV
- **Bad luck !!!**

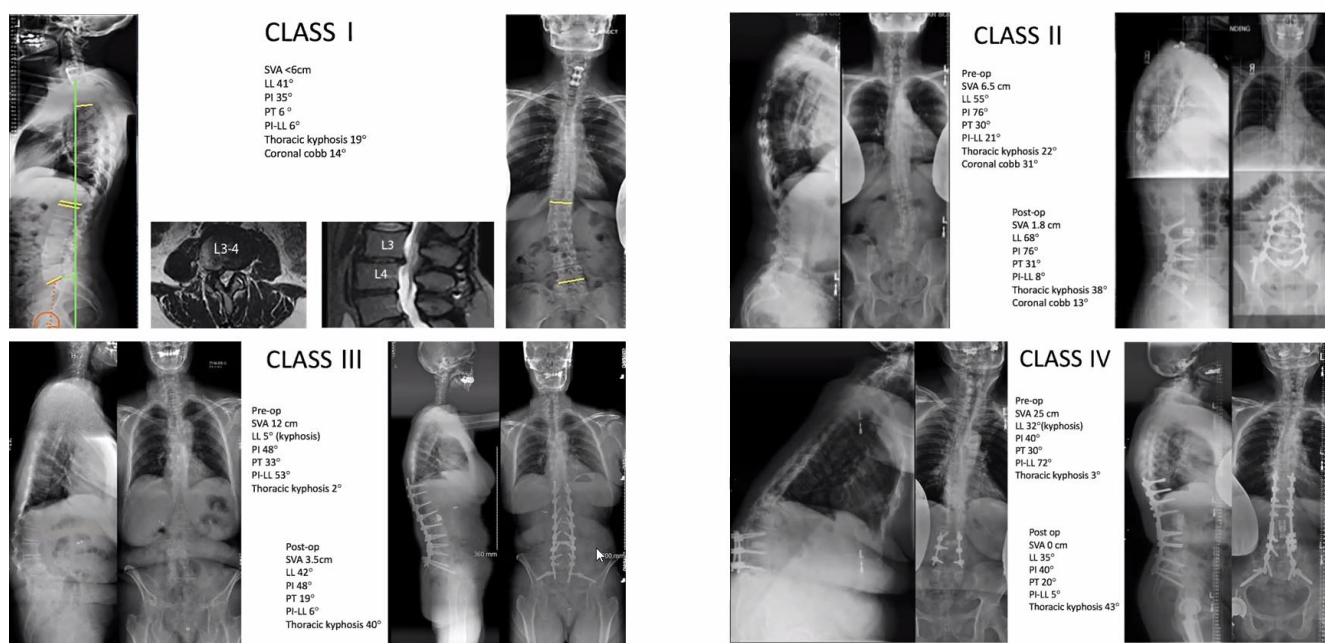


There cases that can be done via MIS approach

Decision-making in adult spinal deformity correction



*Curves > 60°, double major curves are considered class III
 **Only for experienced MIS surgeons



SCHEUERMANN'S KYPHOSIS

- structural thoracic kyphosis - anterior wedging of $\geq 5^\circ$ in at least 3 adjacent vertebral bodies (differentiate Scheuermann kyphosis from postural round-back deformity).
- "developmental" type of kyphosis - develops over time during periods of bone growth (such as puberty)
 - young patients may be treated with brace (Milwaukee, TLSO with cowhorns) worn at least 23 hrs/day for 1–2 years; it is not logical to brace a skeletally mature spine!
- surgery indicated: refractory pain, thoracic kyphosis > 70–80°
- degree of kyphosis operative correction should not exceed 50% of the initial deformity because of an increased risk of proximal and distal junctional failure.

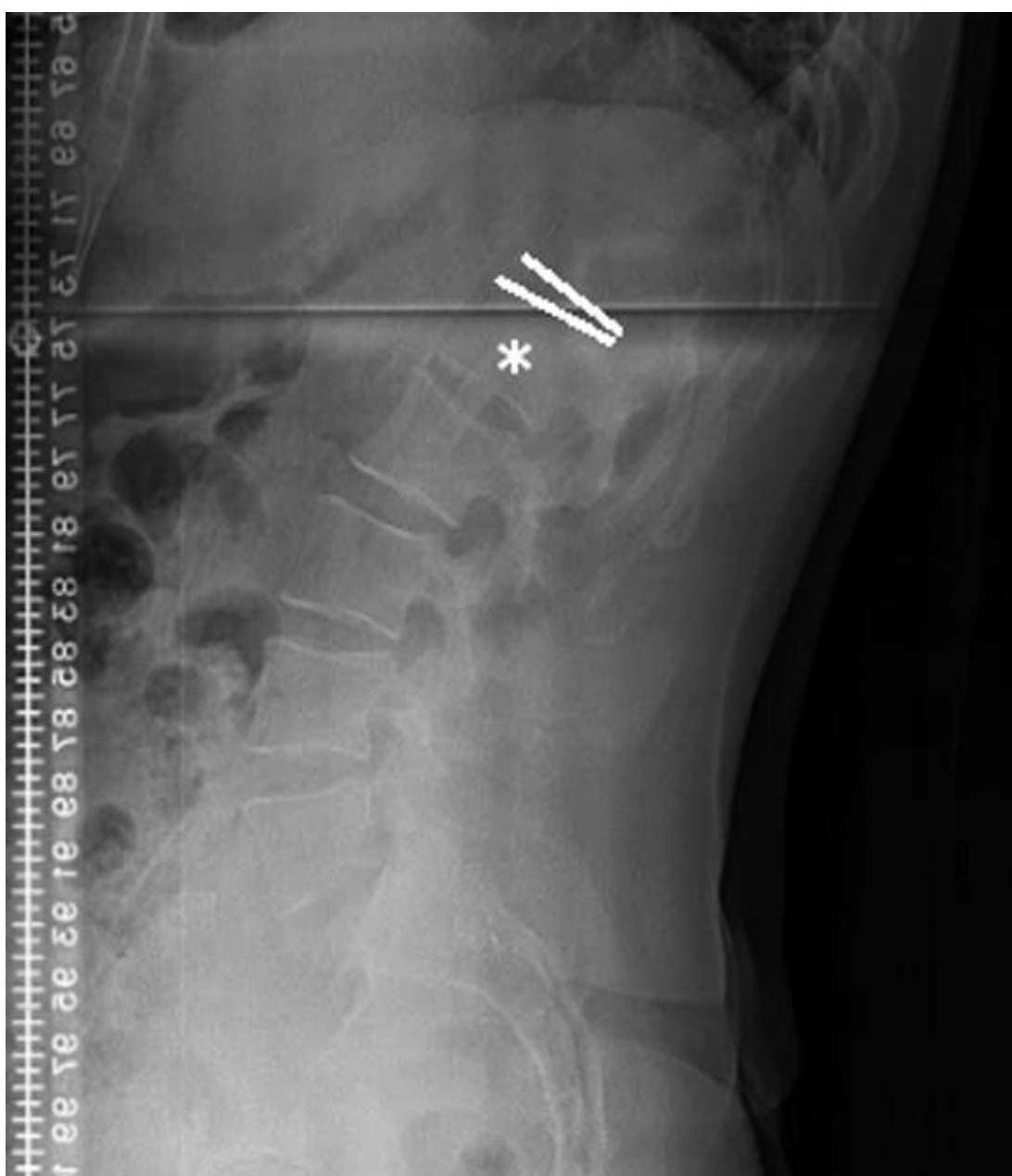Posterior osteotomies + fusion:

Proximal fusion level (upper instrumented vertebra, UIV)

- proximal end vertebra (PEV) or T2 (when it is difficult to determine the PEV especially when the SVA ≥ 50 mm).

Distal fusion level (lower instrumented vertebra, LIV)

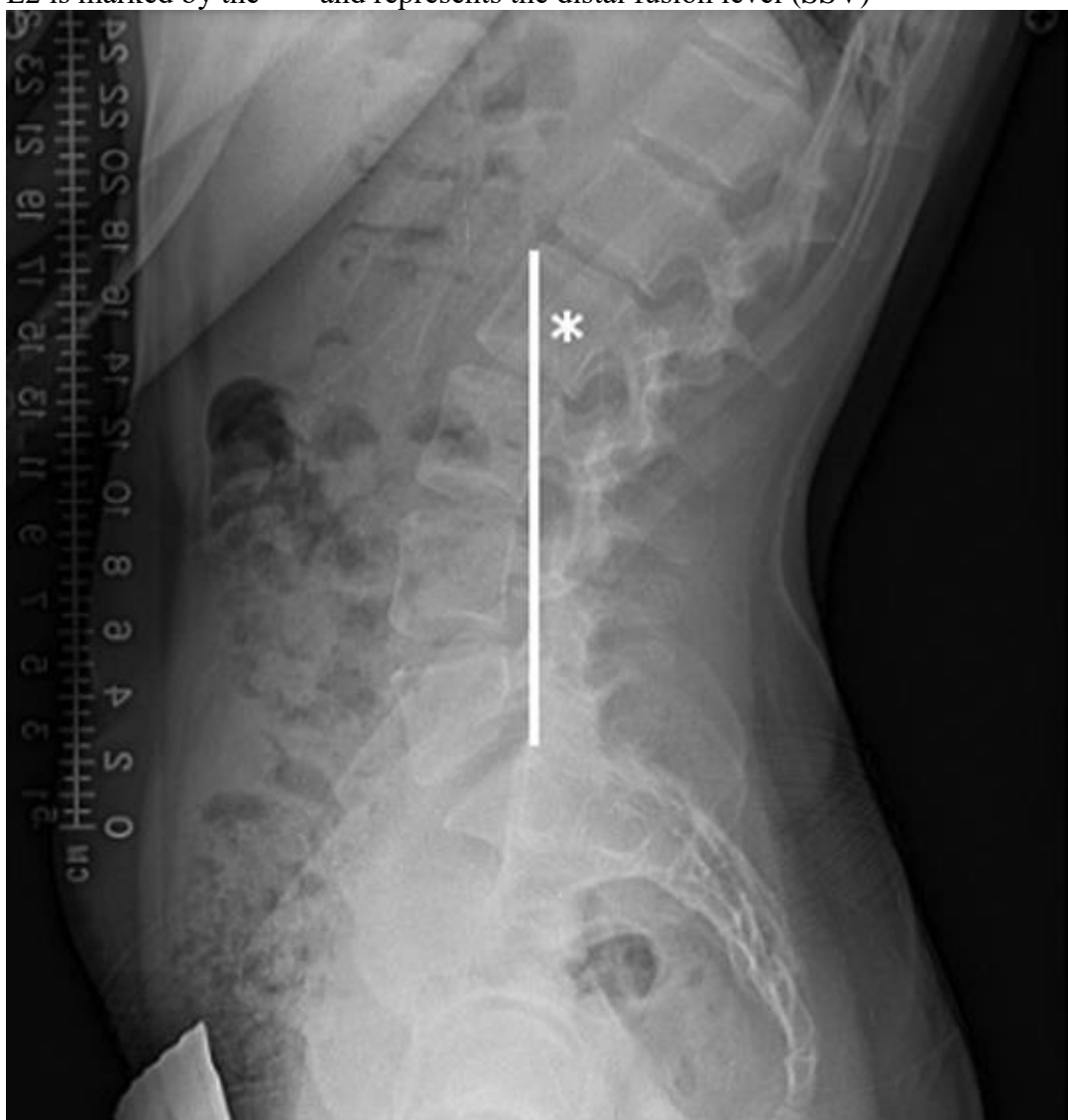- Vertebra just below first lordotic disc (FLD) – historical golden standard; due to the often large kyphosis, patients have compensatory hyperlordosis in the lumbar spine making it difficult to truly determine the FLD level (→ shorter fusion than necessary)



B. **Sagittal stable vertebra (SSV)** – much lower (> 4-fold) distal junctional failure & revision rate (Lenke et al. Global Spine J, 2017) at the expense of incorporating additional motion segments in a typically young population.

SSV - the most proximal (cranial) vertebra touched by a vertical line from the posterior superior corner of S1
 FLD is typically proximal to SSV

L2 is marked by the “*” and represents the distal fusion level (SSV)



N.B. PSF extending to L4 or L5 may cause adjacent segment degenerative disc disease*, minimal degeneration occurs with fusions ending more proximally (e.g. Green et al reviewed MRI of 20 scoliosis patients comparing subgroups between LIV = T12 or L1 and LIV = L3 found no significant differences in Pfirrmann scores)

*if need to stop at L4 or L5 with longer construct, better extend to pelvis (+ always add L5-S1 interbody cage)

SCOLIOSIS (CORONAL DEFORMITY)

- measure **coronal offset** with plumb line (C7 spinous process tip – midsacrum); **normal < 4 cm**

Adult degenerative scoliosis: deformity with **Cobb angle > 10°** in skeletally mature individual.

- tends to progress at an average rate of 3° per year (range: 1–6°).
- **apex** (or apical vertebra) is the vertebra whose center is most laterally displaced from central line
- **non-structural curve** can correct on side bending vs **structural curve** is not flexible.
- **major curve** is the largest structural curve; fractional curve is the curve below the major curve.
- coronal deformity is usually less functionally important than sagittal balance.

Lippmann-Cobb method (on AP X-ray): “end vertebrae” are identified at the top and bottom of the scoliotic curve and are defined as the vertebrae with the greatest angle relative to the horizontal plane.

Minimally invasive lateral lumbar interbody fusion (LLIF) – can be performed from the concavity or convexity.

Curve Laterality for Lateral Lumbar Interbody Fusion in Adult Scoliosis Surgery: The Concave Versus Convex Controversy. Adam S Kanter et al. Neurosurgery, Published: 18 January 2018

- no statistically significant clinical or operative complication rates regardless of a concave or convex approach to the curve.
- clinical outcomes and coronal plane deformity improved regardless of approach side.

- in cases wherein L4-5 is in the primary curve, **approaching the fractional curve at L4-5 from the concavity** may be associated with a higher complication rate compared to a convex approach.

POSTOPERATIVELY

- see ERAS protocol. *see above >>*

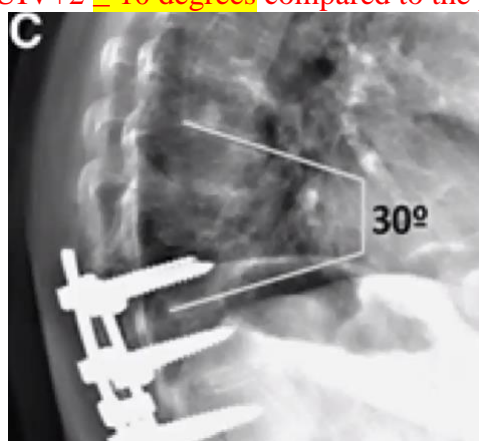
ADJACENT LEVEL DISEASE

- accelerated degeneration of segments adjacent to a lumbar fusion
- associated with the increased mobility and stress put on segments neighboring a fusion because of its rigidity.
- accounts for a significant portion of revision spinal surgery and failed back surgery syndrome and is a major consideration when deciding how many levels to fuse.
- **25% incidence** (requiring reoperation for ALD) **after L4-5 fusion** over a 10-yr period (131 patient): *Prognostic Factors for Adjacent Segment Disease After L4-L5 Lumbar Fusion. Georgios A Maragkos et al. Neurosurgery, Volume 86, Issue 6, June 2020, Pages 835–842,*
 - rostral** (L3-L4) - 18.3%
 - caudal** (L5-S1) - 2.3% **rostral > caudal 8-fold**
 - N.B. when considering posterior L4-L5 fusion, refrain from prophylactic (without strong clinical indications) procedures in the L5-S1 level because ASD incidence is reassuringly low;
 - rostral and caudal** - 4.6%
 - risk factors - **decompression of segments outside the fusion construct** (OR = 2.68, P = 0.039), **female** gender (OR = 3.55, p = 0.011); **PI-LL mismatch > 10°** → 10-times higher risk of **adjacent segment disease**
 - **older age** is associated with lower incidence (OR = 0.95, p = 0.011).
- **treatment**
 - a) board answer – **extend posterolateral fusion** and do decompression.
 - b) alternative – **LLIF** and wait – many patient won't need posterior decompression as large cage jacks up disk space and unbuckles nerve root (indirect decompression).

PROXIMAL JUNCTIONAL KYPHOSIS (PJK), PROXIMAL JUNCTIONAL FAILURE (PJF)

upper instrumented vertebra (UIV)
vertebra one level higher (UIV+1)

PJK – radiographic diagnosis (clinically “insignificant”). Definition: **sagittal Cobb angle between the inferior endplate of the UIV and the superior endplate of the UIV+2 ≥ 10 degrees** compared to the preoperative angle



PJF – clinical significance (pain, neurological symptoms, need for surgery): **PJK + fracture** of UIV or UIV+1

Classification of PJK:

- Type 1 = disc and ligament failure (more common in upper thoracic spine)
- Type 2 = bone fracture (more common in lower thoracic spine)
- Type 3 = implant-bone interface failure.

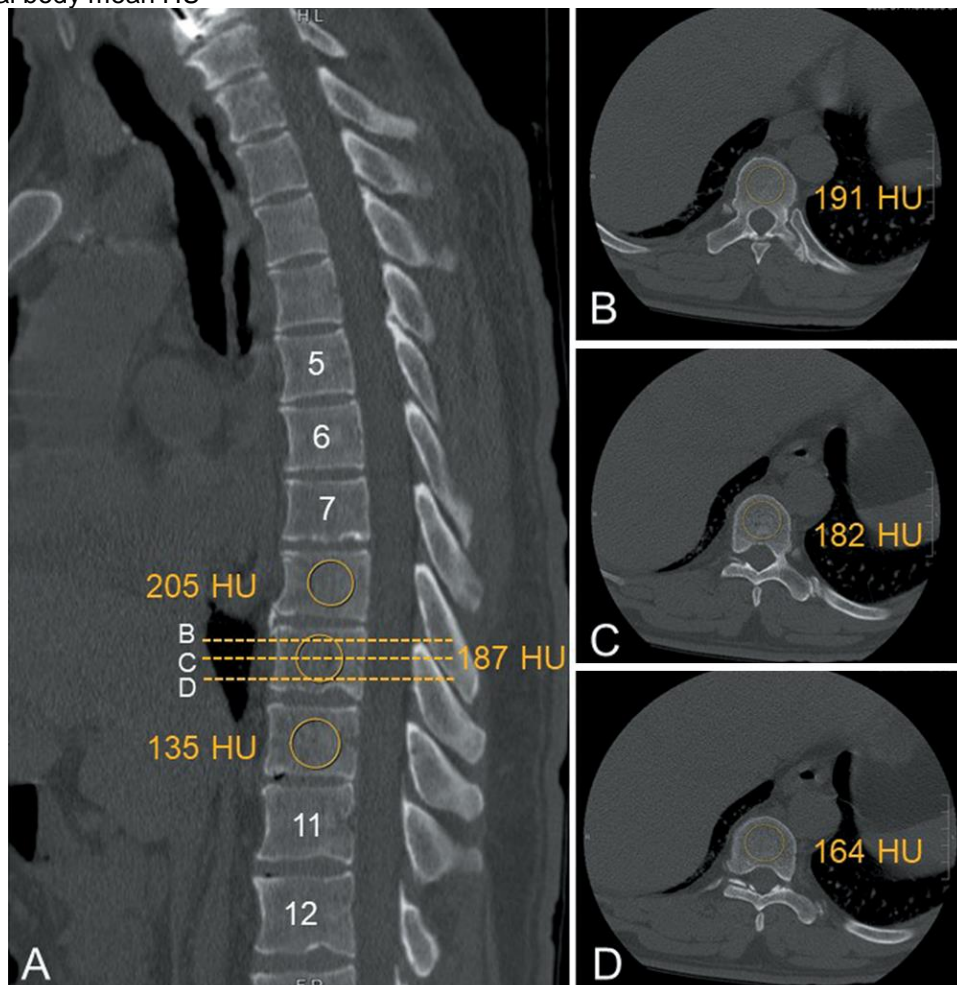
Risk groups: age > 55*, postmenopausal women, osteoporosis / poor bone density, obesity, smoking, long-segment fusions from the lower thoracic spine to the sacrum / pelvis, disruption of the posterior ligamentous tissues / facets, overcorrection of sagittal plane deformities or residual sagittal imbalance, extreme rod stiffness, combined front+back operations

*adults (vs. kids) are very prone to PJ failure

Mechanism of PJK – multifactorial.

- most common mechanism - fracture of the UIV or, less commonly, UIV+1, which may be related to low bone mineral density which can be simply measured on CT as Hounsfield units (HUs):

Ellipsoid region of interest (ROI) is used, ideally including the largest possible cancellous bone region while excluding cortical margins, osteophytes, and Schmorl nodes. ROIs are measured in four separate sections of each vertebra: the midsagittal plane, immediately inferior to the superior endplate, in the middle of the vertebral body, and immediately superior to the inferior endplate. The HU value of each ROI is calculated using the PACS. The mean HU value of the four ROIs is defined as the vertebral body mean HU



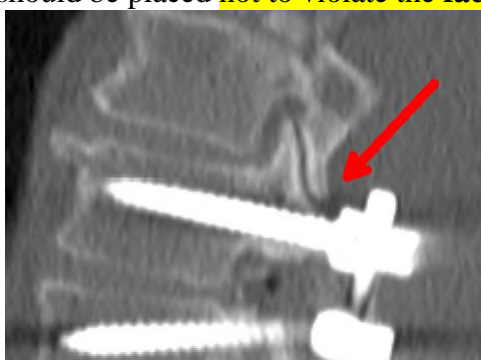Ping-Guo Duan et al. The association between lower Hounsfield units of the upper instrumented vertebra and proximal junctional kyphosis in adult spinal deformity surgery with a minimum 2-year follow-up. DOI: <https://doi.org/10.3171/2020.5.FOCUS20192>

HU at the UIV cutoff value determined by the Youden index was 104 HU (sensitivity 0.840, specificity 0.517) - preoperative L,T spine HU value of < 104 may be a risk factor for PJK after ASD correction.

PROPHYLAXIS

No successful strategy exists to prevent it – need to use complex of measures:

- A. Make **sagittal balance as neutral** as possible.
N.B. **overcorrection** will definitely lead to PJK!
- B. **Vertebral cement augmentation** at UIV+1 (e.g. if instrumented fusion stops at T10, place cement into T9 body); esp. recommended for osteoporotic patients (may include UIV – will prevent screw pullout).
- C. Extend **noninstrumented fusion** one level above instrumented fusion (leave facets intact!) – smoothens transition.
- D. **“Soft landing”** - avoiding rod being proud (pre-loading) in **upper screws** (i.e. contour rod so it sits perfectly in upper screw heads without pulling).
- E. **Flexible rods** at the top.
- F. Respect soft tissue - preserve **interspinous ligaments** (e.g. leaving top of lamina intact with attached lig. flavum).
- G. Upper screws should be placed **not to violate the facet joint above:**

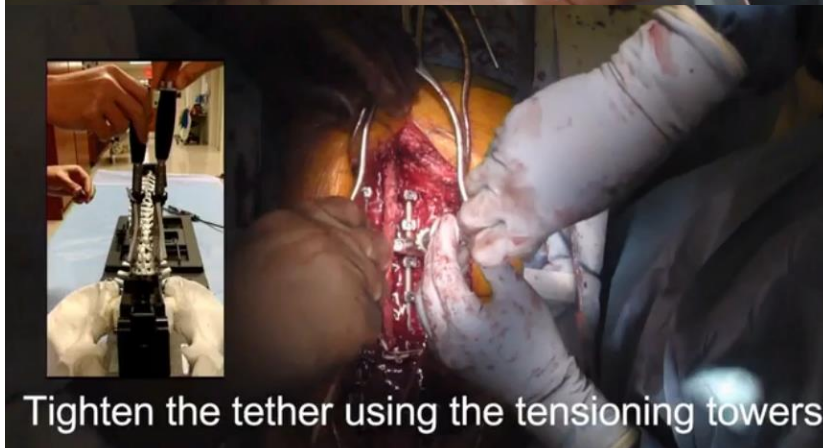
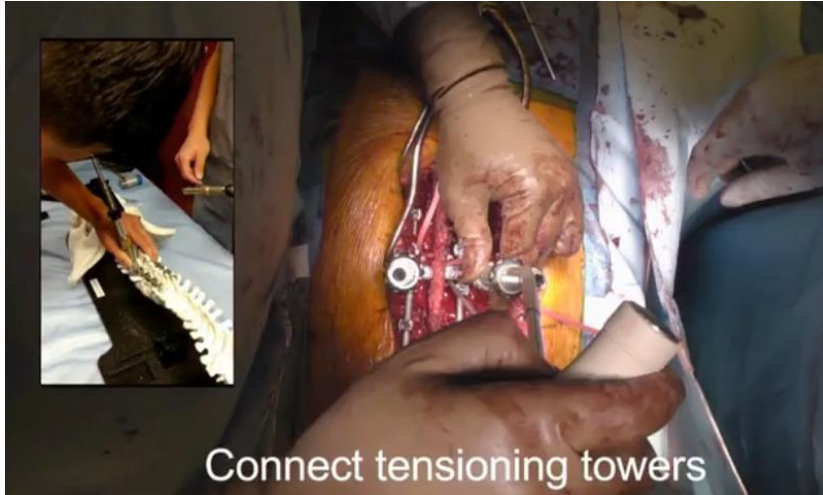
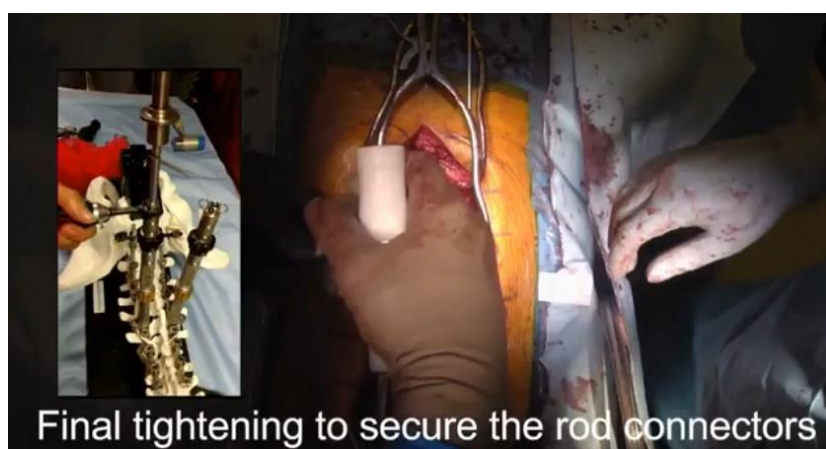- when operating on lumbar spine, sweep muscle of facet joint with Cobb and gauze, then place UIL screws in convergent oblique trajectory (to avoid facet violation).

- H. **Sublaminar hooks** (instead of pedicle screws) for upper levels.
- I. **Sublaminar bands**
- J. **Rib fixation** at UIV+1.
- K. **Transverse process hooks**
- L. **Spinous process augmentation with “Tethers”** around UIV and UIV+1 (up to UIV+2 – dissect soft tissues just to expose sides of spinous process, drill hole in spinous process)– do not overtighten (best – 100 N tension force)

Mersilene Tape

Nuvasive VersaTie® - posterior band system that provides distributed loading across the fixation hardware; system’s independent locking connector and advanced tensioning device offers enhanced control.






Final tightening to secure the rod connectors

M. TLSO brace for 3 months – retracts brain to avoid anteroflexion.

May also leave longer ends of rods (in case will need extension):



REDO CASES

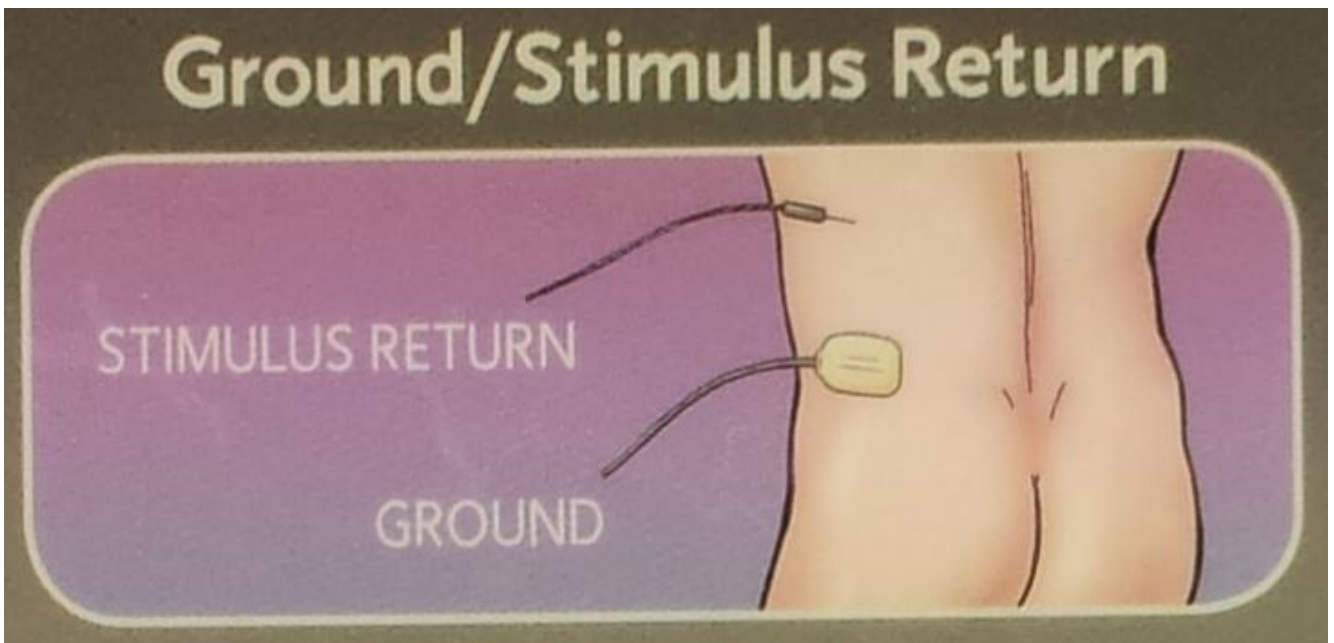
- dissect down to bone far away from dura and neural elements → work with curette detaching scar from bone (stay always on bone – only safe place) and thus approaching target (in lumbar spine it will help to establish laminectomy level but even then dura sometimes bulges above laminectomy level!)
- doing fusion – expose previous fusion bony mass – will have to connect to new fusion mass.

INTRAOPERATIVE NEUROPHYSIOLOGICAL MONITORING

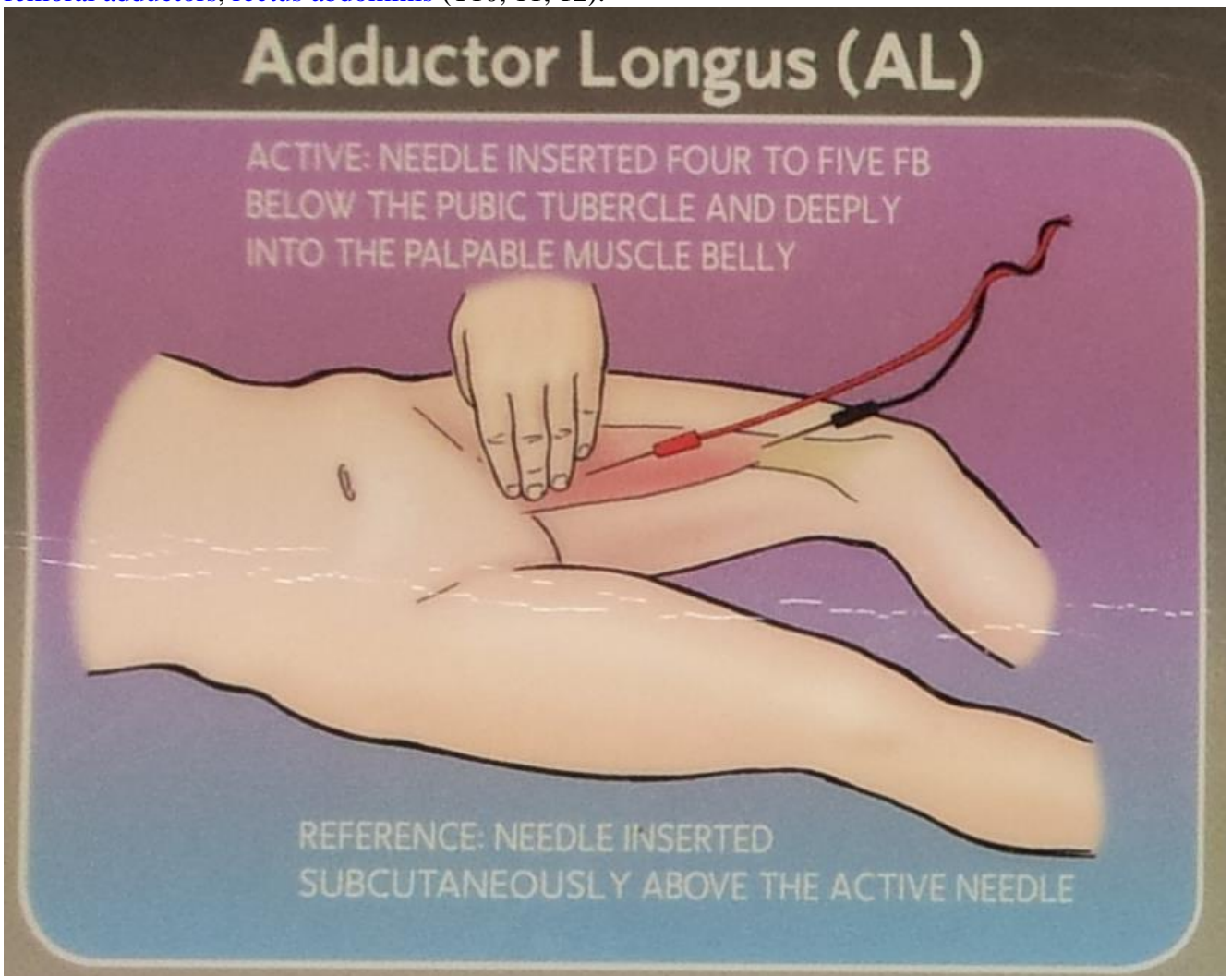
See p. D25 >> (including protocol for intraop spinal cord injury)

FREE RUNNING EMG (S. NIM, NEURAL INTEGRITY MONITORING)

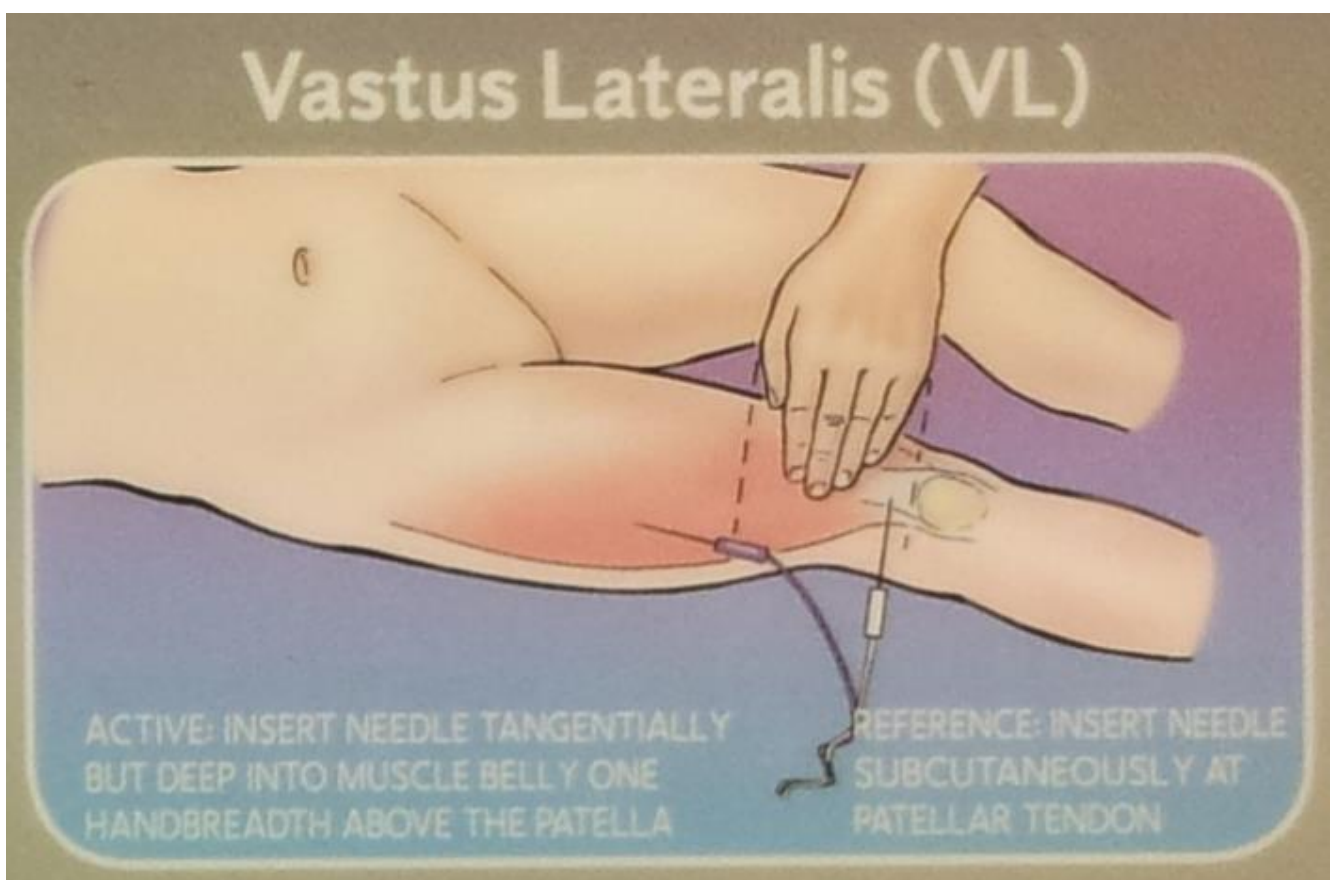
- see Medtronic NIM Eclipse system >>



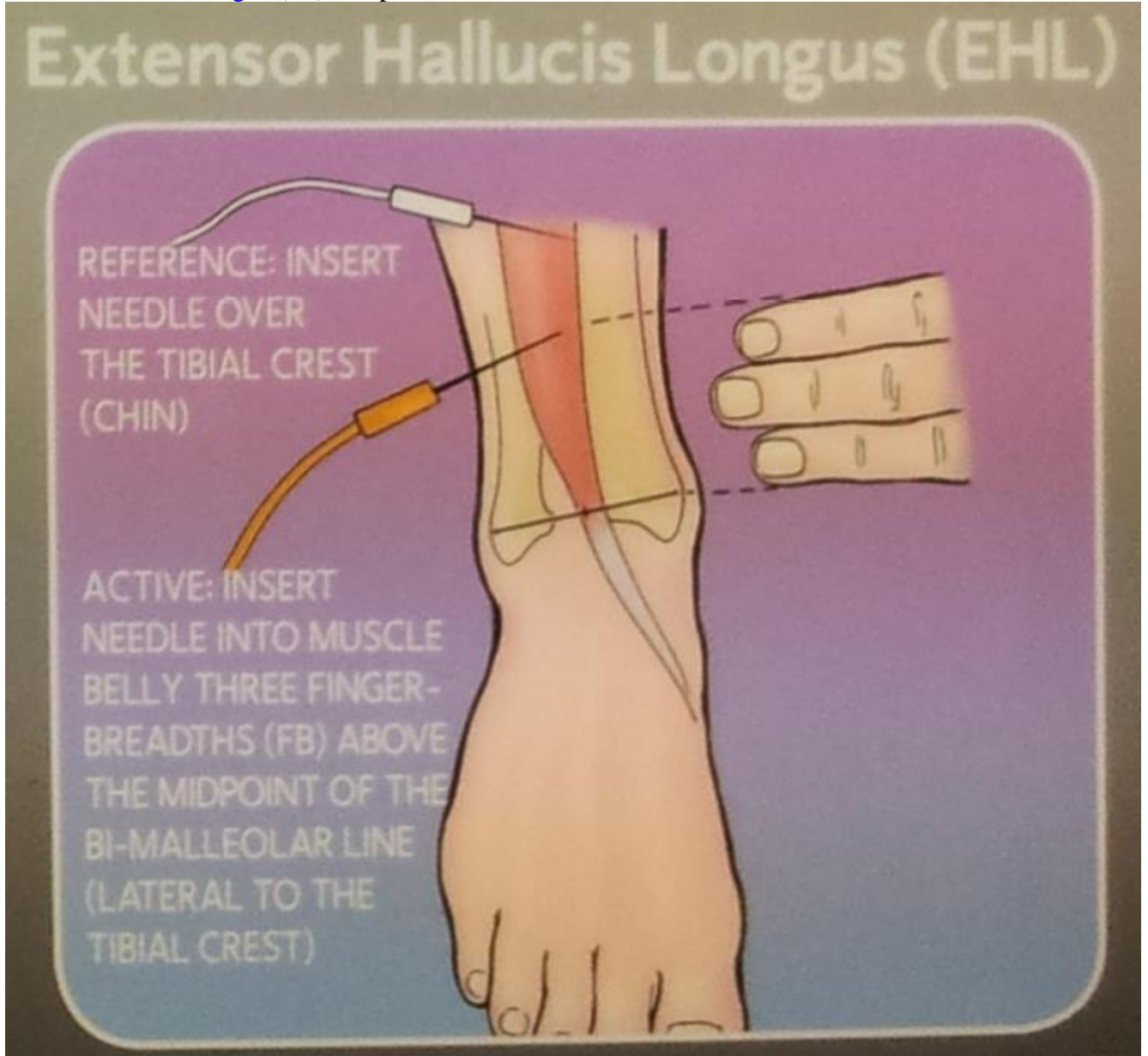
femoral adductors, rectus abdominis (T10, 11, 12):



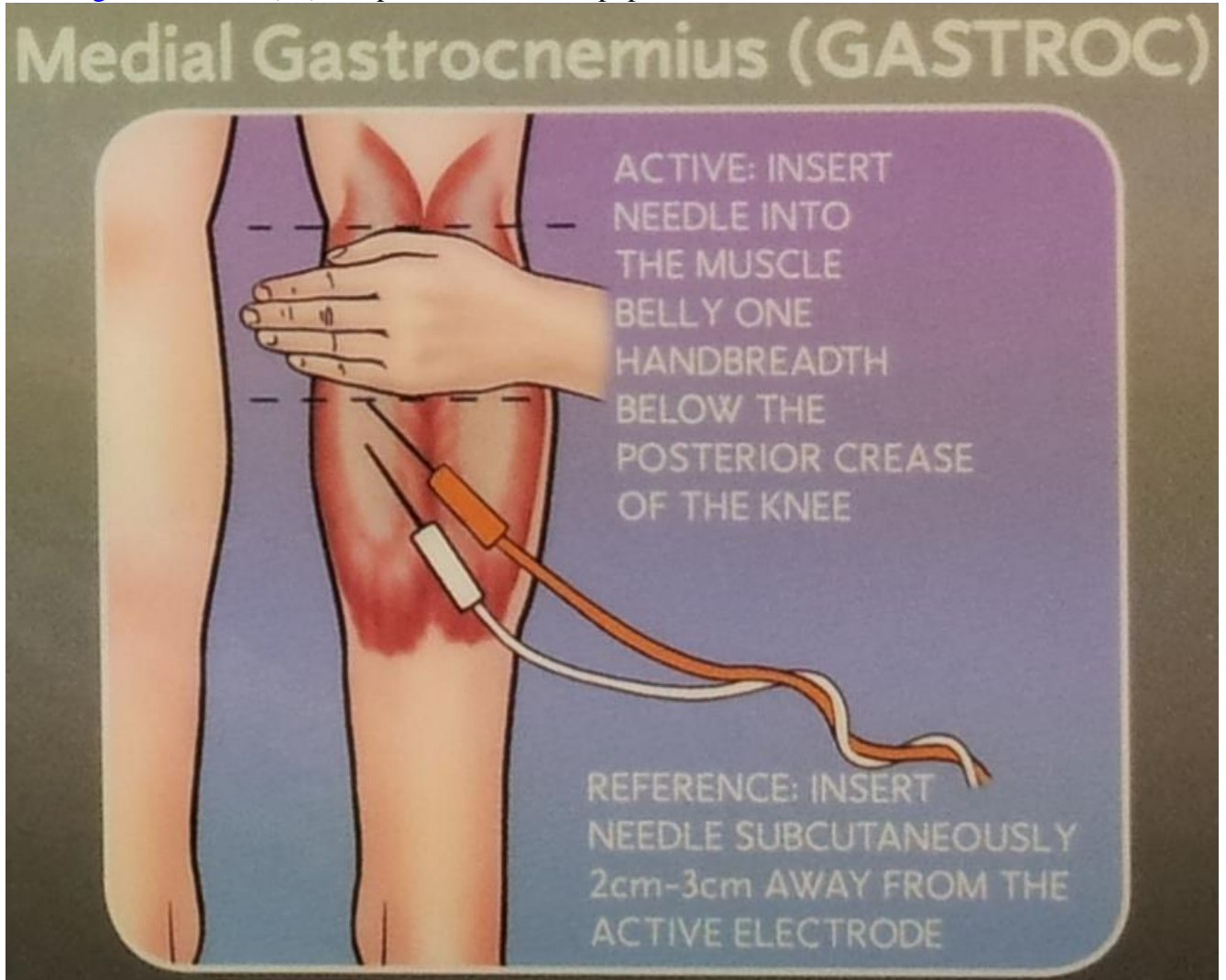
lateral vastus (L4):



extensor hallucis longus (L5) one palm-width above ankle, close to tibia:



medial gastrocnemius (S1) one palm-width below popliteal fossa:



O-ARM

- arms in superman position except for upper thoracic – papoose arms.
- patient tracking clamp is attached to spinous process closest to camera (if planning laminectomy – drill pedicle screw holes, then do laminectomy, then place screws)
- cover patient with two large sheets that overlap in midline so only spinal tracking frame is exposed (secure sheets with hemostats – easy to undo; if use staples – staples fly everywhere, even into wound); open O-arm into C and slide over patient from side; after scan is done, remove O-arm and pull down sheets, change gloves.
- O-arm spans only 4-5 spinal segments; if need more, move O-arm and scan again – all are imported as separate scan volumes but it is easy to switch between volumes during navigation.

STEALTH SPINE

- instruments come with already attached SureTrak frames.

- sequence:
 - 1) with regular Stealth probe identify pedicle screw starting point
 - 2) drill cortex with Midas M8
 - 3) navigated PowerEase Stryker drill – to drill holes (watch navigation screen)
 - 4) ball probe
 - 5) navigated tap
 - 6) ball probe
 - 7) navigated screw driver with screw

DURAL SCAR PROPHYLAXIS

Oxiplex/SP gel – barrier gel to coat dura and nerve roots.

NASS Clinical Guidelines for Lumbar Disc Herniation with Radiculopathy (2012): insufficient evidence for or against the addition of Oxiplex/SP gel or ADCON-L to discectomy.

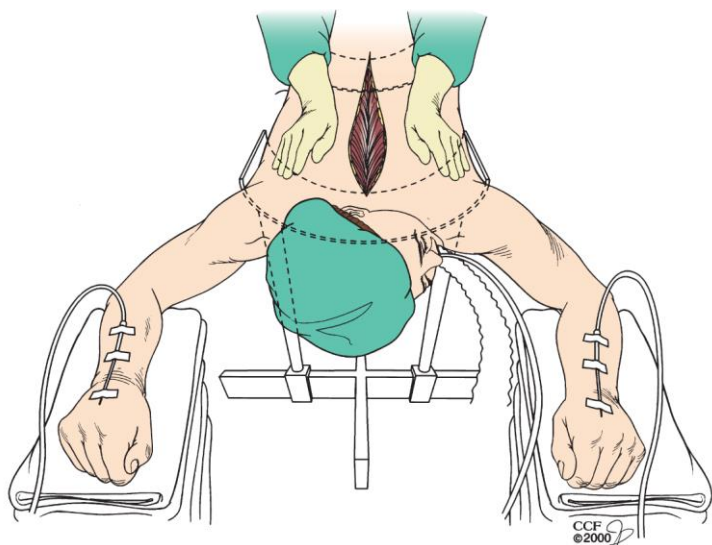
COMPLICATIONS

AVOIDANCE OF LITIGATION

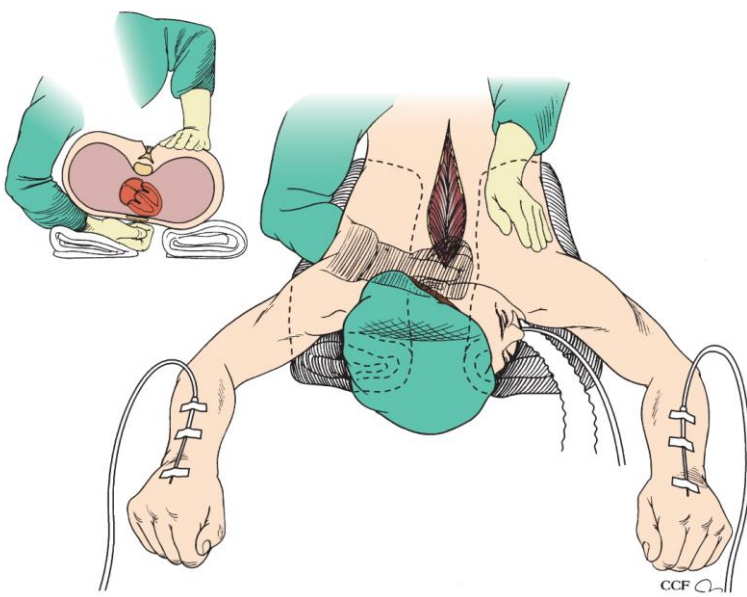
- see p. Op210 >>

CARDIAC ARREST (INTRAOP, PRONE)

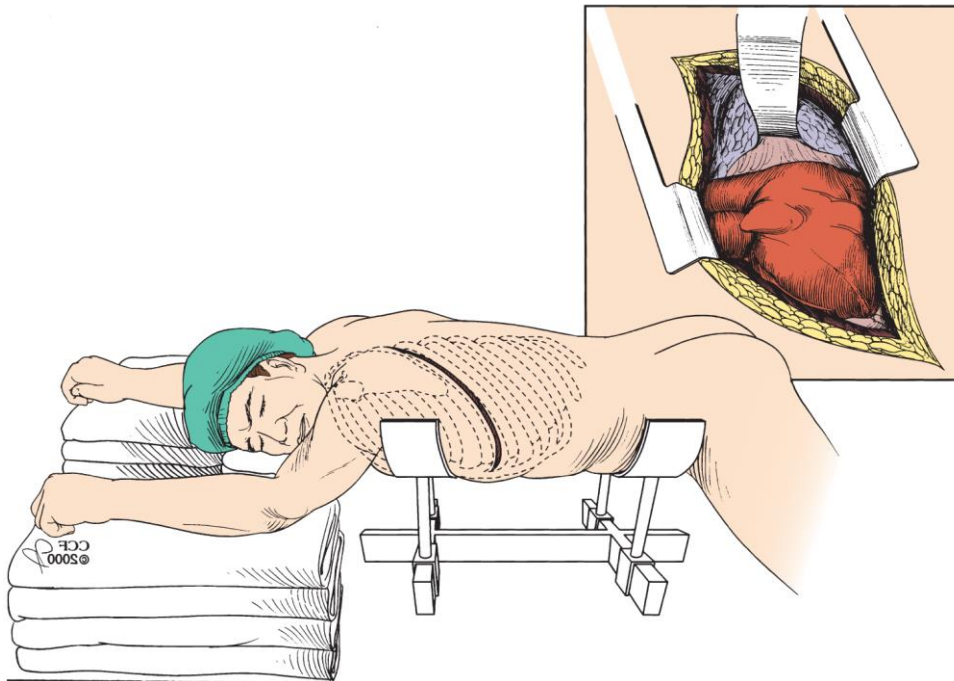
- risk factors: cardiac disease, whereas intraoperative factors include hemorrhage, gas embolism, and diminished venous return
- quickly close incision (e.g. cover widely with **large Ioban**) → *roll supine* on the bed.
- when flipping the patient is not feasible (e.g. risk of neurological injury due to unstable spine) – do chest compressions (chest support – sternal bar of Jackson table) – both hands over scapulae:



- if sternal support is not present (e.g. patient on chest rolls), surgeon clenches fist and places it under chest over lower 3rd of sternum and massages chest at midthoracic level (better if assistant does that):



- if unsuccessful – consider **prone left dorsal thoracotomy** (cut between ribs, incise parietal pleura) → cardiac massage:



UNABLE TO VENTILATE IN PRONE POSITION

- never roll bed away after flipping patient prone until anesthesiologist confirms bilateral breath sounds.
- **Axis table** is the worst (consider **longitudinal gel rolls**).
- quickly close incision (e.g. cover widely with **large Ioban***) → *roll supine* on the bed
*if time permits, may place several sutures on fascia and staples to the skin

LEVEL LOCALIZATION / WRONG LEVEL SURGERY

See p. Op210 >>

BLOOD VESSEL INJURY

DORSAL APPROACHES

Dorsal thoracic surgery - vascular injury is rare.

Lumbar disc surgery (vascular complication has been estimated to be at the most 0.14%)

- most commonly injured vessels are the common iliac arteries, left common iliac vein, median sacral artery, aorta, and inferior vena cava.
- typically caused by **aggressive use of a pituitary rongeur** that penetrates the ventral annulus fibrosus.
- two clinical scenarios and management:

A) in OR: **brisk bleeding** into the interspace (only observed in 25% so may not be immediately evident; observed brisk bleeding is more commonly due to extradural veins and not an arterial injury) → start resuscitation, quickly close, call vascular surgery, flip supine and prep for laparotomy

B) in PACU: **hypotensive, tachycardic, abdominal distension and pain** → start resuscitation, immediately take back for **laparotomy**

- cross clamping of the aorta can facilitate resuscitation.
- tear in a vein may be primarily repaired with suture (iliac artery may be divided to gain access to an injured vein and then must be reanastomosed).
- arterial injuries may be repaired primarily or with an interposition graft.
- internal iliac vessel (artery or vein) may be ligated if other methods of repair are not possible.

N.B. **angiography** has been gaining popularity - rapidly identifies bleeding source → coil embolization or stent grafts.

VENTRAL APPROACHES

- majority of injuries are venous and require only simple suture or clip repair.
- usually occurs during exposure (esp. L4-5, then L5-S1)
- **risk factors**: radiation therapy, osteomyelitis.
- during ventral exposure, middle sacral vessels and iliolumbar vein should be ligated.
- if sudden hemorrhage occurs → direct pressure to the vena cava → identification of the injured vessel:
 - torn lumbar or iliolumbar vein may be clamped and ligated.
 - iliac vessel injury → direct pressure → proximal and distal control → repaired primarily.

DUROTOMY

- **dural violation** requires **primary closure** (± under microscopy).
- **needle driver** - Castro-Viejo or long Ryder
- **suture choices** (running or interrupted):
 - a) 5-0 nylon/Prolene
 - b) 4-0 silk
 - c) Gore-Tex
 - d) metal clips (e.g. AnastoClip GC® Closure System) see p. Op140 >>

N.B. use **Hemo-Seal (HS-7) needle** – needle diameter smaller than suture – dural hole is smaller than suture!
- need to **well expose durotomy** (e.g. remove more bone around while protecting durotomy site and nervous elements with the patty).
Ventral CSF leak – put DuraGen + lumbar drain (may try to repair in thoracic where root can be sacrificed)
- if **nerve root keeps plugging durotomy hole** (preventing placing stitch) → place patient into reverse-T and drain some CSF – nerve root now can be easily pushed out of way; may even leave a patty / piece of Gelfoam inside the dura for the dural closure start to keep nerves away.
- **tying deep knots**:
 - a) knot pusher
 - b) hold one string with needle driver and push knot with finger (assistant may pull on other string)
 - c) use DeBakey to pull loose end
- check repair line with Valsalva maneuver; if leaking – place another suture line.
- **obligatory reinforcement**: **DuraGen soaked with autologous blood, dural sealant with Surgicel layers**
N.B. **DuraGen / DuraMatrix is placed first! (“DuraGen goes on Dura”)**
- some experts would add **muscle patch** or **mashed piece of fat** (mash wrapped in the gauze).
- **meticulous fascial and skin closure** decreases postoperative CSF leaks dramatically.
- **avoid drain** (or at least no suction).
- patient lays **flat** postop for 1-3 days.

Dural defect (unable to close with dural suture)

- use DuraGuard / DuraMatrix-Suturable patch and interrupted 4-0 silk sutures: suture through dural edges and keep tagged on mosquitos → then suture each through patch graft edges and again keep tagged on mosquitos → slide graft down and tie each knot separately.

Epidemiology, prognosis

- durotomy **occurs in 9% of first-time open laminectomies** (with or without fusion).
- durotomy significantly **increased operative duration, operative blood loss, and inpatient stay**
- durotomy **does not have long term effects!** (no differences in incidence of nerve root injury, mortality, additional surgeries, or primary outcomes – up to 4 years of follow up)
“Durotomy Does Not Affect Long-Term Outcomes of Spine Surgery” Congress of Neurological Surgeons (CNS) 2013 Annual Meeting. Abstract #161. Presented October 22, 2013 >>
Desai “SPORT: Does Incidental Durotomy Affect Longterm Outcomes in Cases of Spinal Stenosis?” Neurosurgery March 2015 - Volume 76 - Issue - p S57-S63 >>

ISCHEMIC OPTIC NEUROPATHY (ION)

- the most common pathological diagnosis underlying postoperative vision loss.

Spine surgery remains one of the **largest sources of acute perioperative visual loss!**

- **two forms**:
 - a) anterior (AION) - affecting the optic disc
 - b) posterior (PION) (58-83%) - affecting the optic nerve proximal to the disc.
- **risk factors** - fusion, higher number of operative levels, higher blood loss, change in hemoglobin, hematocrit, prone surgery, longer operative time, intraoperative hypotension.
- bilateral (75%).
- **only 30% patients demonstrate improvement** in visual acuity while the rest remain either unchanged (40%) or worsened (20%) at last follow-up.

- PION is associated with higher odds of severe visual deficit at immediate presentation (odds ratio [OR]: 6.45, confidence interval [CI]: 1.04–54.3, P = 0.04) and last follow-up.
- **management:**
 - 1) urgent ophthalmologic examination to ascertain the cause of vision loss.
 - 2) test pupillary reflex - absence implicates injury of the optic nerve or globe, while presence of a normal pupillary reflex indicates cortical blindness from either stroke or posterior reversible encephalopathy syndrome (PRES).
- **prophylaxis:**
 - stage the surgery to reduce the duration and intensity of each operative stage.
 - deliberate hypotensive anesthesia must be used cautiously while avoiding prolonged periods of hypotension.
 - soft headrests to avoid undue pressure on the globe vs. pin the head in Mayfield.
 - regular eye checks.

SURGICAL SITE INFECTION

CDC 2017 guidelines for SSI prevention. JAMA Surg. Published online May 3, 2017

- see p. Op120 >>

EPIDEMIOLOGY

- despite appropriate prophylaxis, the rate of surgical site infections in spine surgery is **0.7% - 13%** (patients without comorbidities 0.7 – 4.3%; patients with comorbidities* 2.0 - 10%).
- current best practice with antibiotic protocols has failed to eliminate (reach rate of 0.0%) surgical site infections.

***diabetes** (level of evidence: III), **obesity** (level of evidence: insufficient), **neurologic deficits**, **incontinence**, **hyperglycemia** (preoperative > 125 mg/dL, postoperative > 200 mg/dL), **smoking**, **nutritional depletion**, **immunodeficiencies**, use of **antithrombotic therapies**, **trauma** and **prolonged multilevel instrumented** surgery.

PROPHYLAXIS

- **stage** surgeries.
- frequent intraop **irrigation**.
- < 5% **BETADINE** irrigation before closure.
- **VANCOMYCIN** powder decreases risk 2-fold; side effects: **vancomycin-resistant** organisms*, **nephrotoxicity** and **ototoxicity**.
 - a) **SUBFASCIAL** vancomycin - reported side effects: seroma formation, adverse effects on bone healing and neural elements, washout by subfascial drains.
 - b) **SUPRAFASCIAL** vancomycin 1 g (for wounds > 20 cm, 2 g)

*meta-analysis of nearly 20 000 patients treated with intra-wound vancomycin powder during spine surgery reported no increase in incidence of vancomycin-resistant infections

SUPRAFASCIAL vancomycin

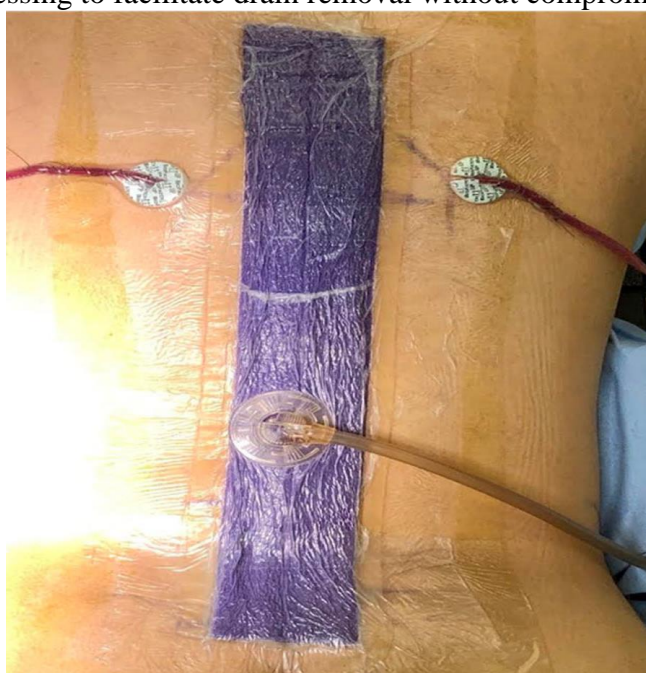
Ralph T. Schär et al. Negligible Systemic Uptake of Suprafascial Vancomycin Powder Following Instrumented Posterior Spinal Fusion—Preliminary Results From A Randomized Clinical Trial (VANCO Trial). Neurosurgery 89:967–972, 2021

- 34 patients, open instrumented spine surgery
- randomized 50/50 to: no intervention vs. vancomycin 1 g (for wounds > 20 cm, 2 g) before wound closure.
- **no measurable systemic uptake of the antibiotic:** serum vancomycin levels on postoperative day (POD) 1 and 2 – all in treatment group had **serum [vancomycin] below the limit of quantification** (< 4.0 mg/L).
- **no statistical significant difference in adverse events:**
- postoperative serum creatinine levels - no in treatment group had **nephrotoxicity**.
 - 2 patients in treatment arm showed ↑ in postoperative serum [creatinine] (+2% and +26%) vs 8 patients in control group (range: +4% to +29%)
- no cases of **ototoxicity**.
- 2 patients in the vancomycin group had persistent **serous discharge** from the wound but no clinical evidence of an SSI; one patient third patient in the vancomycin group developed a large wound **seroma with fascial dehiscence**.

Closed Incisional Negative Pressure Wound Therapy

Kyle B. Mueller et al. Effect of Incisional Negative Pressure Wound Therapy vs Standard Wound Dressing on the Development of Surgical Site Infection after Spinal Surgery: A Prospective Observational Study. Neurosurgery 88:E445–E451, 2021

- **indications for surgery** - degenerative disease, deformity, malignancy, and trauma.
- **exclusion criteria** - anterior and lateral approaches to the spine, intraoperative durotomy, or use of minimally invasive techniques.
- 274 patients.
- negative pressure dressing was set at –125 mmHg and remained in place for 7 d.
- surgical drains were tunneled at least 5 cm from the incision site in cases using a negative pressure therapy dressing to facilitate drain removal without compromising the negative pressure seal.



- **SSI rate (within 60 days) was significantly lower** with ci-NPT dressing (n = 118) as compared with the standard dressing (n = 156) (3.4 vs 10.9%, P = .02).
- no statistical difference in SSI rate for **decompression alone** procedures (4.2 vs 9.1%, P = .63), but there was a statistically significant reduction with the use of a negative-pressure dressing in cases that required **instrumentation** (3.2 vs 11.4%, P = .03).
- higher cost of a ci-NPT dressing might be justified with instrumented cases.

TREATMENT

- **operative washout and drainage;** use pulse lavage with liters of bacitracin.
- if in doubt and skin is intact (infection vs hematoma vs seroma vs CSF) – do MRI w/wo, aspirate fluid for analysis.

- infection in the presence of **hardware**:
 - practically never need to remove hardware; some experts leave even bone grafts in place.
 - stainless steel** (typically, old fusion hardware) - needs to be removed as it creates biofilm (vs. **titanium**)
 - index surgery long time ago** (do CT to verify fusion) – remove hardware
 - fresh surgery:
 - Gr+ cocci – washout, leave hardware
 - Gr- rods** – will likely need multiple washouts, even temporary hardware removal (keep patient on bed rest)
- close incision with **retention sutures** (esp. in obese patients).
- place “Aquacel Ag” **dressings** on incision.
- antibiotics** for ≥ 6 weeks (ESR and CRP need to normalize).
 - N.B. do not start perioperative antibiotics and do not irrigate with bacitracin **until cultures are sent!**
 - sometimes, if hardware present, needs lifelong suppression with **RIFAMPIN**.
- keep **drains** on suction until output = 0 (it is fine to discharge with drains in).
- if infection recurs needing OR again – consider **woundVAC** placement → delayed closure with plastic surgery.

NONFUSION / PSEUDOARTHROSIS


See p. Op210 >>

SPECIAL CONDITIONS

OSTEOPOROTIC SPINE

Preoperative testing and optimization – see above >>

- avoid hardware / avoid fusion**; if still needed:
 - use **more constrained** screws – less wobble, less loosening.
 - do not tap!**
 - choose **PEEK** - more elastic than **titanium** - ↓risk of graft subsidence in osteopenic and osteoporotic patients; for rod choice – use **titanium** (vs. **cobalt-chrome**)
 - osteoporotic spines are predisposed to screw pull-out, wire cutout, and instrumentation-associated laminar fractures - **increasing points of fixation** (e.g. 360 – **anterior cage**, **multilevel** pedicle screws) may be necessary to offset poor bone quality.
- some experts suggest traditional pedicle screw technique replace with **MIDLF technique** due to the better cortical purchase.
- rigid external orthotics** aid in maintaining stability while fusion occurs.
- cement augmentation** (e.g. injection via cannulated screws); for pathologic fractures may use cement instead of metal cage into vertebral body defect:



ANKYLOSING SPONDYLITIS (MARIE-STRÜMPPELL DISEASE)

- rheumatoid factor** is absent in the serum
- begins in SI joints (sine qua non of involvement) progressing rostrally.
- inflammatory morning back stiffness, progressive thoracic kyphotic deformity limits chest expansion.
- imaging: **osteoporotic** VBs, **calcified intervertebral discs** (sparing **nucleus pulposus**), **ossified ligaments** → square-appearing VBs with bridging syndesmophytes (“**bamboo spine**”).
- Andersson lesion**: discovertebral lesion that results from previously missed fracture → mechanical stresses prevent from fusion → pseudarthrosis (erosive changes can mimic discitis on MRI)
- fragile rigid spine highly susceptible to **very unstable chalkstick** (3-column) **fracture** and SCI even after low energy trauma:
 - cervical → **long segment rigid PCF** e.g. C2-T2 fusion (consider 360; N.B. stand-alone **anterior** fusion → **50% failure rate**)
 - thoracic fracture – look at MRI
 - no ligamentous injury – brace
 - ligamentous injury – fusion (fixed-angle screws!!!, thicker rigid rods, PMMA augmentation to prevent screw pullout)

OSTEODISCITIS, OSTEOMYELITIS

Infection likes stability – consider fusion!

- consider BMP (some experts swear it gives good results even it is formally contraindicated)
- destroyed endplates** – place **large footprint TLIF** graft or 2-level **corpectomy** through lateral approach (may need vascular surgeon for approach due to chronic infection), then supplement with posterior fusion (consider quad-rods to bridge corpectomy levels).

PREGNANT PATIENT

- use open spine table.

POSTERIOR MIDLINE APPROACH

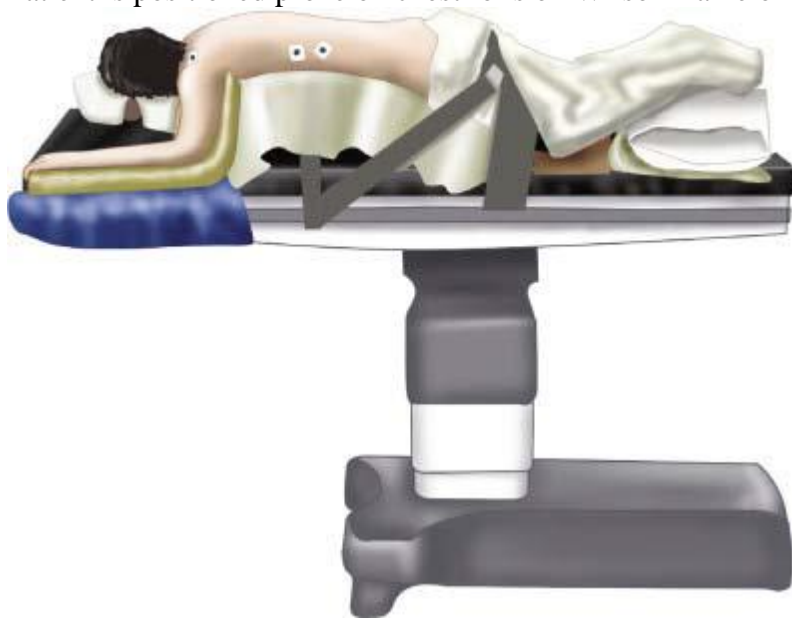MEDICATIONS

- preoperative antibiotics before skin incision

- ketorolac (Toradol) can be instilled at end of case

POSITIONING

Patient is positioned prone on chest rolls on Wilson frame or Jackson table to hold spine in flexion:



Source of picture: R. Jandial “Core Techniques in Operative Neurosurgery: Expert Consult - Online and Print”, 1st ed (2011), Saunders; ISBN-13: 978-1437709070 >>

- crank frame for discectomies; frame has to be in neutral position for fusions!!!
- *hips* flexed (to open interlaminar spaces); *legs* cannot be overflexed.
- protuberant *belly* should hang as freely as possible (to reduce venous hypertension – main cause of **severe intraoperative bleeding!**).
- pad ulnar nerves at elbow (to prevent neuropathy).

Axis / Jackson table

- top of chest bar 1-2 fingerbreadths below top of sternal notch
- iliac crest at interface of top 1/3 and bottom 2/3 of hip support

SKIN INCISION

- palpate anterior superior iliac crest \approx L4-5 interspace
- obtain preincision **radiograph** with spinal needle (to confirm localization and to determine correct size of exposure; **surgeons still operate on wrong level!!!**).
- local anesthetic with epinephrine to skin and deeper tissues.

FASCIAL AND SUBFASCIAL DISSECTION

- Bovie electrocautery for subcutaneous dissection and for achieving hemostasis.
- **thoracolumbar fascia** is identified after dissection through subcutaneous fat.
- dry sponge raked along fascia identifies white tissue easily, and periosteal elevator can be used to dissect off subcutaneous fat from fascia beneath (Dr. Graham thinks that it leaves unnecessary dead space).
- self-retaining retractor (such as Gelpi retractor).
- palpate to find midline.
- Bovie (on cut) to cut through fascia in **midline***.
*for MICRODISKECTOMY/HEMILAMINECTOMY, **paramedian fascial incision** ensures midline ligamentous structures are not damaged.

SUPERIOSTEAL DISSECTION

- retract **paravertebral muscles** (away from spines and laminae on involved side).
- after minimal one-sided exposure obtain **localizing film**.
Laminae lie, pedicles – never!
- subperiosteal dissection can be done rapidly with open dry sponge raked ventrally and laterally along spinous process and lamina with large periosteal dissector, such as Cobb elevator.
Note: this dissection can be done very rapidly and in case of in situ lumbar fusion can be carried out to lateral gutters to rest atop transverse processes of lumbar vertebrae.
- alternatively, Bovie electrocautery done just subperiosteally (“on bone”, “bone is home”) can greatly reduce amount of muscle bleeding encountered during operation; cautery from caudal to rostral removes paraspinal muscular attachments most efficiently and with least blood loss.
- bipolar electrocautery (e.g. large Medtronic Aqua-Mantis) can be used for point source bleeding.

N.B. for revision laminectomies, be careful because lamina and all posterior ligamentous structures protecting thecal sac are absent – check preop CT

CLOSURE

- copious irrigation; any bleeding source should be controlled until irrigation is clear.
- to ensure **deep fascial closure** is dry, before placing last fascial stitch, irrigate into deep space and suction out irrigation; this should be clear in color.
- closure should be meticulous to prevent CSF leak in event of subclinical violation and to allow for quick and less painful recovery.
- interrupted, figure-of-eight, 0-size absorbable sutures to close deep muscle layer is controversial.
- absolutely watertight 0-size interrupted, noninverted layer of sutures at narrow 5- to 8-mm intervals should be completed to achieve completely dry closure.
- **superficial fascial closure** – 2-0 inverted, interrupted sutures at equally narrow intervals to ensure adequate strength of closure.
- inject **local anesthetic** into skin – dramatically decreases postop pain!
- **skin** is closed with either staples or running 4-0 (subcuticular) stitch.

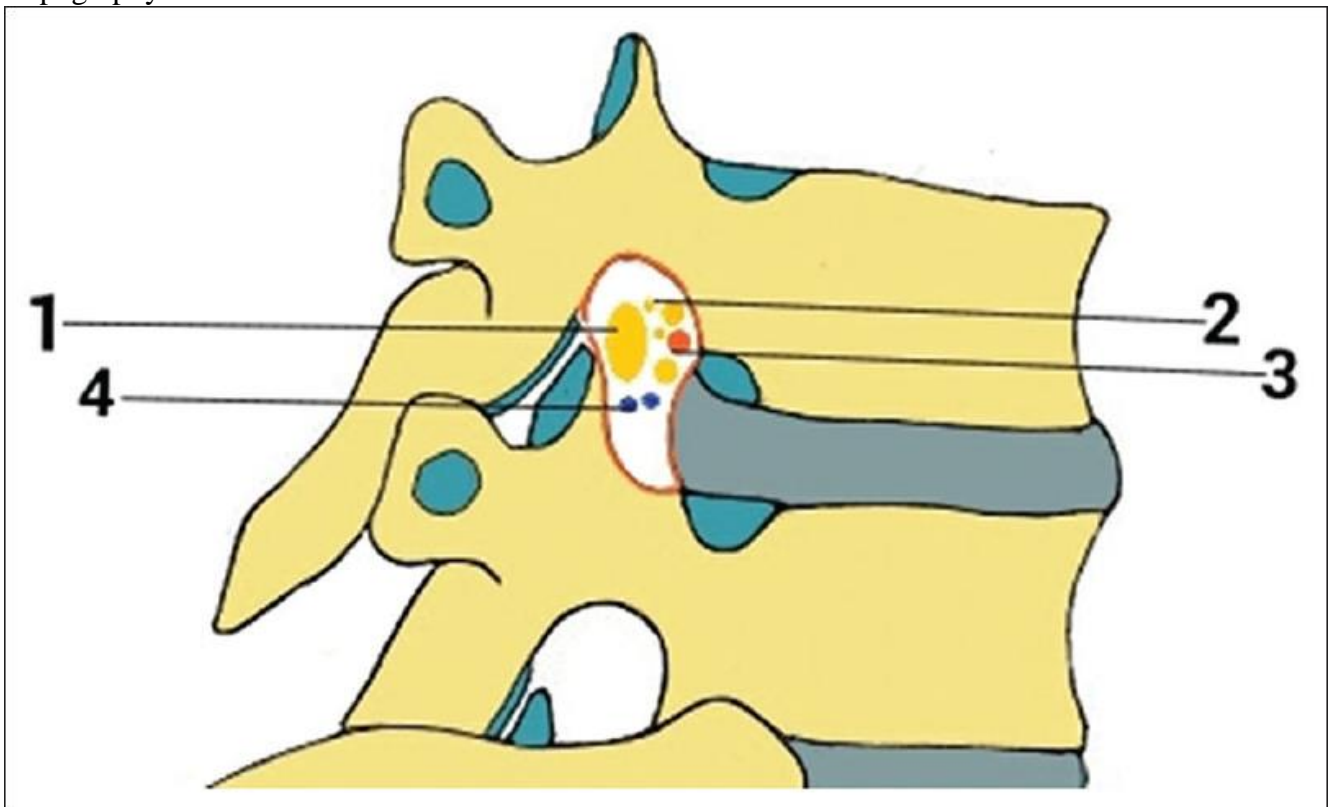
THORACIC SPINE APPROACHES

- key issue (for selecting approach) - ability to visualize lesion without retraction on already deformed spinal cord (**paraplegia can occur from additional traction on already compromised spinal cord!!!**) - imaging requires careful review - particular attention to lesion relationship to midline, dura, disk space, pedicle, and nerve roots.
- radicular arteries variably supply thoracic cord, and **watershed infarcts** can occur after root sacrifice. H:
 - 1) delineate with preoperative spinal angiography location of **artery of Adamkiewicz**.
 - 2) if nerve root sacrifice is necessary, **temporary aneurysm clip** should be placed over root sleeve for 10 to 15 minutes with electrophysiologic monitoring before suture ligation

Adamkiewicz – comes from Left at T10-L2 – better to operate from R side (may check for Adamkiewicz with preop CTA/DSA, may place temporary clip on root before sacrifice and watch IONM).

- use **monitoring** (MEP, SSEP), **steroids**.
- **maintenance of blood pressure** (MAP > 85 mmHg) is crucial in severe cord compression!

Topography of intervertebral foramen:



1: segmental spinal nerve/dorsal root ganglion, 2: sinuvertebral nerves and rami communicantes, 3: spinal branch of segmental arteries, 4: intervertebral veins

LOCALIZATION

See p. Op210 >>

1. DORSAL-LATERAL

Incisions

- determined by instrumentation (if needed), degree of intended exposure, and surgeon preference.

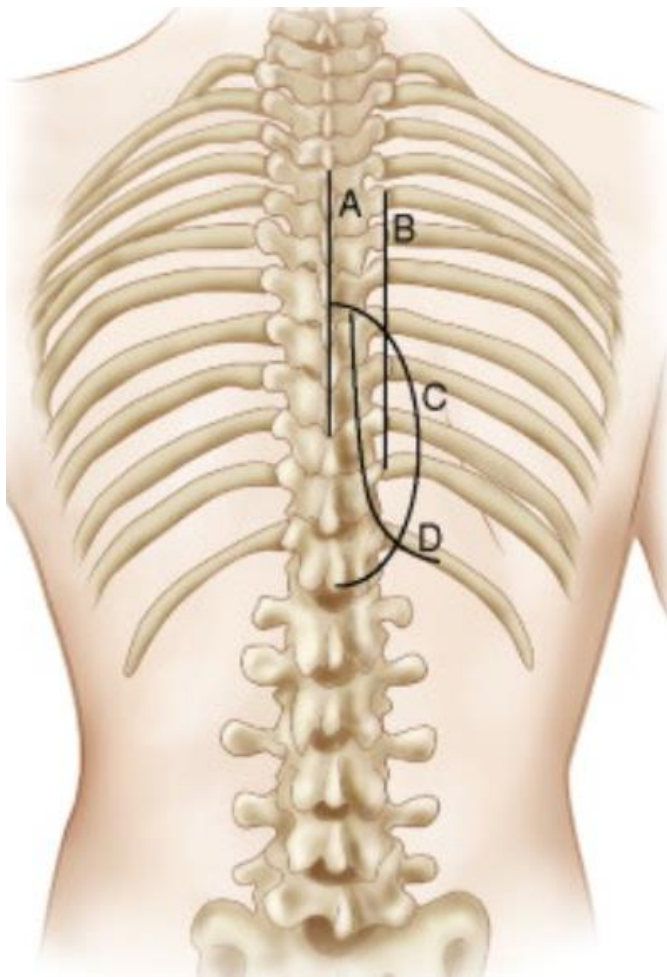
A. **Midline** - adequacy of exposure, potential for bilateral access, and ease of subsequent instrumentation; avascular.

B. **Paramedian** - used in lateral extracavitary approach

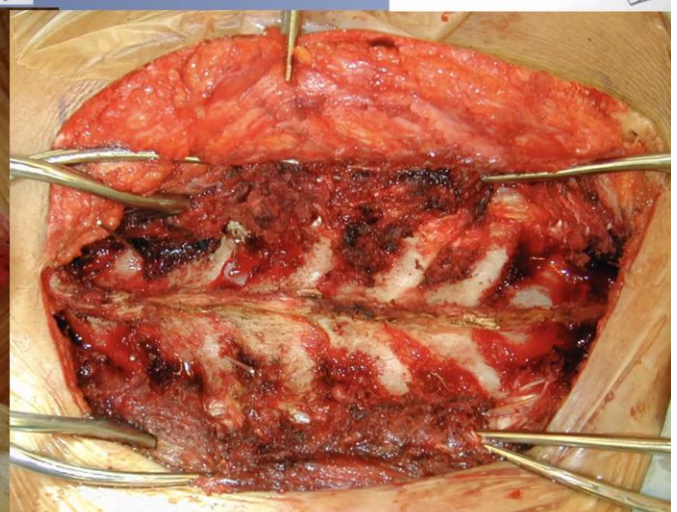
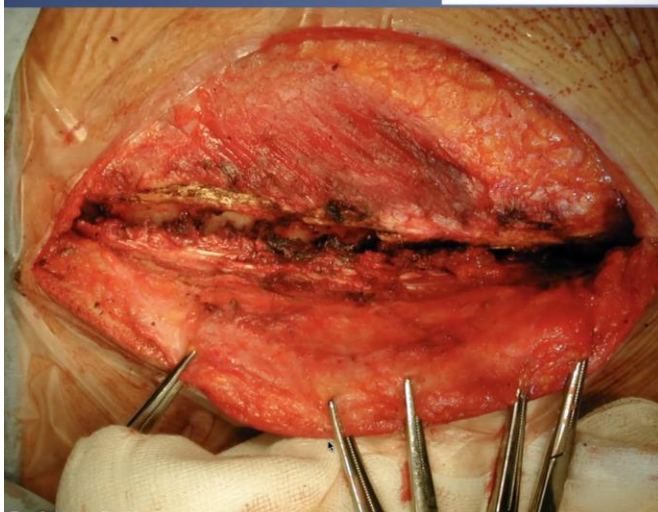
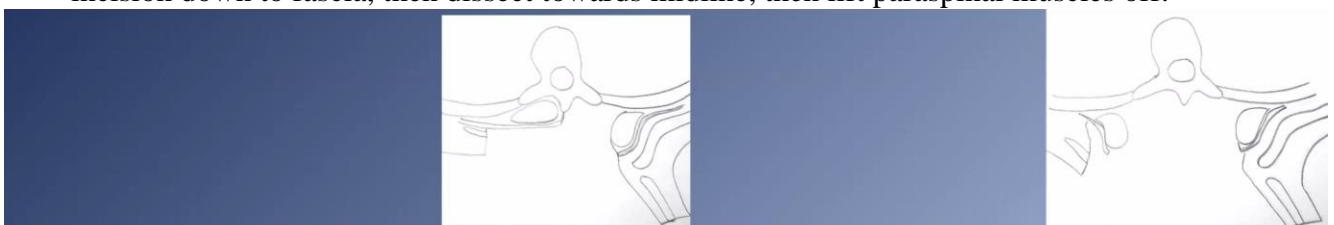
C. **Semilunar** - used in lateral extracavitary approach

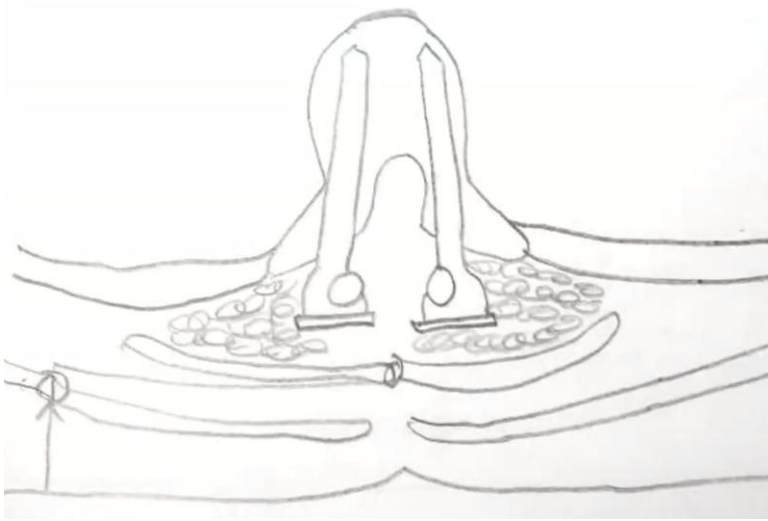
B and C incisions need not extend more laterally than articulation of rib head or transverse process

D. **"Hockey-stick"** or **T in midline** - may be added to midline incision if additional rib exposure is required.



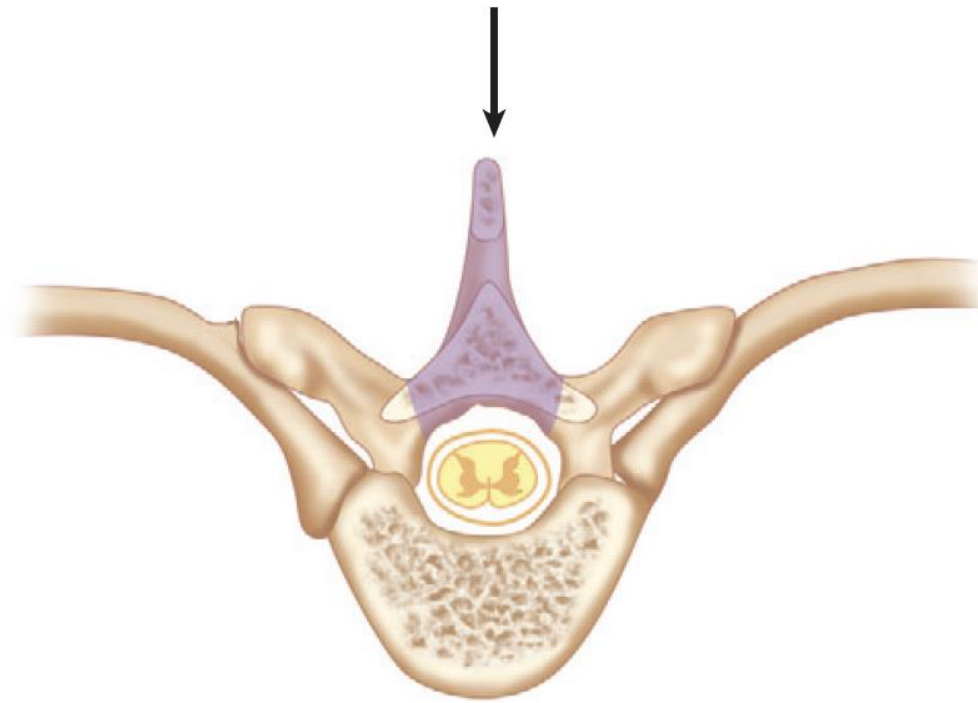
- some experts recommend paramedian approaches for spine oncology cases – incision is no longer in the radiation field – dehiscence / infection rates decrease from 25% to 5%; paramedian skin incision down to fascia, then dissect towards midline, then lift paraspinal muscles off:





LAMINECTOMY

- access to vertebral body and anterior dura is precluded by need for excessive cord manipulation.

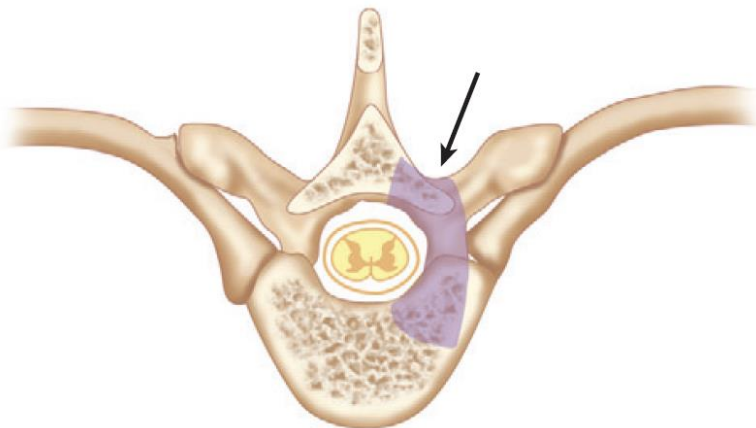


Source of picture: R. Jandial “Core Techniques in Operative Neurosurgery: Expert Consult - Online and Print”, 1st ed (2011), Saunders; ISBN-13: 978-1437709070 >>

- use drill to make troughs (as for CLAM); alternatively – eggshell drill entire lamina and remove with curettes.

TRANSPEDICULAR approach

- bony removal of facet and pedicle to level of posterior vertebral body cortex (+ hemilaminectomy) - most limited access to lateral disk, canal, and vertebral body.

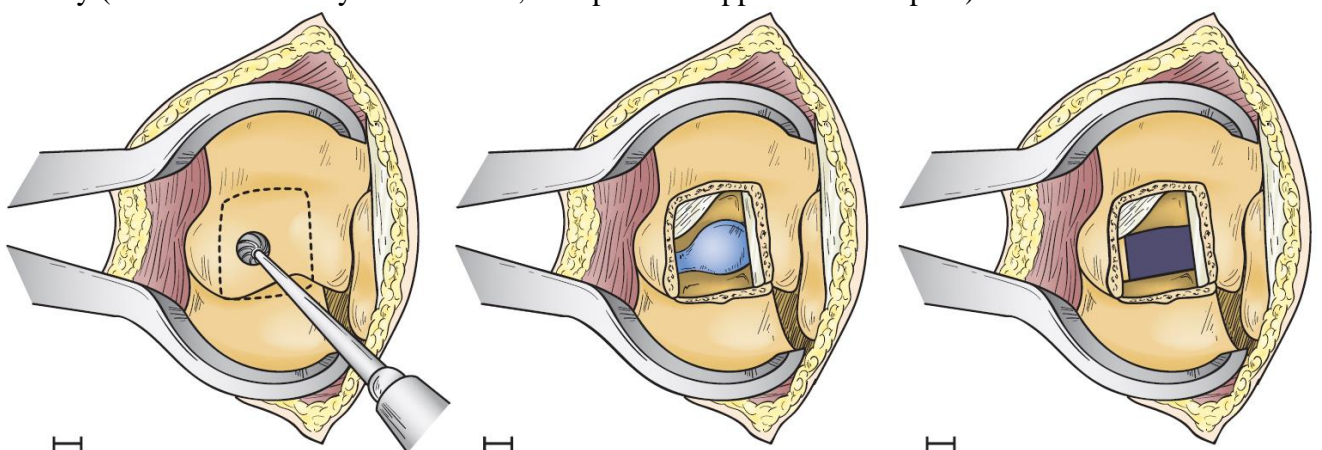


Source of picture: R. Jandial “Core Techniques in Operative Neurosurgery: Expert Consult - Online and Print”, 1st ed (2011), Saunders; ISBN-13: 978-1437709070 >>

- for **lateral calcified** and **paramedian soft** disc herniations, for tamping retropulsed bone fragments in burst fractures.
- use preop CT – see if disc calcified – will be stuck to dura!
- wide 2-level laminectomy / hemilaminectomies with drill.
- drill off pedicle caudal to disc – enter disc space and perform **formal discectomy** to have space to pull herniated disc down into now empty disc space.
 - tumor invasion of pedicle can sometimes soften bone so that suction or pituitary forceps are only tools needed for removal.
- small (1.5-2 cm) cavity can be drilled into vertebral body so that disk can be pushed away from cord.
- *At no point in operation should one attempt to retract cord!*
- remove herniated disc using downgoing curette / tamp retropulsed bone fragments ventrally using increasing size tamps.
- for calcified central disk, entire width of thecal sac should be visualized to ensure thorough decompression; if fragment is stuck to dura – try to rotate dura and carefully dissect that fragment off dura.
- to ensure complete decompression to contralateral side, **contralateral pedicle should be palpated** with blunt instrument.
- for **unilateral** transpedicular approach to midthoracic spine, **no need to instrument** for stabilization (but may leave back pain); if bilateral – need to instrument.

TRANSFACET PEDICLE-SPARING APPROACH

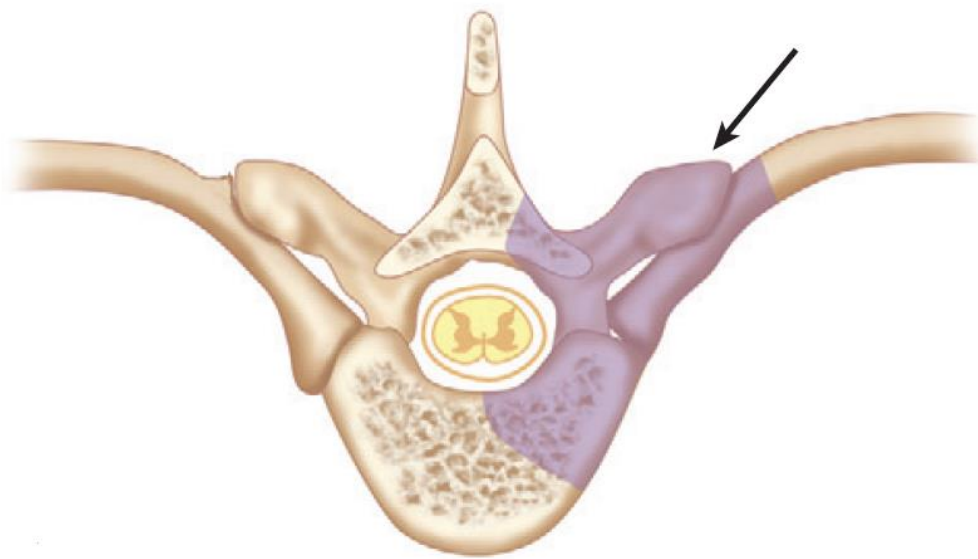
- simpler alternative to transpedicular approach - keyhole **partial mesial facetectomy** without associated pedicle or lamina removal → underlying neuroforaminal fat is coagulated with bipolar cautery (nerve root is rarely encountered, except in the upper thoracic spine):



- underlying anulus is coagulated and incised → disc herniation is removed.

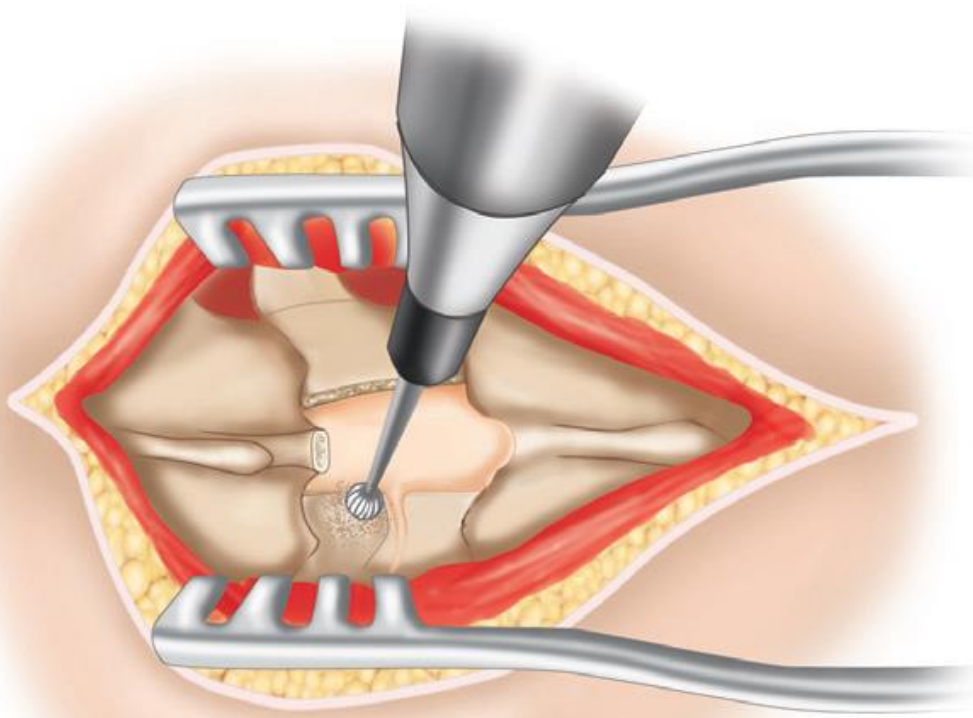
COSTOTRANSVERSECTOMY

- disarticulation and removal of proximal 3-5 cm of rib - allows greater visualization of lateral vertebral body, disk space, and neural foramen; **anterior decompression is limited to midline**.
 N.B. it can expose any thoracic level!



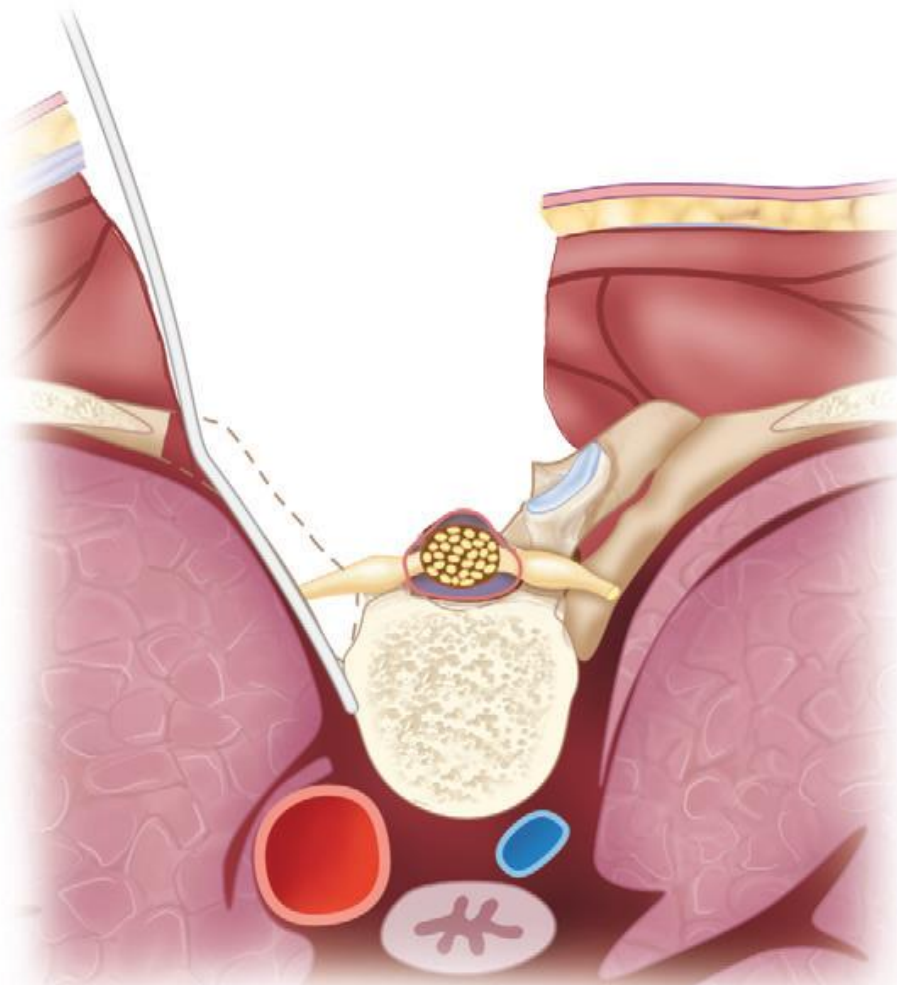
Source of picture: R. Jandial "Core Techniques in Operative Neurosurgery: Expert Consult - Online and Print", 1st ed (2011), Saunders; ISBN-13: 978-1437709070 >>

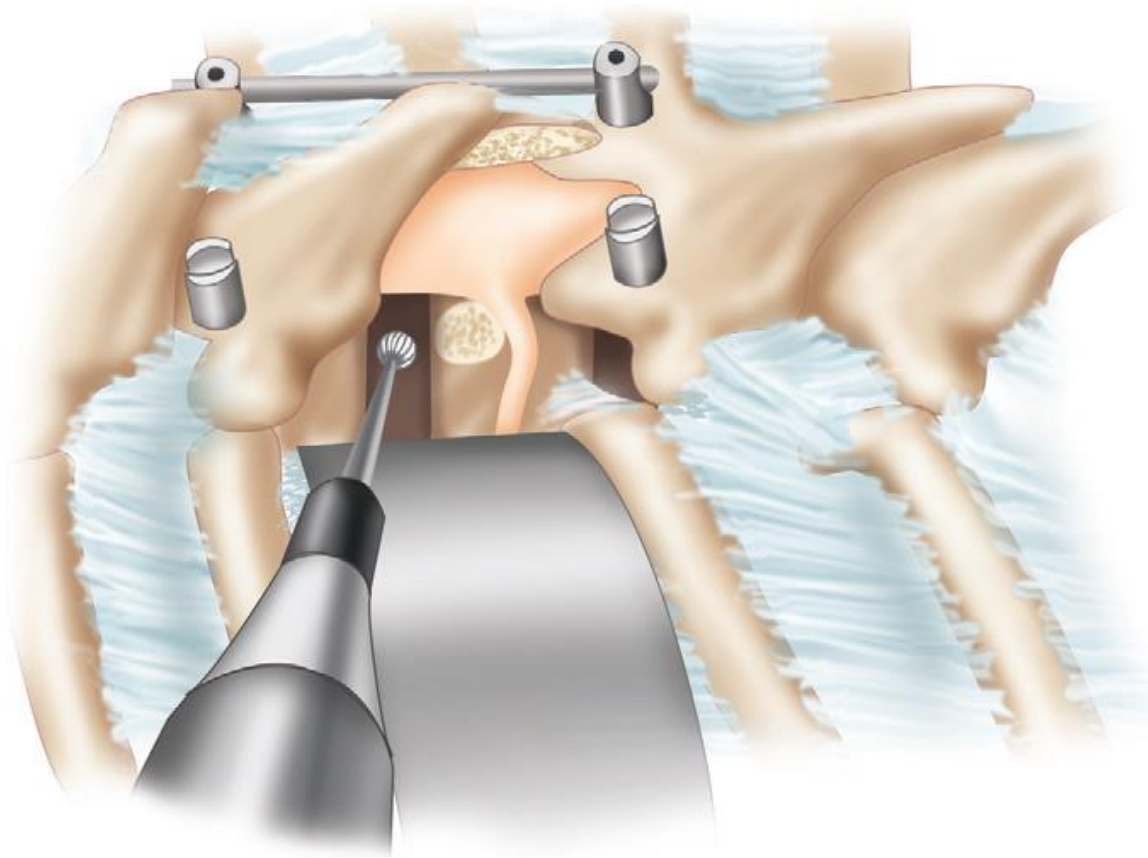
- need long incision as need lots of retraction.
 - incisions vary - paramedian incision (along lateral border of erector spinae muscles) or semilunar incision.
 - skin, subcutaneous tissue, and fascial flap may be rotated medially toward the spinous process.
 - **trapezius muscle** can be incised in line with the skin incision and retracted medially.
 - **erector spinae muscles** are dissected from their attachments and reflected medially (some surgeons prefer to cut this muscle complex and reapproximate it at the time of closure).
- may need up to wide 3-level laminectomy and variable facetectomy:
 - a) for **paramedian** disc - two-level laminectomy and drill pedicle (e.g. T7-8 disc herniation → T7 and 8 laminectomies, T8 pedicle drill off with M8 and T7 pars removal).
 - b) for **lateral** disc - limited laminotomy just over the disc → facet (and maybe superior portion of pedicle) drill off with M8.
- pedicle is drilled to level of posterior vertebral body cortex:



Source of picture: R. Jandial "Core Techniques in Operative Neurosurgery: Expert Consult - Online and Print", 1st ed (2011), Saunders; ISBN-13: 978-1437709070 >>

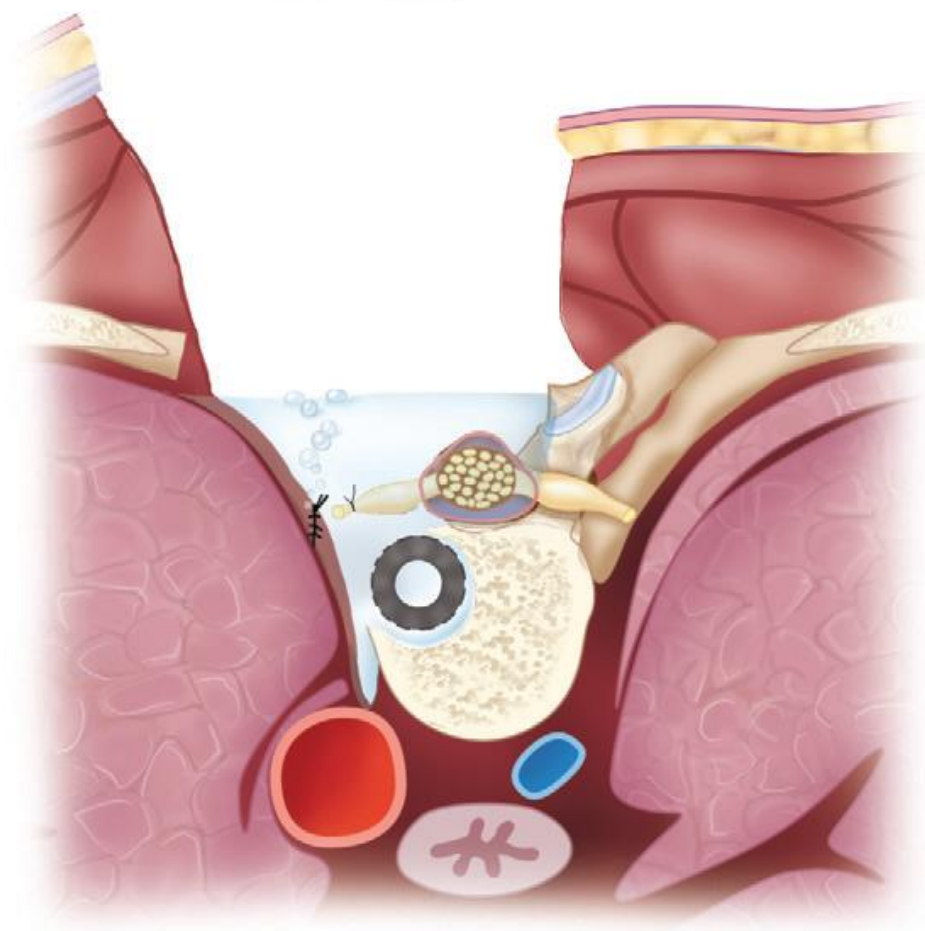
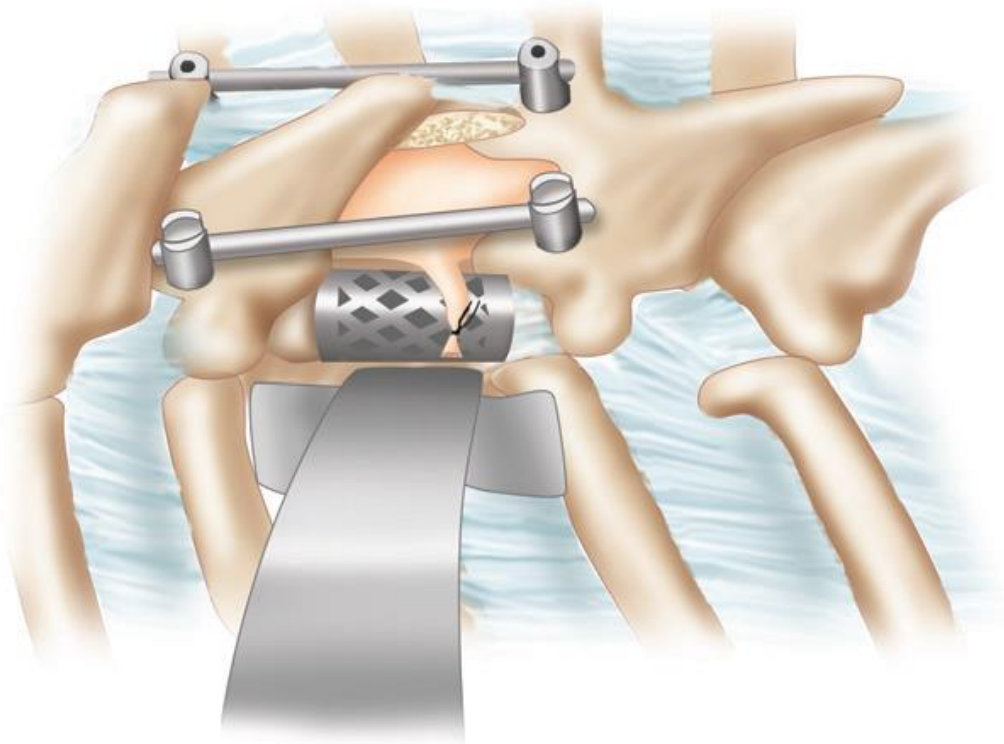
- take proximal rib of level below
 - after circumferential dissection from underlying pleura, rib osteotomy is performed distally using rib cutters, Leksell rongeur, or B-1 footplate.
 - although parietal pleura is typically protected by thin layer of yellow fat, Kerrison rongeur is preferred to Leksell rongeur for removal of rib head to avoid pleural violation.
- downward retraction on pleura with malleable retractor allows visualization of lateral body.
- **subperiosteal dissection** along vertebral body is useful to avoid **segmental vessel** or **sympathetic trunk** transection.





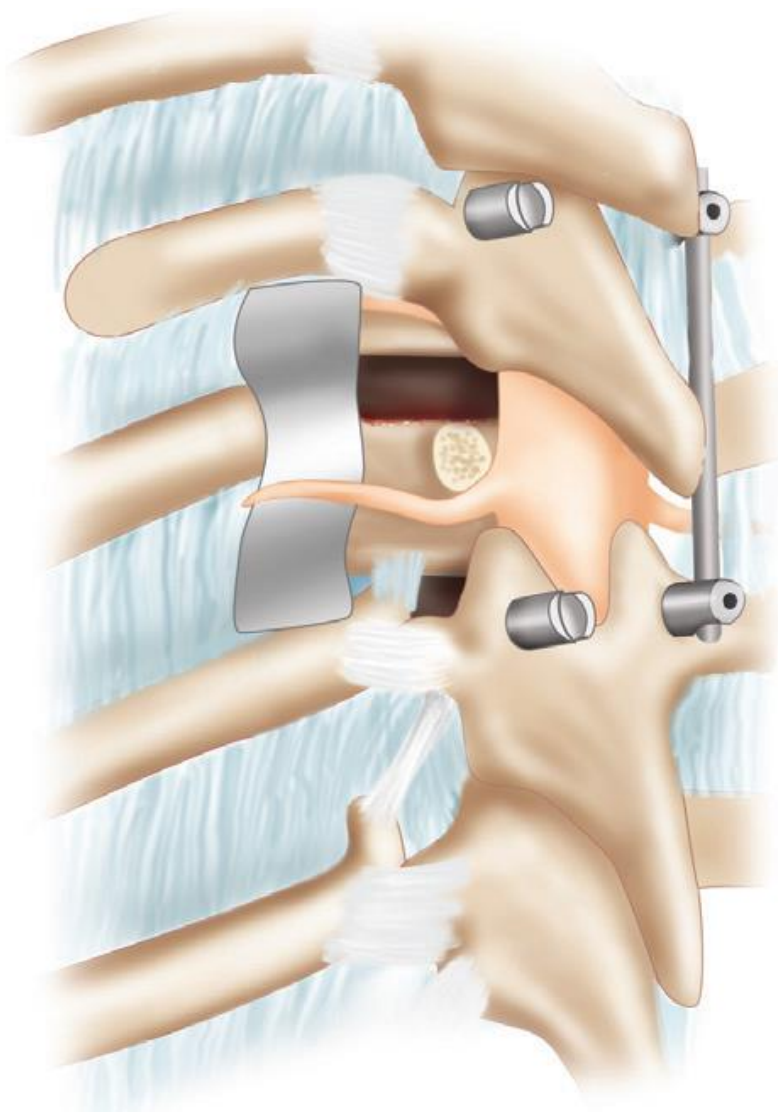
Source of picture: R. Jandial "Core Techniques in Operative Neurosurgery: Expert Consult - Online and Print", 1st ed (2011), Saunders; ISBN-13: 978-1437709070 >>

- approach can be expanded to lateral extracavitary procedure with further distal rib resection, removal of multiple ribs, single-lung ventilation, and more aggressive pleural retraction.
- *reserve tumor debulking until full exposure has been achieved* (early aggressive attempts at tumor resection with inadequate exposure may lead to preventable blood loss).
- *formal discectomy* to have space to pull herniated disc down into now empty disc space vs *small cavity can be drilled into body* so that disk can be pushed away* from cord.
 - *impossible for **calcified disk** that is adherent to dura - curette / high-speed drill should be used to drill disk off thecal sac, rather than pulling it off with rongeur
 - remove disc with reverse-angle curette.
 - ensure complete decompression – see below >>
- if decompression is likely to result in significant destabilization, place pedicle screws and provisionally tighten rod on contralateral side before removal of any bony elements; root sacrifice may be needed for cage placement.



Source of picture: R. Jandial "Core Techniques in Operative Neurosurgery: Expert Consult - Online and Print", 1st ed (2011), Saunders; ISBN-13: 978-1437709070 >>

- Valsalva maneuver under irrigation to evaluate for **occult pneumothorax**.
- for *unilateral* transpedicular approach to midthoracic spine, *no need to instrument* for stabilization; if bilateral – need to fuse.
- for cases that require bilateral transpedicular corpectomy, contralateral screws and temporary rod should be placed to stabilize spine during corpectomy and cage placement:

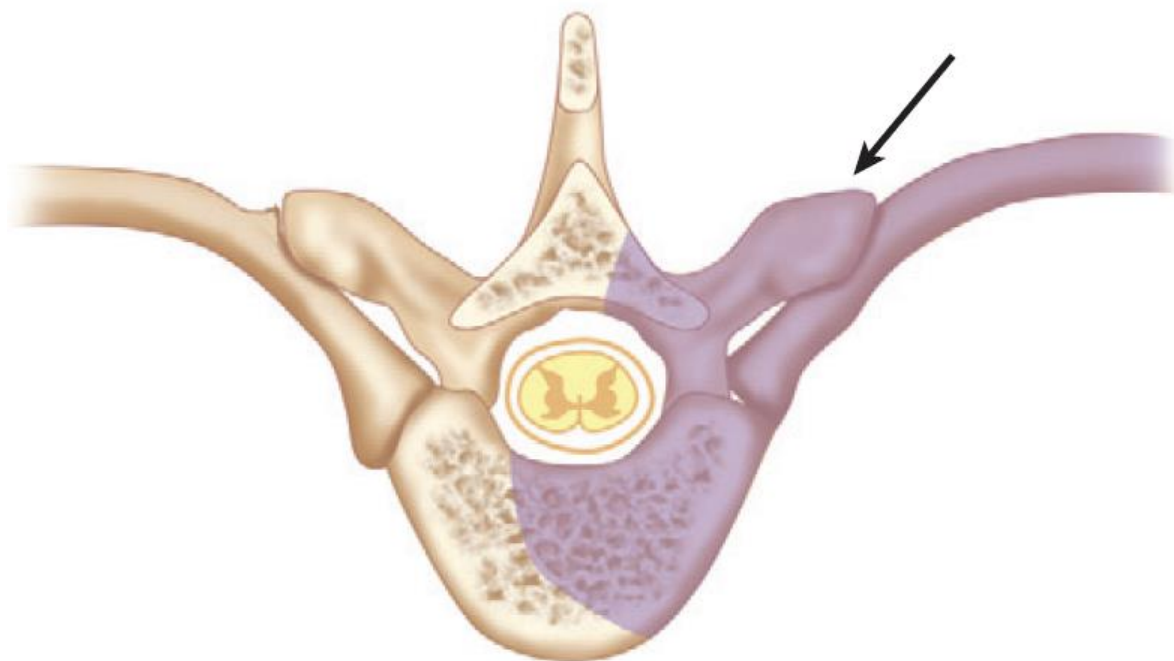


Source of picture: R. Jandial "Core Techniques in Operative Neurosurgery: Expert Consult - Online and Print", 1st ed (2011), Saunders; ISBN-13: 978-1437709070 >>

- if **neuromonitoring signal changes** occur, **compression on temporary rod** may relieve tension on spinal cord that sometimes occurs as body settles after circumferential bony removal.

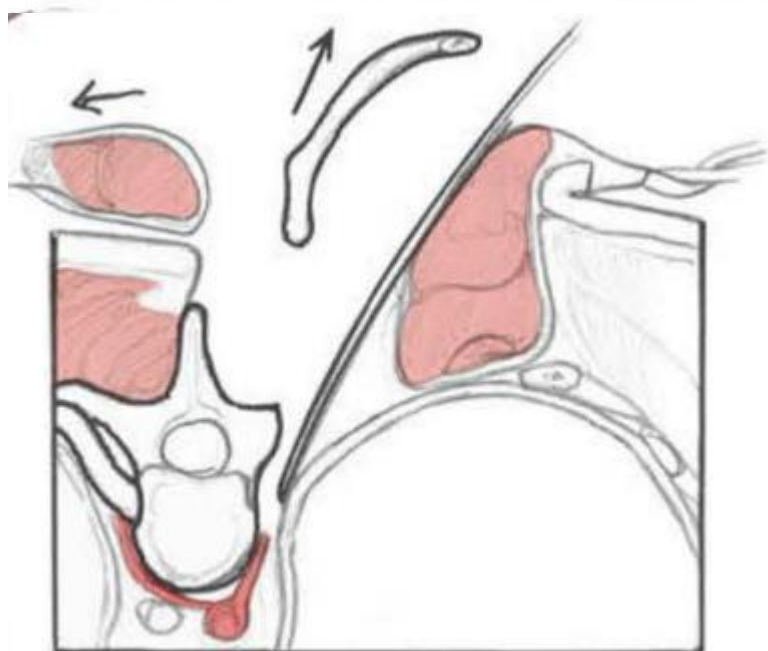
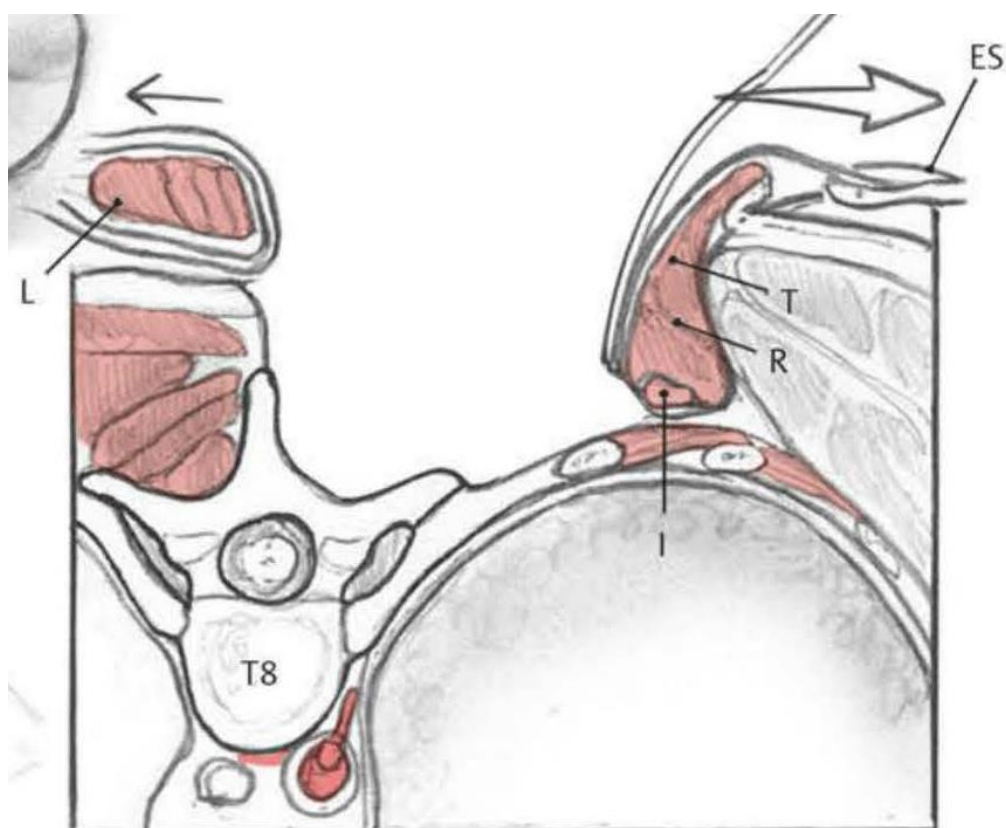
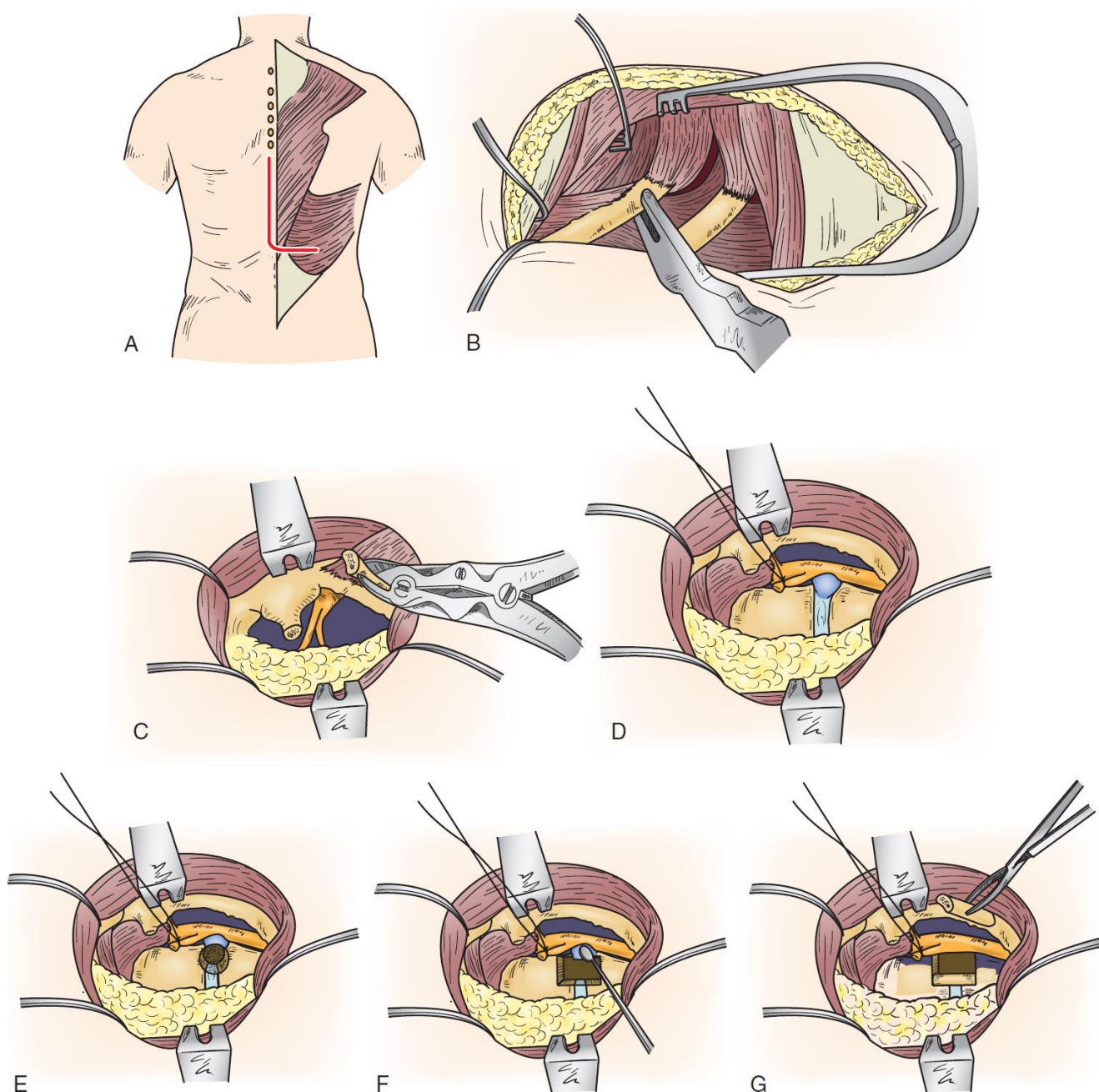
LATERAL EXTRACAVITARY APPROACH

- further lateral extension of costotransversectomy.
- need hockey stick incision (incision is gently curved off the midline for 8-12 cm, enabling skin, subcutaneous tissue, and fascial flap to be rotated far laterally); alternative - paramedian lunar-shaped incision.
- additional 5-7 cm of lateral rib removal + downward pleural retraction allows for greater exposure and more lateral angle of entry, which translates into **improved anterior decompression across midline**.



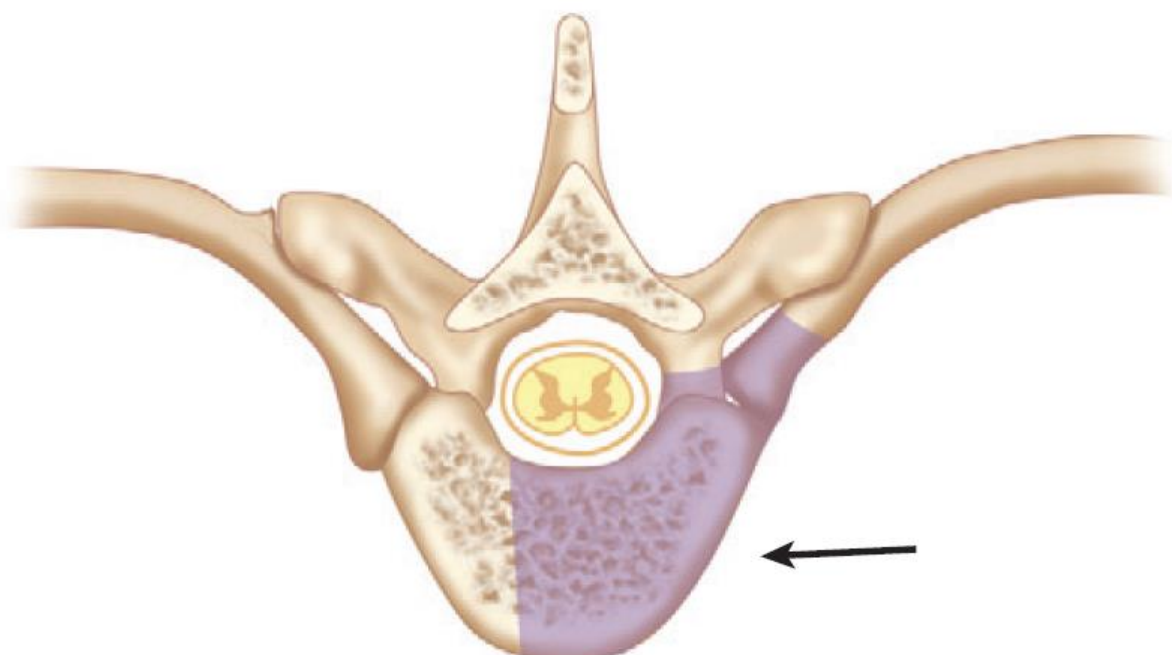
Source of picture: R. Jandial "Core Techniques in Operative Neurosurgery: Expert Consult - Online and Print", 1st ed (2011), Saunders; ISBN-13: 978-1437709070 >>

- Hockey stick-shaped incision centered over the level of disc herniation; caudally, the incision is curved off the midline 8-12 cm to maximize the amount of rib that can be exposed and removed - facilitates a more lateral approach to the disc space; skin, subcutaneous tissue, and fascia are rotated laterally.
- Erector spinae muscles are subperiosteally dissected off the dorsal ribs and transverse processes and flapped medially, exposing the underlying rib(s), which are resected flush with the vertebral body.
- Removal of 8-12 cm of proximal rib, transverse process, and pedicle directly caudal to the disc space.
- Intercostal nerve is identified and traced into its respective foramen → tagged and cut; pedicle caudal to the disc is identified and removed, exposing lateral dura.
- Lateral anulus is incised, and a portion of nucleus is removed, enabling drilling through the disc to the contralateral side; dorsal disc, PLL, and disc herniation are left intact; cavity is created by removing a portion of the rostral and caudal vertebral bodies.
- Remaining disc and PLL are then depressed into this cavity.
- Once ventral dura and spinal canal are inspected (directly or with dental mirror / endoscope) for retained fragments, rib that was removed is fashioned into struts and gently impacted across the defect.



2. VENTRAL-LATERAL

- greatest degree of access to vertebral body, providing access to decompress **entire anterior canal** while avoiding cord manipulation; **posterior elements cannot be addressed**.
Provides excellent exposure to the anterior column T3-L1



Anterior access to Thoracic Spine:

T1-2: Anterior neck suprasternal approach with or without sternotomy.

in majority of patients, T3 vertebra is above suprasternal notch (eps. in patients with long necks)

T3-4: Anterior neck dissection with partial **median sternotomy** and anterolateral thoracotomy "trap door" technique; some experts consider it "no fly zone for anterior approaches" (big vessels, heart) alternative - posterior lateral extracavitary approach

T5-10: thoracotomy:

- a) **Transthoracic open**
- b) **Thoracoscopic** – less postop pain!
- c) **Extra/Retro-pleural** – does not open pleural space – may not need chest tube!

Preferable side:

upper thoracic – right (avoids heart, aortic arch, subclavian and carotid arteries)
middle, lower thoracic – left (avoids inferior vena cava, liver)

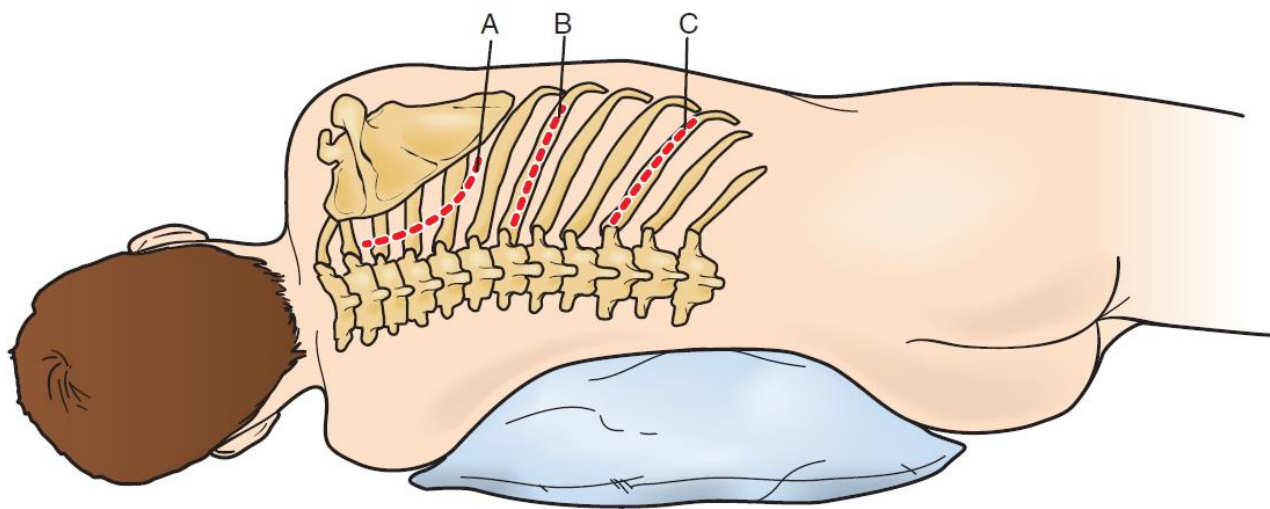
T11-L2: Combined thoracoabdominal approach (requires partial takedown of diaphragm) - retropleural retrodiaphragmatic retroperitoneal approach or transpleural transdiaphragmatic retroperitoneal approach.

Incisions

A - for **upper thoracic spine**: hockey stick incision is made that parallels the medial and caudal scapular border → incision is then carried through the scapular muscles (trapezius and rhomboids) to the ribs → scapula is rotated rostrally to expose appropriate rib

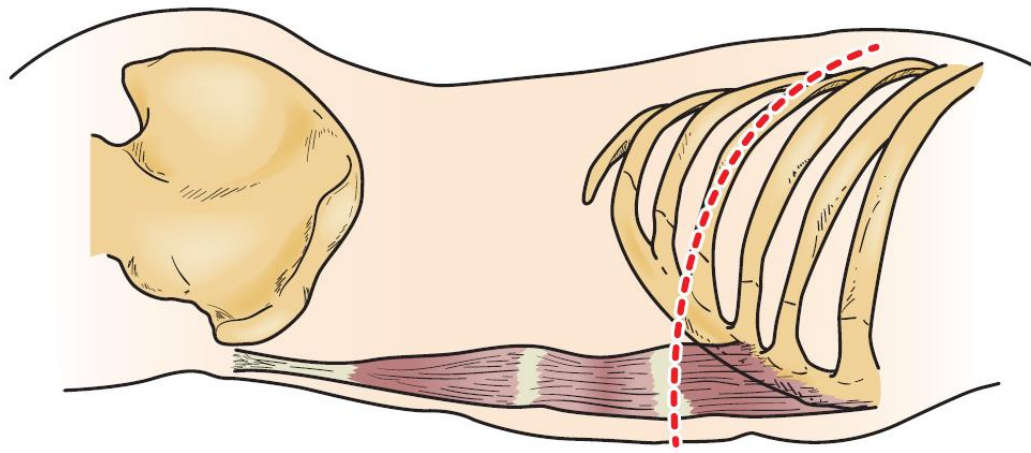
B - for **T5-10**: 12-cm skin incision from the dorsal axillary line to a point 4 cm lateral to the dorsal midline over the rib at the level of pathology.

C - for **thoracolumbar**

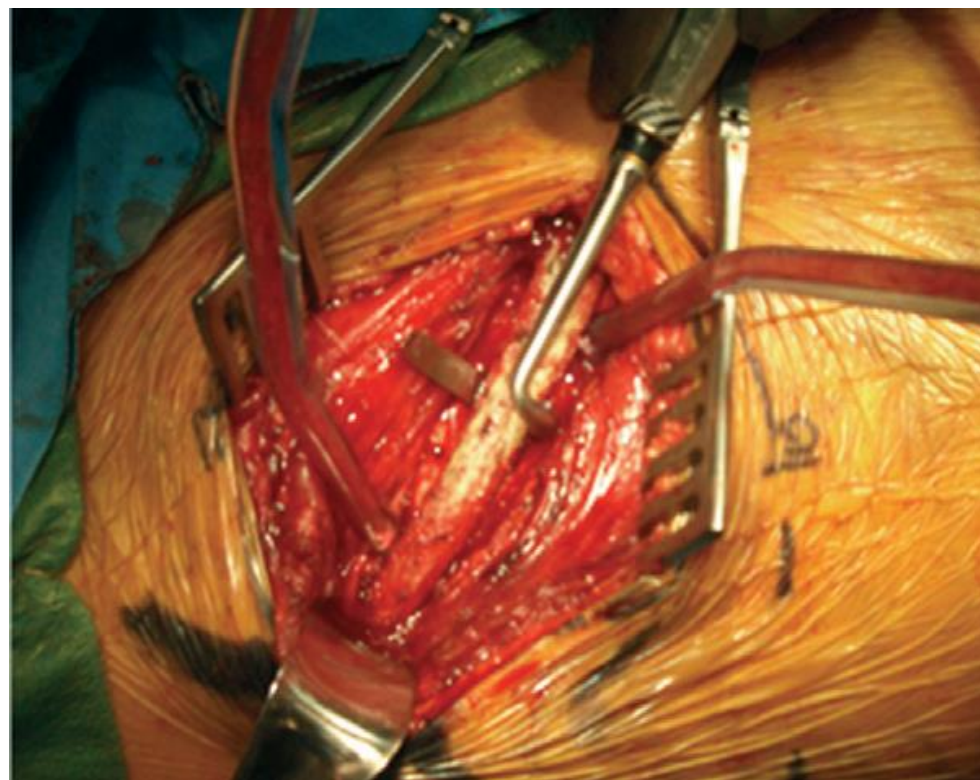


TRANSTHORACIC APPROACH

- thoracic surgical instruments include:
 - rib retractors (e.g., Finochietto retractor)
 - self-retaining retractor system
 - long-bayonnetted instruments (Kerrison rongeurs, pituitary rongeurs, Leksell rongeurs, bipolar cautery)
 - high-speed drill with long handle
- indication – calcified central disc herniations (possible to do several levels)
N.B. 5-12% of thoracic disks are intradural
- contraindication: pulmonary pathology such that patient cannot tolerate one-lung ventilation.
- double-lumen endotracheal tube should be used for intubation; lung deflated and retracted medially and superiorly during the case.
- steroids, MAP > 85 mmHg.
- table – Jackson table with flat top; lateral decubitus position; beanbag and tape are used to maintain this position so that the patient may be rolled during the decompression.
- area of pathology is centered over the break in the table
- incision - over the rib to be resected (two rib levels above level of rib corresponding to the affected level?); incision extends from border of paraspinous muscles to sternocostal junction:

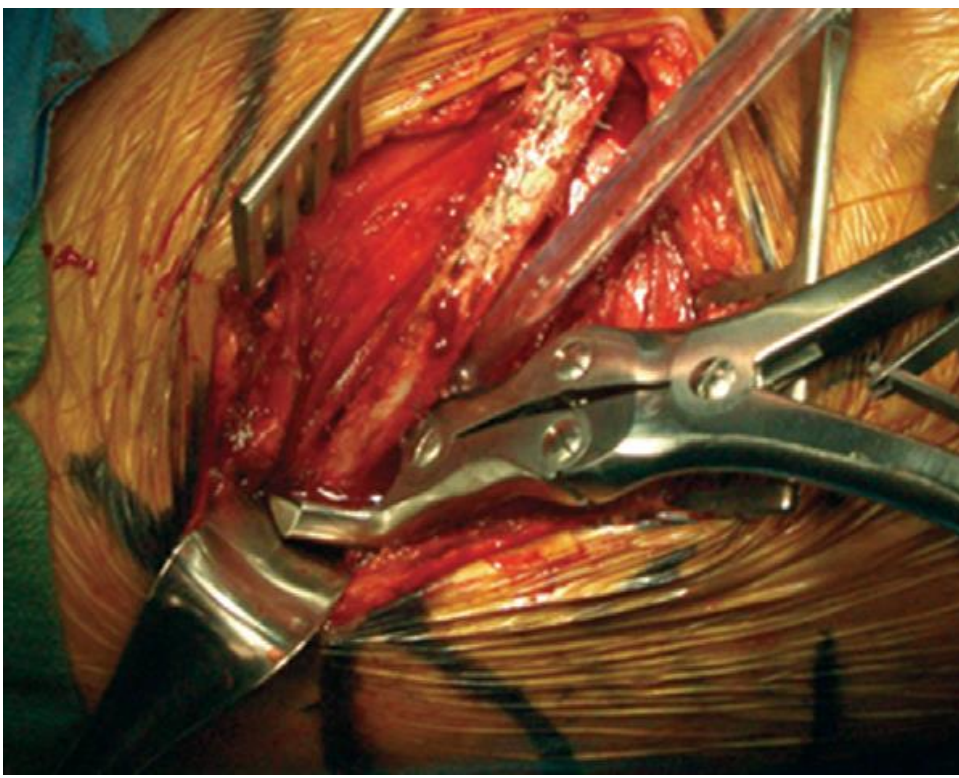


- verify that the proper rib is being resected by AP X-ray.
- periosteum of the rib is then incised and exposed using subperiosteal dissection.
- intercostal neurovascular bundle is dissected in a subperiosteal fashion from the ventral surface of the rib without violating the underlying endothoracic fascia and pleura using periosteal elevator and Doyen elevator:

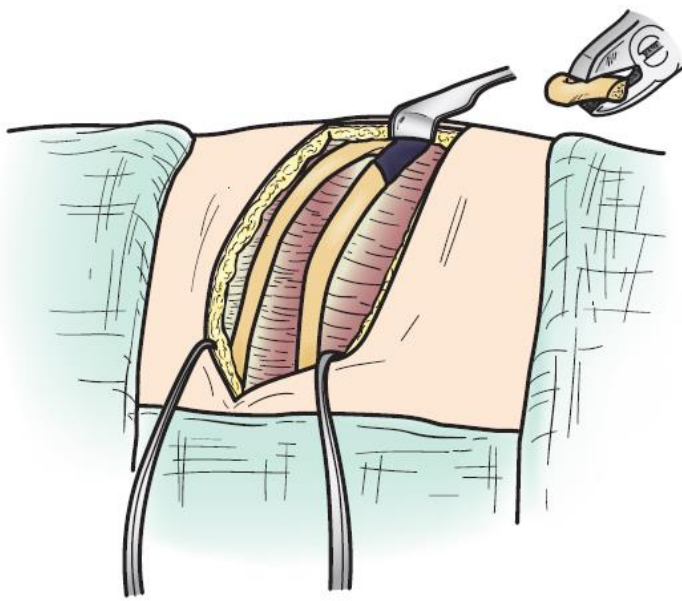


Source of picture: R. Jandial "Core Techniques in Operative Neurosurgery: Expert Consult - Online and Print", 1st ed (2011), Saunders; ISBN-13: 978-1437709070 >>

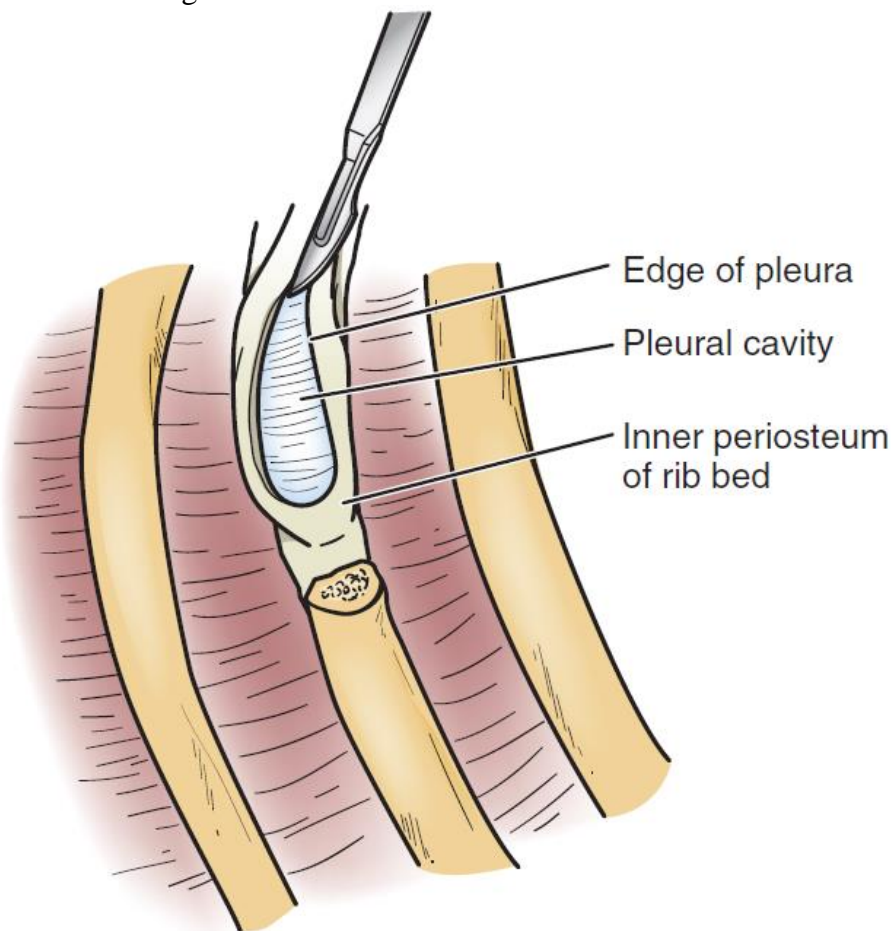
- rib is exposed and resected flush with the lateral spinal column; harvested rib is saved for grafting material; edges of the rib are waxed



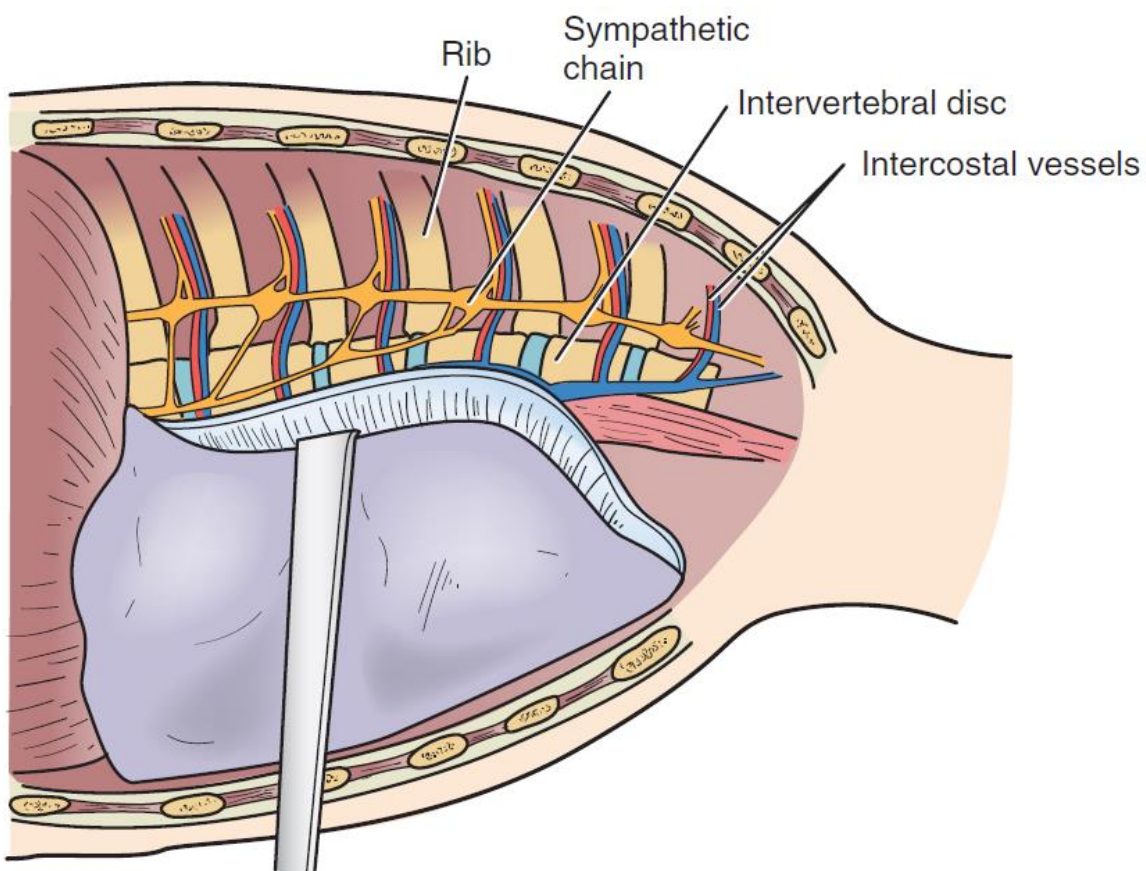
Source of picture: R. Jandial "Core Techniques in Operative Neurosurgery: Expert Consult - Online and Print", 1st ed (2011), Saunders; ISBN-13: 978-1437709070 >>>



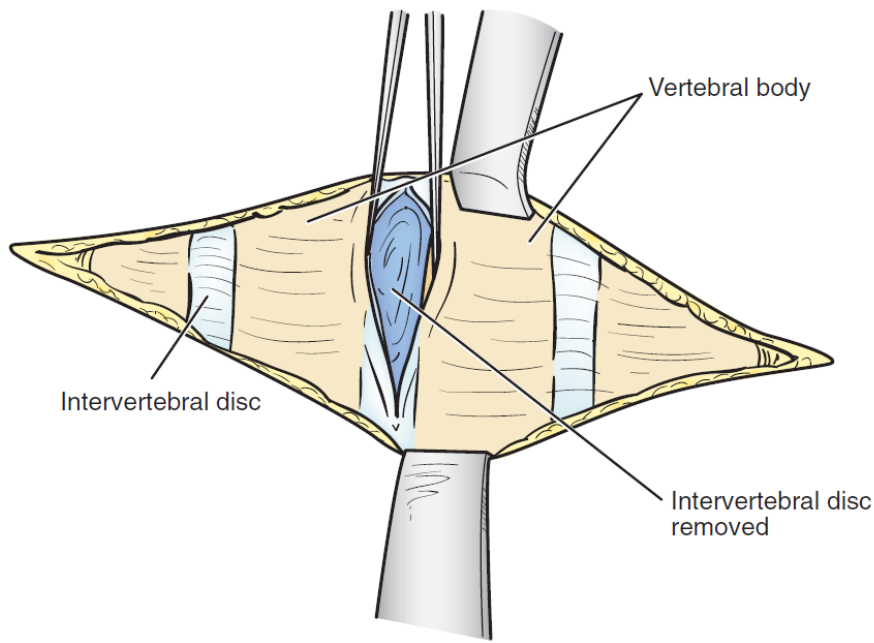
- pleura is opened in line with the rib bed → wound is held open by introducing a rib spreader as a self-retaining retractor



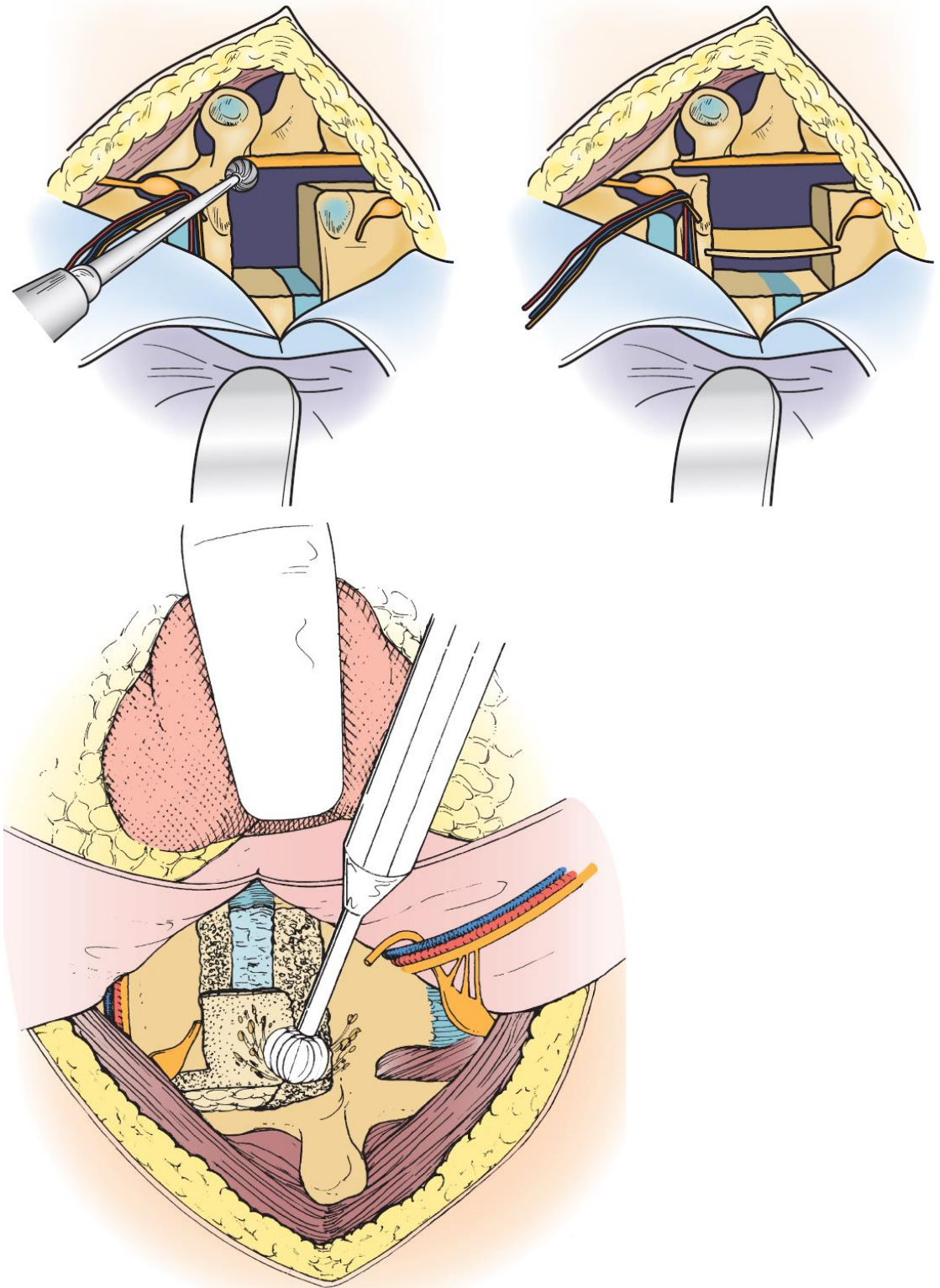
- lung is deflated, covered with a moistened laparotomy pad and gently retracted medially and ventrally.
- vertebral body and disk space are exposed in a subperiosteal fashion - **parietal pleura overlying spinal column is incised** and carefully reflected with Cobb elevator; dissection must **avoid injury to the segmental vessels, as well as the sympathetic chain** that crosses the middle portion of each vertebral body (but often necessary to ligate or clip intercostal vessels; some say sympathectomy may occur with little or no morbidity).



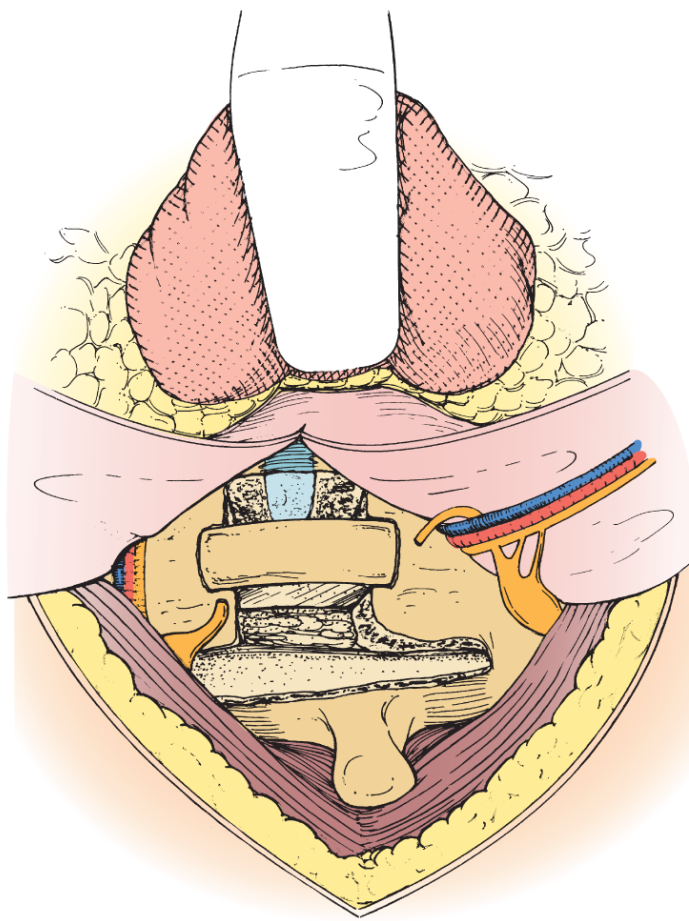
- to expose the dorsolateral disc space, ventral spinal canal, and entire neuroforamen, it is necessary to incise costotransverse ligament and to **drill off rib head** with high-speed drill, osteotome, or rongeur - rib head removal exposes disc space and neural foramen.
- disc space is exposed, and the disc herniation can now be removed.
 - transverse process, neurovascular foramen, and rostral and caudal boundaries of pedicle (caudal to disc space) are palpated with a small nerve hook
 - find foramen and pedicle → using high-speed drill, (rostral part of) caudal pedicle is removed, and lateral dura mater is identified.



- if additional exposure of the neuroforamen is needed, *section intercostal nerve proximal to dorsal root ganglion*.
- dorsal annulus is incised*, and the discectomy is carried across the vertebral body approaching the other side.
 - *care is taken to leave intact the most dorsal margin of disc and PLL
- for **calcified central disk**, entire width of thecal sac should be visualized to ensure thorough decompression;
 - after disc curettage, 25% of the upper and lower vertebral bodies (i.e. dorsal quadrants next to disc space) need to be removed with high-speed drill (amount of removal needs to be precisely tailored to the pathology encountered).
 - drilling is taken across the vertebral body to the contralateral pedicle.
 - under microscope magnification, curettes (forward and reverse-angle) are used to manipulate the vertebral endplates and annulus into the formed cavity.
 - dorsal disc margin and PLL can be incised and gently depressed into the cavity, away from the ventral dura mater.
 - PLL may be calcified; therefore, it needs careful burring
 - PLL should be opened sharply above then below the level of the calcified disk protrusion
 - any disk material around the spinal cord can be gently teased away from it in an anterior direction in atraumatic fashion using microdissectors and reverse-angled curet; this is performed across the entire disk space until the contralateral pedicle is reached.

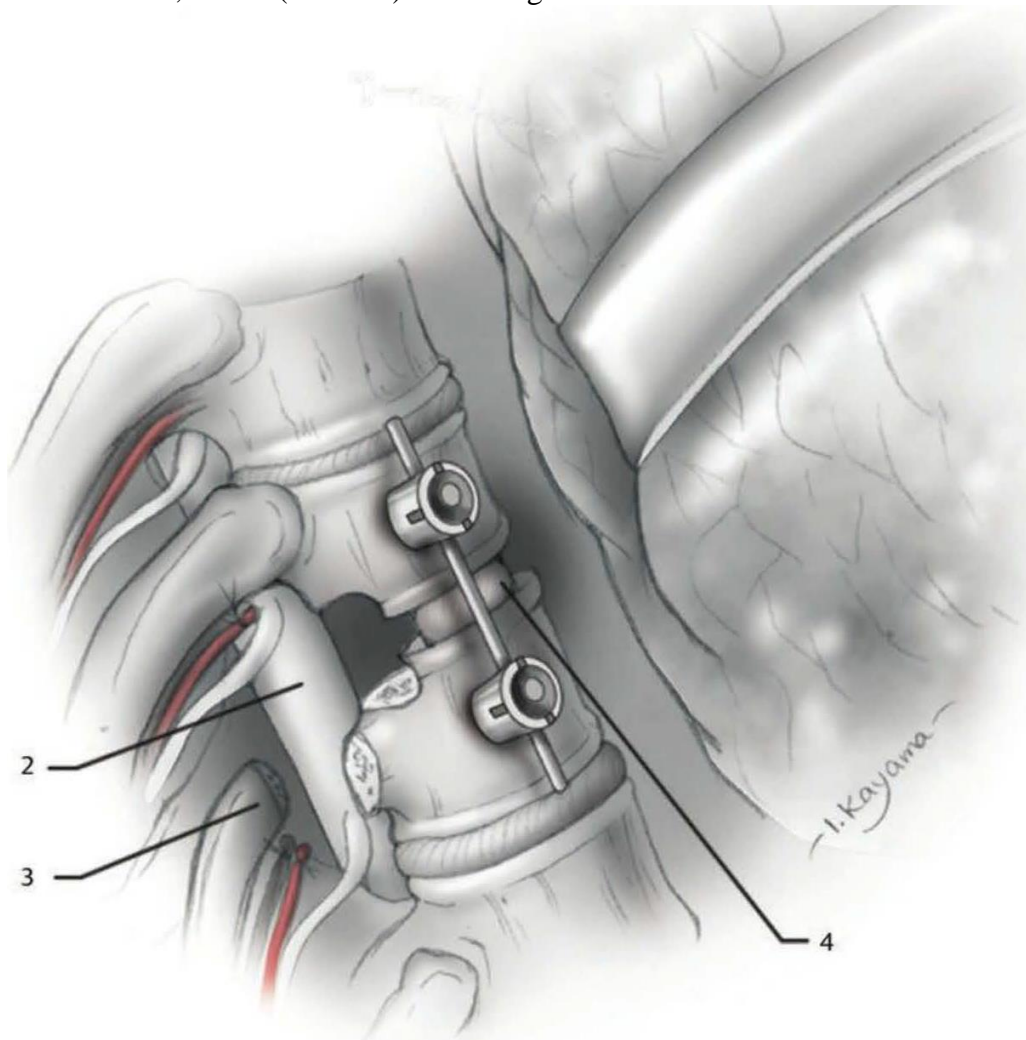


- great care should be taken not to retract or manipulate cord in any way.
- direct palpation using microsurgical blunt hooks can confirm exposure across to contralateral pedicle (i.e. to ensure complete decompression to contralateral side, contralateral pedicle should be palpated with a blunt instrument).
- **ensure all disc was removed** – see below >>
- interbody rib graft is placed:

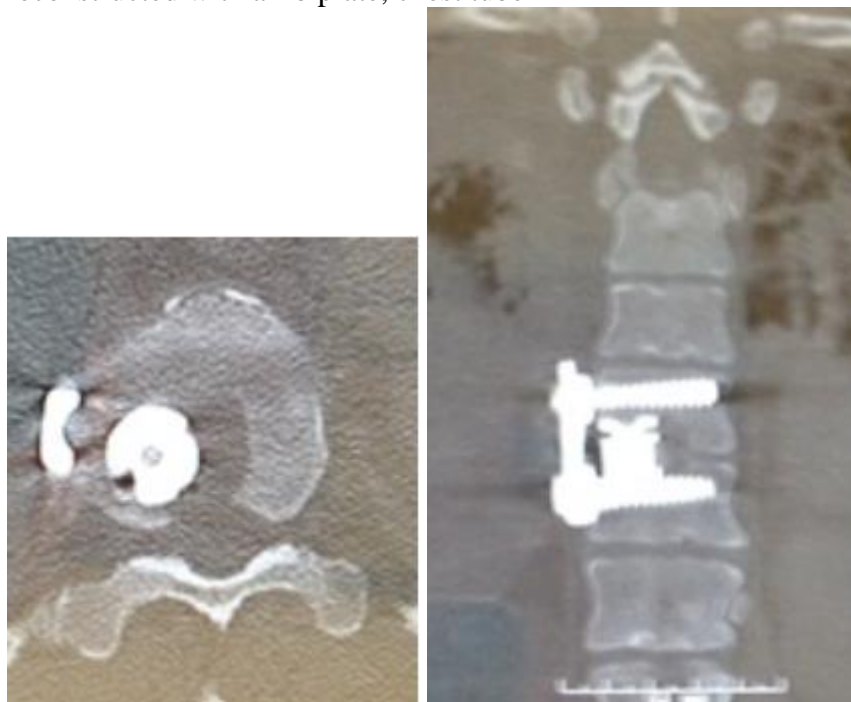


- if a significant amount (> 25%) of the superior and inferior vertebrae has been removed, an **instrumented fusion** is recommended (ventral spinal canal and dura mater should be directly inspected to ensure that there is no encroachment of the spinal canal).
- parietal pleura is closed over the vertebral bodies.
- lung is expanded under direct visualization.
- chest cavity is then copiously irrigated.
- parietal pleura is closed over a thoracostomy tube
 - 1-2 chest tubes (28-32 F, depending on bleeding during closure) are inserted superior to the incision in the midaxillary line and put on low suction.
- ribs are reapproximated with heavy (No. 2 Vicryl) sutures.

Discectomy with bone graft placed between the vertebral bodies and instrumentation (lung retracted):
 2. Thecal sac, 3. Rib (resected). 4. Bone graft.



Example - T10-11 discectomy: pleurae taken down over the T10 and T11 vertebrae, as well as T11 rib head → drill the rib head and underlying pedicle → partial corpectomy of T10 and T11 + T10-T11 discectomy → expandable cage filled with morcellized autograft → anterior thoracic plate → rib reconstructed with a rib plate, chest tube



POSTOP

- potential for considerable postoperative pain (H: epidural analgesia).
- lung collapse (H: closed chest drainage for 3-6 days)

CSF-PLEURAL FISTULA

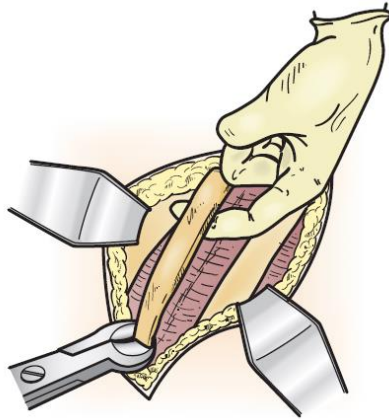
- may fill entire **hemi-chest** (hydrothorax) postop and cause **subdural hematoma!**
- treatment:
 - 1) **lumbar drain**
 - 2) reoperate for repair: primary repair, graft, use small pleura flap → **chest tube on water seal** [not on suction]

RETROPLEURAL THORACOTOMY APPROACH

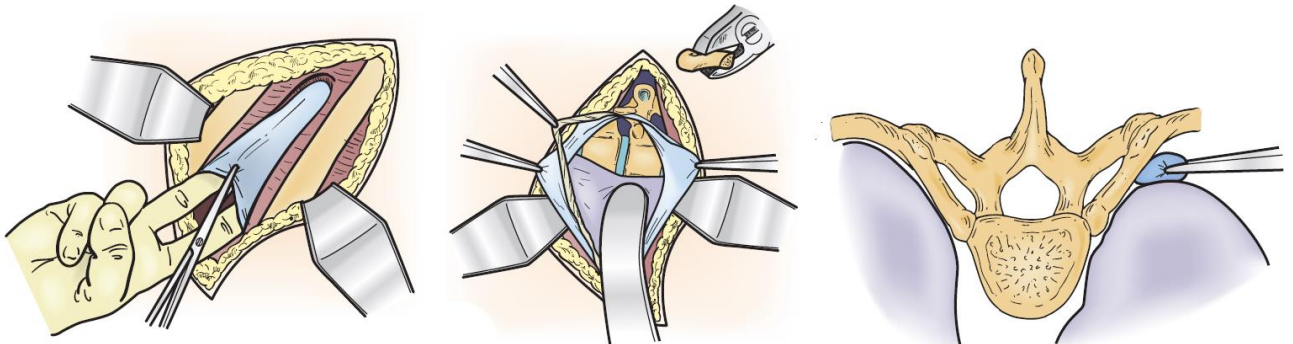
See “Transthoracic” for details.

Specifics:

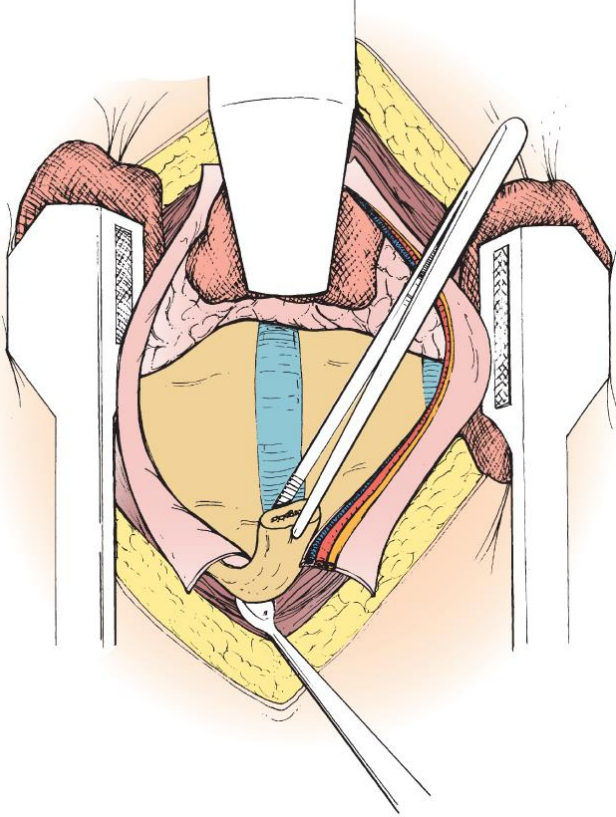
- 8-10 cm (but the most proximal 4 cm) of rib is removed.



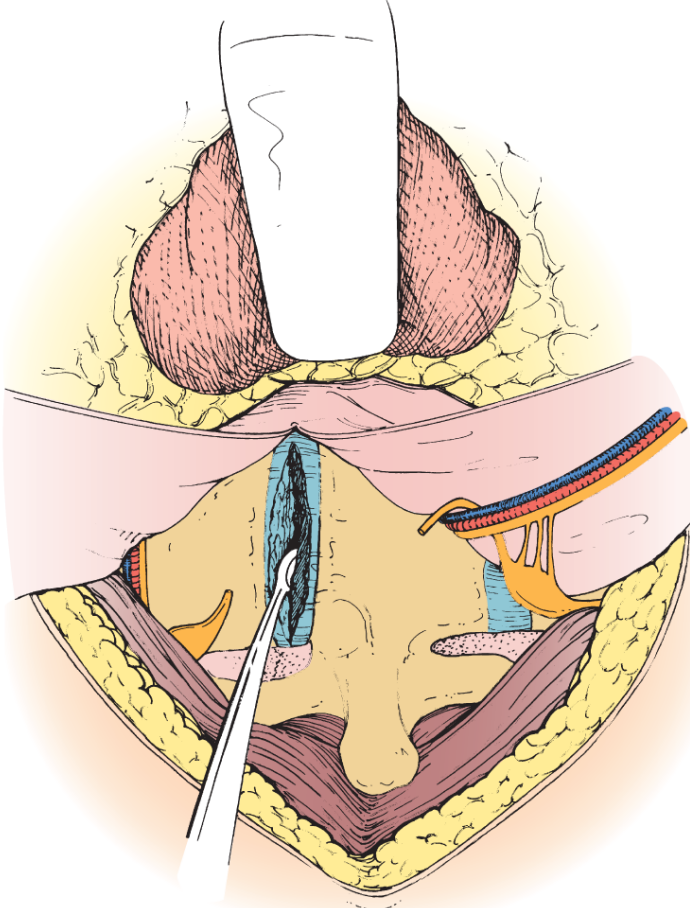
- well-defined **endothoracic fascia** is identified within the rib bed → endothoracic fascia is opened in line with the rib bed and **parietal pleura** is bluntly swept away from undersurface of endothoracic fascia (there is a potential space between endothoracic fascia and pleura that may contain loose areolar tissue).
 - intercostal neurovascular elements, thoracic sympathetic chain, thoracic duct, and azygos veins are contained against thoracic wall and vertebral bodies within this fascial layer.



- placement of a rib retractor.
- pleura is dissected off the spinal column.
- table-mounted malleable retractor maintains retraction of a laparotomy pad-covered lung.
- endothoracic fascia is opened over remaining 4 cm of proximal rib:



- endothoracic fascia opening is continued onto the lateral aspect of the vertebral bodies - it is reflected away from the disc: intercostal vessels remain within reflected tissue, thoracic sympathetic chain is divided → disc is incised:



THORACIC (LATERAL) CORPECTOMY

- contraindication - limited life expectancy (< 3 months) - protracted recovery period may not be justified.

VESSELS

- preoperative angiography / CTA to identify **artery of Adamkiewicz** and vascular flow to tumor (allow for embolization when appropriate).

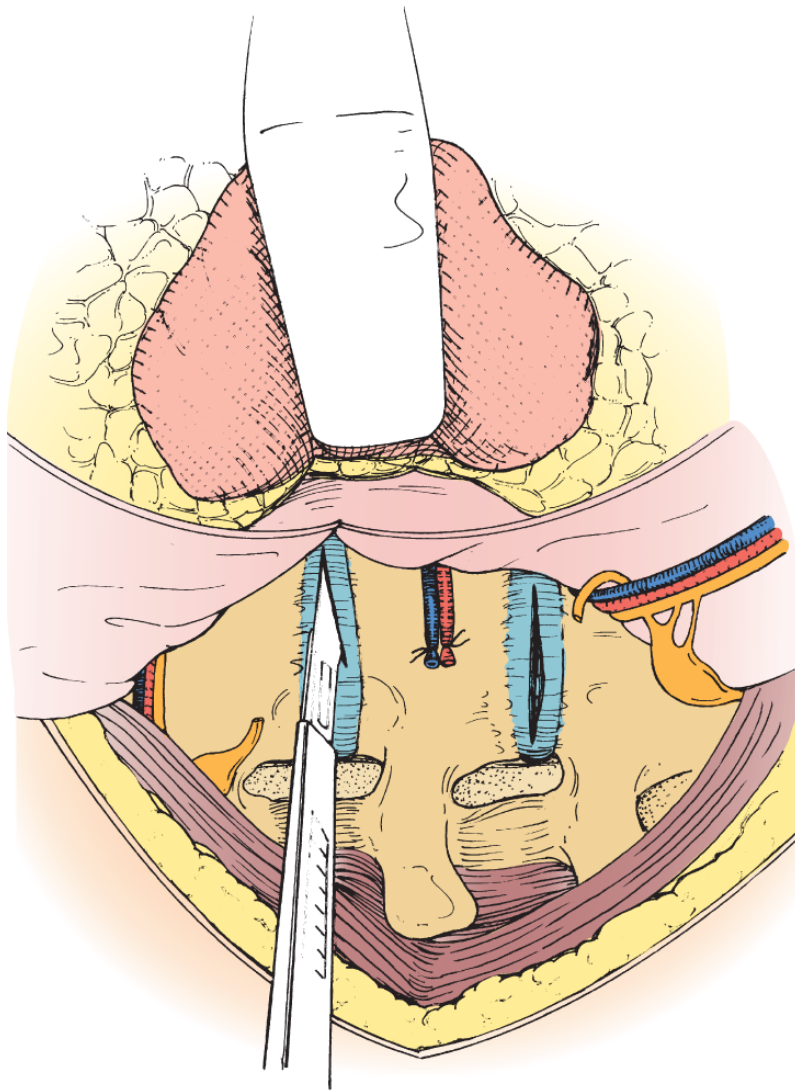
See p. A203 >>

TECHNIQUE

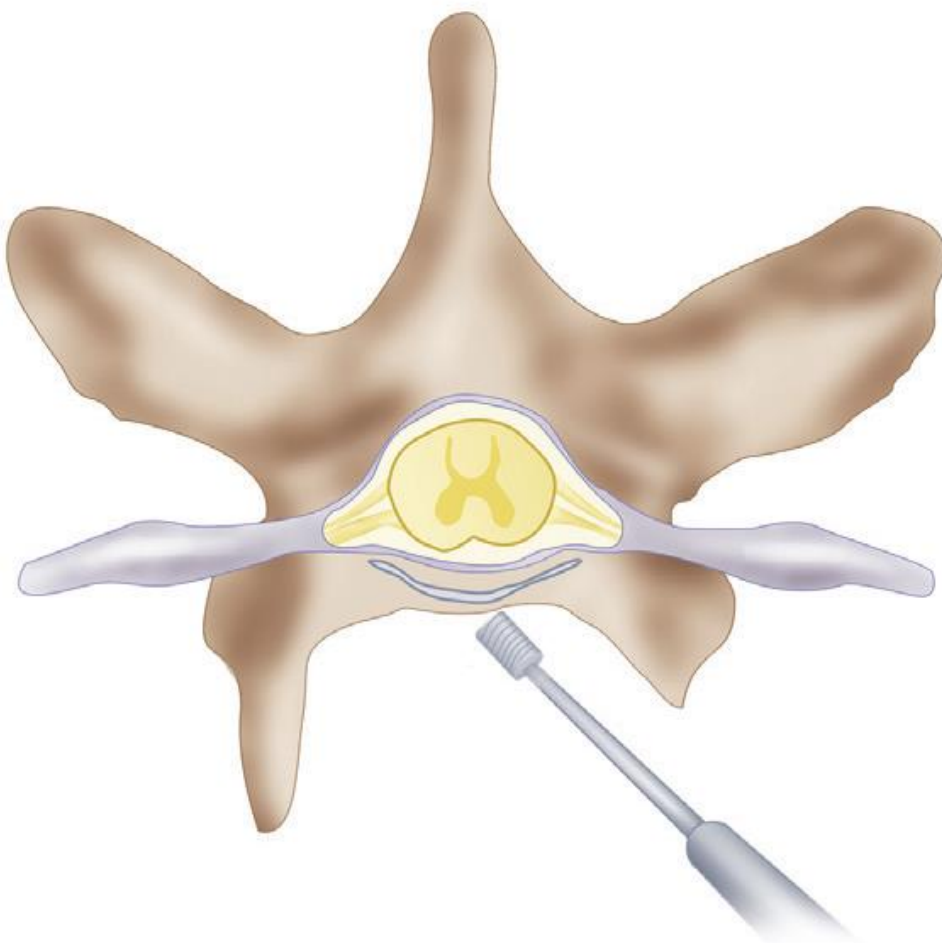
- self-retaining rib spreader system → ipsilateral lung is collapsed.

- transpleural* or retropleural plane is developed bluntly through resected rib bed.
*parietal pleura is incised longitudinally over the intended vertebral bodies.
- **segmental vessels (posterior intercostal arteries)** over each body (located in the mid portion of the vertebral body) must be identified, dissected, isolated, and preserved if possible; they can be ligated / clipped if needed, but this should be done anterior (proximal) to the lateral foramen.
N.B. segmental vessels bleed a lot; maybe difficult to control, especially if injured on the contralateral side.

Adequate exposure for a corpectomy requires additional removal of just proximal rib head at the lower margin of the vertebral body to be resected; segmental vessels are ligated and divided.



- Cobb elevator is used to retract the parietal pleura posteriorly, and electrocautery is used to subperiosteally strip it off each vertebral body (again – watch for segmental vessels).
- pedicle is visualized and drilled off (gives idea of posterior margin for resection).
- cranial and caudal disks are removed back to annulus or posterior longitudinal ligament (PLL) – using osteotome and pituitary rongeurs.
- corpectomy is performed with rongeurs and osteotomes when preserving bone, which may be used later for autograft; high-speed bur is essential for completing corpectomy by drilling out contralateral pedicle and posterior wall back to PLL (high-speed drill (small burr) should be used as it is less traumatic than rongeurs):

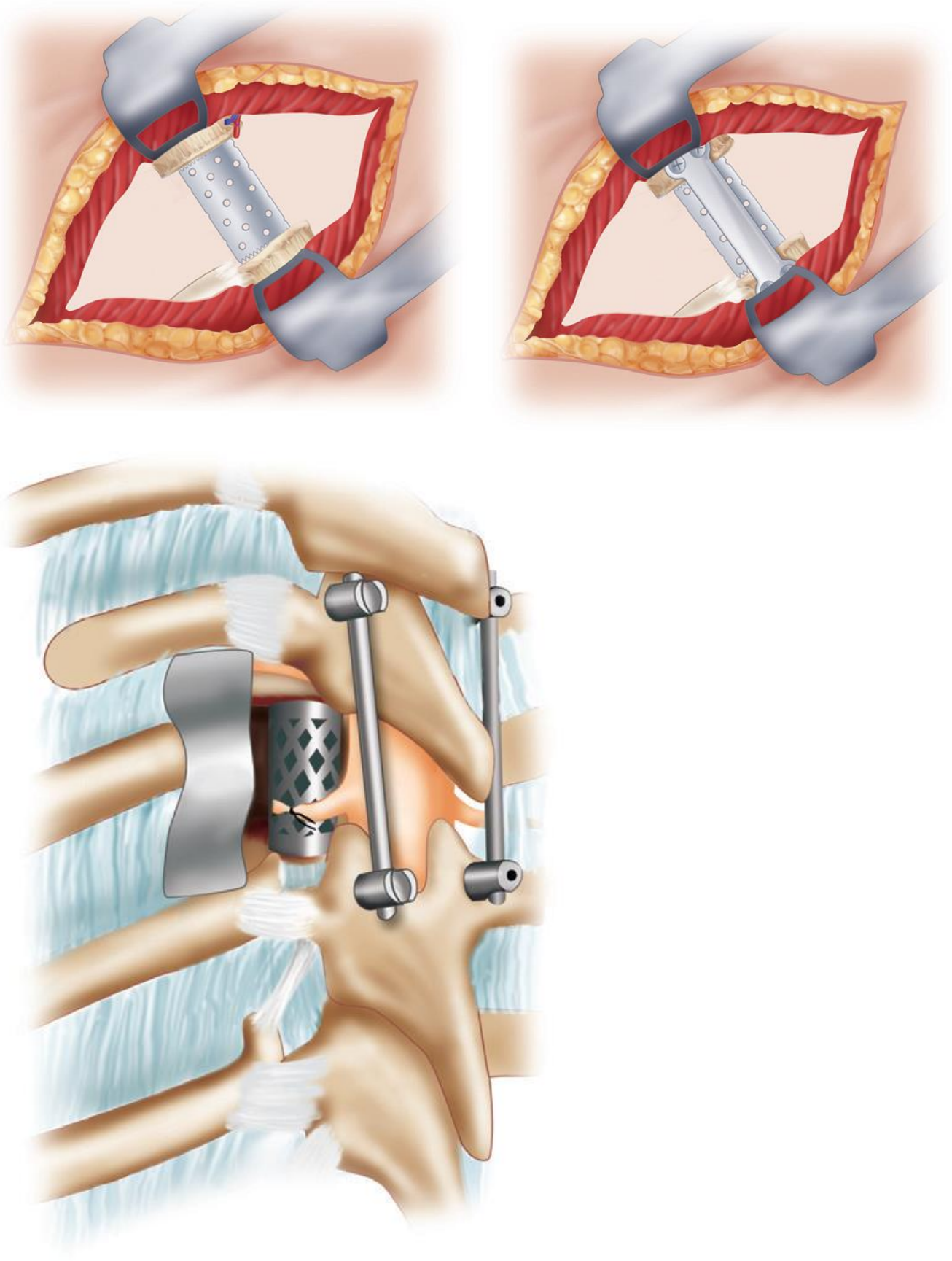


Source of picture: R. Jandial “Core Techniques in Operative Neurosurgery: Expert Consult - Online and Print”, 1st ed (2011), Saunders; ISBN-13: 978-1437709070 >>>

- PLL and any bony remnants can be removed off the dura with fine curettes and Kerrison rongeurs.
N.B. remove posterior vertebral body from contralateral pedicle toward ipsilateral side; this prevents decompressed dura from expanding into operative field and obscuring visualization.
- ALL and lip of bone is left behind anteriorly for stability and to prevent graft kickout (unless curative tumor resection is being performed).
- **dural injury** – attempt to repair; alternative – DuraGen, sealants, lumbar drain.

Reconstruction of corpectomy defect

- Tricortical iliac crest autograft
 - Ceramic or titanium metallic cages packed with bone graft
 - Steinmann pins and polymethyl methacrylate (PMMA).
- with or without instrumentation (anterior or lateral plating or posterior screw fixation):

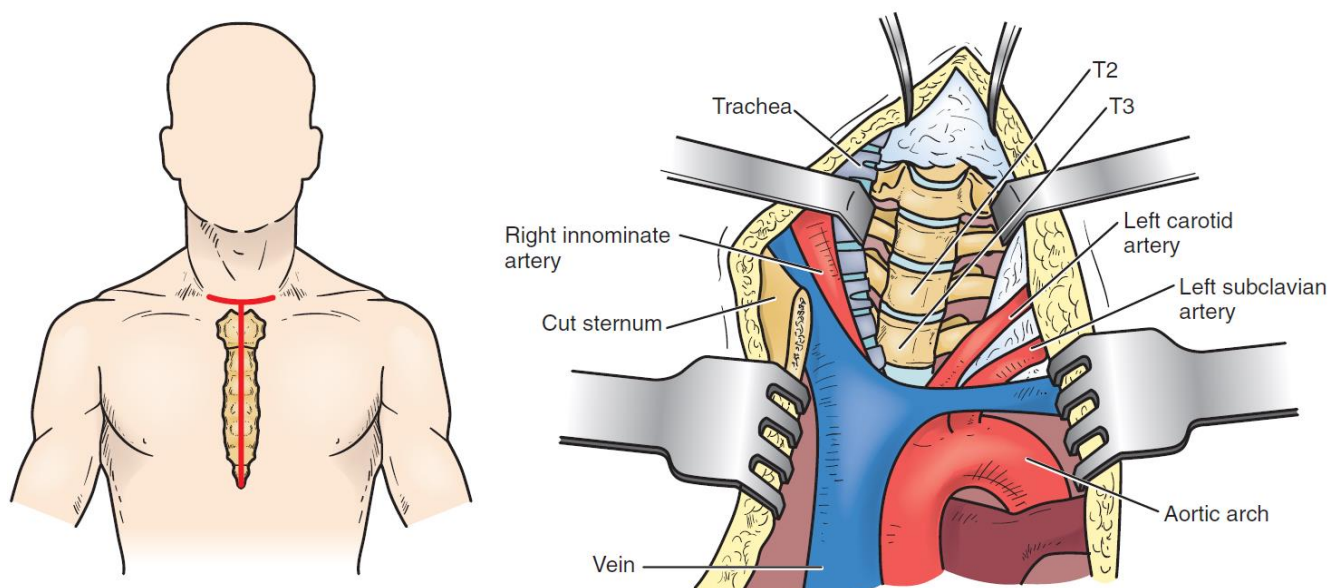


Source of picture: R. Jandial "Core Techniques in Operative Neurosurgery: Expert Consult - Online and Print", 1st ed (2011), Saunders; ISBN-13: 978-1437709070 >>

- compression is applied across cage.

TRANSSTERNAL APPROACH

- for midline, densely calcified herniations at T2-5 (for T4-5 level, preoperative imaging must define the relationship between the aortic arch and the ventral spinal column).



- T-shaped skin incision that has its vertical limb extending from the lower cervical skin crease to a few centimeters below the xiphoid process
- strap muscles are then divided, and the precervical fascia and pretracheal fascia incised at the level of the sternal notch.
- sternum is then split and retracted laterally.
- thymus is retracted to the right, exposing the left innominate vein, which can be sacrificed.
- working space is between the left common carotid artery and the innominate artery, trachea, esophagus, and thyroid - gentle retraction of these structures exposes the ventral region of the spinal column.
- challenging operation with significant physiologic cost, risk of left recurrent laryngeal nerve and the thoracic duct injuries.

THORACIC DISKECTOMY

- paraparesis may progress to paraplegia even with surgical intervention!
- **simple laminectomy approach – high risk of paraplegia** (awareness started with Logue review in 1952):
 - a) if no discectomy - does not remove ventral compression
 - b) if discectomy is performed – requires cord retraction

At no point in operation should one attempt to retract cord!

- use **preop CT – see if disc calcified.**
- **verify adequacy of cord decompression:**
 - 1) examine ventral spinal canal with a dental mirror, endoscopy
 - 2) *contralateral pedicle should be palpated* with a blunt instrument
 - 3) *check with US* – shape of cord, areas of remaining compression
 - 4) restoration of dural pulsations

APPROACH SELECTION

By **nature and location of disc:**

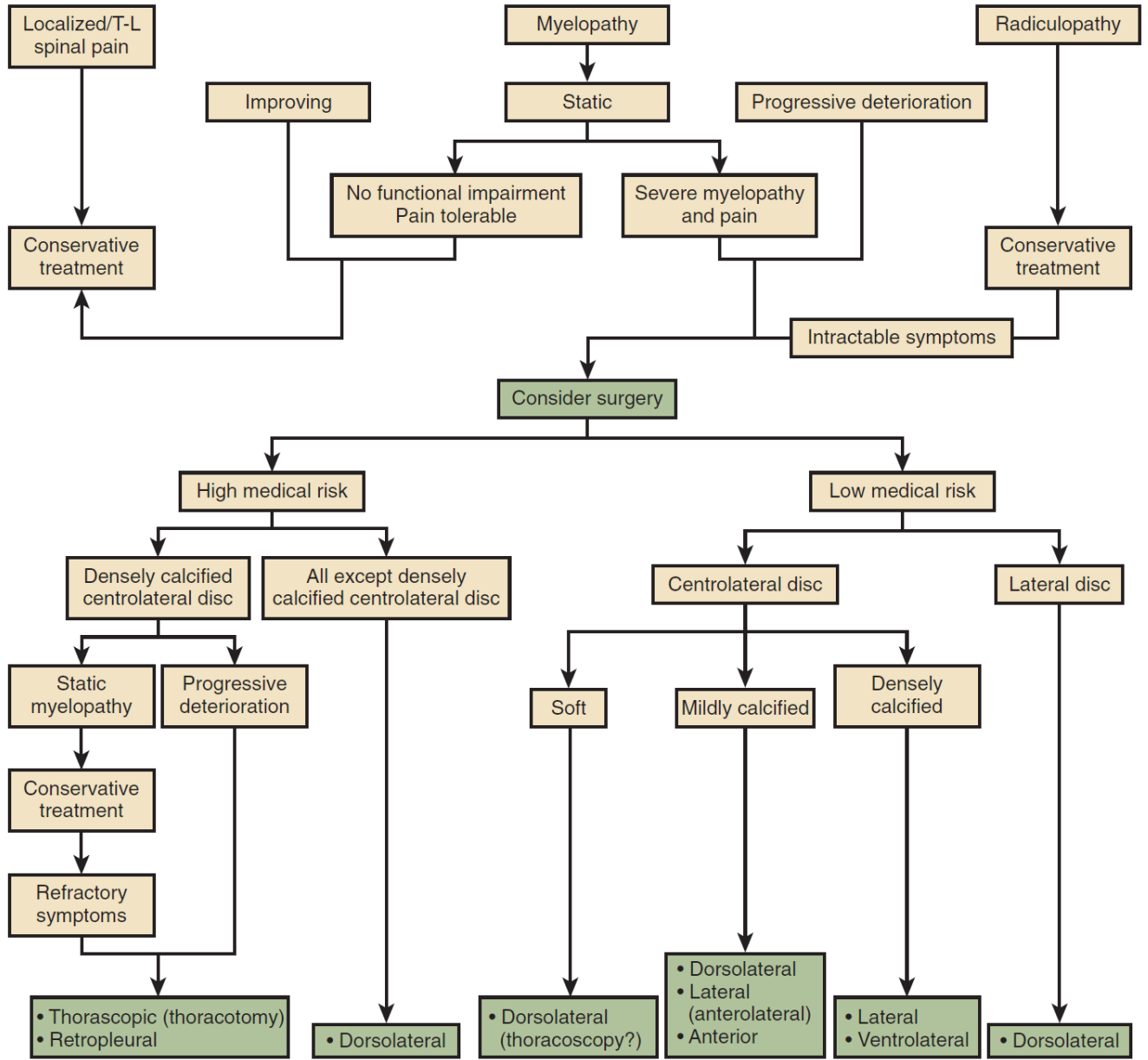
- a) **calcified (central) disk** - **anterior approach** (CT surgeon for approach with one lung ventilation).
- b) **soft herniated discs, lateral calcified discs** – **posterolateral approach** (transpedicular ÷ transthoracic approach, best **costotransversectomy**) – semiblind procedure!

By **nature of indications:**

- a) severe, intractable **back pain** - surgery has a high failure rate!
- b) severe, intractable **radicular pain** - dorsolateral approach (radiculopathy alone is generally associated with a far lateral disc)
- c) (progressive / severe) **myelopathy**

N.B. nonsevere static myelopathy without functional impairment → treat nonoperatively

By **patient condition: high-medical-risk patients** - dorsolateral decompression (unless disc is midline, large, and densely calcified)



LUMBAR INTERLAMINAR STABILIZATION (INTERSPINOUS SPACERS)

— for spinal stenosis with facet disease when fusion would be a consideration.

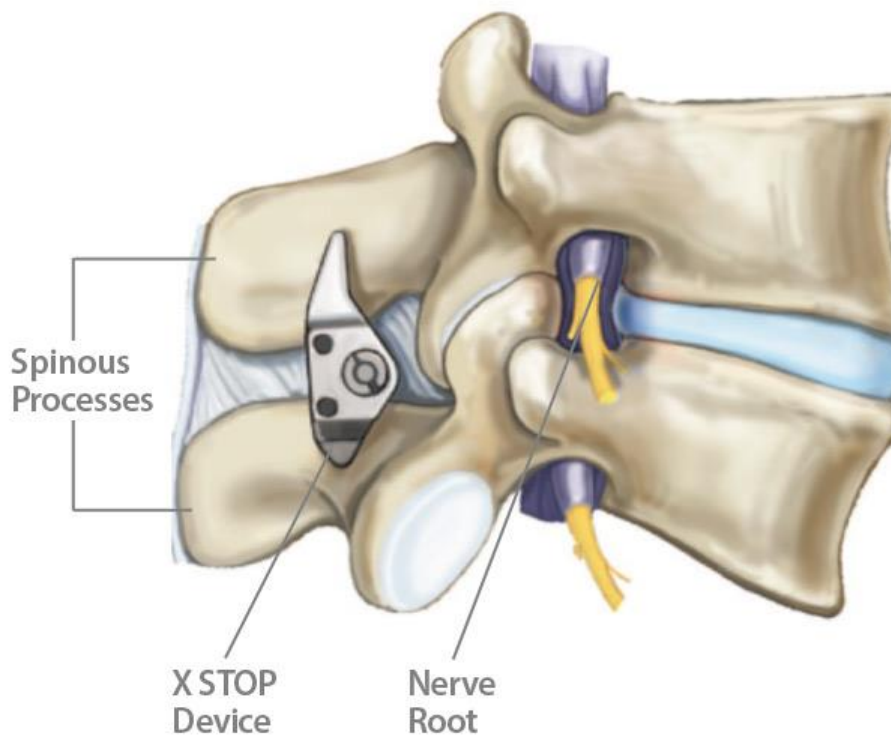
Contraindications: severe stenosis, advanced osteoporosis

MIST Consensus (2022): Interspinous spacers should be considered for mild-to-moderate spinal stenosis, with ≤ grade 1 spondylolistheses, in the absence of dynamic instability or micro-instability represented as fluid in the facets. Grade A; Level of certainty high; Quality of Evidence 1-A

In 2014, Wu et al published a systematic review and meta-analysis on dynamic interspinous spacers comparatively evaluated against traditional decompressive surgery:

- no difference between the interspinous spacers and decompression for **low back pain**;
- decompression cohort had a significantly lower incidence of **reoperation** (RR: 3.34; 95% CI: 1.77, 6.31; *P* = 0.60; I2 = 0%)
- **greater cost** for performing interspinous spacer technique vs open decompression

X-STOP





COFLEX

Paradigm Spine, LLC >> (surgical technique starts at page 28)

Dynamic stabilizer – good alternative to fusion!

- maintains foraminal height, offloads facets and posterior annulus – facetogenic back pain↓
- compressible in extension - physiological adjacent segment kinematics, maintains sagittal balance
- axial force shock absorption.



Official indication:

- use in one or two contiguous level lumbar stenosis from L1–L5* in skeletally mature patients with at least moderate impairment in function, who experience relief in flexion from their symptoms of leg/ buttocks/groin pain, who have undergone at least 6 months of non-operative treatment.
- performed after decompression (flavectomy) of stenosis at the affected level(s).

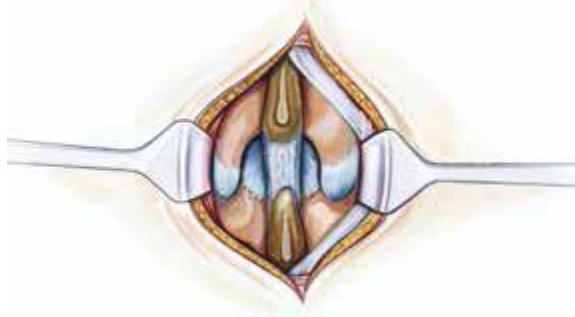
*S1 spinous process is unpredictable

Technique

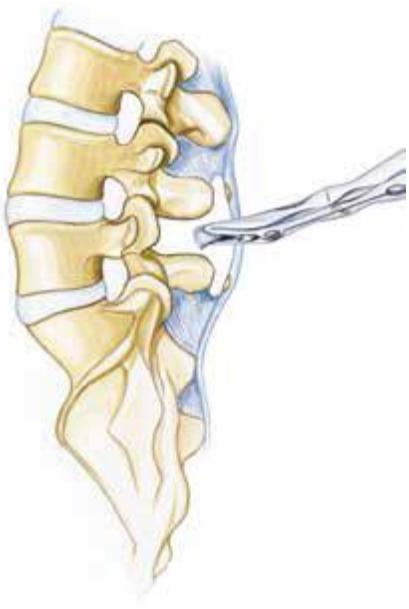- position patient neutral on the table (uncranked Wilson frame is OK).

The patient is placed in prone position on a surgical frame avoiding hyperlordosis of the spinal segment(s) to be operated on. For the surgical decompression as well as for appropriate interspinous distraction, a neutral position or a slight kyphosis may be advantageous

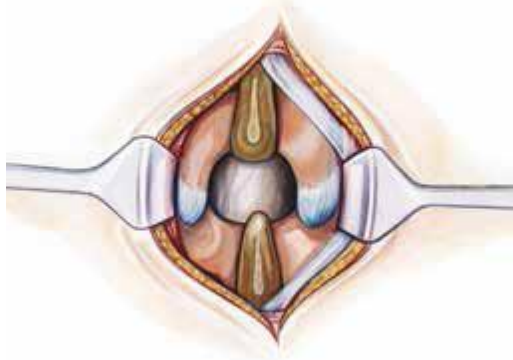
Paramedian or midline approach is taken with preservation of the supraspinous ligament. The muscle is sharply dissected lateral to the supraspinous ligament preserving the entire thickness of the supraspinous ligament



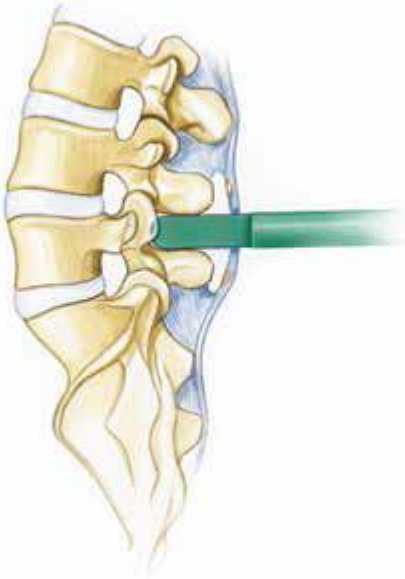
The basic surgical approach entails a midline incision and reflection of the supraspinous ligament. For a minimally invasive approach, this reflection of tissues extends to the base of the spinous process, which affords microsurgical access through the ligamentum flavum into the spinal canal. For an open approach, this reflection of tissues extends to the facet capsules affording total access to the entirety of the posterior elements. The interspinous ligament is sacrificed and any bony overgrowth of the spinous process that may interfere with insertion is resected.



Ligamentum flavum is resected and microsurgical decompression is performed, relieving all points of neural compression



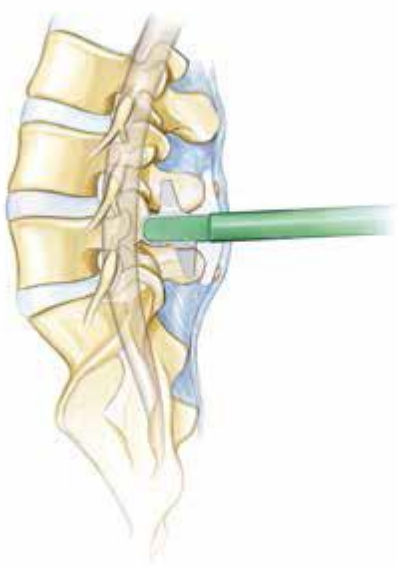The trial instrument is placed to evaluate proper contact with the spinous process and the amount of facet distraction. Some bony resection of the spinous process may be needed to ensure proper contact of the implant:








Prior to insertion, the wings may need to be opened slightly using the bending plier to ensure appropriate depth of insertion



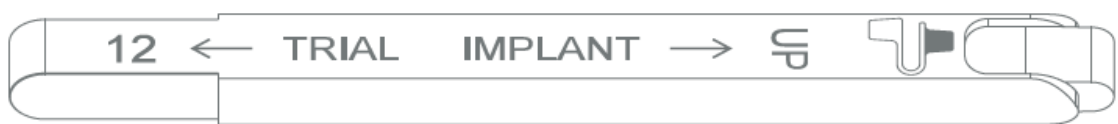The implant is introduced via impaction utilizing a mallet








Trials

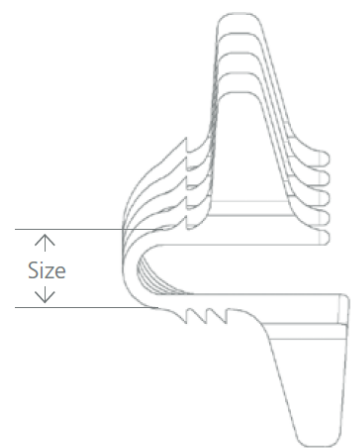
Color Code	Size	Article Number
	16mm	UBT10016
	14mm	UBT10014
	12mm	UBT10012
	10mm	UBT10010
	8mm	UBT10008

Material: Medical grade acetal copolymer



coflex® Implant

Color Code on Implant Box	Size	Article Number
	16mm	UQI00016
	14mm	UQI00014
	12mm	UQI00012
	10mm	UQI00010
	8mm	UQI00008

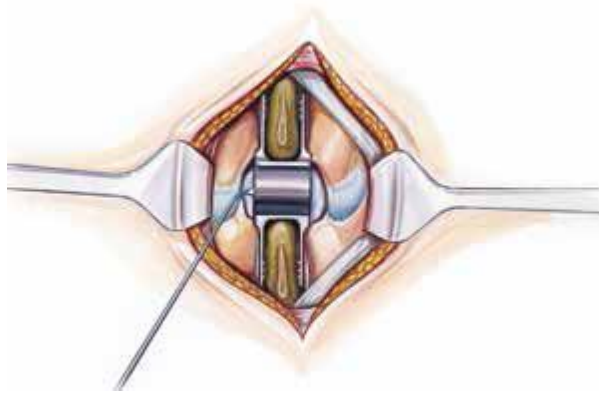


Material:
Wrought titanium 6-aluminium 4-vanadium alloy according to ISO 5832-3

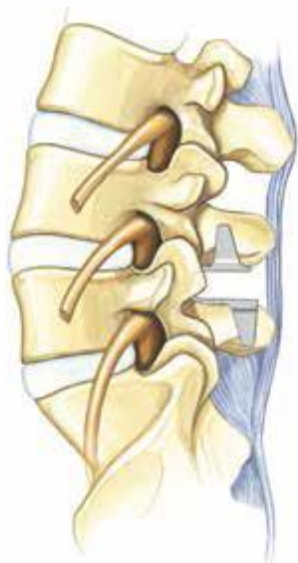
The *coflex*® implant is delivered in sterile packaging.

- can be implanted either way (i.e. upside down).
- trial should spread spinous processes only 1-2 mm apart.
- max. device height – 16 mm.
- must leave only 1-2 mm gap to dura; i.e. must be implanted rather anteriorly as most stress will be taken by laminar bone (and not spinous process) – wing must contact lamina (prevents anterior migration).

Proper depth is determined if a ball tip probe can be passed freely leaving 1–2mm separation from the dura



By deeply inserting the coflex® implant at the level of the facet joints, the implant counteracts the majority of posterior column forces (interlaminar positioning).



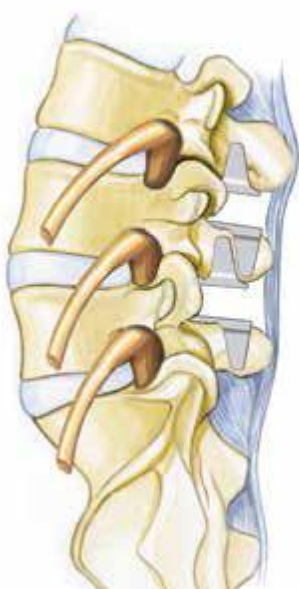
- after device is in situ, compress wings to achieve additional purchase.

Once proper placement has been achieved, it is recommended to securely crimp the wings of the implant using the crimping plier



In case of ligament reconstruction, the fascia and the supraspinous ligament can be closed in one layer over the spinous processes. A surgical drain may be placed as per surgeons' preference. Paraspinal muscles are reattached to the supraspinous ligament. Skin is closed in the usual manner

If a two level decompression is mandated, the Coflex® implants must be sequentially placed to the appropriate depth avoiding an overlap (contact) of one pair of wings upon the other. The Coflex® device is indicated for implantation at 2 contiguous levels



MILD (minimally invasive lumbar decompression) / PILD (percutaneous image-guided lumbar decompression)

- percutaneous removal of hypertrophied lumbar ligamentum flavum.

- PILD was developed in 2005.
- debulks posterior elements of the spine (lamina and LF).
- indication - mild-to-moderate LSS due to hypertrophied ligamentum flavum (HLF) of ≥ 2.5 mm within the lumbar spinal canal, contributing to 50% to 85% central canal narrowing.
- $>$ grade 2 spondylolisthesis is a relative contraindication.
- prior spine surgery at the index level is Absolute contraindication.
- performed percutaneously via a 5.1 mm port specifically designed for minimally invasive instruments used to debulk lamina and small portions of ligament.
- **epidurogram** to define the anterior border of LF to the use of bony anatomy.
- in contralateral oblique fluoroscopic view, a bone rongeur is used to perform selective laminotomies of superior and inferior lamina to gain access to the interlaminar space.
- this is followed by a tissue sculptor via the same trochar to debulk sections of the LF.
- when there is no longer material to debulk and the instrument falls into the space created by the decompression of lamina and ligament, then the procedure is complete.
- procedure can be performed unilaterally or bilaterally, and at multiple symptomatic levels through a single midline stab incision, and requires no general anesthesia, large incision, extensive surgical dissection, or surgical implants.
- risk profile is identical to that of an epidural injection.

ENCORE – PILD vs. ESI

- level 1 evidence - RCT involving over 300 patients randomized to PILD or ESI
- PILD to be statistically and significantly superior to ESI in NC central stenosis due to LFH at 1- and 2-year follow-up.
- PILD is as safe as ESI.

VERTOS MEDICAL

Nice video:

<https://www.youtube.com/watch?v=fE8BJMjMjM0>

LUMBAR LAMINECTOMY

INDICATIONS

- 1) spinal stenosis
- 2) contraindications (or medical comorbidities) for anterior approach
- 3) contraindications for general anesthesia for extended fusion because of increased cardiac risk

CONTRAINDICATIONS

1. **Herniated disk** - needs additional discectomy and foraminotomy.
Check preop radiculopathy!
2. **Pars defects** (congenital or acquired) - fusion is required to prevent dynamic instability and spondylolisthesis.

PLANNING

MRI – look for neural foraminal stenosis (→ discectomy and foraminotomy).

Before any laminectomy (esp. if spondylolisthesis is present) – do **flexion and extension XR** - dynamic instability? (→ lumbar fusion rather than laminectomy alone).

PROCEDURE

Medications, Positioning, Skin incision, Fascial and Subfascial and Subperiosteal Dissection, Closure - see "Posterior Midline Approach" >>

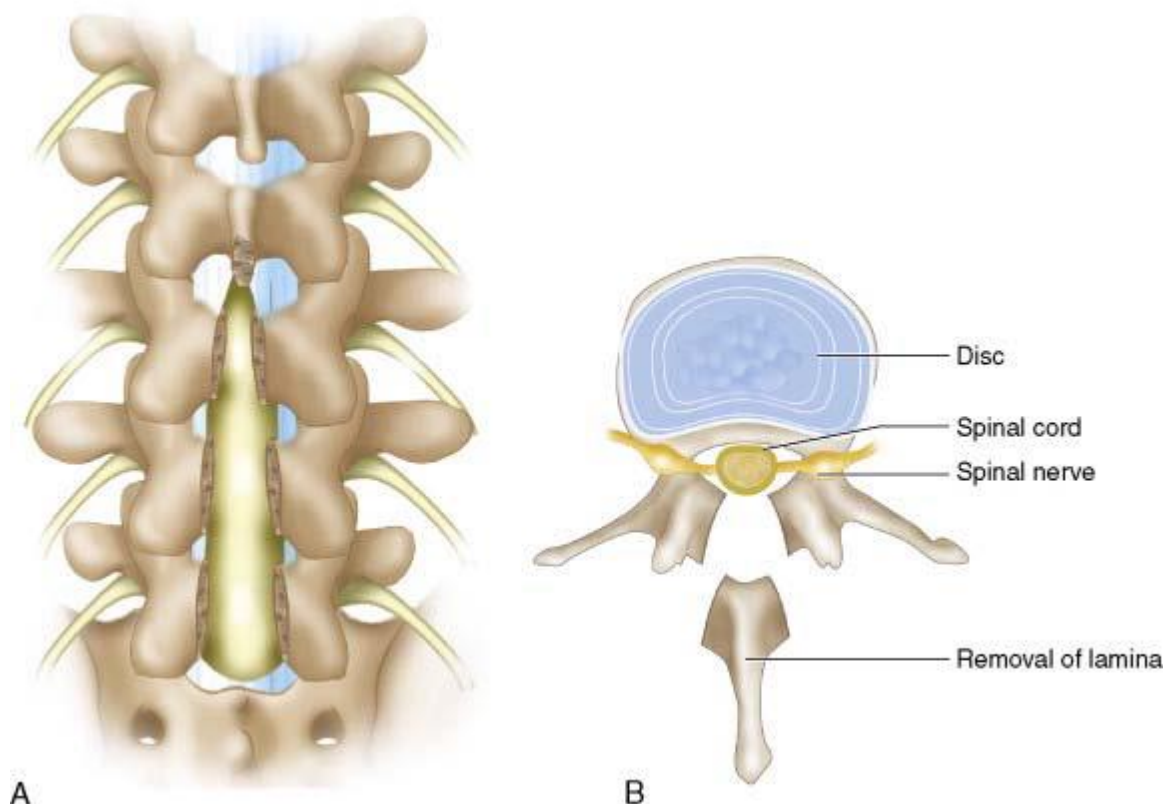
N.B. wide lumbar laminectomies becoming obsolete – aim for spinous process-sparing decompression! (preserves tension band – does not destabilize spine)

SPINOUS PROCESS REMOVAL

- when spinous process out to facet is dissected, bony dissection can begin.
- Horsley bone cutter and double-action rongeur can be used to remove spinous process.
- bone can be saved and used for posterolateral in situ fusion if needed.
- cortical bone at base of spinous process may bleed easily, and one should be prepared with **bone wax** (irrigation can be used to identify further bleeding sites); rather than attempting to place bone wax on bleeding lamina using Freer elevator, small ball of wax can be placed over bleeding site, and dry $\frac{1}{2} \times \frac{1}{2}$ cottonoid can be used with bayoneted pickup to compress and mold wax into bleeding sites.

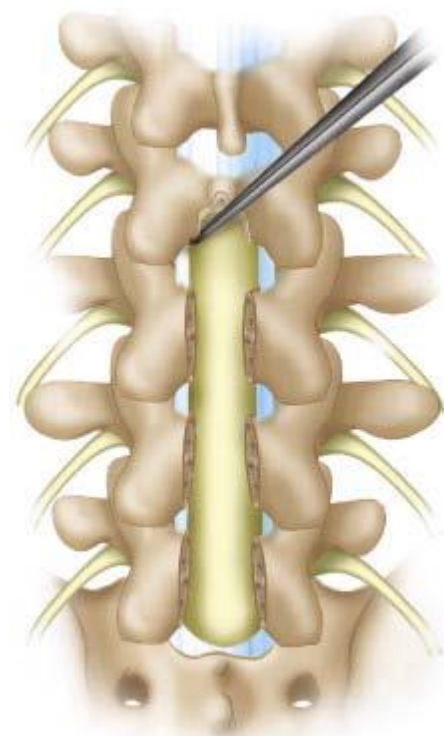
LAMINECTOMY

- when all spinous processes are removed for planned laminectomy, attention can be turned to completing laminectomy with high-speed drill or with various Kerrison rongeurs or (fastest and least bloody) with ultrasonic bone scalpel (e.g. Misonix).
- bone should be removed *from caudal to rostral* because top of lamina is close to dura and unprotected by ligamentum flavum (one may encounter dura easily in this location).



Source of picture: R. Jandial "Core Techniques in Operative Neurosurgery: Expert Consult - Online and Print", 1st ed (2011), Saunders; ISBN-13: 978-1437709070 >>

- 2-mm side-cutting drill can be used to thin remaining lamina and bone to identify yellow ligamentum flavum without violating dura (while drilling laterally, one can create trough to assist in subsequent completion of laminectomy).
- after thinning lamina sufficiently, 2- to 4-mm up-biting Kerrison rongeurs can be used to remove remaining bone exposing yellow ligamentum flavum.
- sharp right-angled instrument can be inserted into ligamentum flavum and used to pull dorsally away from thecal sac while cutting along instrument using No. 15 blade.
- most difficult and time-consuming part - *developing plane between dura and ligamentum flavum* (frequently hypertrophic and closely adherent to underlying dura – risk of durotomy).
- dissection is carefully continued until whitish blue thecal sac is identified. Careful removal of window of ligamentum flavum can be done with pituitary rongeur.
- after ligamentum flavum is removed, widen laminectomy to medial edge of pedicles.
N.B. thecal sac may be under pressure; to avoid CSF leak, small $\frac{1}{2} \times \frac{1}{2}$ cottonoid is advanced before each bite with Kerrison rongeur (Kerrison bites cottonoid rather than thecal sac).
- to avoid inadvertent CSF leaks from sharply angled bony spurs, bites with Kerrison rongeur should be kept continuous and overlapping.
- thecal sac should appear relaxed and more pliant on palpation after laminectomy.



Source of picture: R. Jandial "Core Techniques in Operative Neurosurgery: Expert Consult - Online and Print", 1st ed (2011), Saunders; ISBN-13: 978-1437709070 >>

- lateral gutters contain venous plexus that bleeds quite easily; hemostasis techniques:
 - a) place thrombin-soaked **Gelfoam** → use wet $\frac{1}{2} \times \frac{1}{2}$ cottonoid to impress Gelfoam in place; by irrigating on cottonoid and holding suction, Gelfoam shrinks and fits into desired dimensions.
 - b) place **Avitene Hemostat** over bleeding venous plexus → place dry $\frac{1}{2} \times \frac{1}{2}$ cottonoid over Avitene Hemostat, and bayonet forceps can be used to hold clot in place.
 - c) inject **hemostatic foam** (Surgiflo, Floseal)
 - d) use **bipolar** cautery

COMPLICATIONS

Adjacent segment disease (ASD) after lumbar laminectomies without fusion - **cumulative incidence of ASD requiring reoperation* is 10%** (for 1- and 2-level laminectomies) over a mean of 4 years.

*50% patients require fusion

LUMBAR MICRODISKECTOMY

Used literature:

R. Jandial “Core Techniques in Operative Neurosurgery” (2011)

NASS Clinical Guidelines for Lumbar Disc Herniation with Radiculopathy (2012)

DISCECTOMY - one of most commonly performed elective operations in USA (many performed in outpatient setting).

TRIALS

Surgery vs. conservative management (Norwegian study)

- class of evidence III
- statistically significant **benefit of surgery** at 1 year (p = 0.0015).
- beyond 4 years, although there was a trend towards benefit, the difference was not statistically significant.

1 year outcomes	Conservative Management	Surgery	Statistical significance
Good	36%	65%	p = 0.0015
Fair	42%	27%	
Poor	20%	8%	
Bad	2%	0%	

Weber H. Lumbar disc herniation. A controlled, prospective study with ten years of observation. *Spine* 1983 ; 8 : 131 – 140 .

SPORT trial: surgery vs. conservative management (US study)

- class of evidence II
- statistically significant **improvement of Sciatica Bothersness Index (SBI) in the surgery group** at 1 year (p = 0.003).
- benefit from both surgery and conservative management but **no conclusions regarding the superiority of either** can be made on an intention-to-treat analysis (N.B. significant cross-over between groups with: 40% of the surgical group; 45% of the conservative group).

Outcomes (12 months)	Surgery	Conservative management	Statistical significance
Pain (SF-36)	39.7	36.9	None
Physical function(SF-36)	36.4	35.2	None
ODI	-30.6	-27.4	None

Weinstein JN et al. Surgical vs nonoperative treatment of lumbar disk herniation: the spine patient outcomes research trial (SPORT): a randomised trial. *JAMA* 2006; 296 : 2441 – 2450 .

Early surgery vs. conservative management (Netherlands study)

- class of evidence II
- surgery was performed within 2 weeks of randomization.
- surgery offers **faster recovery** but **no long term benefits** (benefit of early surgery ceased to be statistically significant by 6 months).

	Surgery	Conservative management
Median time to recovery	4.0 weeks (95% CI, 3.7 to 4.3)	12.11 weeks (95% CI, 9.5 to 14.8)

Peul WC et al. for the Leiden – The Hague Spine Intervention Prognostic Study Group. Prolonged conservative care versus early surgery in patients with sciatica caused by lumbar disc herniation: two year results of a randomised controlled trial. *BMJ* 2008; 336 : 1355 – 1358

NASS Clinical Guidelines for Lumbar Disc Herniation with Radiculopathy (2012):

Discectomy is **suggested** to provide **more effective symptom relief (up to 4 years)** than medical/interventional care for lumbar disc herniation with radiculopathy whose symptoms warrant surgical intervention. Surgical symptom relief is **long-term (> 4 years)** but a substantial portion (**23-28%**) of patients will have chronic back or leg pain.

In less severe symptoms, surgery or medical/interventional care appear to be effective for both short- and long-term relief.

INDICATIONS

Clear indications for surgery:

- 1) **cauda equina** or **conus medullaris** syndrome → emergency surgery!
- 2) acute or progressive **myelopathy**
- 3) severe or progressive neurologic (esp. **motor**) deficits.
- 4) intractable **pain**.

Additional indication - **unsatisfactory response** within 4-12 weeks of conservative measures.

How urgent surgery must be?

- decision to operate emergently is often based on fear of legal repercussions rather than on scientific evidence.
- ensure completeness of **diagnostic workup** prior to operation (all surgeons can recall several cases in which diabetic plexopathy or epidural metastasis was missed).

NASS Clinical Guidelines for Lumbar Disc Herniation with Radiculopathy (2012):

preoperative assessment for **signs of psychological distress** (somatization, depression) is suggested - patients with signs of psychological distress have **worse outcomes** (Grade of Recommendation: B); **positive straight leg raise test** correlates with **better outcomes** (Grade of Recommendation: B).

Surgical intervention prior to 6 months is suggested for lumbar disc herniation severe enough to warrant surgery. **Earlier surgery (within six months to one year)** is associated with **faster recovery** and **improved long-term outcomes**.

There is **insufficient evidence** for or against **urgent surgery** for **motor deficits** due to lumbar disc herniation with radiculopathy

Recovery of ankle dorsiflexion weakness

- patients treated with surgical decompression at various intervals [urgent (< 10 days), expeditious (<30 days) and routine (> 30 days)].
- outcomes assessed at 24 months
- ankle dorsiflexion power at the long-term follow-up significantly correlated with the preoperative ankle dorsiflexion power (p < 0.001).
- level IV therapeutic evidence that **timing of surgery does not affect recovery of ankle dorsiflexion**.

Mangialardi R et al. Lumbar disc herniation and cauda equina syndrome. Considerations on a pathology with different clinical manifestations. *Chir Organi Mov.* Jan-Mar 2002;87(1):35-42

1. The **natural history** of sciatica due to lumbar disc herniation: **the majority of patients improve significantly** within 8 weeks!
2. **Surgery provides a faster relief** from the acute attack than conservative management (Gibson and Waddell, 2007).
3. There is **no overall difference in the longer-term outcomes** between surgery and conservative management.
4. **Risks of surgery need to be balanced** against the risks of conservative management – **no winner**:
Surgical risks - 1 % risk of neurological damage.
Risks of conservative management - have not been quantified and may include further neurological deterioration and the development of cauda equina syndrome.
5. Strong economic argument supporting **rationale for early surgical intervention** based on a **cost–benefit analysis** (cost of surgery vs. cost of lost productivity for the longer recovery in patients managed conservatively)

Van den Hout WB et al. for the Leiden – The Hague Spine Intervention Prognostic Study Group. Prolonged conservative care versus early surgery in patients with sciatica from lumbar disc herniation: cost utility analysis alongside a randomised controlled trial. B MJ 2008; 336 : 1351 – 1354

Nerve root decompression principles:

True hernia → discectomy.

Annular bulge or prolapse → medial facetectomy (lateral recess decompression) without discectomy.

CONTRAINDICATIONS

- 1) **unrelenting back pain** after bout of sciatica has resolved (discectomy results are not good).
- 2) patient **not provided adequate conservative treatment** (e.g. short period of sciatica without bedrest and steroid trial).

PLANNING

MRI – look for level of neural foraminal stenosis; **make sure MRI is recent!!!**

Flexion and extension XR - dynamic instability? (→ lumbar fusion rather than discectomy alone*).
 *discectomy will treat radiculopathic pain but would be unable to treat mechanical back pain

PROCEDURE

POSTERIOR APPROACH

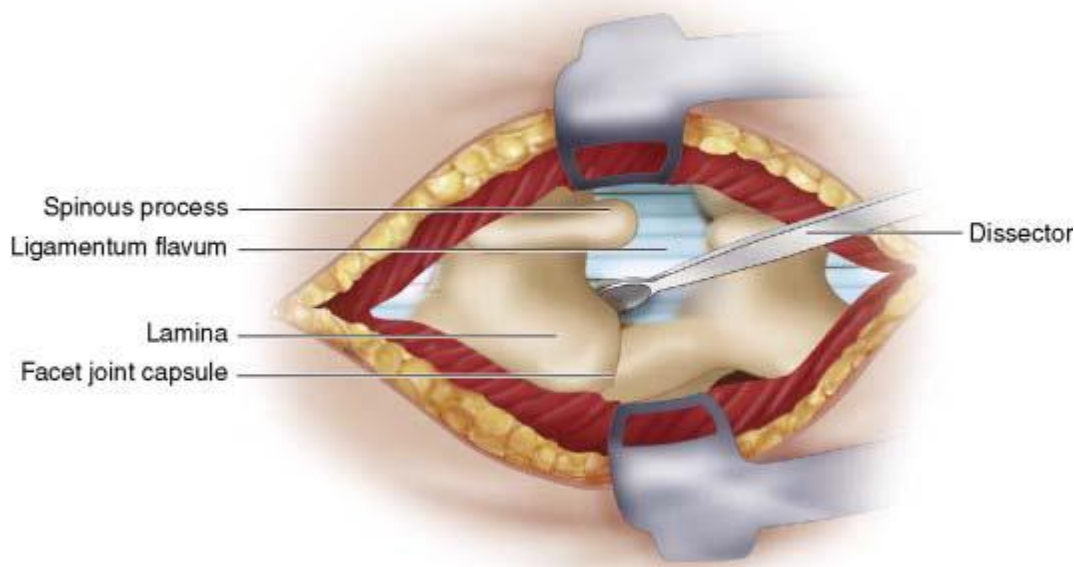
Medications, Positioning, Skin incision, Fascial and Subfascial and Subperiosteal Dissection, Closure - see “Posterior Midline Approach” >>

Large central disk herniation - **full laminectomy** is indicated.

- in stenotic canal it is prudent to decompress widely prior to manipulating dural sac to facilitate discectomy.
- fascial incision is **paramedian** to ensure midline ligamentous structures are not damaged by dissection.
- Williams, Caspar, or similar retractor.
- for **morbidly obese** patients use Taylor retractor; also consider open spine table (to accommodate stomach) or lateral decubitus position (if a patient has significant respiratory compromise).
- localizing imaging – lateral XR:
 - 1) two 18G needles on skin – for incision planning
 - 2) Penfield #4 under lamina – to verify level
 - 3) Penfield #4 in disc space (**Dr. Broadus**) – to document correct discectomy.

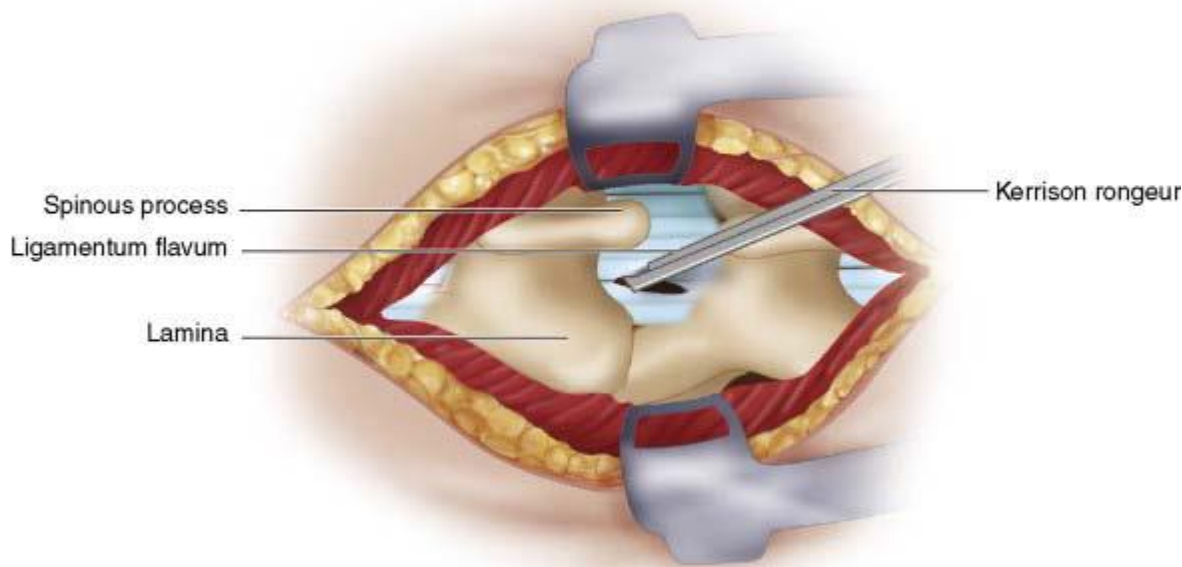
REMOVAL OF LIGAMENTUM FLAVUM

- find soft interspace between two laminae of interest.

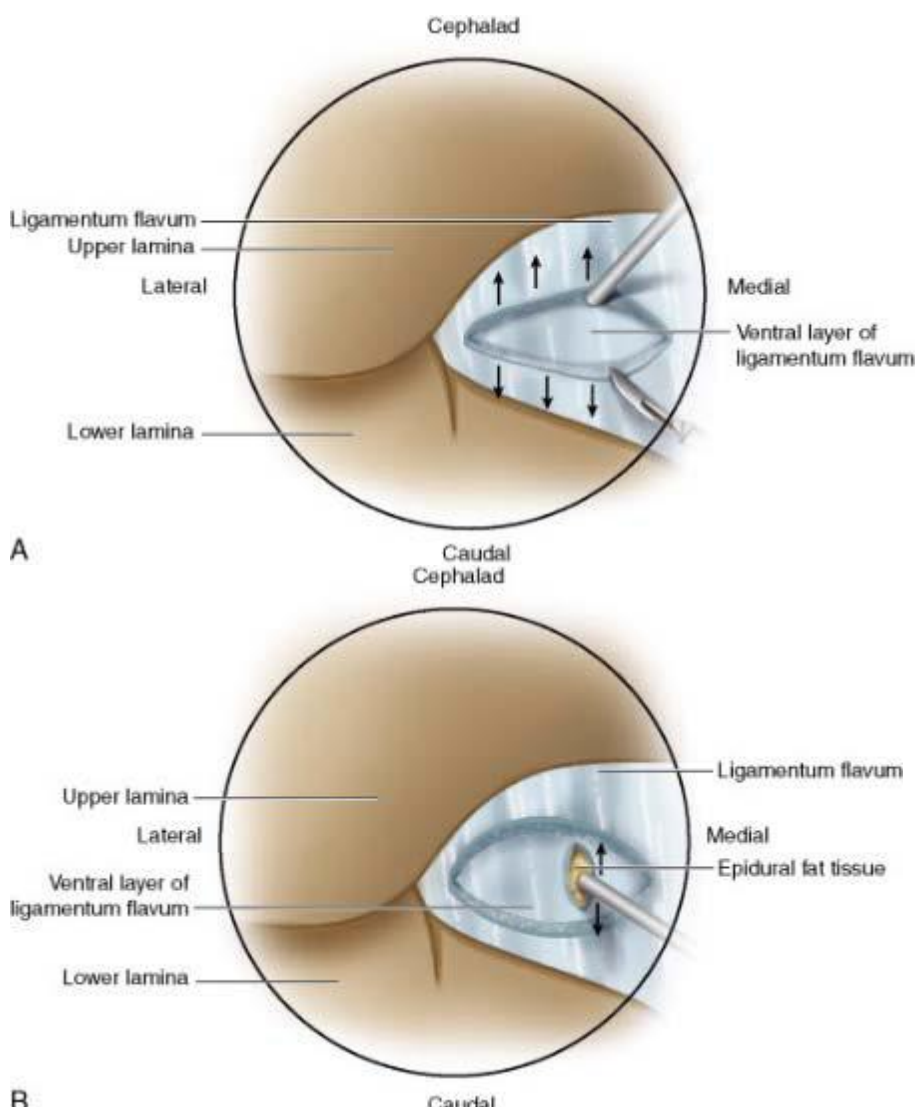


Source of picture: R. Jandial “Core Techniques in Operative Neurosurgery: Expert Consult - Online and Print”, 1st ed (2011), Saunders; ISBN-13: 978-1437709070 >>

- sharp right-angled instrument can be inserted into ligamentum flavum and used to pull dorsally away from thecal sac while cutting along instrument using No. 15 blade.
- dissection is continued until whitish blue thecal sac is identified.
- removal of window of ligamentum flavum can be done with pituitary rongeur.
- rest of ligamentum flavum is removed with Kerrison rongeurs to create largest working window possible.



Source of picture: R. Jandial "Core Techniques in Operative Neurosurgery: Expert Consult - Online and Print", 1st ed (2011), Saunders; ISBN-13: 978-1437709070 >>



Source of picture: R. Jandial "Core Techniques in Operative Neurosurgery: Expert Consult - Online and Print", 1st ed (2011), Saunders; ISBN-13: 978-1437709070 >>

Williams described minimalistic approach – no bone removal, just window in ligamentum flavum (but need excessive nerve root retraction).

N.B. **injured ligament flavum is a source for epidural scar**, thus – either completely remove it* (preferred) or just make small window leaving inner smooth surface of ligamentum flavum intact

*with angled curettes, ligament removal from the undersurface of the remaining rostral lamina should be thorough

INFERIOR HEMILAMINOTOMY

- standard for **posterolateral herniation** (unilateral radiculopathy).
- remove **portions of lamina** with drill or rongeurs (to gain entrance into lateral aspect of spinal canal).
- operating **microscope** may now be used.

NASS Clinical Guidelines for Lumbar Disc Herniation with Radiculopathy (2012): operative microscope is suggested to obtain **comparable outcomes** to open discectomy.

N.B. remove enough bone to avoid excessive nerve root retraction but also beware of weakening pars!

- **medial facet** is partially resected in most patients (but structural integrity of facet should be preserved!); do not resect > 50% of **pars interarticularis** bone.

NASS Clinical Guidelines for Lumbar Disc Herniation with Radiculopathy (2012): *insufficient evidence* for or against medial facetectomy to improve the outcomes.

If needed, perform **HEMILAMINECTOMY**:

- quickly thin bone (e.g. drill or Leksell) past cortical bone in lamina to cancellous bone on other side; up-going curet can be used to remove remaining bone.
- semicircular or square laminectomy can be completed with 1- to 3-mm Kerrison rongeurs and up-going curet.

Dr. Cameron likes to remove top of S1 lamina when operating on L5-S1 disc space.

LAMINECTOMY

- for **central herniation** (additional indications - large herniations, free disc fragment).

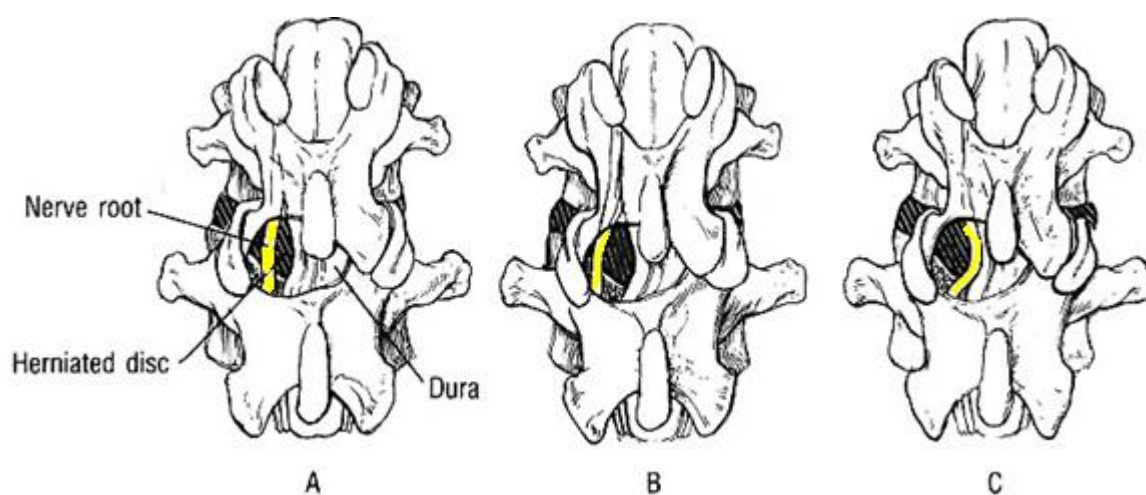
NERVE ROOT MOBILIZATION

- experts recommend **preserving epidural fat** (tuck it away with patty for the duration of discectomy then fat can be moved back into a protective position)
- make sure there are no ventral adhesions between the disk and the root
- obstacles to root mobilization:
 - 1) **conjoined nerve roots** - if the conjoined root is large and pulled or pushed tightly into the lateral recess by the disc pathology, it can be mistaken for hernia itself. see p. D70 >>
 - 2) **low root origins** - results in a lateral course over the disc space (impossible to safely mobilize root to access the disc)
 - 3) interradicular anastomoses

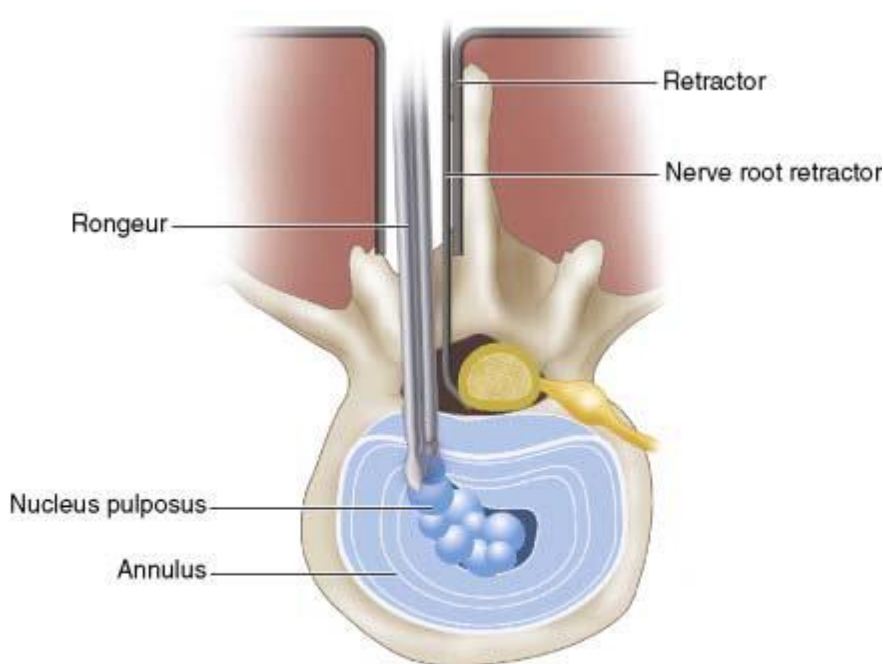
DISCECTOMY

- adequate, countertension-free traction is achieved with nerve root retractor (in redo cases, nerve root can be tethered distally, thus, retraction can tear dura at axilla)
 - N.B. can place small patties inferiorly and superiorly into gutter – keeps dura pushed away from bone!
- retract affected root **medially*** and **expose disc herniation** immediately anterior to it.
 - *if hernia is present in axilla between nerve root and adjacent dura, root must be retracted **laterally**.

Disk hernia impinging on root from directly anteriorly (A), medially (B), and laterally (C):



- coagulate with bipolar epidural veins.
- single* *transverse incision* is made in annulus with No. 15 blade in medial to lateral direction (to direct sharp end of blade away from dura).
 - *don't cut *window* in anulus – will ease reherniation postop; *Dr. Graham* makes cut vertically
- pituitary rongeur is used to remove disk material:
 - a) if there is free epidural fragment – remove it (sequestrectomy) and don't do discectomy at all
 - b) if there is only disk bulge – remove only free nucleus pulposus fragments (don't rip all possible disk material)
 - c) some experts do formal discectomy, esp. for young people (they have higher rate of recurrences; plus, left nucleus pulposus sets inflammatory reaction – severe postop pain).
- down-going Epstein curet or right-angled Williams instrument can be used to push down paracentral disk material into now decompressed disk space.



Source of picture: R. Jandial "Core Techniques in Operative Neurosurgery: Expert Consult - Online and Print", 1st ed (2011), Saunders; ISBN-13: 978-1437709070 >>>

- with *angled instrument* *explore nerve root* thoroughly along its course to ensure that it is adequately decompressed.
 - if osteophytes compromise neural foramen → FORAMINOTOMY (resection of anterior and medial segments of facet).
 - *intraoperative sonography* may help locate disk fragments / osteophytes located anterior to dura or nerve root.
- always *take a picture* of removed disc material and show to the patient – many feel better when they see "what was sitting on their nerve"

AGGRESSIVE DISCECTOMY VS. CONSERVATIVE DISCECTOMY (S. SEQUESTRECTOMY)

- controversial.

General Trend: more aggressive discectomy – less recurrences but more back pain.

NASS Clinical Guidelines for Lumbar Disc Herniation with Radiculopathy (2012): when surgery is indicated, either sequestrectomy or aggressive discectomy is **recommended** since there is **no difference in rates of reherniation** (Grade of Recommendation: B); *insufficient evidence* for or against aggressive discectomy vs. sequestrectomy for the avoidance of chronic low back pain.

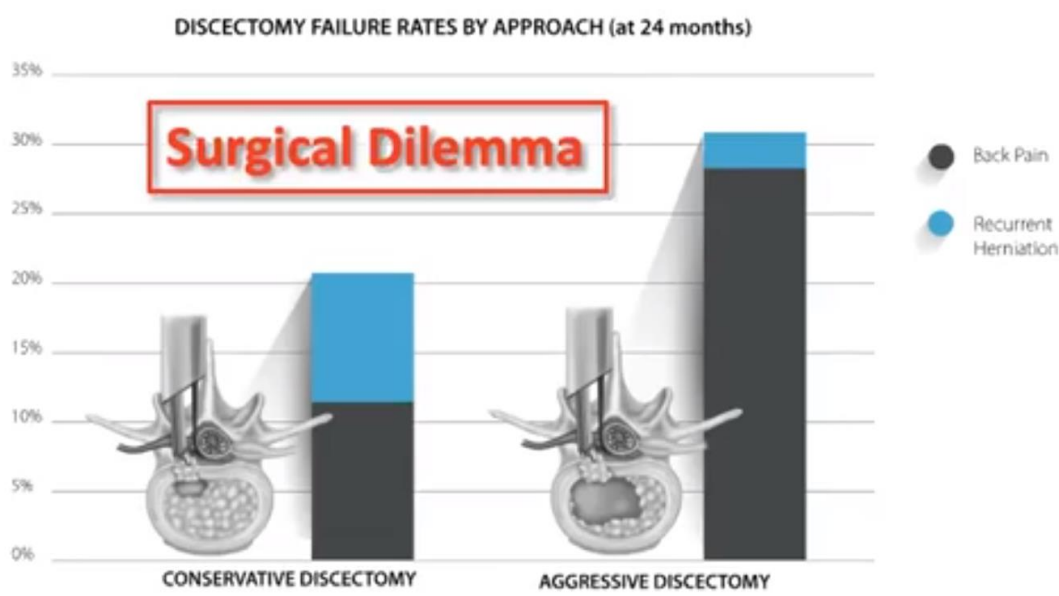
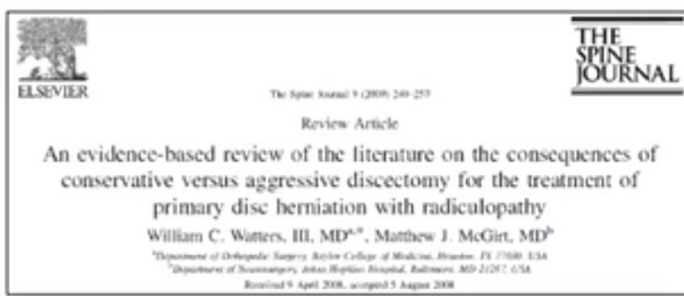Aggressive discectomy vs. Sequestrectomy

- there was 2-week return to work and 1-month accelerated with conservative discectomy.

	Sequestrectomy	Aggressive discectomy
Technique	surgeon removes only herniated disk fragment	large incision is made on posterior longitudinal ligament with aggressive removal of disk fragments and curettage of disk space
Mean operative time and hospital stay	shorter	longer
Recurrence rate*	12.5%	10%
Persistent back or leg pain	less	more
Return to full-capacity work	accelerated	slower
Post-operative disc degeneration and end-plate changes on MRI**	less	
Overall outcome over time (≥ 2 years)*	better (p = 0.029)	

*Barth M et al. Two-year outcome after lumbar microdiscectomy versus microscopic sequestrectomy: part1: evaluation of clinical outcome. Spine 2008; 33 : 265 – 272

**Barth M et al. Two-year outcome after lumbar microdiscectomy versus microscopic sequestrectomy: part 2: radiographic evaluation and correlation with clinical outcome. Spine 2008; 33 : 273 – 279



LOCAL STEROIDS

- some experts apply 40 mg of **DEPOMEDROL** solution on the nerve root (after finished irrigation, right before closure); others believe that it increases the risk of delayed CSF leak. N.B. DepoMedrol (methylprednisolone) FDA labeling states that it is *not approved for epidural application*; thus, for epidural injections, interventional pain specialists switched to dexamethasone!
- Level I therapeutic evidence that application of steroids (vs. saline) on a collagen sponge to the decompressed nerve root results in **short-term (14 day) improvement in back pain**, but not leg pain. *Debi R et al. Local application of steroids following lumbar discectomy. J Spinal Disord Tech. Aug 2002;15(4):273-276*
- Level II therapeutic evidence that addition of steroid and fentanyl sponge (vs. nothing) to the nerve root **does not appear to improve outcomes** with regard to VAS or work status. *Masopust V et al. Postoperative epidural fibrosis. Clin J Pain. 2009 Sep;25(7):600-606*

NASS Clinical Guidelines for Lumbar Disc Herniation with Radiculopathy (2012): insufficient evidence for or against the application of **glucocorticoids**, with or without **fentanyl**, for **short-term** perioperative pain relief following decompression; application of **glucocorticoids**, with or without fentanyl, is **not suggested** to provide **long-term relief** of symptoms following decompression.

FAT GRAFT

- to reduce the degree of dural scarring.

NASS Clinical Guidelines for Lumbar Disc Herniation with Radiculopathy (2012): insufficient evidence for or against application of a **fat graft** following open discectomy.

STABILIZATION

- stabilization **role is very unclear** (increasing number of patients are having fusions).

- a) **rigid fusion**; modern trend - **INTERBODY FUSION**
- b) **ARTIFICIAL DISC implantation**

NASS Clinical Guidelines for Lumbar Disc Herniation with Radiculopathy (2012): insufficient evidence for or against **fusion** for specific patient populations with lumbar disc herniation with radiculopathy whose symptoms warrant surgery.

- the best available evidence suggests that outcomes are equivalent whether or not a fusion is performed.

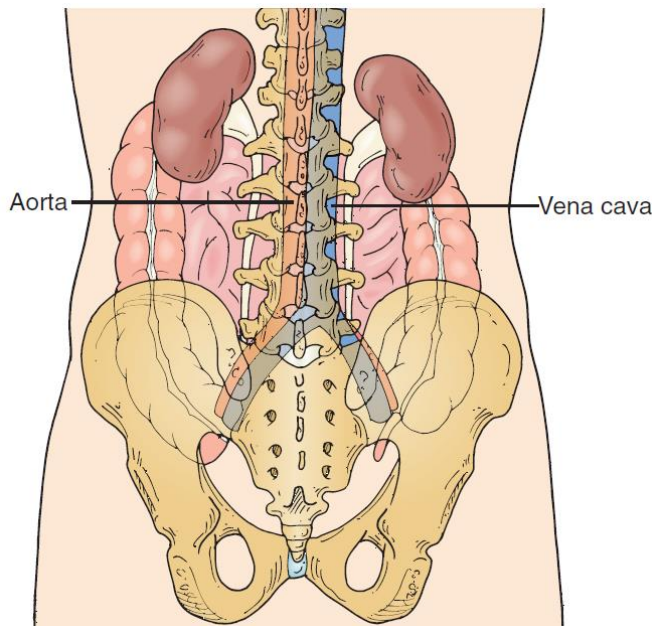
TIPS FROM MASTERS

- use straight cupped curet to remove soft tissue to find yellow ligament between two laminae. When ligament is visible, resist temptation to dissect away under inferior aspect of superior lamina in field because this would cause bleeding and ultimately interfere with hemilaminectomy. Using 2-mm side-cutting “matchstick” bur or 3-mm acorn drill bit, drill medially to laterally (from intersection of lamina and spinous process in lateral direction toward facet joint). Do not drill too far laterally because entering facet capsule can destabilize joint and cause facet joint pain. Do not drill too far rostrally because this can create pars defect leading to instability. Operating on levels with associated spondylolisthesis may require upfront fusion.

INTRAOPERATIVE COMPLICATIONS

1. **Durotomy** (risk ≈ 3-5%) – aim to repair primarily
2. Very rarely, anterior annulus is violated and **retroperitoneal vessel is injured** (left common iliac artery crosses directly over L4-5 disc) → **close back** while vascular surgeon prepares to repair vessel via LAPAROTOMY (if patient is stable, may go to IR instead).

“No guilt or chagrin should result from a negative retroperitoneal exploration when one suspects a vascular injury has occurred.”



POSTOPERATIVE COMPLICATIONS

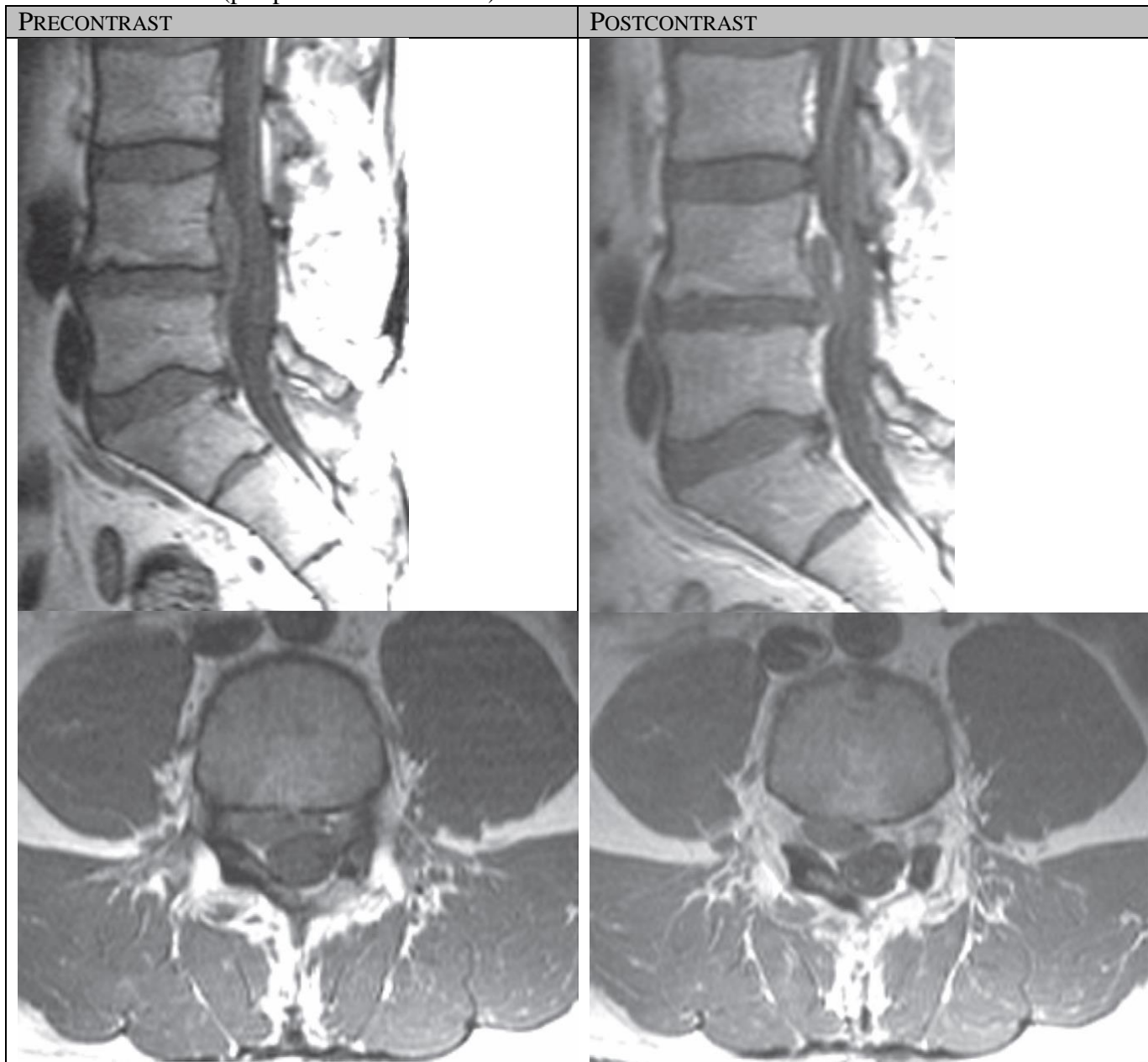
Overall complication rate is 2-4%

1. **Postoperative discitis** (fevers, severe localized pain, recurrent symptoms).
 - disc space is avascular and, as a result, less resistant to infection.
 - many patients experience **transient radiculopathy flare up at 2 weeks postop** (likely due to inflammation).
 - ESR↑, CRP↑, MRI w/wo, blood culture, CT-guided biopsy (if liquid pus obtained → surgical disk washout) → abx for 6 weeks + immobilization
2. **Disk recurrence** (≈ 15% of lumbar discs).
3. **Postoperative scar** (epidural granulations → mature fibrous tissue) - **extradural** reactive process; may cause recurrent symptoms - imaging studies show prevalence & severity entirely similar in pain-free patients.
 - lumbar epidural fibrosis (scar) is replacement of normal epidural fat with postoperative fibrotic tissue, which is capable of binding dura and nerve roots to surrounding structures anteriorly and posteriorly.

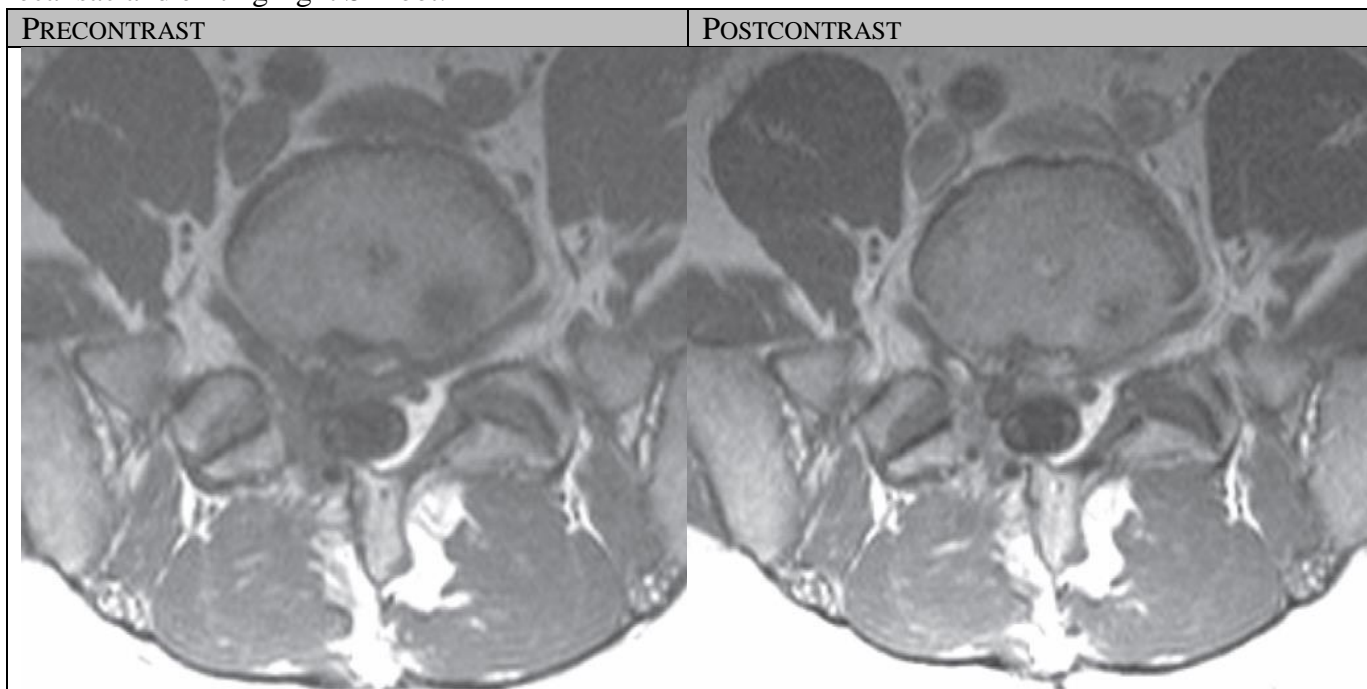
N.B. distinguish from **recurrent / residual disc material** (**MRI w contrast** is best – accuracy 96-100%) - firm indication for re-operation!!!

Scar enhances consistently regardless of time since surgery.
 Disc material does not enhance (or has peripheral enhancement) owing to its lack of vascularity.

Recurrent herniation (peripheral enhancement):

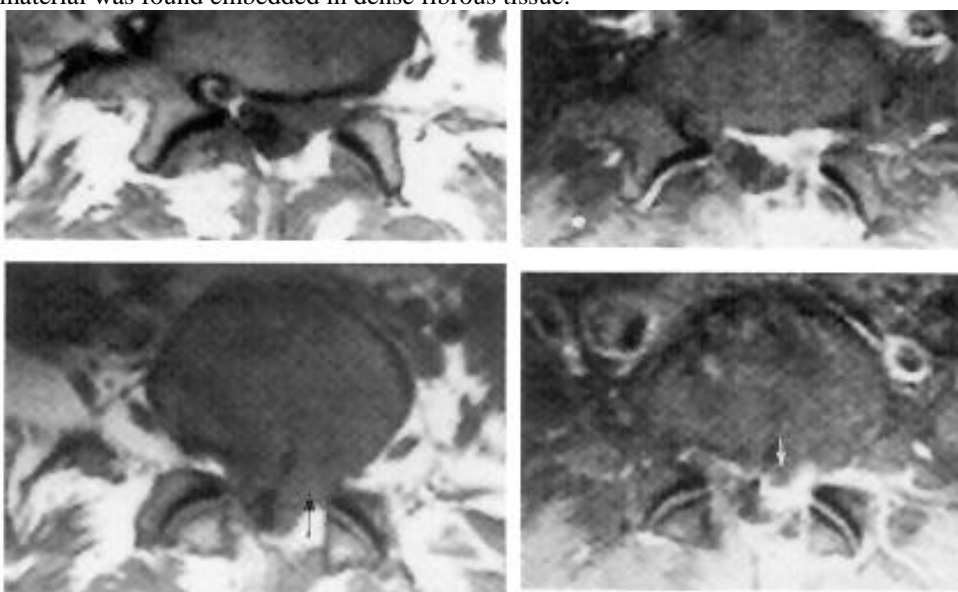


Postoperative epidural scar - diffuse enhancement of scar tissue surrounding right lateral aspect of thecal sac and exiting right S1 root:



Epidural scar & residual/recurrent disc protrusion:

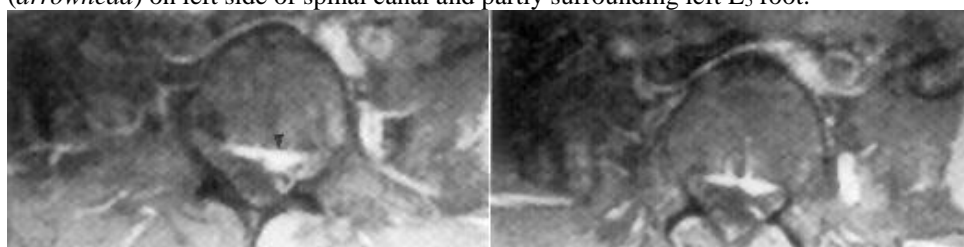
- A. T1-MRI just below (*above*) and through (*below*) L4-5 disc - large epidural mass (*black arrow*) on left side.
- B. T1-MRI at similar levels after IV gadolinium + fat presaturation - marked enhancement of most of epidural mass (scar), but also central non-enhancing region in contact with disc margin (*white arrow*); at re-operation, recurrent disc material was found embedded in dense fibrous tissue.



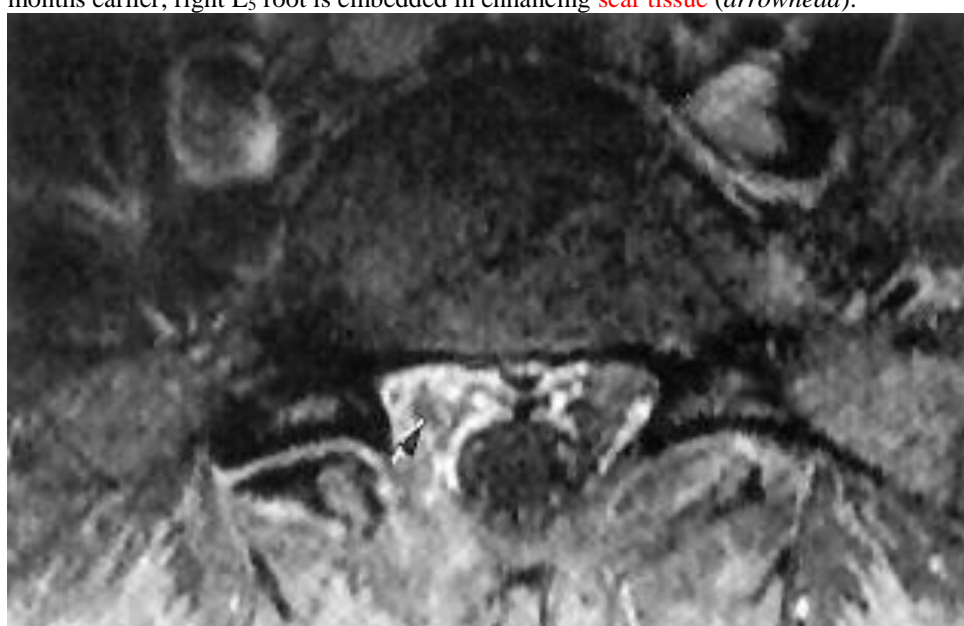A

B

Postoperative epidural scar: T1-MRIs just below L₄₋₅ disc (fat presaturation, IV gadolinium) - enhancing scar tissue (*arrowhead*) on left side of spinal canal and partly surrounding left L₅ root:



T1-MRI just below L₅-S₁ disc (fat presaturation, IV gadolinium) – patient had had right partial hemilaminectomy 18 months earlier; right L₅ root is embedded in enhancing **scar tissue** (*arrowhead*):



4. **Pseudo-meningoceles** (dura breached during surgery) - *not* of clinical relevance; distinguish from **abscess** (no communication with thecal space).
5. **Lumbosacral adhesive arachnoiditis** (**intradural** reactive process) - cause for **failed lumbar disc surgery** - occurs in only 3%; markedly diminished since abandonment of preoperative myelography using *oil-based iophendylate* (Myodil, Pantopaque).
 - may be **confined** to operation site or be more **generalized**.
 - arachnoiditis is *detected* with similar sensitivity by both MRI and water-soluble myelography.
6. **Vertebral instability** → **spondylolisthesis** H: fusion.

POSTOPERATIVE REGIMEN

- oral narcotics and IV supplementation for pain.
- **mobilized** 4-6 hours after surgery; should be able to void without help.
- once patient tolerates fluids, he may **leave hospital** with ample supply of narcotics, antispasmodics, and stool softeners (rarely, patient may remain in hospital for 2-5 days).
- **prevention of recurrence:**
 1. Avoidance of certain activities (bending or twisting at waist frequently, lifting heavy objects) for 6 weeks.
 2. Low back exercises in long term.

FOLLOW UP

- 1st **follow-up** – 6 weeks after surgery (for uncomplicated cases, patient is then released from surgeon's care).
- **return to work** after 3-10 weeks of recuperation at home.

IMAGING POSTOP

- typically not needed for routine F/U.

CT

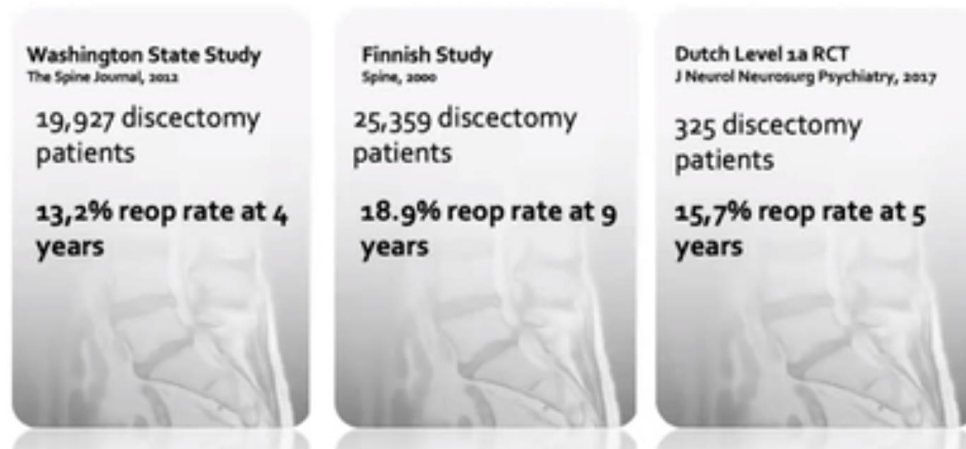- not useful *soon after surgery* - edema and blood eliminate soft-tissue contrast within spinal canal.
- *after few weeks* - **scar tissue** (CT attenuation similar to dura mater) is seen; molded to shape of theca which also may be drawn towards it (vs. recurrent disc material indents and displaces dura away).

MRI

- MRI is preferable for postoperative lumbar spine evaluation (determining cause of “failed back”) - **gadolinium-enhanced images with fat signal suppression** reliably distinguish **recurrent / residual disc material** (lack of enhancement) from **epidural scar** (strongly enhances).
 - scar enhancement diminishes over 2 years, but persists for many years.
- signal change in **damaged spinal cord** usually regresses when functional outcome is good, but persists when it is poor.

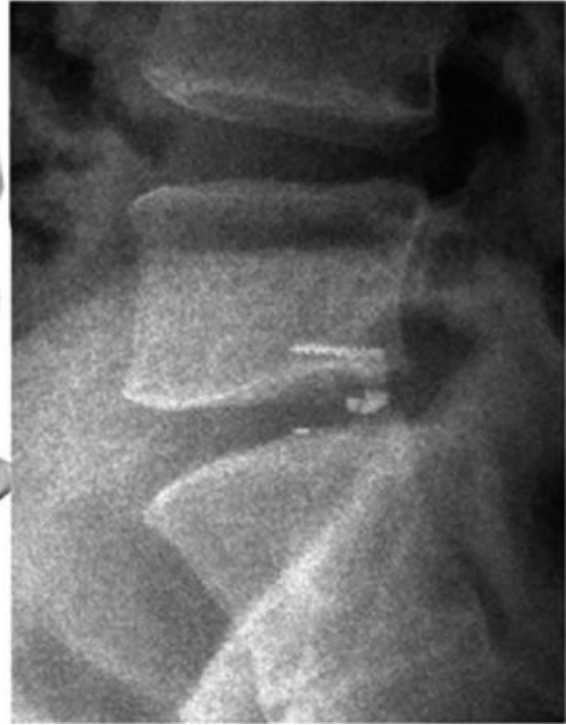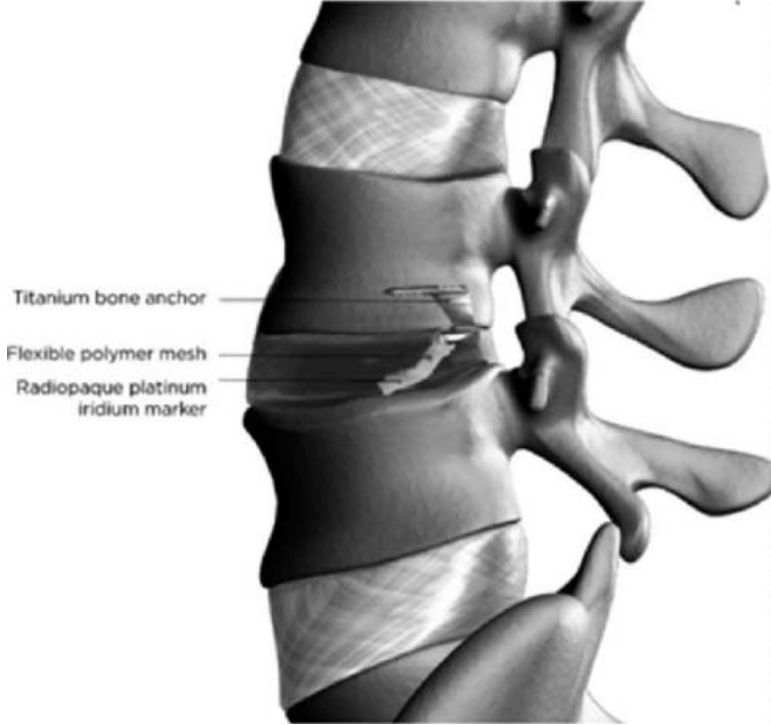

OUTCOMES

- **patient satisfaction** at 1 year (Swedish Registry) – 76%
- **reoperation** for **recurrence** (from 13.2% at 4 yrs to 18.9% at 9 yrs):



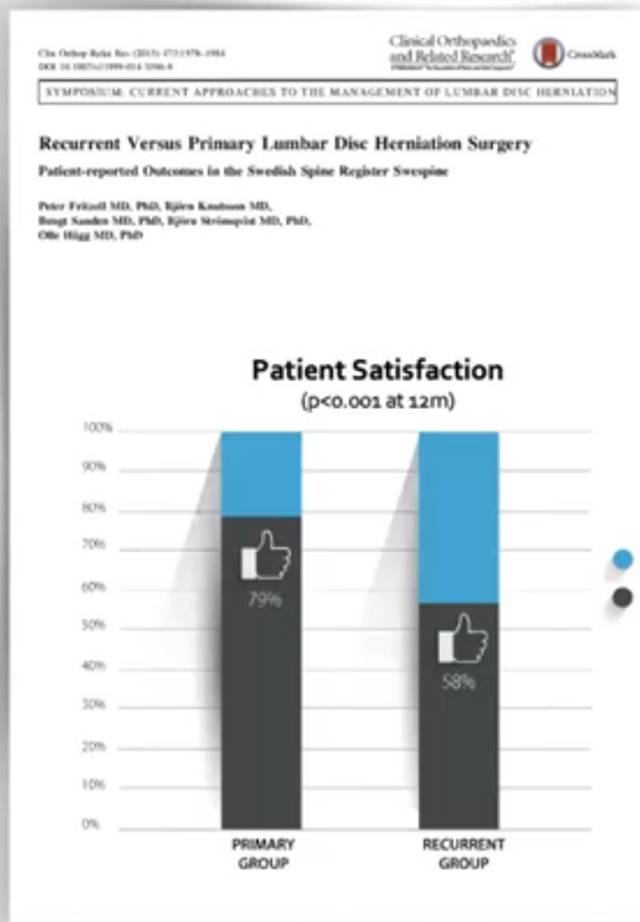
Risk factors for recurrence: **young** (< 50 yo) **females** with **tall discs** and **large annular defects**

- consider annular closure device, such as Barricaid® (FDA-approved, bone-anchoring closure device, reduces reherniation rate by 50%):



Reoperation outcomes are worse:

Swedish Spine Register



PEDIATRIC ASPECTS

- no free disc fragments – they are continuous with nucleus pulposus.
- irrigate disc space to remove inflammatory cytokines.

(FAR) LATERAL LUMBAR DISKECTOMY

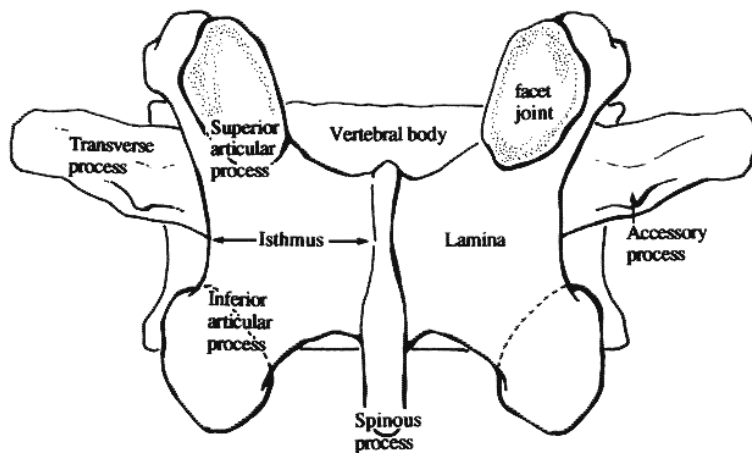
NASS Clinical Guidelines for Lumbar Disc Herniation with Radiculopathy (2012): *insufficient evidence* for or against the specific surgical approach for far lateral disc herniations.

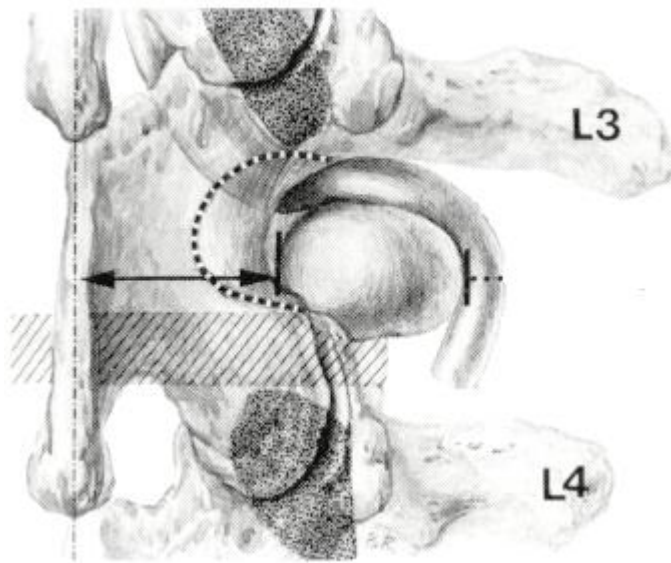
N.B. nerve root is displaced dorsal and cephalad (and pressed against the lower edge of the pedicle) – approach surgically from inferior (encounter disk, not nerve root, first)

From the surgeon's dorsal view, the root leaving foramen becomes visible outside the isthmus laminae (lateral edge of pars); it is hidden by the intertransverse muscle and ligament

“Operative window” for the lateral approach:

- medially** – isthmus
- superiorly** – lower edge of pedicle and transverse process and (if present) by a prominent accessory process
- inferiorly** – facet joint of the respective motion segment.



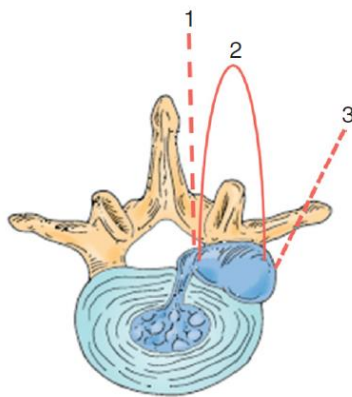


dotted line indicates the area of the isthmus that may be resected

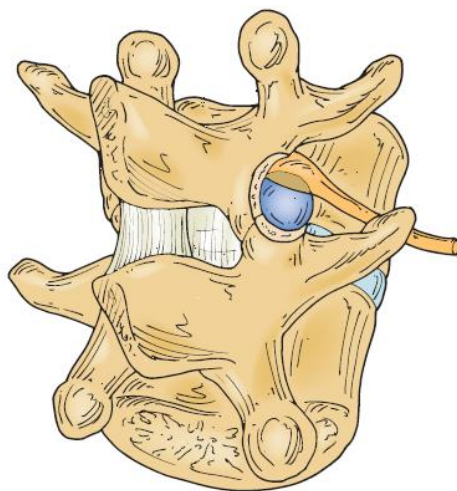
Ganglion issue

- clinically - more radiculopathic pain, less back pain (cf. paracentral herniations).
- intertransverse fascia and the lateral extension of the ligamentum flavum are removed only when drilling and bone resection are complete - *ganglion is very vulnerable to thermal* (drilling, cautery) *or mechanical trauma* → painful postoperative dysesthesia.
- counsel patient that you can remove disc but it takes months for irritated DRG to recover (do not disturb venous vessels around DRG – will cause *venous congestion* and burning pain).

Classification and choice of approach (1 and 2 are intraforaminal, 3 is extraforaminal hernia)

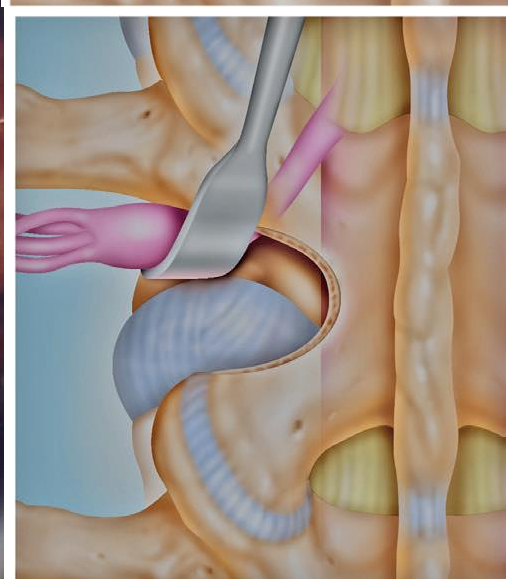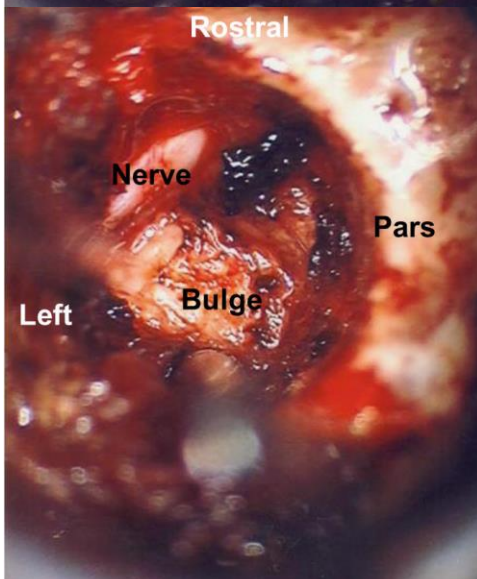
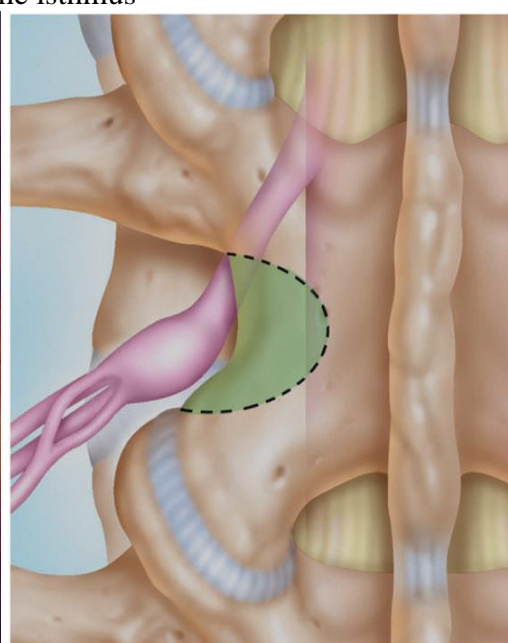
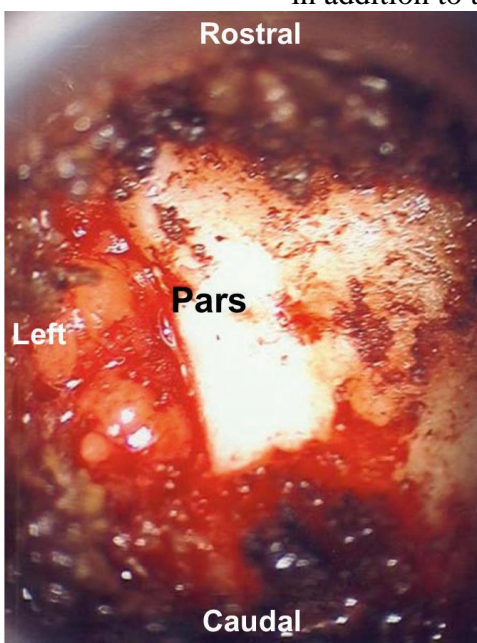


1. Hernia within proximal foramen (just at the medial aspect of the pedicle) → midline incision and interlaminar exposure with **medial facetectomy** (amount of bone that must be removed over the annulus to gain exposure to the neuroforamen may be greater than that in simple dorso-lateral hernias); higher in lumbar spine, in order to preserve the narrow pars, it may be necessary to augment a medial facetectomy approach with **intertransverse approach**.
 - alternative - approaching from **interlaminar approach originating from contralateral side** → proceeding across the midline and under the facet, minimizing facetectomy.
2. Hernia in lateral foramen → **lateral pars (up to 1/3) resection ± lateral facetectomy**: muscle is not dissected off the spinous processes but rather incised 1 cm lateral to the midline → facet joint is exposed → drill and punch are used to produce a partial lateral facetectomy through which the rostral and caudal pedicles can be palpated → nerve root (forced dorsally by hernia), lies deep to the facet capsule and ligamentum flavum, can be mobilized and retracted to address the disc hernia:

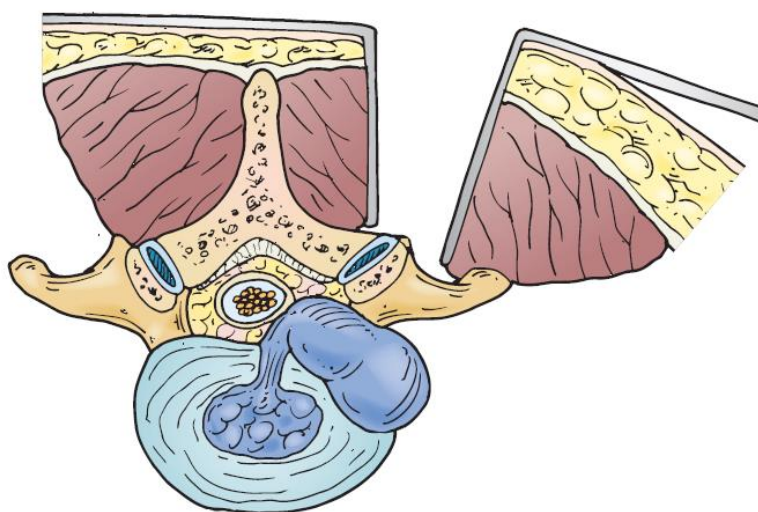


MIS approach (22 mm tube is docked on the pars) - following excision of the lateral one third of the pars (isthmus), the foramen is unroofed* and nerve root visualized → elevating the root brings the herniation into view:

*sometimes need to shave the superolateral aspect of the facet complex in addition to the isthmus



3. Hernia in extraforaminal location → **extraforaminal, paramedian muscle-splitting, inter-transverse approach** (avoids complete facetectomy):



- with tubular retractors (far lateral disc is the only advantage of tube vs. microdiscectomies), using navigation!
- paramedian skin and fascial incision, 3 cm from midline (or farther lateral at lower levels), is made just over natural plane groove between multifidus and longissimus muscles.
- descending through paraspinous musculature between transverse processes onto neuroforamen from a lateral orientation, surgeon is able to locate lateral facet and its capsule and need remove only a small amount of lateral facet, if any.
- medial transverse processes are exposed, the multifidus muscular attachments to the facet are incised, and the intertransverse muscle and ligament are incised. It is then possible to expose the affected nerve root in the neuroforamen, retract it aside, and address the disc hernia.
- advantage - preservation of the pars interarticularis and the facet joint with little likelihood of instability.
- disadvantages: surgical unfamiliarity, deeper dissection, possibly poorer visualization, difficulty enucleating the disc space, potential injury to the nerve root.

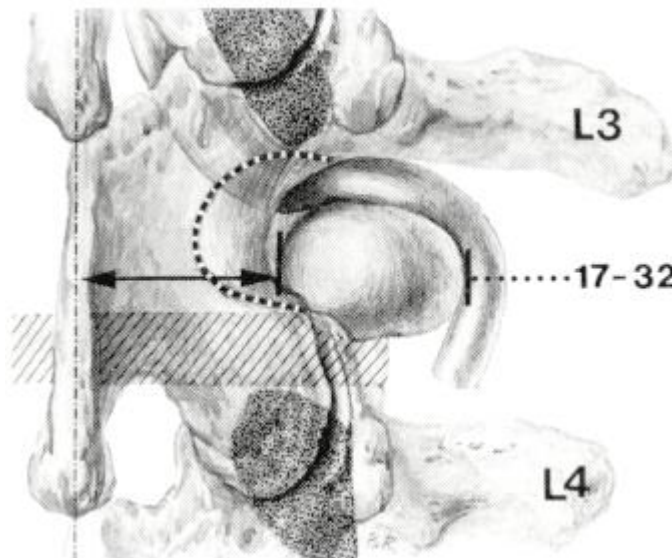
Very large and difficult hernias → **complete facetectomy**.

- although complete facetectomy has been historically reported to be relatively benign, it is now recognized as resulting in delayed instability - consider adding **TLIF**.

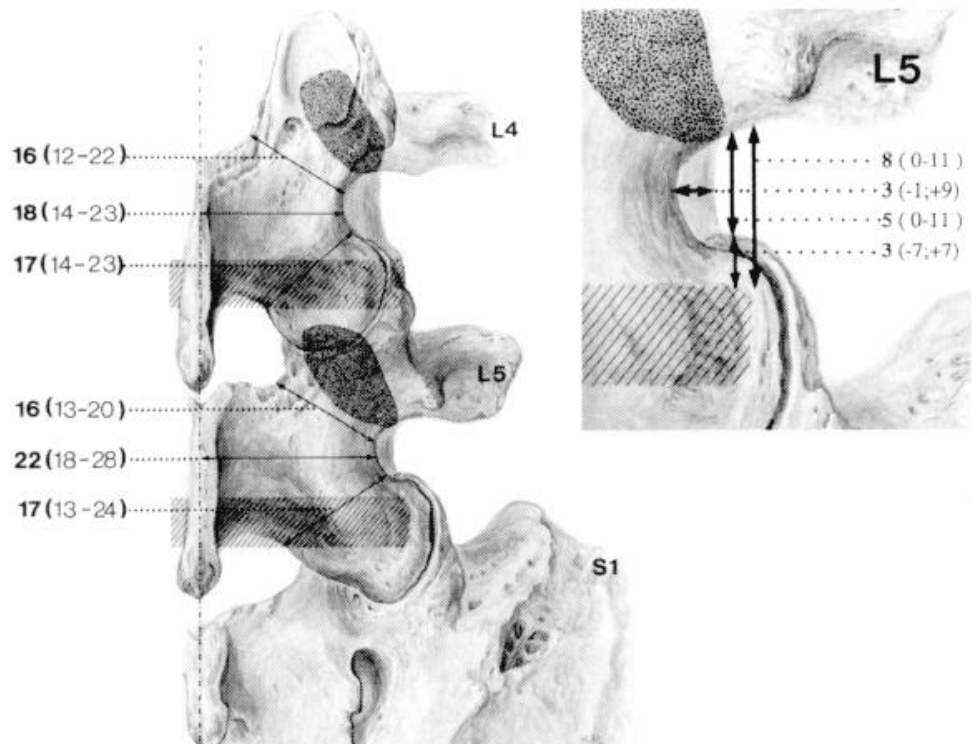
Anatomical study

Reulen, H. et al (1996). *Microsurgical Anatomy of the Lateral Approach to Extraforaminal Lumbar Disc Herniations. Neurosurgery*, 39 (2), 345-351.

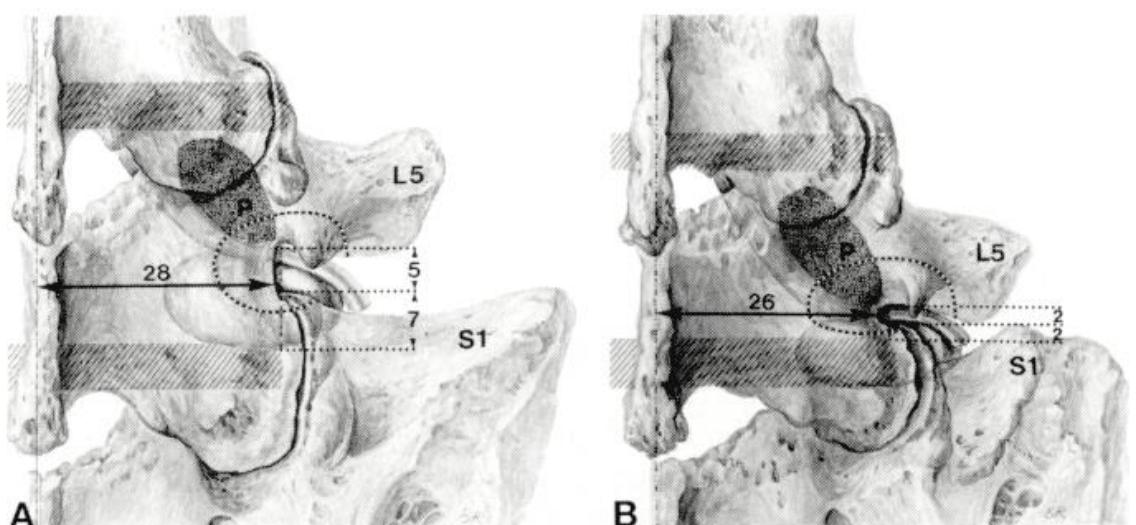
- anatomic study of medial intertransverse space to examine the bony boundaries.
- **operative window becomes progressively smaller** as approach moves from L1-L2 toward L5-S1 (variations and abnormalities are found particularly often at the L5-S1 level):
 - 1) **medial boundary (isthmus laminae)** gradually extends farther laterally and eventually covers the waist of vertebral body;
 - 2) **lower boundary (facet joint)** gradually overlaps disc space in upward and lateral direction;
 - 3) **upper boundary (transverse process)** gradually moves downward.
- at levels **L1-4** - **midline approach with lateral retraction of the paraspinous muscles** allows for efficient exposure of the lateral neural foramen and avoidance of trauma to the facet joint:



at level **L4-5** (often) and at level **L5-S1** (nearly always as foraminal length [medial-lateral] may reach 25 mm and height [cranial-caudal] of operative window may be 0-3 mm) - **tangential paramedian transmuscular approach** offers many advantages:



- two unfavorable situations encountered at L5-S1:



LUMBAR MICRODISKECTOMY - REDO

Increase laminotomy window – that will also help detach scar tissue from bone edges.

Detach scar tissue from dura using curette (same if disk fragment is attached to dura) – always stay on bone (the only safe way).

LUMBAR MICRODISKECTOMY – MIS (TUBULAR RETRACTORS)

- using **Medtronic METRx II** tubular retractor system; introduced to increase rate of recovery – studies do not confirm it!

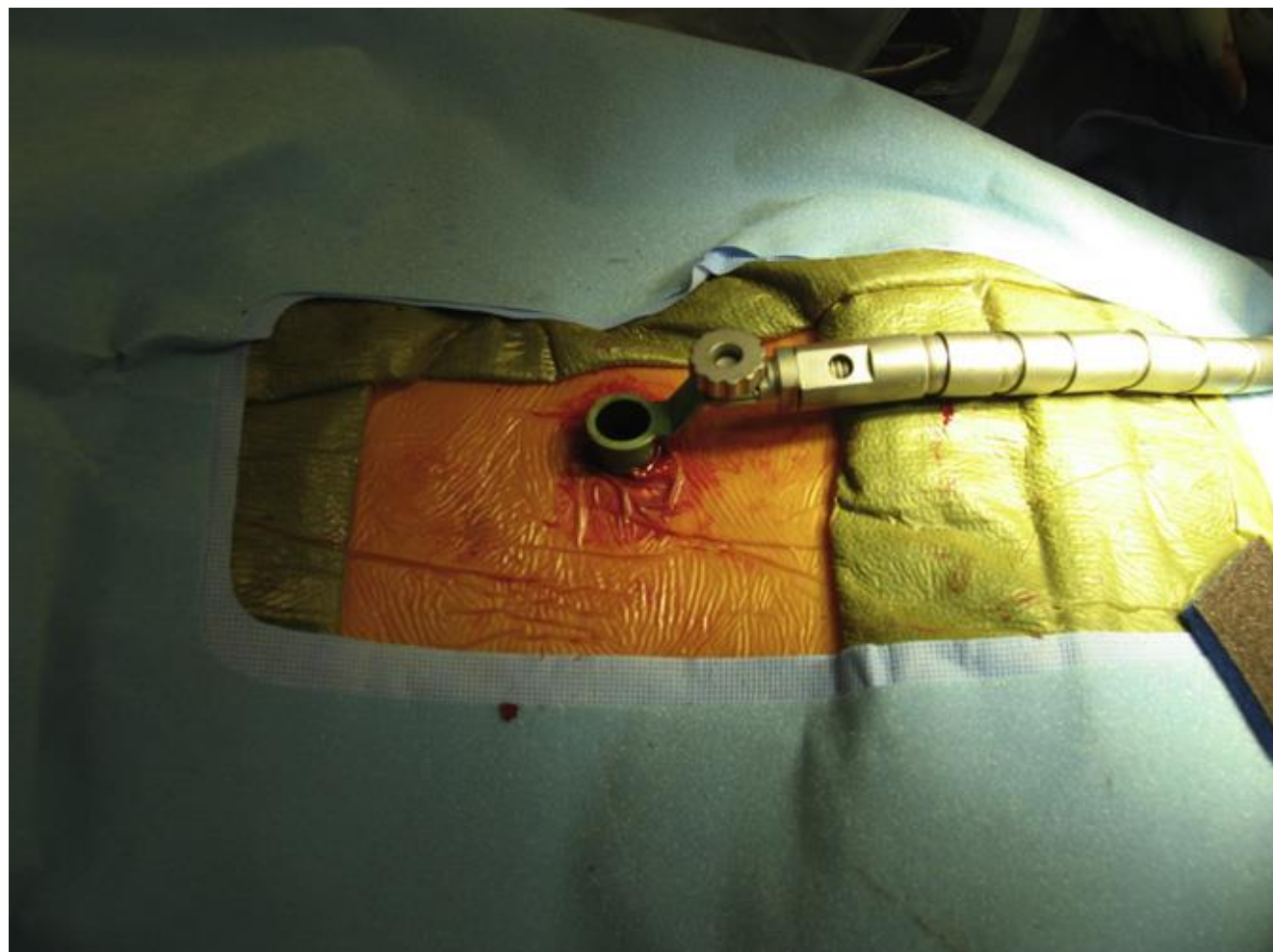
- wear lead apron but no loupes.
- Wilson frame.
- draped fluoro at the time of patient draping.

INCISION

- spinal needle inserted into the paraspinal musculature → lateral fluoroscopy.
- 22 mm vertical skin incision one fingerbreadth from midline with No. 10 blade at the puncture site followed by fascia incision to make tissue dilation easier.

TARGETING

- Styman guidewire placed through the incision and directed medially towards lamina under lateral fluoroscopy.
- guidewire is advanced only through lumbodorsal fascia with great care taken to avoid penetration of the ligamentum flavum and inadvertent dural puncture.
- first cannulated soft tissue dilator inserted over guidewire utilizing a twisting motion; once fascia is penetrated, guidewire is removed and dilator advanced down to the bony anatomy; next series of tubular dilators with increasing diameter are sequentially placed over each other.
- note depth marking on outer dilator – choose length of tubular retractor.
- tubular retractor is placed over sequential dilators and seated firmly on bony anatomy.
- sequential dilators are removed.
- Flexible Arm is attached to bed rail and Tubular Retractor.
- all soft tissue exposed in the operative corridor is removed with electrocautery in order to maximize working space.
- that established tubular operative corridor.



DISCECTOMY

- operating microscope is brought into field.
- hemilaminotomy is performed with a high-speed drill and Kerrison.
- nerve root is retracted medially utilizing a Love retractor.
- lateral recess stenosis is addressed with Kerrison.
- annulotomy → loose disc material as well as central subligamentous disk material are removed with a pituitary rongeur and sharp curette in a standard fashion.
- JRC uses 40 mg of DepoMedrol over exposed nerve root.

CLOSURE

- Tubular Retractor is slowly removed inspecting paraspinal musculature for bleeding.
- thoracolumbar fascia is closed with 2-0 Vicryl in interrupted fashion.
- skin is closed with 2-0 Vicryl in interrupted fashion with inverted knots.
- SteriStrips and the sterile Island dressing.
- **durotomy (CFS leak)** – no need to attempt repair – after Tubular Retractor is removed, muscles collapse and seal the potential space.

OUTCOME TRIALS

- prospective, randomized clinical trial (150 patients in each arm) compared traditional open microdiscectomies with tubular discectomy 1 year after surgery. Patients had significantly **inferior satisfaction scores** with microtubular discectomies versus traditional open microdiscectomies.

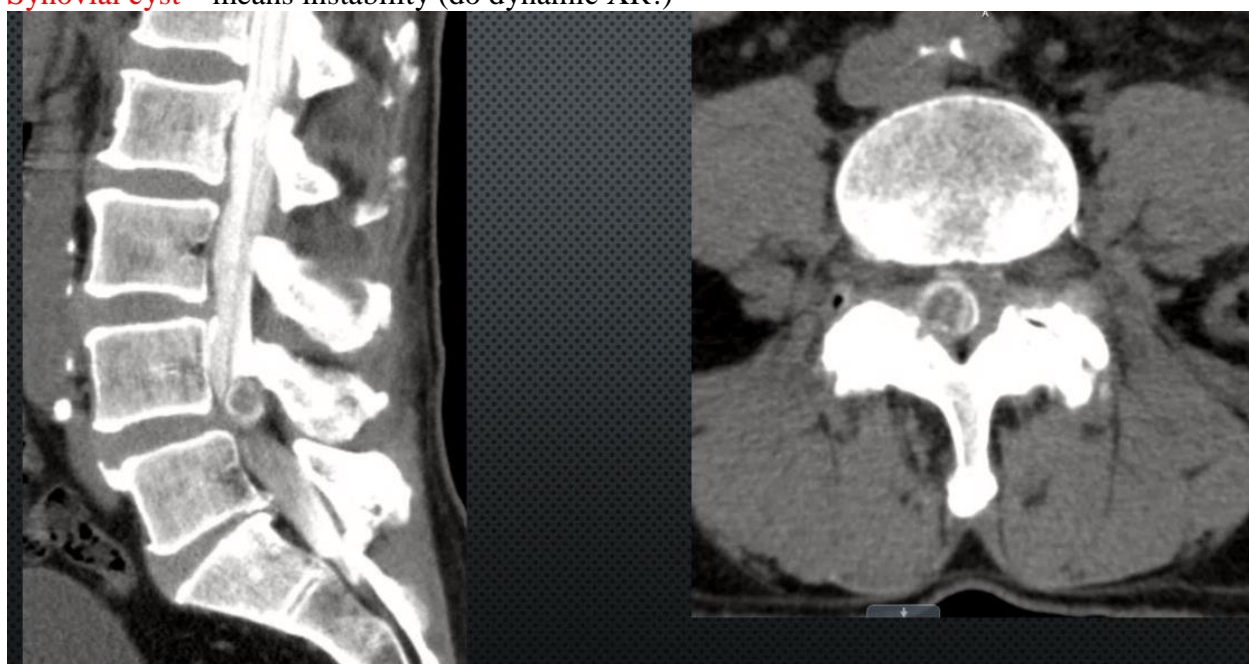NASS Clinical Guidelines for Lumbar Disc Herniation with Radiculopathy (2012): insufficient evidence for or against tubular discectomy compared with open discectomy to improve the outcomes.

Epstein NE. More nerve root injuries occur with minimally invasive lumbar surgery: Let's tell someone. Surg Neurol Int 25-Jan-2016;7:

SYNOVIAL CYST EXCISION

Cyst is misnomer – it is usually ball of hydrated soft tissue, thus, you will not see fluid-filled sac. Dissect and find where cyst originates (may involve long laminotomy; usually need also superior laminotomy of lower vertebra – to expose entire pedicle and medial facet)

Synovial cyst – means instability (do dynamic XR!)



Cyst can be adherent to dura!

FORAMINOTOMY

- **expose lateral edge of pars** – will know how far can take pars for decompression without destabilization (safely can remove medial 1/2 of pars).
N.B. if doing **foraminotomy with microdiscectomy** (i.e. with intact spinous process) – will be difficult to achieve angle (Kerrison will rest on spinous process) – **risk of inadvertently destroying pars** by taking vertical bites on pars (if that happens – decorticate lateral pars surface and place DBX putty, keep patient in simple corset for 6 weeks to remind to prevent bending / twisting motions)
- use 2 mm Kerrison and 45 degree curette to enlarge foramen; check with Woodson probe.

Alternatives – indirect decompression with LLIF or interspinous decompression (e.g. COFLEX)

LATERAL FORAMINOTOMY

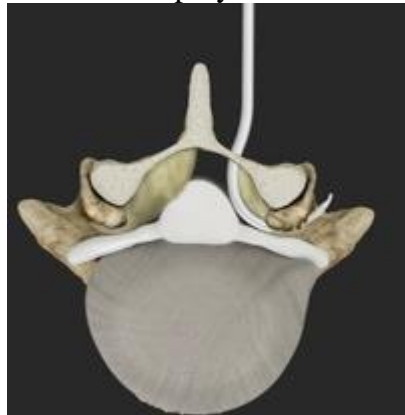- if stenosis is created by **lateral facet osteophyte** – will not reach from medial side; expose lateral side of pars and top of lateral facet; dissect anteriorly; generous venous plexuses – bleed a lot but bipolarizing may irritate dorsal root ganglion (postop neuralgia).
- use drill, pituitary rongeur, 2 mm Kerrison.

MINIMALLY INVASIVE FORAMINOTOMY

Insufficient foraminotomies can lead to persistent radiculopathy.

Baxano iO-Flex® System

- for both open and tubular retractor access.
All instruments are made that white side (vs. black side) on the handle should be facing surgeon (standing on same side as foraminotomy).
- difficult on L5-S1 level – iliac crest on the way.
- use NIM-EMG to monitor muscles innervated by nerve root being decompressed (e.g. left vastus lateralis, extensor hallucis longus, medial gastrocnemius);
settings: 300-4-50
- prone on uncranked (!) Wilson frame
- perform laminotomy.
- **Probe** deploys across foramen (targeting impinging tissue to precisely deliver the wire):



– **Ipsi Probe 90** & **Contra Probe 45** (for contralateral foraminotomy across midline)

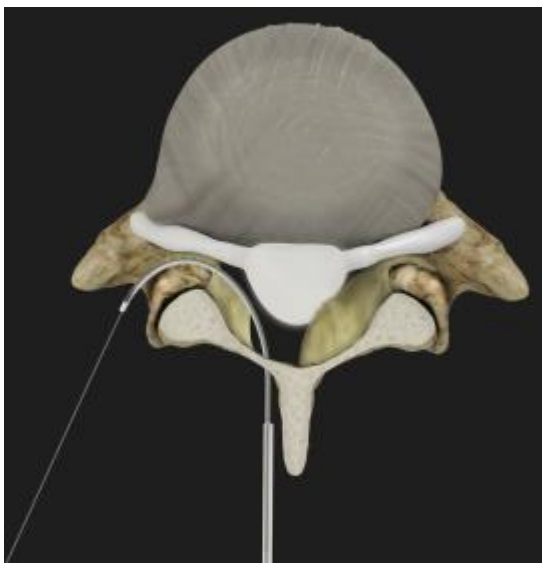

– Guide exits (should be without resistance) to the number 3-4 on the handle.

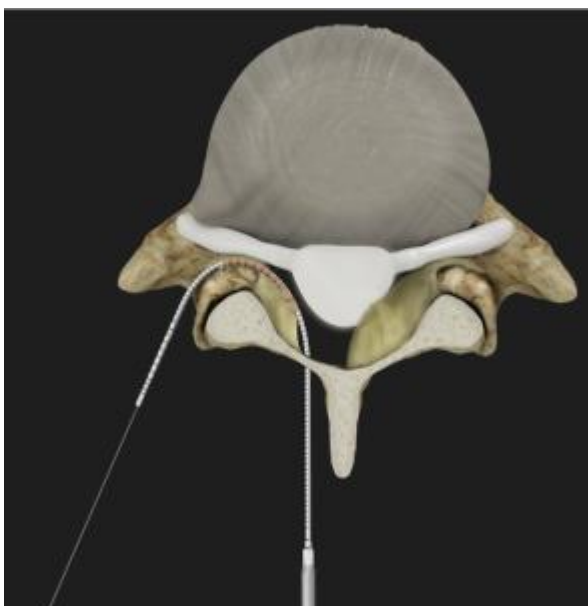- **Guidewire** is passed and exits through paraspinal muscles and skin (therefore, prep and drape wide) and is grasped with Kocher and then **Distal Handle**:



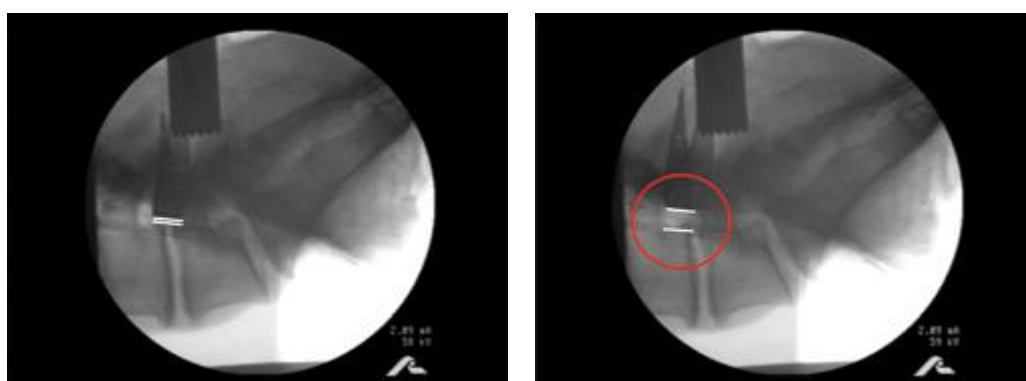- advance **Neuro Check® device** - helps confirm wire is dorsal to nerve root – switch lets stimulate dorsally and ventrally in foramen (difference to obtain EMG response should be > 3 mA):
 - has two radiopaque dots on each side of electrodes (one must be on pars right in foramen, another – extraforaminal)
 - when stimulating dorsally, pull wire against pars
 - when stimulating ventrally, relax wire



- advance **MicroBlade Shaver® instrument** (comes in three widths – 5.5, 7.5, 10.5 mm) - performs precision removal of impinging bone and soft tissue – by using sawing motion back-and-forth (bimanual reciprocations):



- use lateral fluoro to assess progression of decompression:
 Stenosis prior to reciprocation: Removal of impinging tissue following reciprocation



- there is special cannula for FloSeal deposition in foramen (in case bleeding happens).

NONINSTRUMENTED FUSION

- advantage – more elasticity in the segment (than with instrumentation) – less risk of adjacent level disease.
- good only if segment has started autofuse.
- damage facets to promote fusion.
- decorticate and place grafts as for instrumented fusion.

PEDICLE SCREWS & POSTEROLATERAL FUSION

Medications, Positioning, Skin incision, Fascial and Subfascial and Subperiosteal Dissection, Closure - see “Posterior Midline Approach” >>

- prone on chest rolls (longitudinal or transverse) / Jackson table ensuring anatomical nonflexed position.

BRIEF HISTORY

- first descriptions of use of bone screws to obtain internal spinal fixation at time of fusion were by Tourney in 1943 and King in 1944.
- Boucher in 1959 was first to use pedicle screws.
- Roy-Camille was first to use pedicle screws connected to dorsal plate (Clin Orthop 203:7-17, 1986).
- first system using both screws and hooks connecting them with rods or plates (i.e universal spinal instrumentation) was introduced by Cotrel and Dubousset (Clin Orthop 227:10-23, 1988).

BIOMECHANICS

- pedicle screws **traverse all three columns of vertebrae** - can rigidly stabilize both ventral and dorsal aspects of spine.
- pedicle also represents **strongest point of attachment** of spine:
 - significant forces can be applied to spine without failure of bone-metal junction.
 - allows for incorporation of fewer normal motion segments in order to achieve stabilization of abnormal level.
- pedicle screw fixation does not require intact dorsal elements - can be used after laminectomy or traumatic disruption of laminae, spinous processes and/or facets → less requirements for postoperative bracing and improvements in fusion rates.

pedicle: strong, cylindrical, anatomic bridge between dorsal spinal elements and vertebral body; consists of strong shell of cortical bone and core of cancellous bone

Screws are categorized into two types “self-drilling” or “self-tapping” — and these types are not interchangeable.

- technically, both of these types of screws will tap their own threads, but the self-drilling screws are unique.
- tip of a self-drilling screw is shaped with a point and flute that resembles a drill bit: notched area in the tip behaves as a reservoir to receive chips or filings as the material is carved away by the screw (when drilled) - self-drilling screw allows to skip the initial step of drilling a pilot hole = time-saving and cost-effective choice.
- in contrast, a self-tapping screw requires an initial pilot hole, and can have a sharp, flat, or blunt tip.

Here’s a rule of thumb: All self-drilling screws are self-tapping, but not all self-tapping screws are self-drilling.

Essentially, **a self-drilling screw is a self-tapping screw with the added feature of the drill point.**

DISADVANTAGES

1. Caudal or medial penetration of pedicle cortex can result in dural or neural injury (nerve root occupies ventral and rostral one-third of foramen).
 - screw placement can be checked **electrophysiologically** with direct stimulation of pedicle probe or screw producing electromyogram (EMG) response peripherally; if this response occurs below threshold expected for intact cortical bone, screws may be redirected or removed.
2. Extensive tissue dissection (to expose entry points + to provide required lateral to medial orientation for optimal screw trajectory) → costly lengthy operation, significant blood loss.
3. Postoperative MRI is obscured by implants.
4. Rigid fixation can accelerate adjacent motion segment degeneration.

INDICATIONS

1. Painful spinal instability:
 - 1) post-laminectomy spondylolisthesis
 - 2) painful pseudoarthrosis
2. Potential instability:
 - 1) spinal stenosis
 - 2) degenerative scoliosis
3. Unstable fractures.
4. Augmenting anterior column instrumentation:
 - 1) tumor
 - 2) infection
5. Stabilizing spinal osteotomies.

TECHNIQUE (PERCUTANEOUS, MIS)

- it is stabilization (not fusion, so cannot bill for arthrodesis?):
 - A) for **trauma** (i.e. internal brace) without need for decompression; so, after healing of fracture (6-9 months), hardware needs to come out (as screws will become loose due to movement of nonfused segments and will cause pain); use it only if see enough bone contact on imaging so it will heal (soft tissue components prevent healing – may need fusion).
 - B) posterior support for **lateral interbody fusions**

Prerequisites

- pedicles should be well seen on AP fluoro
- **no need to decompress** canal (if yes, then need open approach with laminectomy)
- **no injury to ligamentous** structures necessary for stabilization (ligaments do not heal – instability will remain even after bone healing)
- difficult for **thoracic** spine as pedicles rather thin (but robot allows very precise trajectories).

GLOBUS – CREO MIS

- CREOMIS polyaxial pedicle screws have breakable flanges.
- plan to place surveillance marker and DRB using spinous process clamps that straddle pathological level (esp. important in unstable trauma) – e.g. on T8 and L1 spinous processes for T11 fracture.
- temporary registration fixture is attached above DRB and then adjusted to be immediately above anticipated instrumentation site; O-arm scan was performed and automatic registration transferred to robot.
- pedicle screw trajectories are planned.
- using navigated guiding tube marked screw entry points on the skin → bilateral Wiltse incisions are made to connect entry points – skin, subcutaneous tissue, until fascia was exposed.
- drive robotic guiding tube to the first trajectory: navigated fascial stab incision is made with knife, followed by high-speed drill bone pilot hole, followed by drill for bone trajectory, followed by a tap.
- intactness of trajectory may be checked using ball-probe feeler through reducing guide tube.
- pedicle screw is placed to preplanned trajectory.
- O-arm scan confirm intended location of screws.
- attach heads on screw flanges.
- sextant is used to measure rod lengths (aim for the next length rod, err on longer length).
- sextant with attached curved rods is placed to fill all screw heads.
- locking caps are applied.
- break off flanges.
- close fascia, skin; no drain.

MEDTRONIC - SEXTANT

Medtronic Sextant system: <https://www.youtube.com/watch?v=8CKKSqDT0aU>
 Medtronic - CD HORIZON SEXTANT System >>

K2M

K2M ENHANCES VISIBILITY Through a Minimally Invasive Approach

Now you SEE it...



EVEREST® MI Spinal System
Featuring SERENGETI®

Now you DON'T!



Traditional MI Posterior Percutaneous Technology

The New & Improved EVEREST® Minimally Invasive Spinal System





[Learn More](#)

www.K2M.com
866.526.4171

TECHNIQUE (OPEN)

Using **O-arm and navigation** – see above >>

L5-S1 is technically most difficult level to fuse properly (esp. if using spondylolisthesis reduction).

- dissection with Bovie to fully expose transverse processes – at junction of pars and superior facet;
 - do not violate superior most facet (it is OK to cut lateral facet joint – i.e. facet process of vertebra involved in fusion); other facets can be denuded by dissecting on bone (as intention is to fuse them)
 - dissect on lateral surface of facets
 - ideally expose intertransverse membrane (careful – nerve root is beneath it)
 - may excise (esp. with **Dr. Mathern**) paraspinal muscles to create space for bone grafts.
 - transverse process only anatomical guide and does not contribute much to fusion.
 - Dr. Cameron** uses large Gelpi retractors!

LAMINECTOMY

- may not be indicated if operating for trauma with no canal stenosis.
- if burst fracture with retropulsion – may use Woodson / bone tamp to push retropulsed fragments ventrally (but usually those get auto-absorbed over time after fusion).

SCREWS

N.B. do not use **polyaxial** screws for TRAUMA (one of old AO principles!)
 Measure pedicle widths on CT scan! – most accurate way as there is a lot of anatomic variability in pedicle width (even between left and right sides)

thoracic – 4.5-6.5 mm

- at T1-3, 4.5 mm diameter screws that are 25-30 mm in length are usually recommended. At T4-T10, screws are usually 4.5 mm in diameter and 30-40 mm in length.

lumbar – 6.5-6.75 mm

sacral – 7.5 mm

- if *replacing old hardware screws* (recommended always, unless fusion is very fresh and screws feel tight) – use screws 1 mm larger in diameter into old trajectories.
- use largest acceptable diameter (as screw bending strength Z increases by cube degree to screw diameter D):

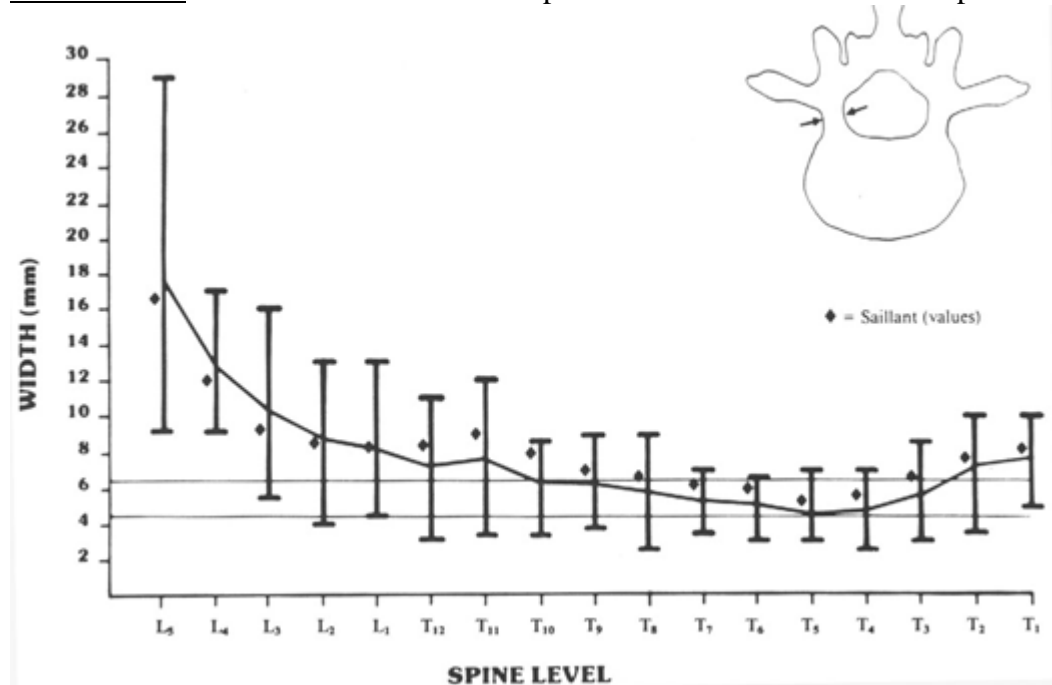
$$Z = \frac{\pi D^3}{32}$$

e.g. difference in strength between 5.0 mm and 6.0 mm core diameter screw is nearly twofold (125 versus 216).

Screw pullout resistance:

- major - screw **diameter**
- thread depth** - screw pullout resistance is proportional to volume of bone between threads.
- cortical purchase** - treads nearest to screw's head bear most of load transferred from bone during pullout stressing
 N.B. proximal cortical "purchase" is very important for pullout resistance!
- depth of screw penetration** - secondary importance

Pedicle width increases in lower lumbar spine and is variable in thoracic spine:



- pedicle width** is more important than **pedicle height** for pedicle screw placement.
 small pedicles – “in-out-in” technique with K-wire.
- pedicle width is narrower than pedicle height except in lower lumbar spine.
- pedicle width increases from L1 to S1
- most pedicles below T10 are > 7 mm in width and most below L1 are > 8 mm.
 N.B. place largest possible pedicle screw! Only disadvantage – if patient will need revision in the future, the larger diameter screws may be needed!

DUAL-HEADED SCREWS

Globus CREO (modular screw):



Medtronic DRMAS (5.5, 6.5, and 7.5 mm diameter):

**CD HORIZON® SOLERA® Spinal System
DUAL ROD MULTI-AXIAL SCREW FOR 5.5/6.0mm RODS**



POLYMETHYLMETHACRYLATE

- used as implant material that conforms to contours of bone; also used for cannulated screws.

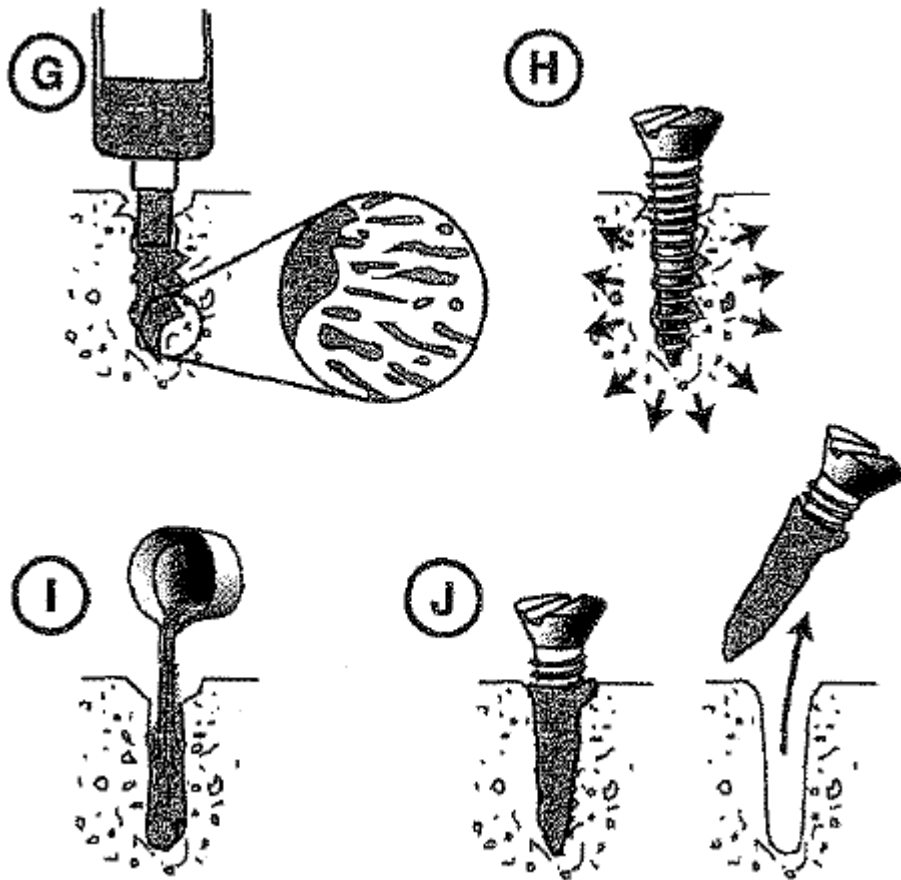
N.B. *loosening of acrylic-bone interfaces is common* - some surgeons have found acrylic to be useful as spinal implant, however, others have found it to have little utility!

Common misconceptions:

- 1) acrylic usually does not conform precisely to bone because of blood interfacing between acrylic and bone (H: injection under pressure)
- 2) bone does not bond to acrylic - osseointegration between surfaces does not occur.

Pressurized injection of polymethylmethacrylate into screw hole causes acrylic to penetrate into bony interstices (G) - this effectively increases screw diameter (H).

If non-pressurized injection is used (I), acrylic penetration into bone interstices does not occur; in fact, acrylic may clump around screw, thus decreasing its efficacy (J):

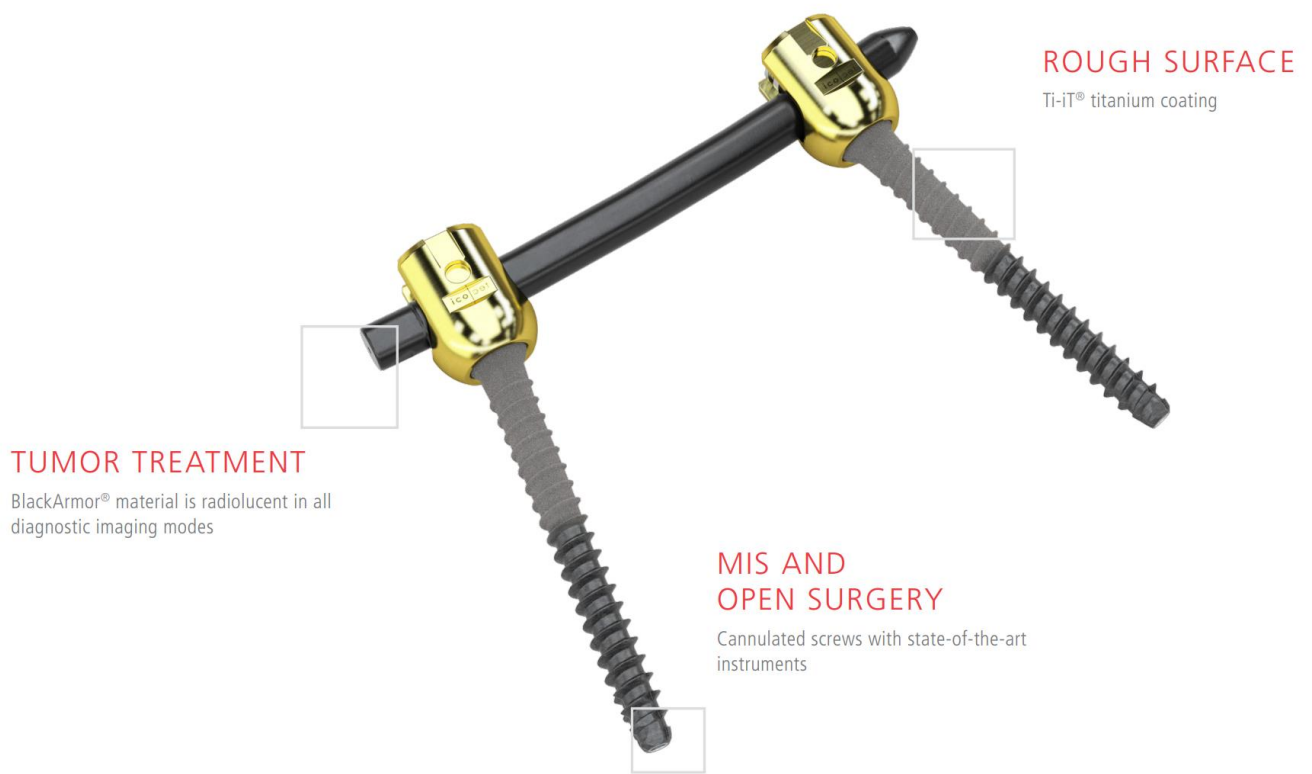


- use approx. 3 mL of cement per pedicle.

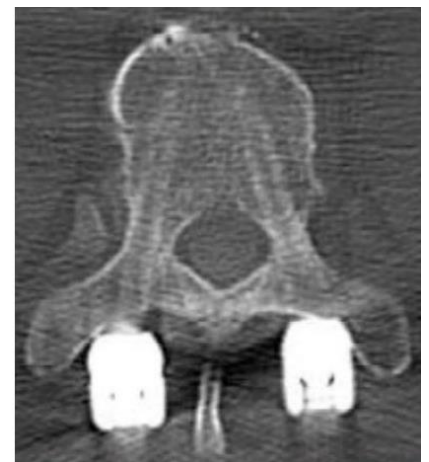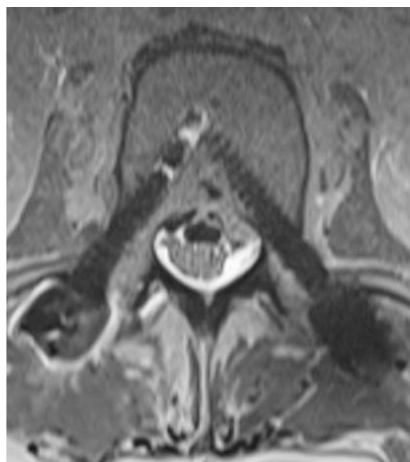
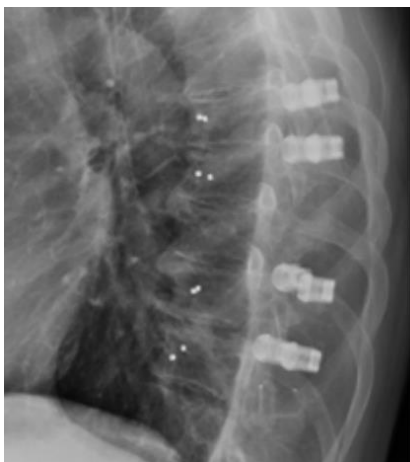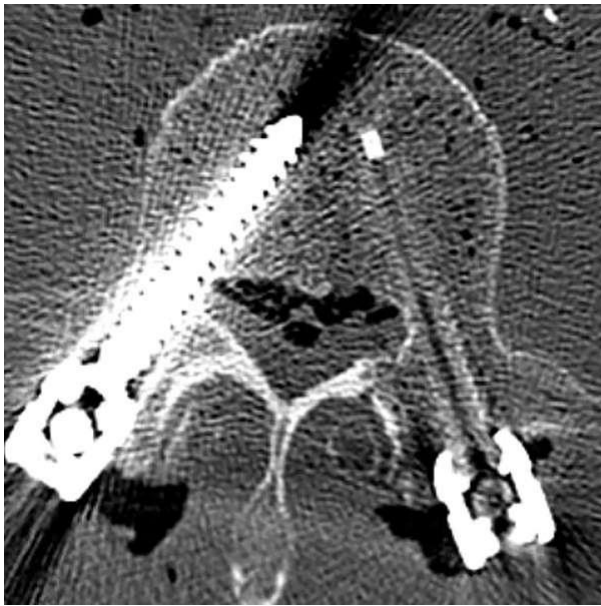CARBON

- artifact-free imaging enables for unobstructed post-operative diagnostic assessment and patient follow-up.
- easy planning of dosage for radiation treatment for more accurate dose delivery.
- reduced scattering and shielding of radiation beam protects adjacent tissue.

BlackArmor® implant material (Icotec-Medical Ag):



Titanium screw and rod vs. BlackArmor® VADER®one screw and BlackArmor® rod:

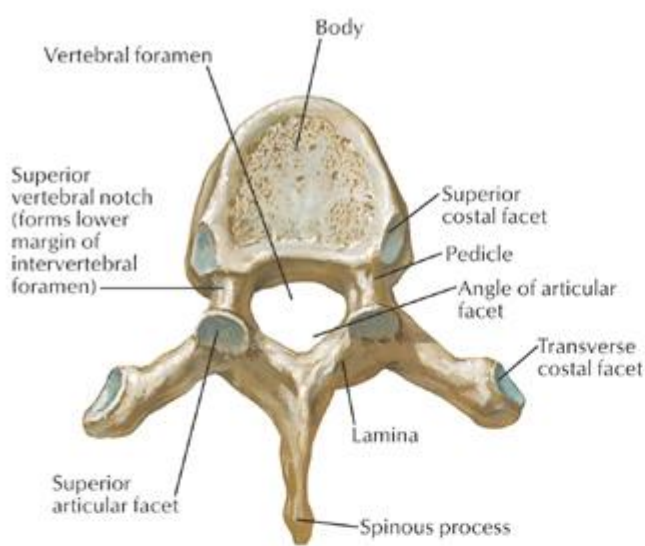
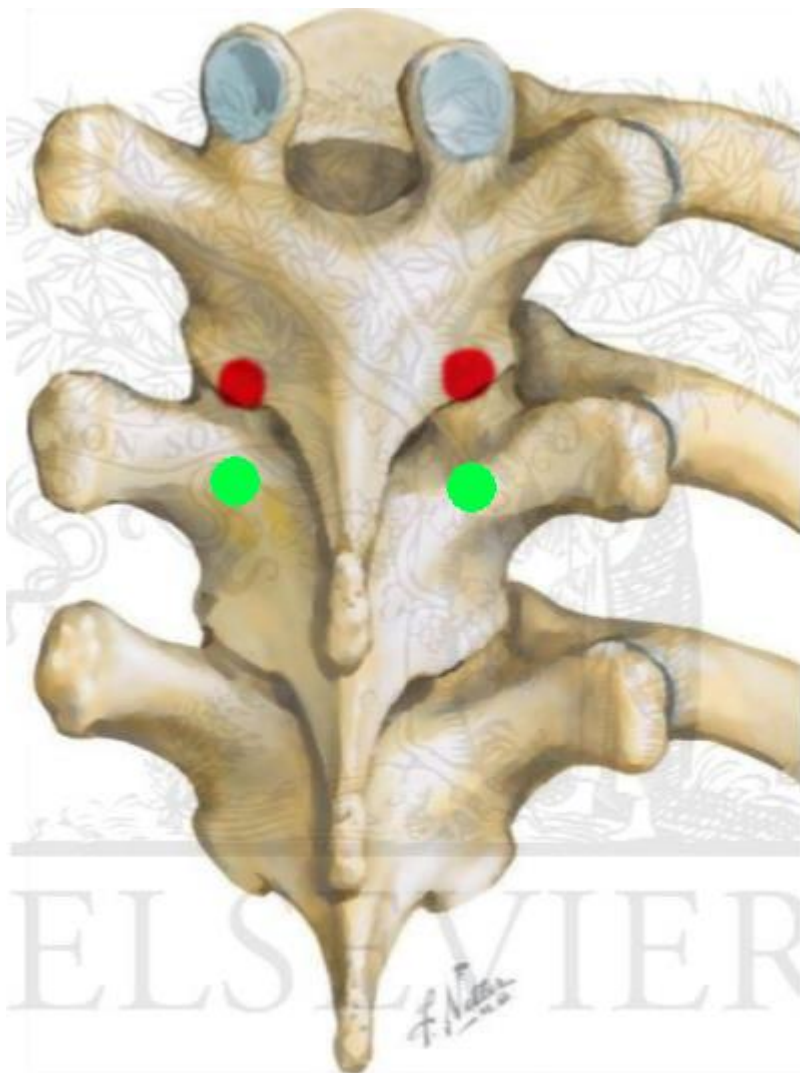


STARTING POINT

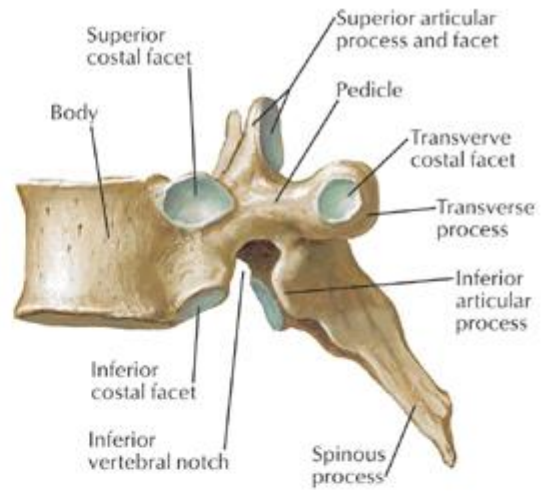
- drill cortical bone at it until see cancellous bone (but only screw core diameter – cortical bone is important structure!);
 - awl would be advantageous as it compacts cortical bone but usually cortex is too sclerotic to penetrate with awl!
- put towel clamp on spinous process of vertebra above – move to see where joint line is.

THORACIC SPINE

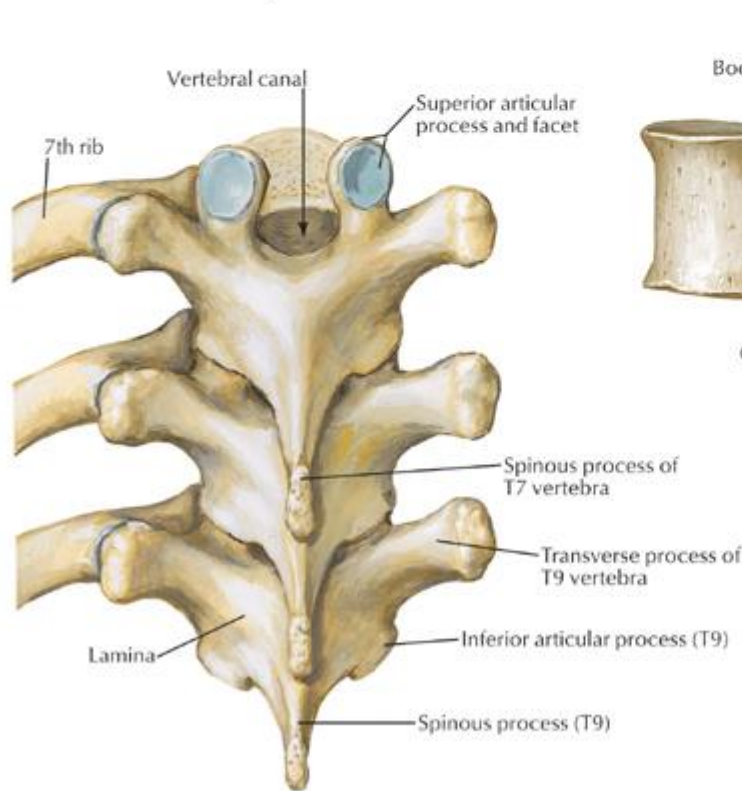
- transverse process commonly does not align with pedicle in axial plane (TP is rostral to pedicle in upper thoracic spine → crossover at T6 → TP is caudal to pedicle in lower thoracic spine) – neuronavigation or fluoroscopic guidance or direct vision and pedicle palpation via laminotomy is highly recommended.
- starting point is the highest (most cranial) at T6, then it migrates caudally when moving towards T12 and towards T1.
- trajectory angle medial-to-lateral gradually changes from 45 degrees at T1 to 0 degrees at T12.
- before placing screw, drill off medial-superior part of transverse processes because it will collide with screw head; then decorticate facet joints to see joint line.
- review anatomical landmarks on preop CT images – both in axial plane (where starting point is on U shape surface of dorsal lamina) and sagittal plane (where starting point is regarding visible joint line – you can see it easily; usually need to drill off a little bit of upper facet joint “lip” to uncover pedicle starting point):
 - red** starting point – for oblique screw trajectory
 - green** starting point – for horizontal screw trajectory



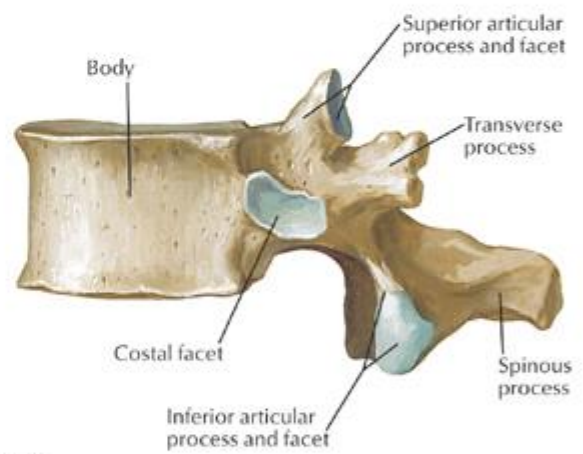
T6 vertebra: superior view



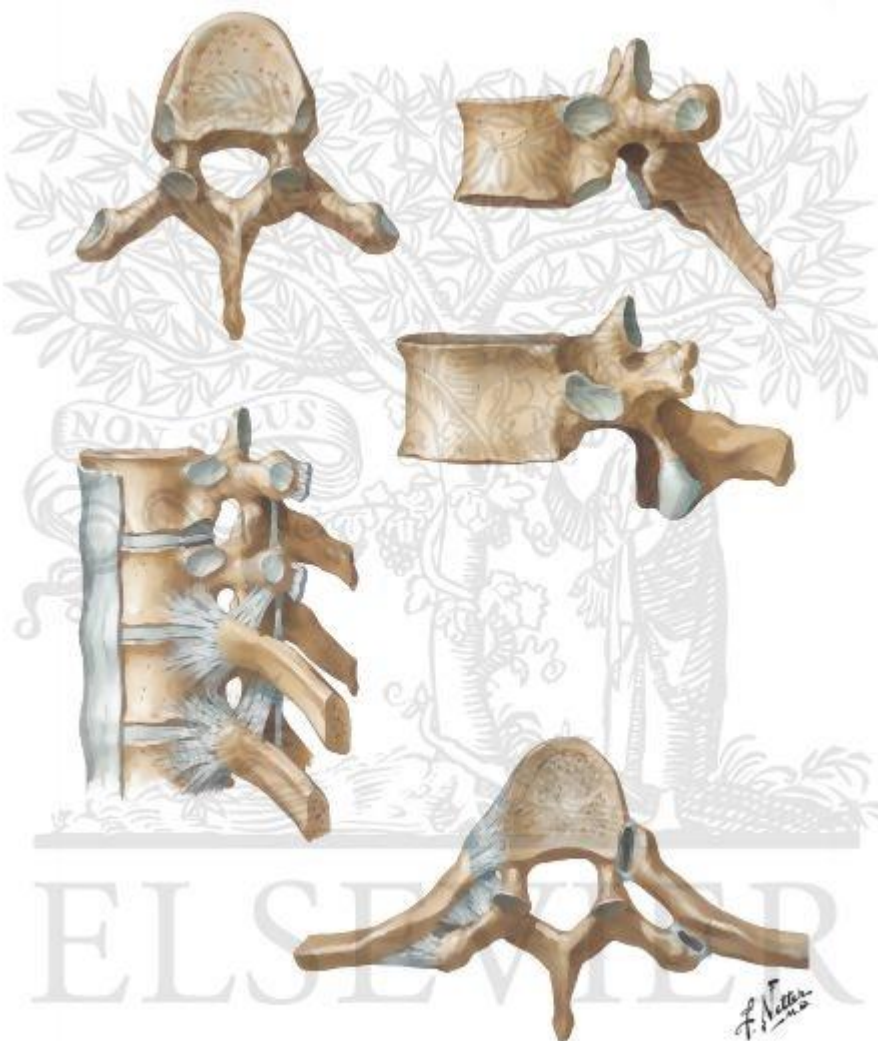
T6 vertebra: lateral view



T7, T8 and T9 vertebrae: posterior view



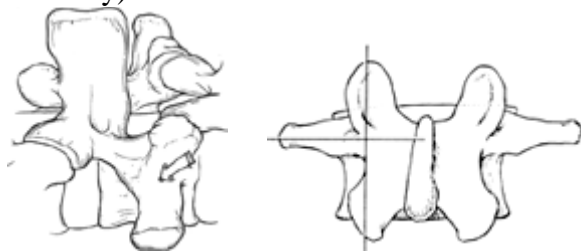
T12 vertebra: lateral view



LUMBAR SPINE

- muscle dissection is performed as lateral as possible to allow palpation of transverse process – one has to be persistent and patient; have some good retractors.

- at junction of lateral facet and transverse process (or bisection of vertical line through facet joints and horizontal line through transverse process), esp. at L4; **Dr. Graham, Dr. Mathern** uses mamillary process (“gift of nature”) as entry point (thus, dissect that area thoroughly to see bone anatomy).

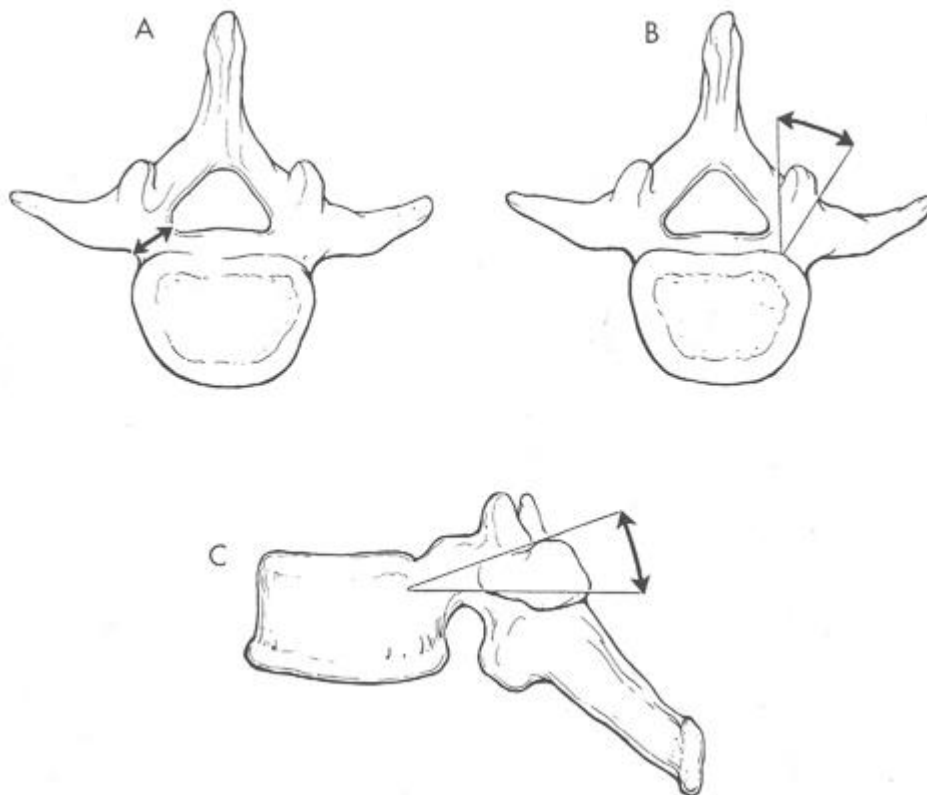


- above L4, midline of TP is rostral to pedicle.
- at L5, it is 1.5 mm caudal to pedicles.
- At S1, entry point is inferior portion of lateral (S1) facet.
- if patient has distorted anatomy (e.g. previous fusion mass – remove it with Leksell), then may use AP fluoroscopy to find starting points.
- Leksell rongeur / drill to remove inferior cortical surface at junction of superior facet, transverse process, and pars (to create room for screw head); at fusion level, can remove dorsal parts of both (medial and lateral) facets – screw starting point in lateral facet immediately adjacent to joint space.
 - in L5-S1 facet, as facet hypertrophies and overgrows dorsally, facet joint line tends to move laterally – thus, remove facet almost flush with sacral surface to see true joint line.

TRAJECTORY

- curved* or straight Lenke probe is passed** through cancellous bone by **generous bidirectional rotation down pedicle** (before that may verify with Woodson probe position of pedicle – most medial point – gives sagittal and lateral angles) but not further (i.e. Lenke is for pedicle only + slightly into vertebral body – typically 30 mm total) → ball probe to verify intactness of trajectory (bottom and pedicle part only; may suction on hole – see if epidural blood is sucked in) → tap for entire (?) trajectory (except last 5 mm)
 - *thoracic is straight (esp. **Dr. Mathern**)
 - **curved tip is facing laterally (to avoid medial breach) and, once passed pedicle, flipped to face medially
- thoracolumbar junction (Th10-L2) pedicles are almost strictly sagittal (or 3-5 degrees per **Dr. Mathern**); for all other direct screws slightly medially.
- sudden plunge suggests breaking out of pedicle laterally.
- increase in resistance indicates abutment against pedicle or vertebral body cortex – do not force but reassess anatomy.
- T1 has unique trajectory – very inward and very towards feet (almost 45 degrees towards floor).
- thin thoracic pedicles – may use parapedicular trajectory (in-out-in).

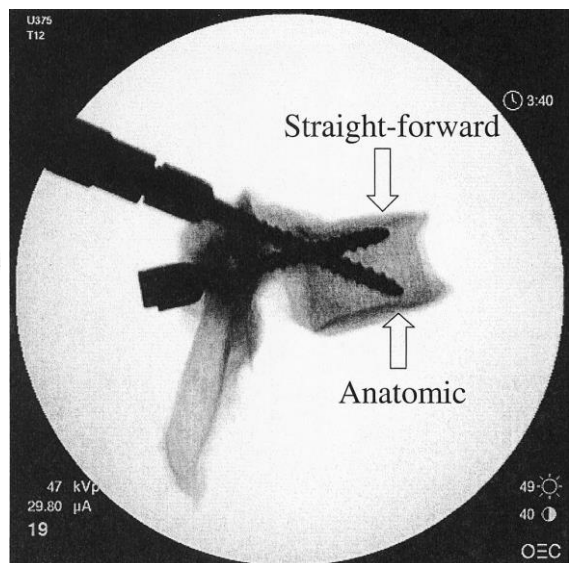
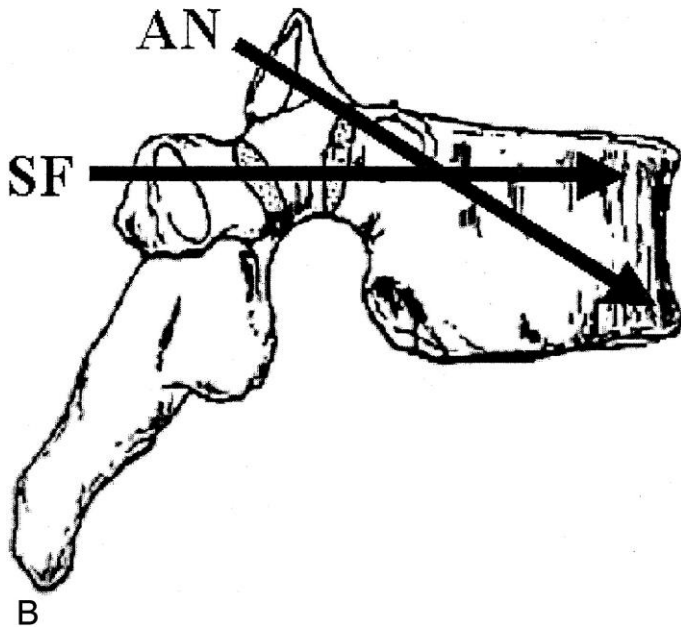
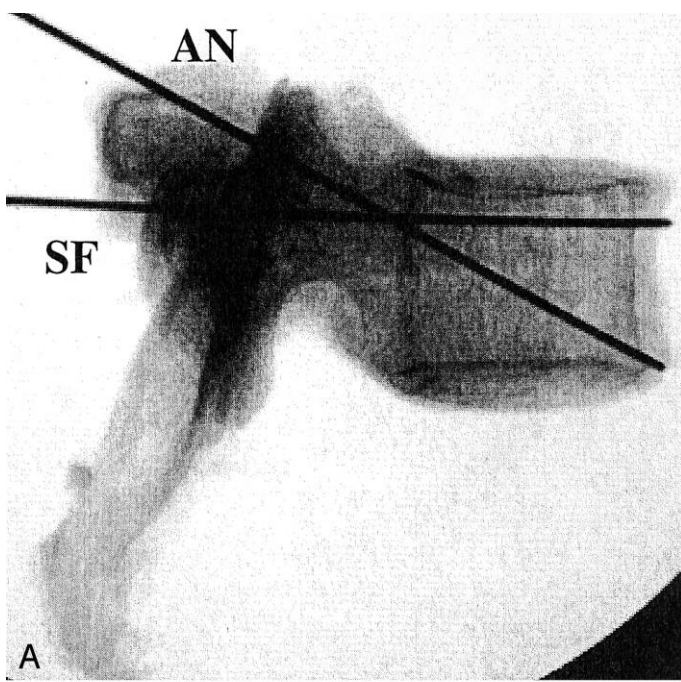
A - pedicle width
 B - transverse (coronal) pedicle angle
 C - sagittal pedicle angle (typically, 22 degrees)



THORACIC PEDICLES SCREW SAGITTAL TRAJECTORIES

Sagittal pedicle angle increases from 0° at T1 to 10° at T8 and then decreases to 0° at T12.

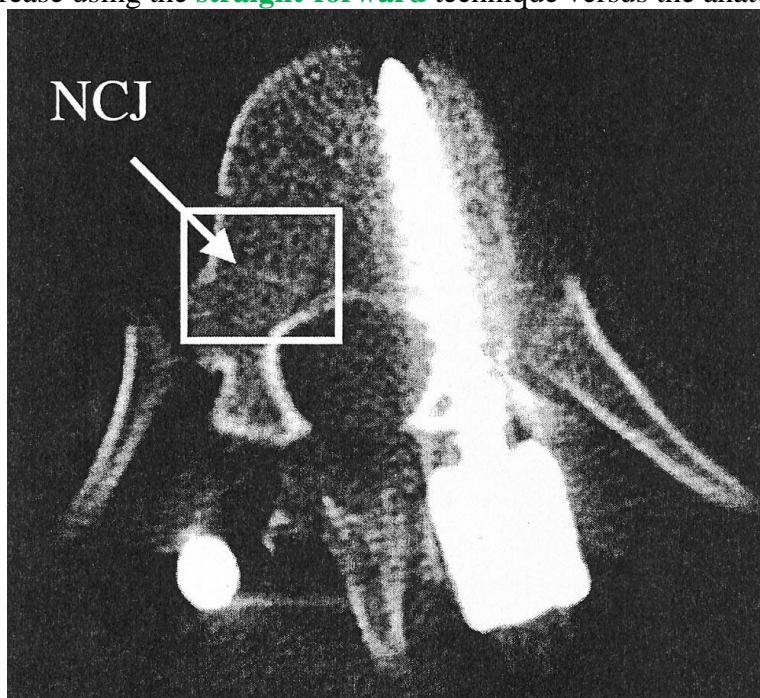
- straight-forward trajectory (paralleling the vertebral endplate)
- anatomic trajectory (directed along the true anatomic axis of the pedicle)



Biomechanical comparison of trajectories

Ronald A. Lehman et al. *Straight-Forward Versus Anatomic Trajectory Technique of Thoracic Pedicle Screw Fixation: A Biomechanical Analysis. SPINE Vol 28, Number 18, pp 2058–2065.*

- **straight-forward** trajectory gives 39% increase in maximum **insertional torque** and a 27% increase in **pullout strength** compared to the anatomic technique.
- maximum **insertional torque at the neurocentral junction (NCJ)** resulted in a 36% increase using the **straight-forward** technique versus the anatomic trajectory:

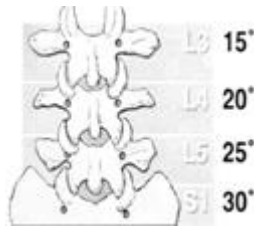


LUMBAR SAGITTAL TRAJECTORY

- L4 sagittal pedicle angle is 0° and subsequent rostral and caudal levels are associated with progressively greater sagittal angles.

TRANSVERSE PEDICLE ANGLE

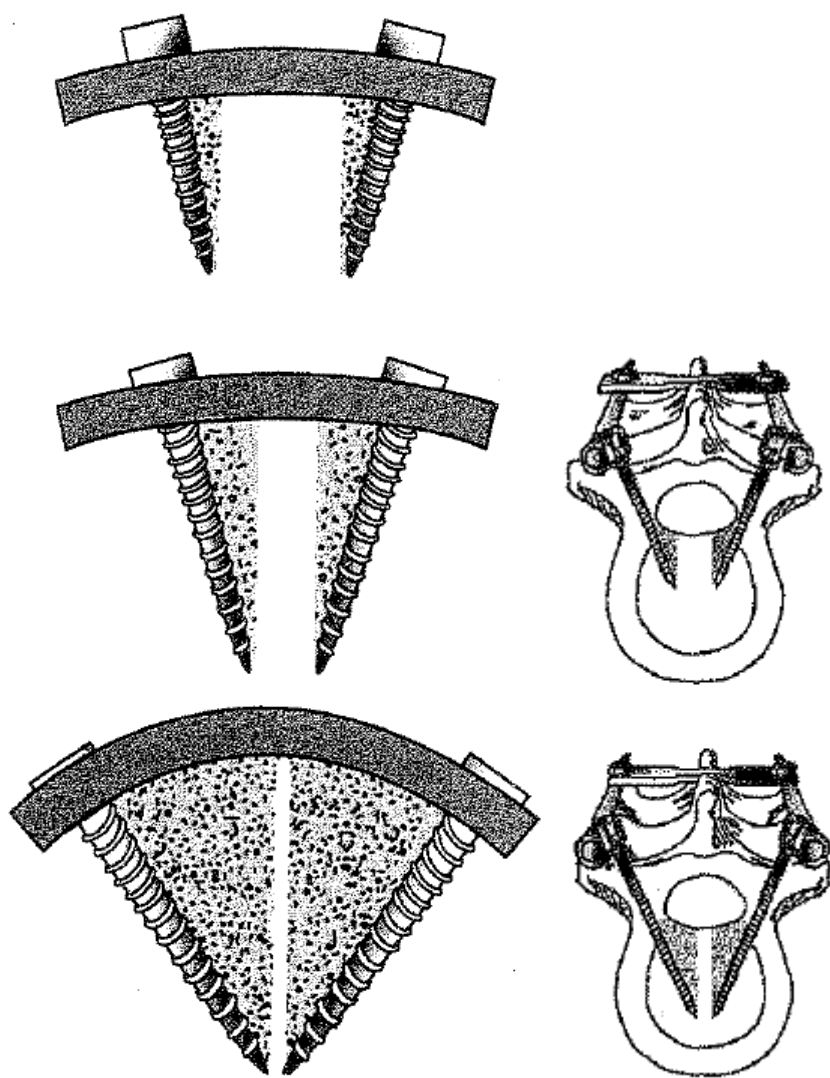
s. coronal angulation (how medial?) decreases as one descends caudally until lumbar region (from 10-15° at T1 to 5° at T12) → angle increases approximately 5 degs per level from L1 to sacrum (L1 medial angulation is 5-10°):



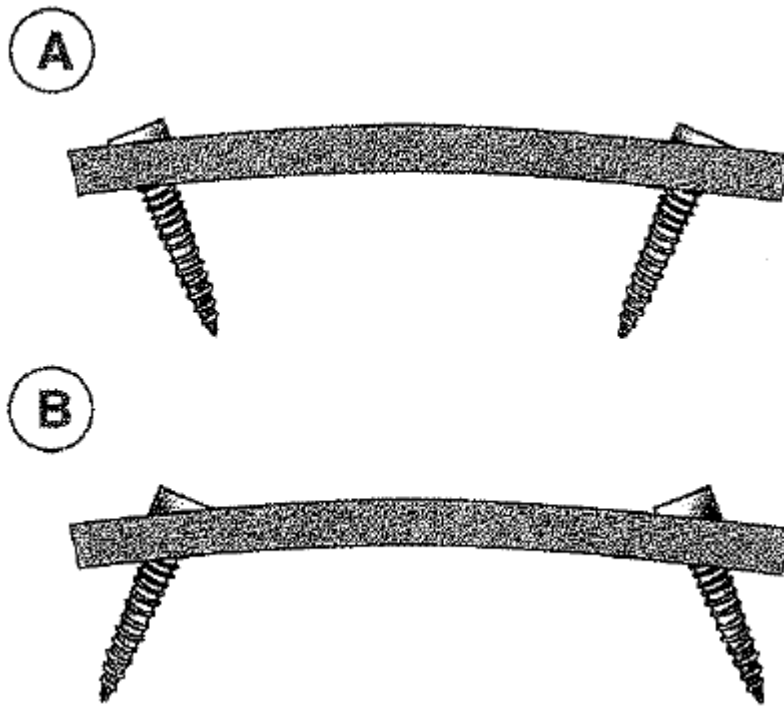
N.B. wider coronal angle is necessary to avoid lateral pedicle penetration in lower lumbar spine.

TRIANGULATION

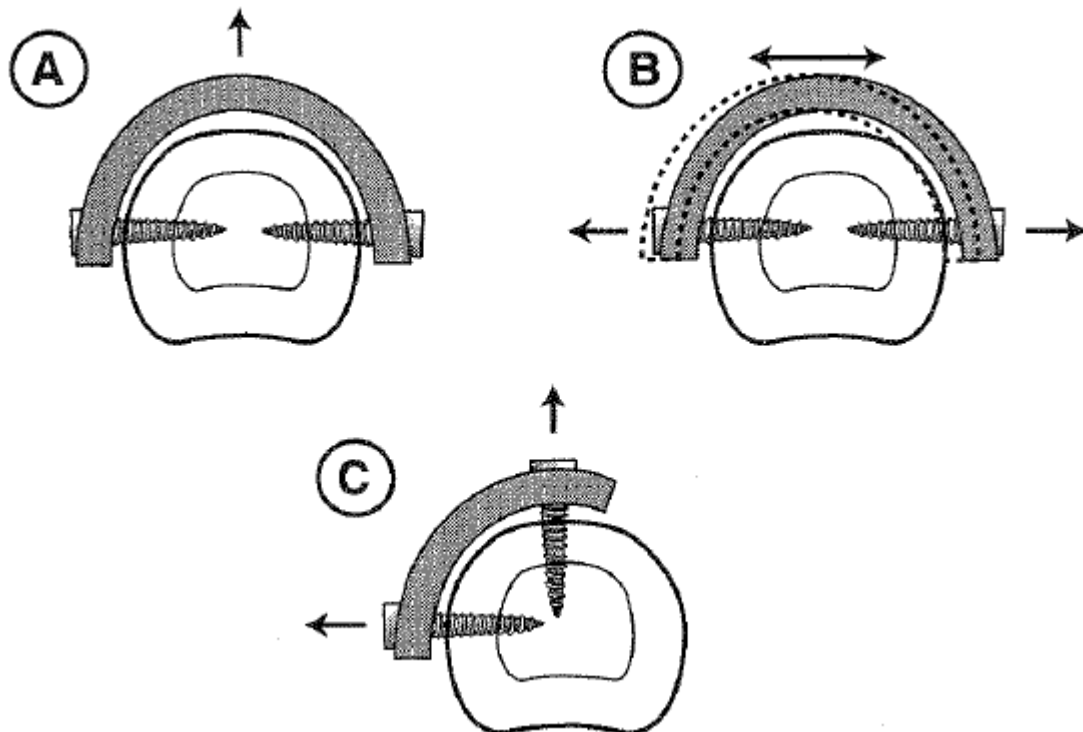
N.B. screws must be on same rigid implant (cross-fixed) for triangulation to work; triangulation works due to **bone mass included**, so to optimize it, need **longest screws** and **increase angle for triangulation** (optimal is 90 degrees):



Toed-in (A) and toed-out (B) screws:



Optimal orientation of screw for pullout resistance via triangulation effect is 180 degrees (A). This angle does not apply to loads applied along long axis of screw (B). Optimal triangulation effect that accommodates forces applied *in all planes* is 90 degrees (C).



DEPTH

- ideally 100% (on lateral fluoroscopy it seems as 50-80%; penetration > 80% of vertebral body on lateral X-ray raises concern of ventral penetration of vertebral body cortex)
- for sacrum it is OK bicortical (screw tip barely penetrates promontory).

TAPPING

Use 1 mm smaller taps than planned screw diameter! (e.g. 5.5 mm for lumbar pedicles, 6.5 mm for S1 pedicles)

Two characteristics of screw tap are fundamental:

- 1) **tapered tip** - helps to align screw in desired direction by directing it down predrilled hole
- 2) **full-length flute** - gathers bone debris carved from wall of drill hole (facilitated by periodic loosening of screw by approximate one quarter to one half turn during tightening, which allows bone debris to collect in flute):

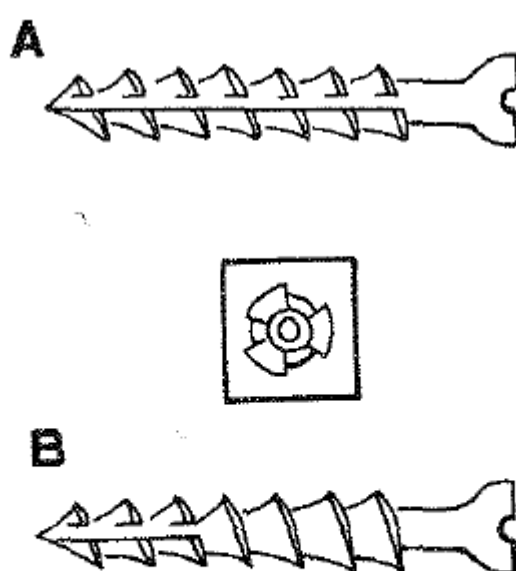


FIGURE 13-10 ■ A screw tap (A). Note the tapered tip and the full-length flute. A self-tapping screw (B). Note the leading-edge flute that does not extend the length of the screw. *Inset*: An end-on view of the tip.

Tips - in cancellous bone, tapping weakens implant-bone interface:

- tapping decreases pullout resistance in **osteoporotic bone**.
- do not tap **vertebral body (cancellous bone)** – tap only pedicle (ideally carves threads inside cortical bone but in practice pedicle screws rarely obtain cortical purchase within pedicle).
N.B. tapping of pedicle screw holes is of questionable value, however, in cortical bone, bone microcracking around screw threads is greater with untapped than with tapped screws - **untapped screws loosen more frequently than tapped screws** - tapping is desirable in cortical bone (e.g. sclerotic pedicle).
- for sacrum if planning bicortical, make sure, when approaching anterior (beak) cortex that tap is advancing (tap tip may hit hard cortex with increased resistance – if will keep spinning tap, it will strip!!!)
- if pedicle is very sclerotic, screw (normally, 1 mm larger diameter than tap) may break pedicle; H: tap such pedicle with same diameter as screw (but only for pedicle part; cancellous bone of vertebral body is still tapped with 1 mm less diameter tap).

STIMULATION

- stimulate pedicle screws up to 30 mA (if cortical bone is intact, EMG response should occur at > 14 mA; threshold to suspect breach is **6 mA**).
- setup free running EMG with NIM – for muscles see above >>

FUSION

- posterolateral gutters are sharply decorticated to see bleeding cancellous bone (i.e. before placing screws – will be difficult to reach then)
 - if redo case (fusion extension), then decorticate also superior and lateral aspects of previous bony fusion mass.
 - a drill bur should be of cutting design rather than a diamond - copious irrigation should be employed while drilling to prevent scorching temperatures, which may inhibit bony fusion.
- multiangle screws are placed.
- rods are used to connect pedicle screws.
- place set screws (locking caps) with “stick”* instrument then tighten with final tightener
*lets only finger tightening – prevents cross-threading
- final tighten
N.B. if operating for fracture – tighten central caps (over the fracture) last – minimizes stress of tightening on fractured segment
- fluoroscopy *see below*
- irrigate
- pack posterolateral gutters with morcellized bone grafts (\pm wrapped into) BMP, Medtronic MagniFuse. *see p. Op140 >>*
- may place DuraGen on exposed dura – to make dural scar smooth.

RODS

- cobalt-chromium** – stiffer (use for spondylolisthesis, scoliosis reduction, osteoporosis)
 - titanium**
 - PEEK** – flexible
- for long constructs, use rod cross link (head-to-head, rod-to-rod).
 - instrumentations along junctions (occ-C, C-T) tend to break rods - some people place 3 or even 5 rods.
 - if it is mandatory to cut the rods to a more specific length, rod cutting should be done at a distance from the operative range (hold both ends so they don't fly dangerously); smoothen rod ends (e.g. with drill) so non-sharp edge remains on the rod.

ROD CONTOURING

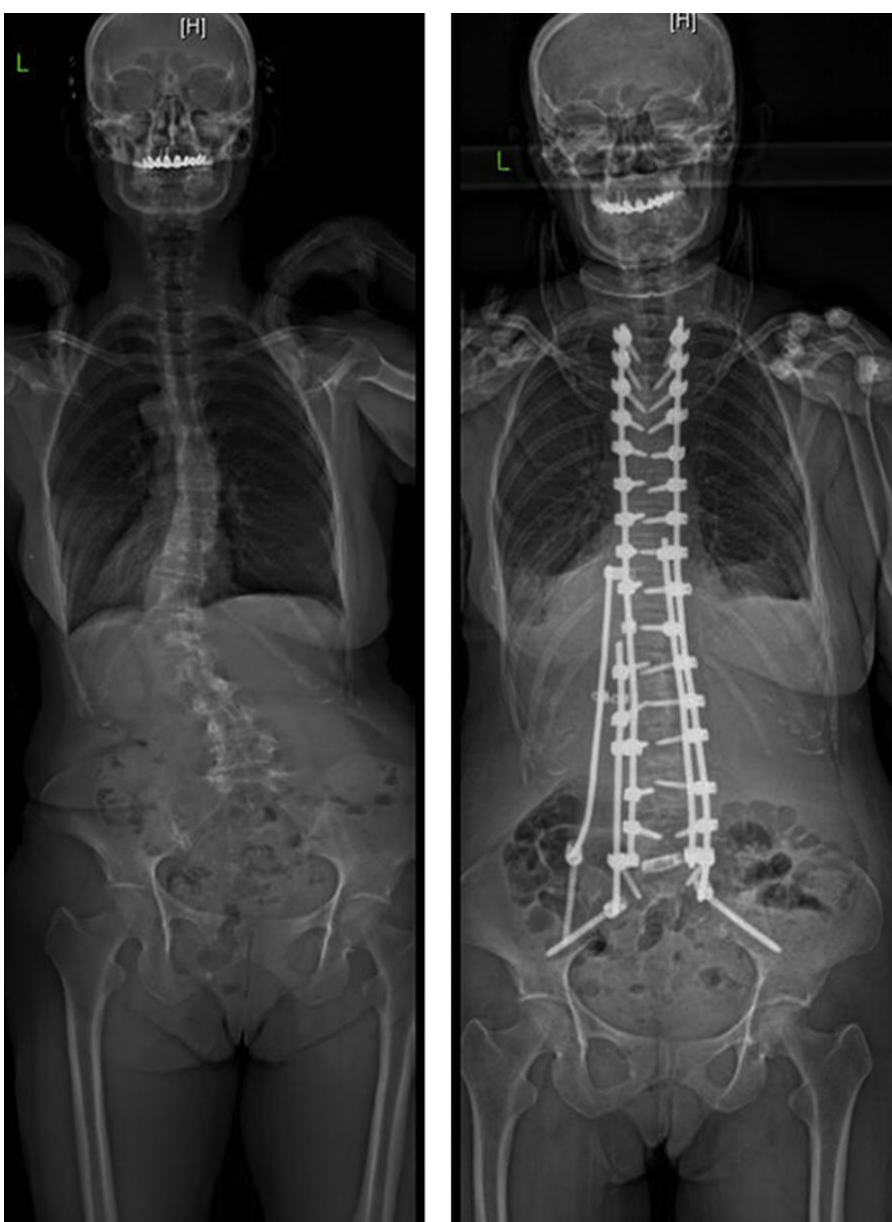- do not bend rod in coronal plane!
- rods should be bent in only **one direction, one time**, at an angle **max 15°** at the same point of location.

OUTRIGGER (QUAD) RODS

- added medially or laterally to main rods.
- outrigger rods may capture screws that main rods may not due to severe deformity.
- indications – poor bone quality, extensive osteotomies, rod extensions (to bridge old and new rod junction)
- use *side-to-side connectors* on existing rods and *dual-headed screws* >>

KICKSTAND ROD

- a supplement to quad-rods in coronal deformity (laterolisthesis) surgery:



REDUCING SPONDYLOLISTHESIS

Also see above >>

- check if there is mobility at the level.
- use cobalt-chromium rod.
- counter-lever technique: place and final tighten cap to lock rod into lower screw (rods sits pride – away from upper screw seat – distance depends how much reduction one is expecting).
- using tower, pull upper screw towards rod (do both sides simultaneously while checking on fluoro – do not strip screws if reduction is not progressing), engage set screws, then final tighten (to finalize reduction).

FLUOROSCOPY

- **lateral** view during the case
- **AP** view at the end – to check for:
 - 1) too *lateral* placement – main goal of AP
 - 2) too *medial* placement – screws should not be crossing
- **Dr. Graham** uses no fluoro (XR only final – lateral and AP to document screw placement).

FUSION REVISION / EXTENSION

Quad (outrigger) rods – *see >>*

Dual-headed screws – *see >>*

- never stop at thoracolumbar junction (ie. L1) – extend fusion to T10-11; next level – T4, then C2.
- to extend previous fusion – depends on status of fusion below:
 - a) **solid fusion** - use **rod-to-rod connectors** to attach to old rods; need at least 1 cm between screw heads to attach connector (loosening set screws may help to move heads apart to gain some width).
 - b) **poor fusion** - **remove old rods** (\pm pedicle screws – if suspicion for being loose) and place longer rods.

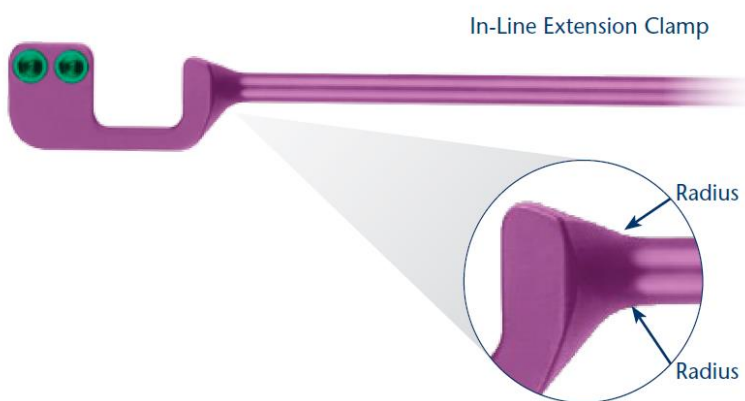
(ROD) CONNECTORS

Medtronic Domino

End-to-end – span 22 mm total (in lower thoracic, lumbar – enough space may place between screws; in upper thoracic – may need to skip one screw)
Side-to-side

Globus Revere Addition system - *see >>*

So called Z-rods or **Rescue® Implants**:




In-Line Extension Clamp

- Attach to existing Globus' REVERE®, CREO® BEACON®, or PROTEX® hardware
- Provide direct in-line coupling
- Integrated rod for stabilization
- Easier access to tighter areas (ideal for smaller stature patients)

The Strength is in the Radius

The critical junction where the rod meets the clamp (the radius) is mechanically stronger than a typical revision connector.



Offset Extension Clamps

- Attaches to existing REVERE®, CREO®, BEACON® or PROTEX® hardware
- Provides 7mm offset coupling
- Integrated rod for extension




"U" Extension Clamps

- Shorter run-on-rod with built-in lordotic curve
- Especially good for lumbar connections
- Offsets medially or laterally depending upon anatomical requirements
- Integrated rod

"Y" Clamps

- Shorter run-on-rod on each side of the screw
- Offsets medially or laterally, to meet anatomical requirements



<p>Length on rod:</p> <p>Single set screw – 11 mm?</p> <p>Double set screw – 15 mm?</p>	 <p>Parallel Connector Clamps</p> <p>Rod-to-Rod Clamps</p>
--	--

Globus Creo Addition system



COMPLICATIONS

- screw misplacement.
Accuracy of screw placement is assessed using **Gertzbein-Robbins scale** (grade A – perfect screw).
- **screw breakage** - has been reported as high as 60%
- **fusion failure** – risk factors:
 - 4) multilevel fusion (esp. > 3 disc levels)
 - 5) allograft (vs. autograft), esp. for > 1 level fusion
 - 6) long-term smokers
 - 7) diabetes
 - 8) long-term steroid use

POSTOPERATIVE

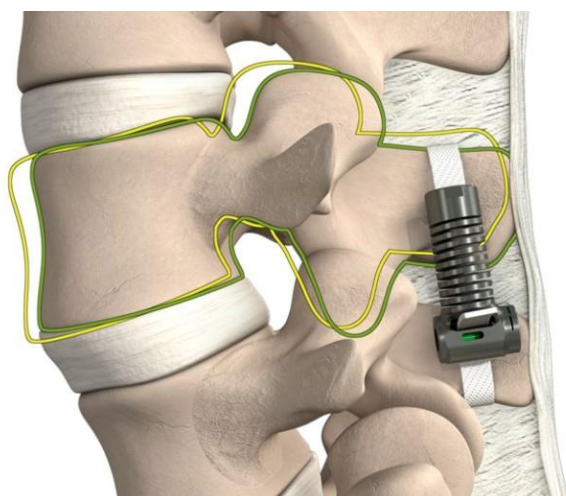
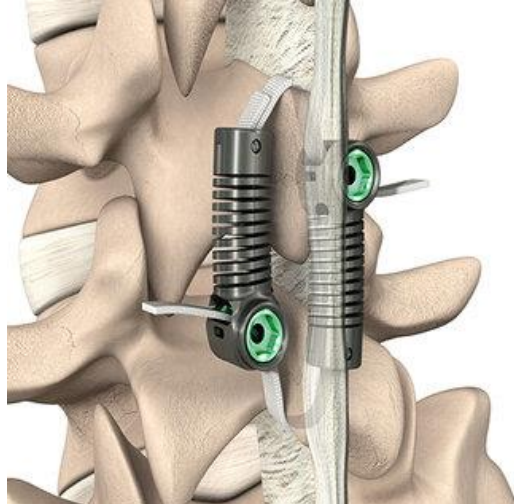
Dr. Cameron – upright XR before patient leaves hospital.

DYNAMIC STABILIZATION

- “flexible fusion”, dynamic stabilization without arthrodesis.

LIMIFLEX (EMPIRICAL SPINE)

- Dynamic Sagittal Tether



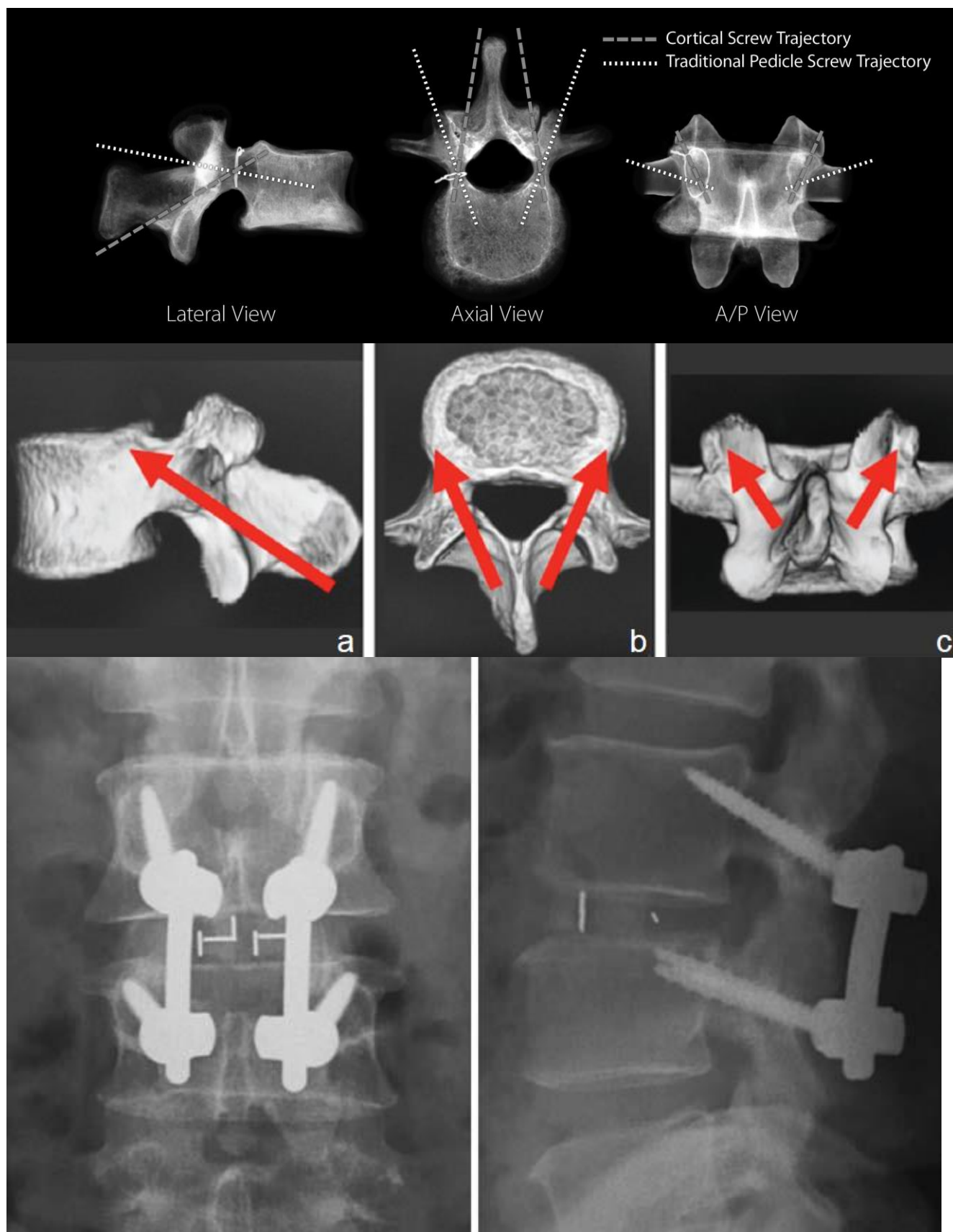
DYNESYS (ZIMMER BIOMET)

Dynesys® Dynamic Stabilization Product Family (LIS, Top-Loading, & Zimmer® DTO®)

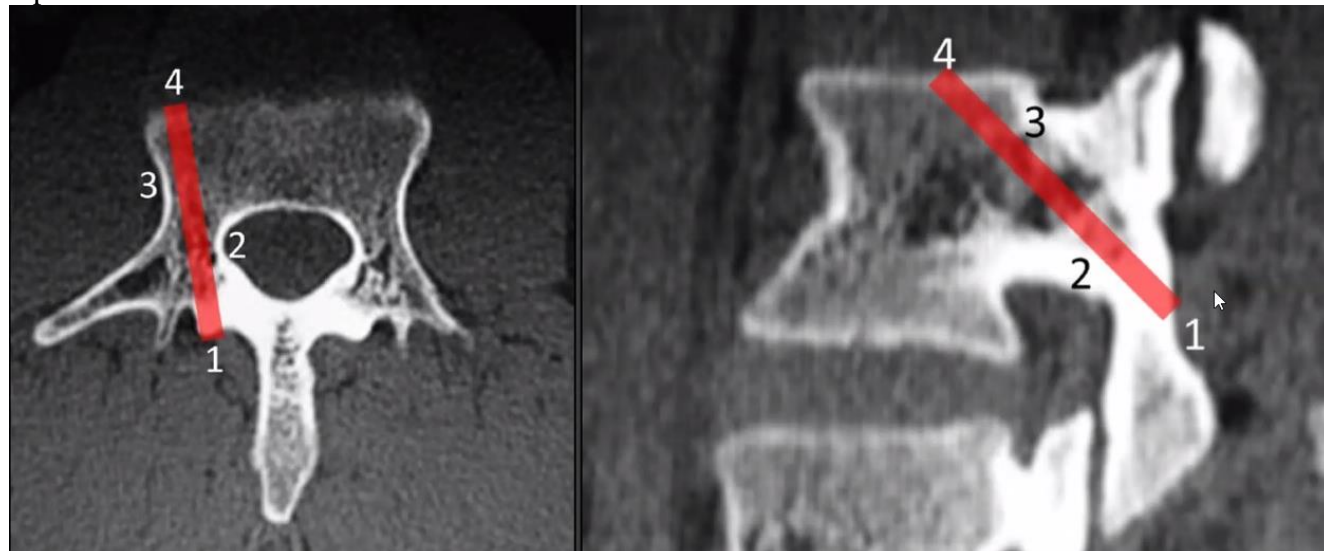


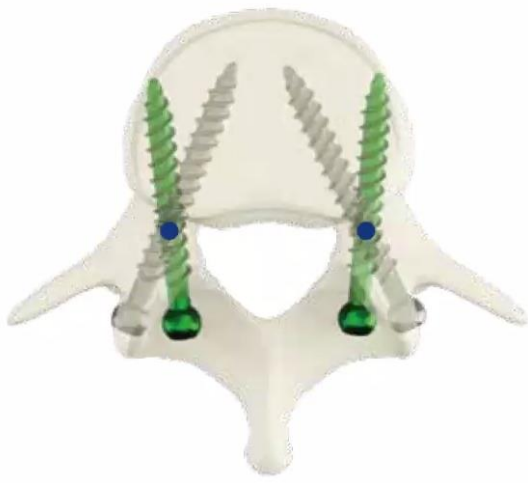- holds the segments in a more natural anatomic position using non-rigid materials.
- preserves natural anatomical structures as much as possible.
- constrains spinal motion ("internal splint").

MIDLIF (S. MIDLINE LUMBAR FUSION WITH CORTICAL BONE TRAJECTORY)



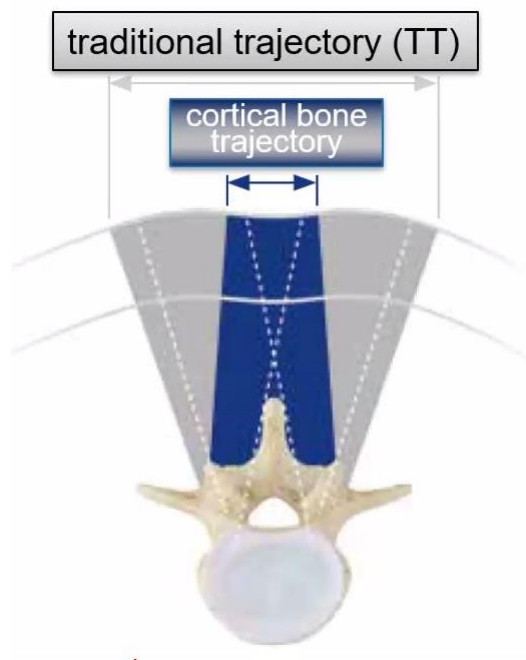
4 points of contact:





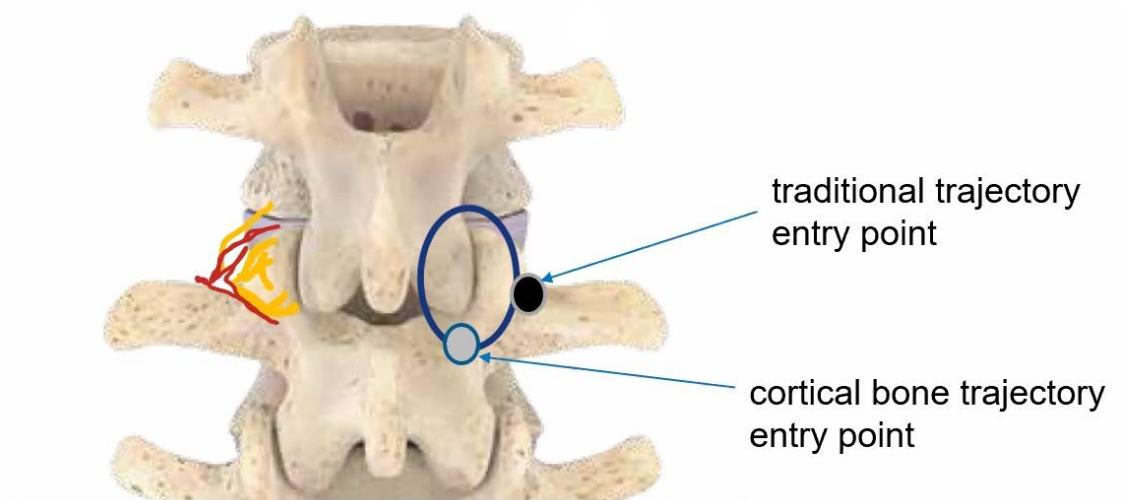
Improved bone purchase vs. conventional technique:

- Reduced screw loosening **-69%**^[9]
- Significantly increase in pull-out resistance **+30%**^[9]
- Strong anteroposterior spondylolisthesis correction, **-83% slip**^[10]



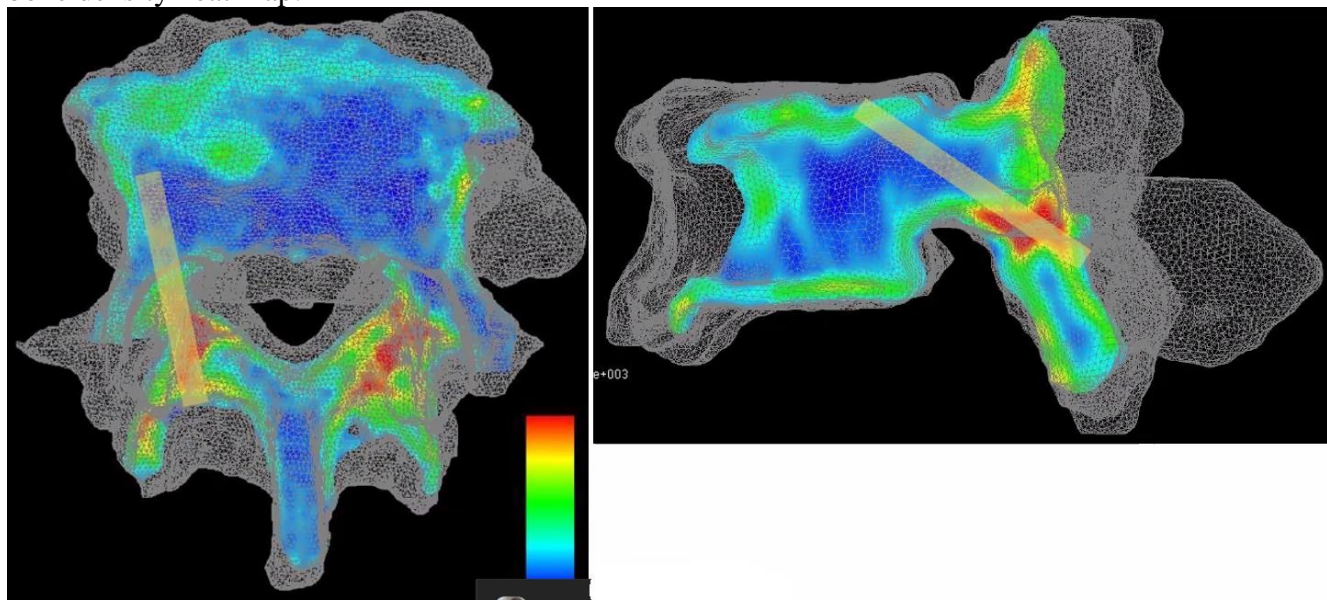
POTENTIAL FOR A LOWER ADJACENT SEGMENT DISEASE (ASD) VS. CONVENTIONAL TECHNIQUE^[2]

UP TO -71%

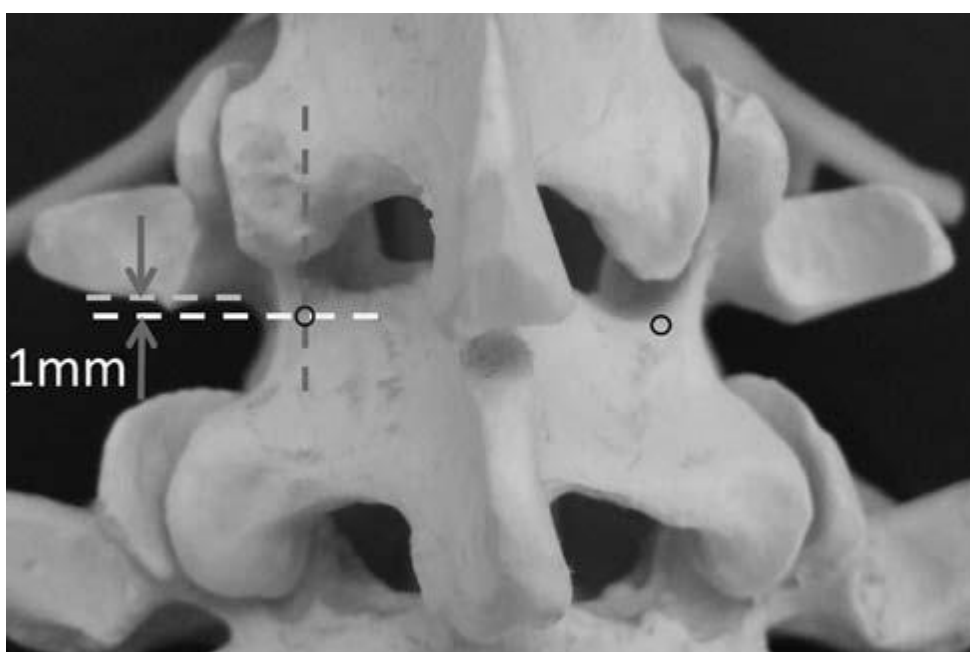


less coagulation near blood vessels / dorsal branch = less damage to the adjacent (cranial) segment)

- Cortical Bone Trajectory (CBT):
8-9° mediolateral
25-26° caudocephalad (more for top level as need to avoid facet joint; less for bottom level as incision doesn't allow to achieve angle)
- engaging with cortical bone maximally from pedicle to vertebral body, i.e. **increased cortical bone contact**, providing enhanced screw purchase (up to 30% increased pullout strength but it is unproven) – some experts believe it is better for elderly osteoporotic spine (with age, vertebral body bone marrow becomes porotic, but pedicle & periarticular bone becomes sclerotic).
- bone density heat map:



- best for L2-5
- screws:
smaller diameter than would be analogous level pedicle screws.
length is 30-39 mm.
- indications:
1) rescue when pedicle was destroyed
2) adjacent level disease (may leave old hardware in untouched)
- screw insertion through medial starting point enables **less tissue dissection** and retraction for reduced muscle disruption – expose as for laminectomy
- direction away from neural elements provides **safety** and lower incidence of postoperative radiculitis.
- starting point - junction of center of superior articular process and 1 mm inferior to inferior border of transverse process:



N.B. best is to use AP fluoro or CT-based navigation – starting point is at 5 o'clock for L side (and 7 o'clock for R side); therefore, important to do AP fluoro before* even incision – if cannot see pedicles, won't be able to do MIDLF!

*probably not as it is easy to convert to regular pedicle screws intraop

- mark with M8 drill bit all **starting points** on **AP fluoroscopy**; then create **trajectories** using monitored Stryker power drill using **lateral fluoroscopy**.
 - often starting points need to be adjusted as they don't look right on lateral fluoro; so AP fluoro value is mostly to define medial-lateral line of starting point.
 - some experts say that tapping is a must (triple tapping – e.g. with 4 mm then 5 mm then 6 mm taps).

N.B. make trajectory holes before laminectomy; then laminectomy, PLIF, etc; place screws at the end.

PLIF (POSTERIOR LUMBAR INTERBODY FUSION)

Used resources:

Jandial - Procedure 73

AANS video (MAST PLIF): <http://www.neurosurgicalatlas.com/grand-rounds/sagittal-imbalance-and-minimally-invasive-spine-surgery>

INDICATIONS

1. **Spondylolisthesis** (symptomatic, progressive, or requiring decompression that necessitates stabilization)
 2. Correction of degenerative **scoliosis**
 3. **Pseudarthrosis** of previous posterior fusion that requires fusion technique with higher success at achieving solid arthrodesis
 4. Degenerative disk disease with **low back pain** that can benefit from fusion
 5. **Recurrent disk herniation**
- for long fusions (thoracic-sacrum) always add L(4)5-S1 interbodies! (Dr. Lenke)

CONTRAINDICATIONS

1. **Osteoporotic** end plates that may not hold interbody graft, leading to **subsidence**
2. Disease at or above **conus medullaris** → TLIF should be considered to avoid thecal sac retraction.

TECHNIQUE

POSITION

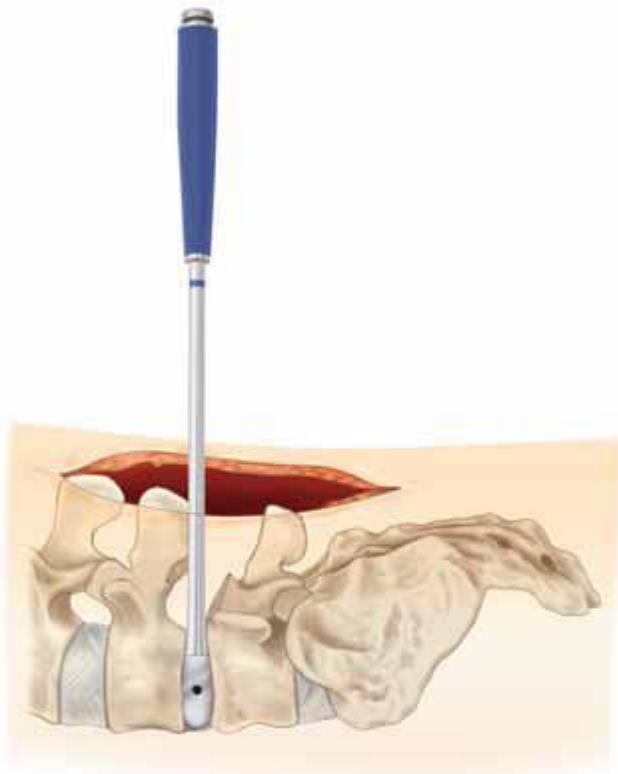
- a) Jackson table – often makes spondylolisthesis to reduce
- b) chest rolls – longitudinal or transverse (more lordosis)
- c) Wilson frame (Dr. Graham)

MONITORING

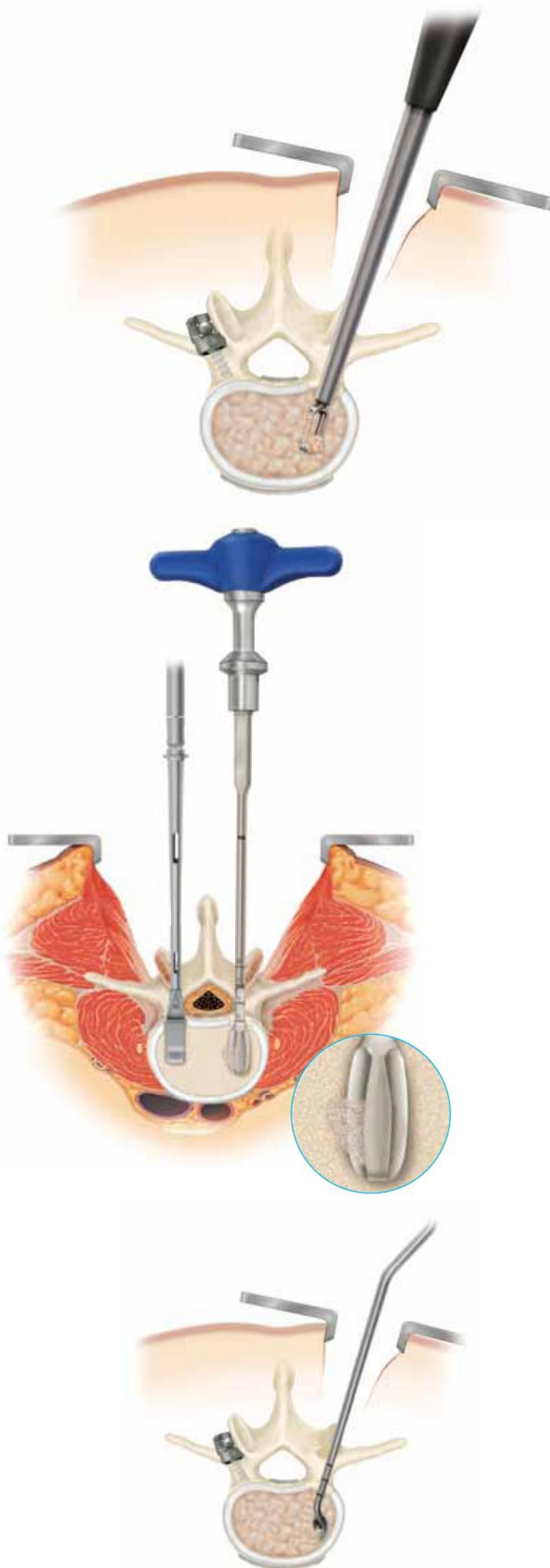
- neurophysiologic monitoring (incl. SSEPs and EMG) is routinely used (Dr. Cameron uses EMG)
- EMG:
 - 1) medial gastrocnemius (S1)
 - 2) EHL (L5)
 - 3) lateral vastus (L4)

DISK PREPARATION

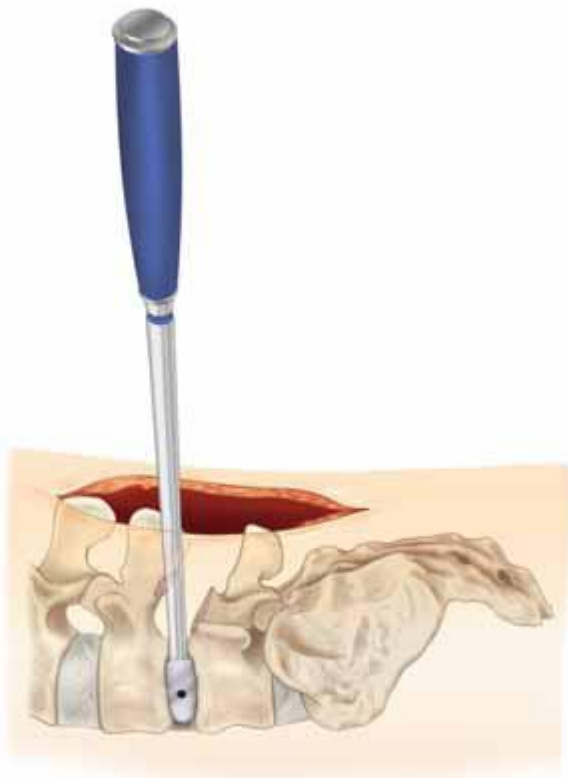
- expose disk space laterally – complete laminectomy, drill pars & medial facet as much as needed; removal of pars interarticularis with chisel (e.g. Smith-Peterson osteotomies or removal of Gill fragments) can be performed for greater exposure of nerve root and disk space + unroofing neural foramen + allows compression of screws / disk space
- perform annulotomies on both sides with No. 15 blade → clean with pituitary.
- thorough complete discectomy (**DRS**) thecal sac is carefully retracted with Love nerve root retractor:
 - 1) increasing sizes of **Distractors** (starting at 6-8 mm) under XR control (should reach anterior annulus)



- optional - insert supplemental pedicle screw and rod fixation on contralateral side to maintain distraction in situ during disc space preparation and to facilitate graft placement; provisionally tighten construct
- 2) **Rotating Cutters or Shavers** (1-2 mm smaller than planned graft - to preserve endplates) to remove cartilaginous end plate (remove end plate fragments with pituitary rongeurs) → **"paw" curettes** to remove cartilaginous end plate



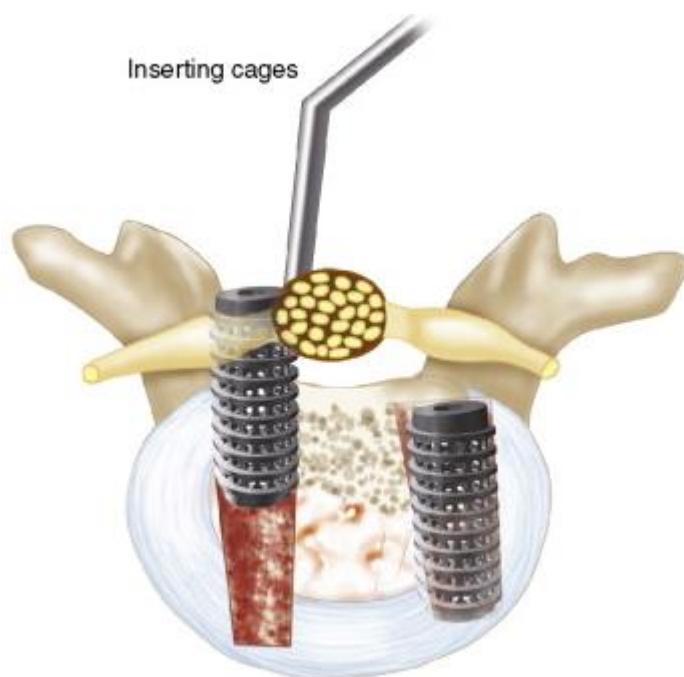
- 3) Trial with **Sizers**.



- use A/P and lateral fluoroscopy to confirm proper placement and trajectory

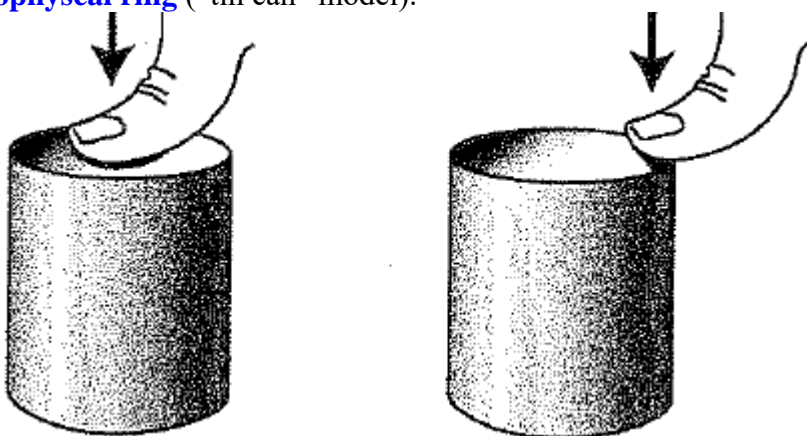
GRAFTS / CAGES

- PEEK**; put some BMP inside graft and between grafts (anteromedially); cage is impacted into disk space until 3 mm below posterior margin of annulus under fluoroscopic guidance; certain design nonexpandable cages need to rotate 90 degrees into final position (graft tends to back out during rotation, so push forward during rotation)
- cadaveric bone dowels** – 12 mm diameter for lumbar spine (**Dr. Graham**) trimmed to appropriate length – use increasing sizes of reamers from 7.5 mm to 10 mm, then scrape endplates with curettes; disk space filled medially with morcellized laminar bone autografts; grafts gently impacted into disk space until 5 mm below posterior margin of annulus



- before inserting the graft, place autograft anteriorly and contralaterally or in the bone construct central cavity.
- mechanically, graft should extend as far anteriorly as safely possible.
- if grafts cannot be placed, bone autograft, allograft, or osteoinductive materials may be placed into disk space instead.
- interbody construct is supplemented by pedicle screws and intertransverse fusion.
- PLIF for spondylolisthesis - compress screws at the end - will create lordosis ± prevents graft migration posteriorly.

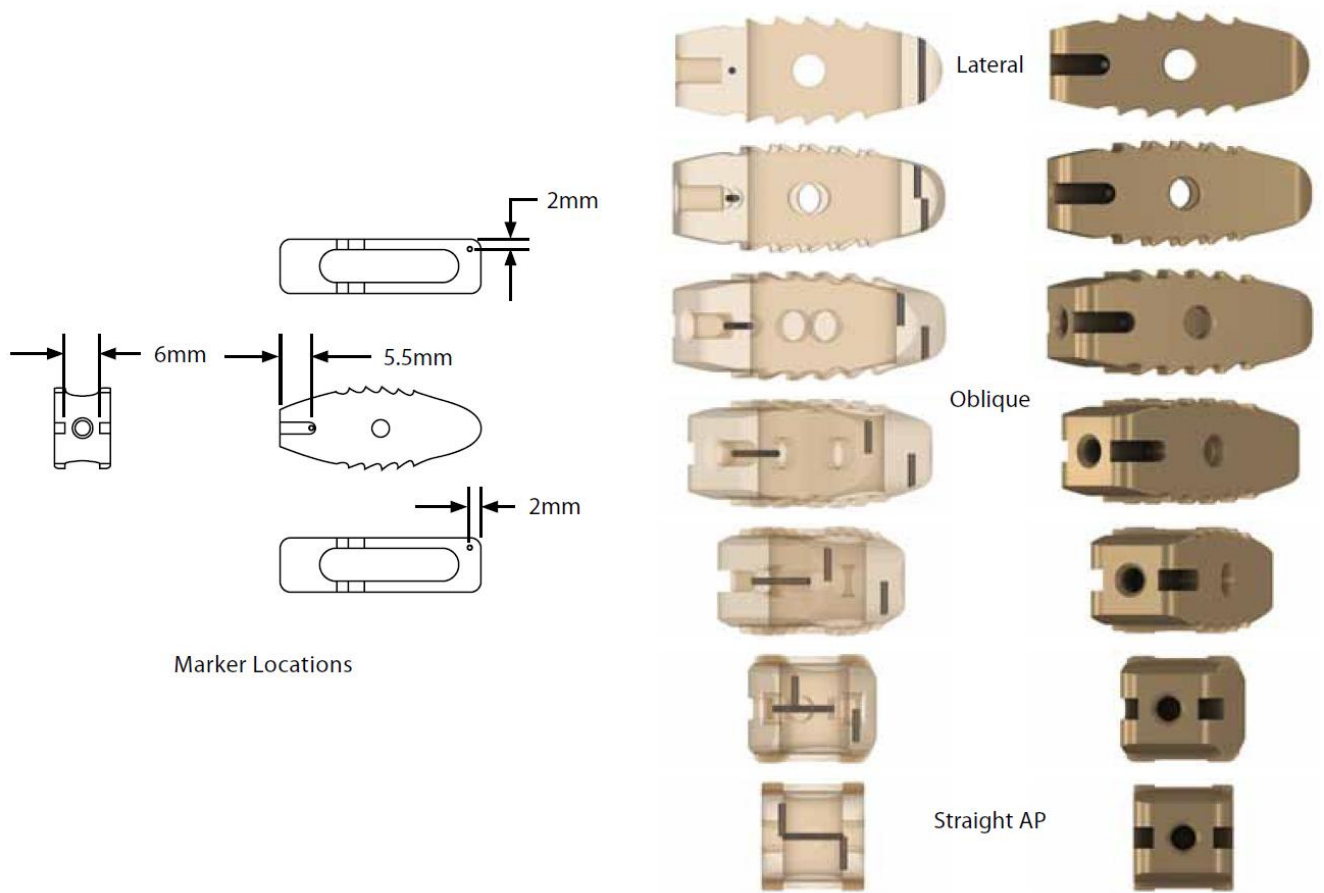
Ideally, graft should extend to vertebral body edges where resistance to compression is highest – **apophyseal ring** (“tin can” model):



CAPSTONE (MEDTRONIC)

Brochures >> and >>


[X-ray Marker Location](#)



WAVE D (MEDTRONIC)

Brochures >>

2975 USD



- bullet tip device with lordotic expansion of 6 and 12 degrees
- MAST® compatible
- ability to postpack device with autograft using funnel and tamp after expansion.
- radiolucency for postoperative diagnosis.
- audible click sound made when device is fully expanded.

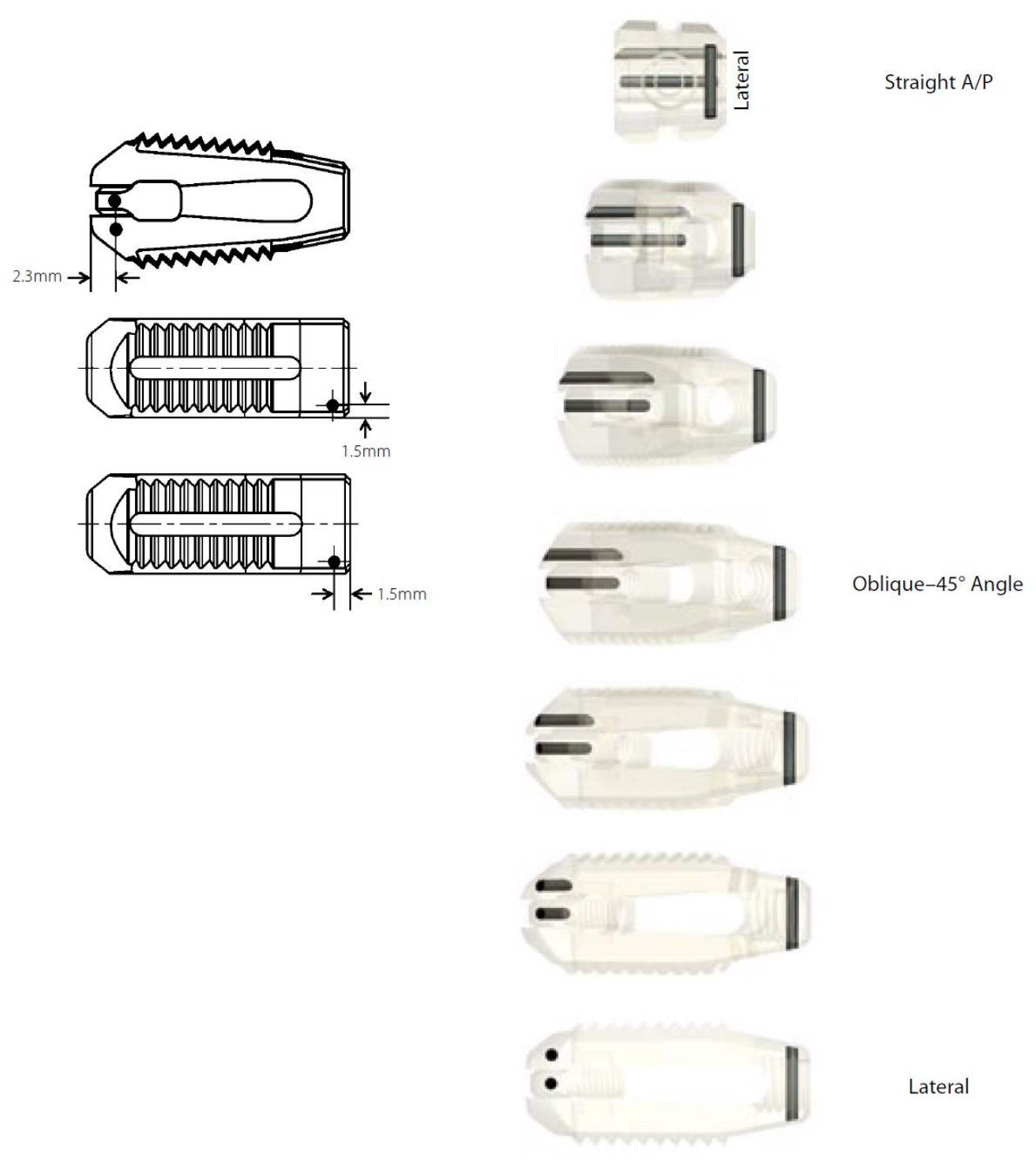
6° Options

AMT Part Number	Medtronic Part Number	Posterior Labeled Height (mm)	Anterior Unexpanded Height (mm)	Anterior Expanded Height (mm)	Lordosis (degrees)	Length (mm)	Surface Area (mm ²)	Autograft Volume (cc)
WD-09.24.6	2660924	9	7	11	6	24.5	319	.692
WD-10.24.6	2661024	10	8	12	6	24.5	319	.737
WD-11.24.6	2661124	11	9	13	6	24.5	319	.765
WD-12.24.6	2661224	12	10	14	6	24.5	319	.806

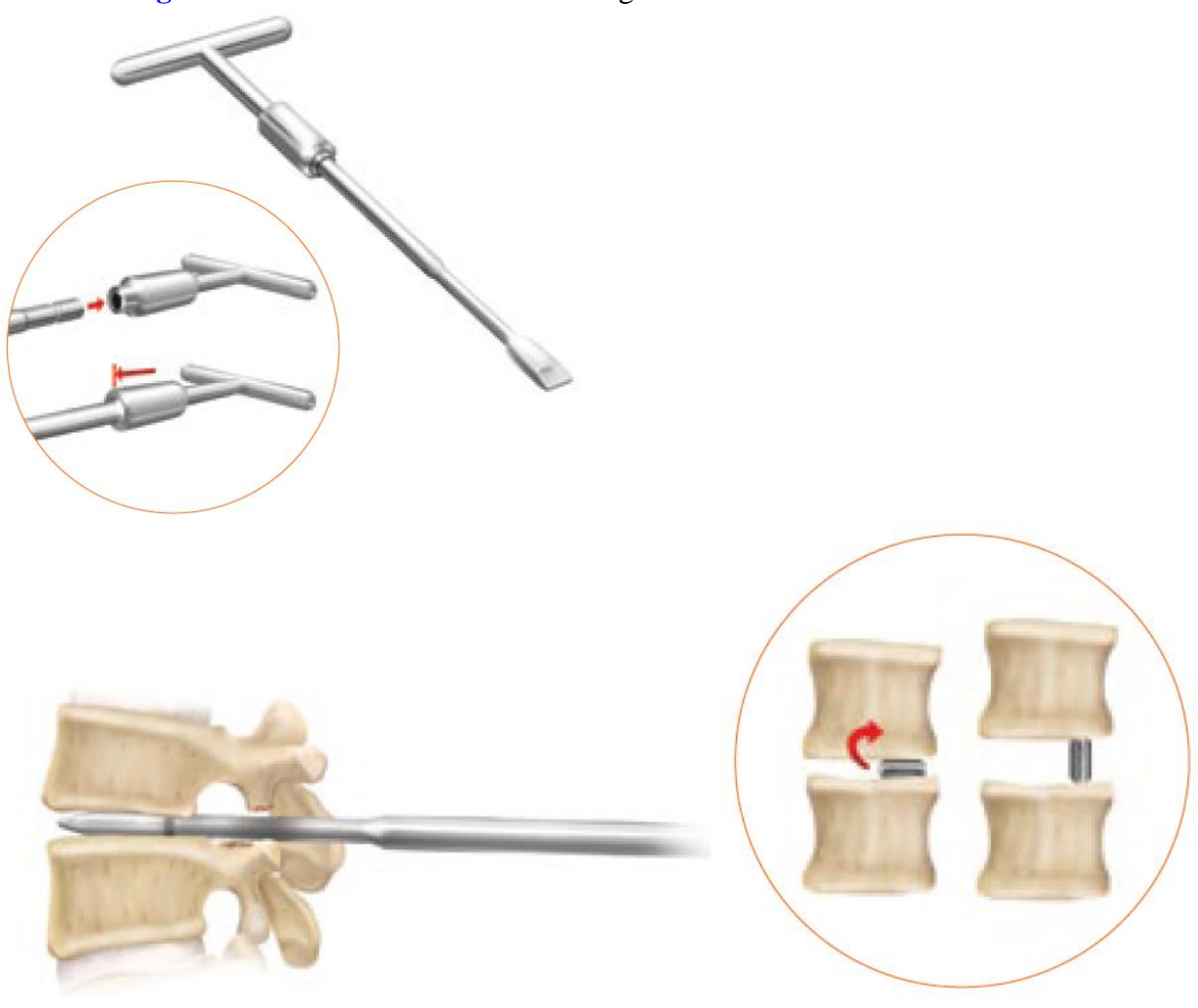
12° Options

AMT Part Number	Medtronic Part Number	Posterior Labeled Height (mm)	Anterior Unexpanded Height (mm)	Anterior Expanded Height (mm)	Lordosis (degrees)	Length (mm)	Surface Area (mm ²)	Autograft Volume (cc)
WD-09.24.12	2620924	9	9	12	12	24.5	319	.692
WD-10.24.12	2621024	10	10	13	12	24.5	319	.759
WD-11.24.12	2621124	11	11	14	12	24.5	319	.794
WD-12.24.12	2621224	12	12	15	12	24.5	319	.828

X-ray Marker Location



Use **Rotating Distractor** for distraction and sizing:



Fixation of the Cage on the Inserter:



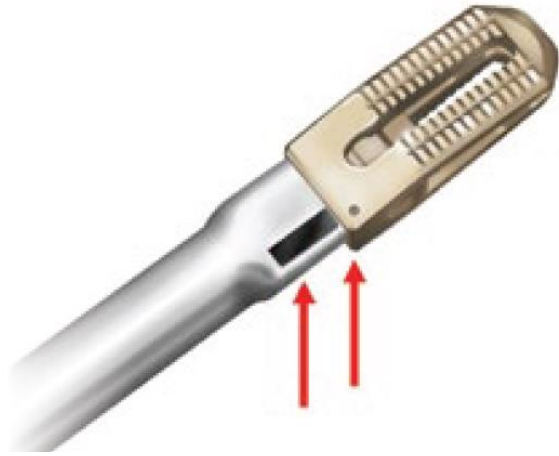
Figure 17

Fixation of the Cage on the Inserter

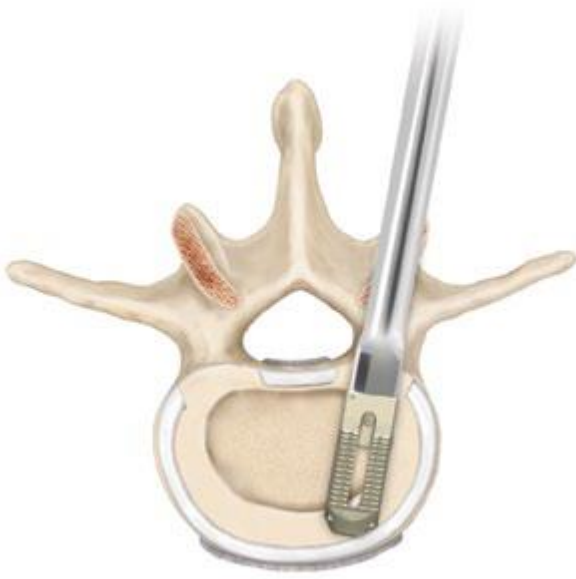Application of the Impactor Cap:



Marking for lateral side of the Cage:



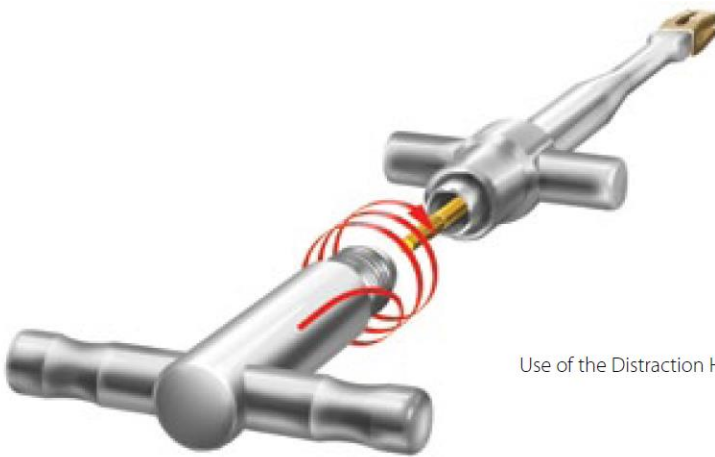
Advance the implant anteriorly so that the leading tip of the implant rests on the anterior apophyseal ring:



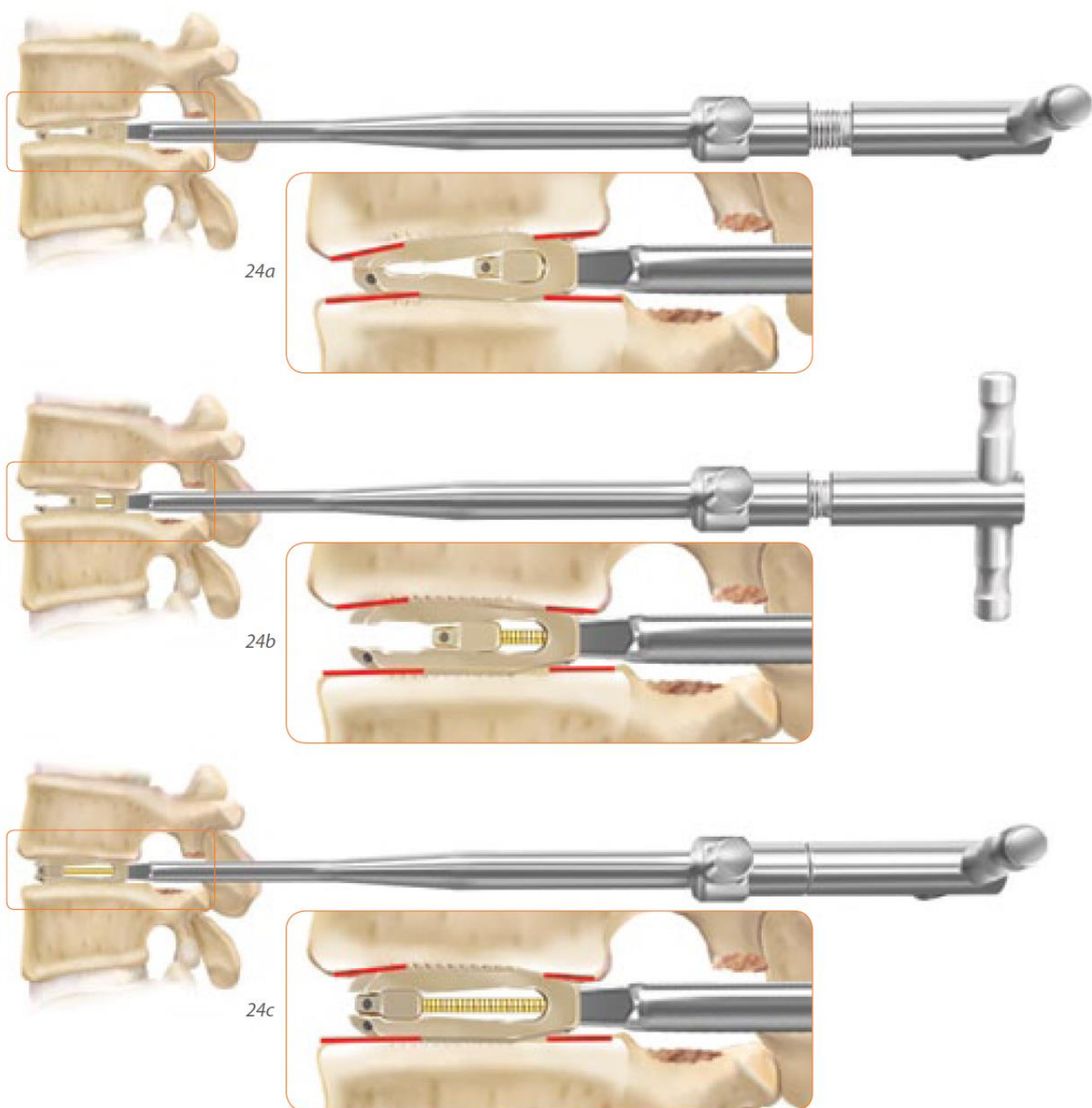
Remove the Impactor Cap after completed implantation and screw the Distraction Rod into the cage distraction plug:



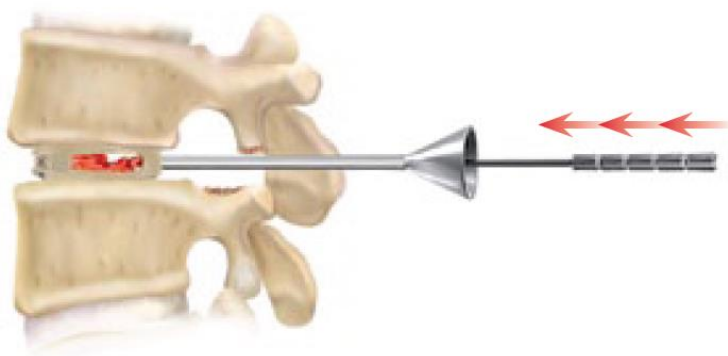
Distraction Rod (short)



Use of the Distraction Handle



Fill the disc space and the cage with autograft, BMP:



ELEVATE (MEDTRONIC)

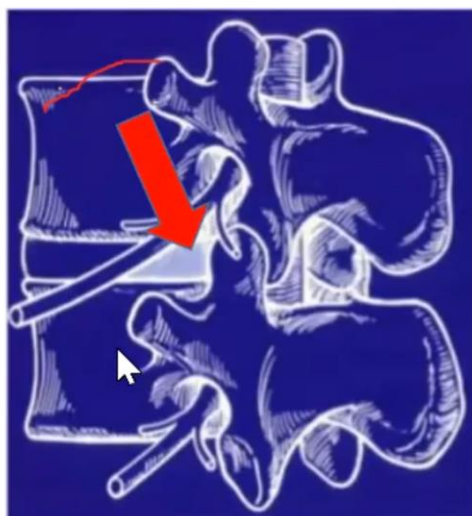
See below >>

TLIF (TRANSFORAMINAL LUMBAR INTERBODY FUSION)

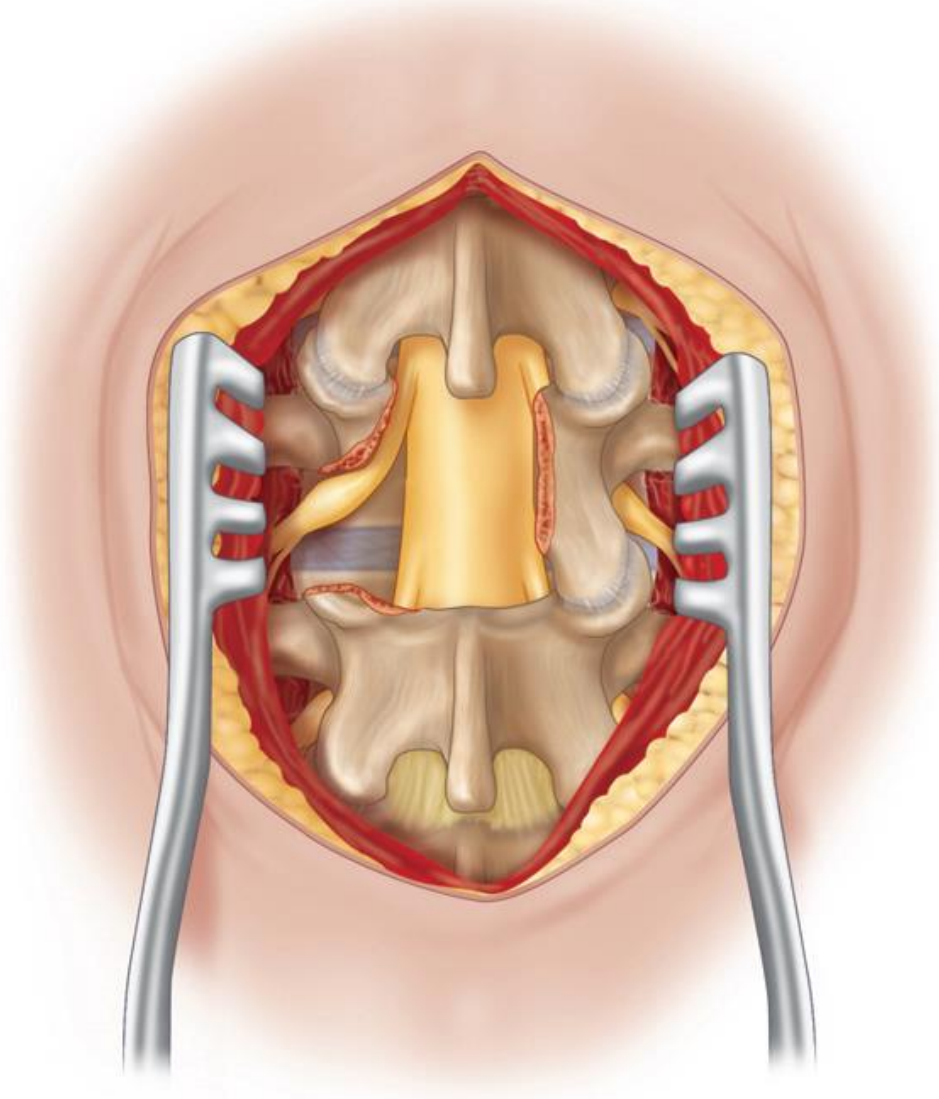
<http://www.neurosurgicalatlas.com/grand-rounds/transforaminal-lumbar-interbody-fusion-tlif>

- first described by Harms et al in 1982 and Jeszenszky in 1998.
- it is alternative to PLIF for lesions at or above conus medullaris because retraction of thecal sac is not an option; also advantageous in case with epidural scarring.
- cheaper than PLIF as uses one interbody cage.
- not feasible at L5-S1 (iliac crests); H: PLIF or ALIF

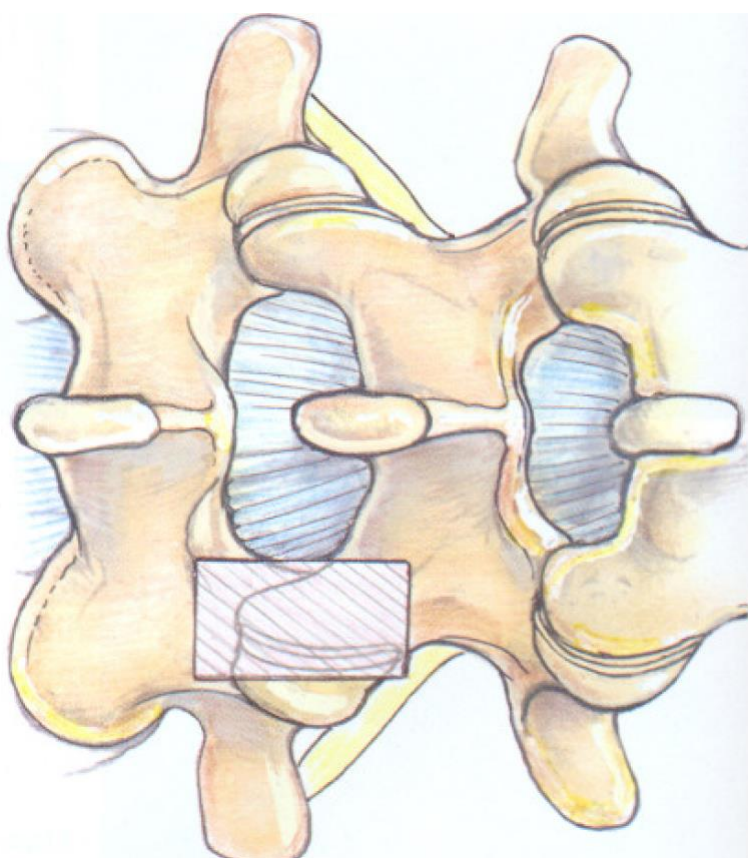
Kambins Triangle



- graft placed obliquely or, more recently, curved graft rotated into position.
- *removal of pars interarticularis, lamina, and inferior and superior articular processes:*

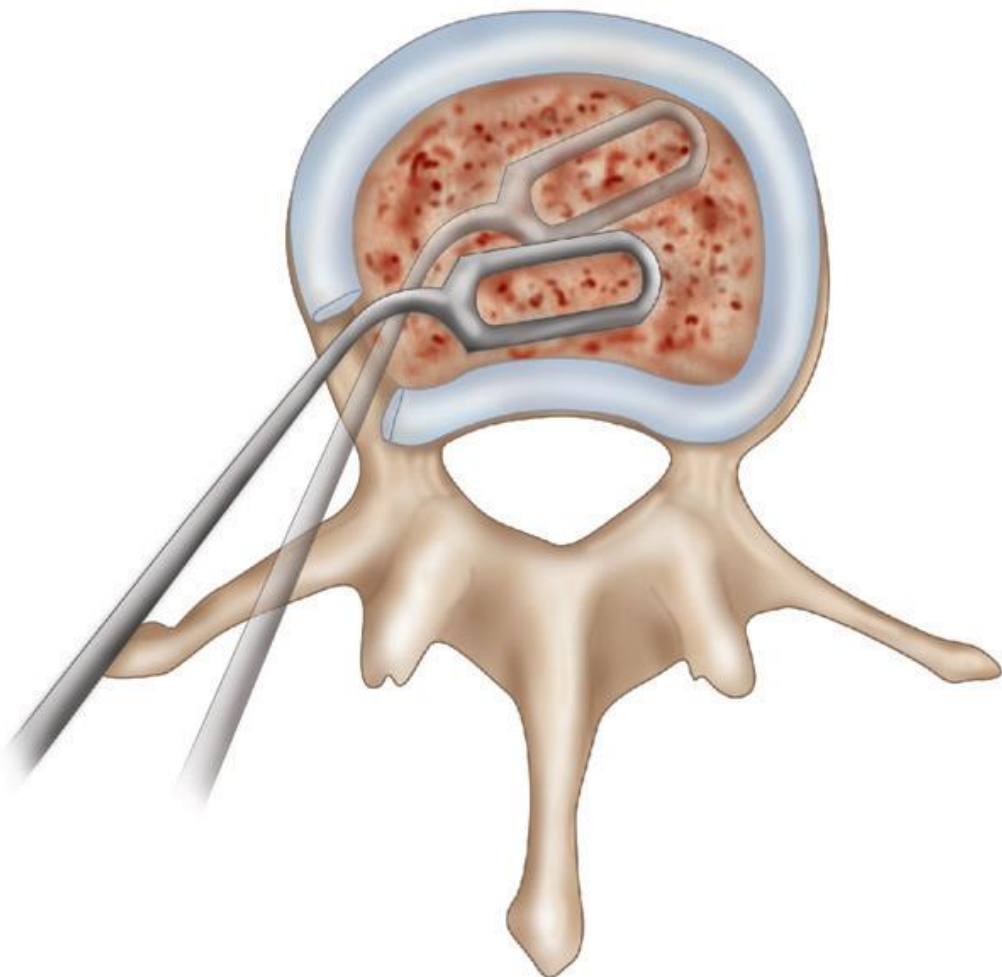


Source of picture: R. Jandial "Core Techniques in Operative Neurosurgery: Expert Consult - Online and Print", 1st ed (2011), Saunders; ISBN-13: 978-1437709070 >>



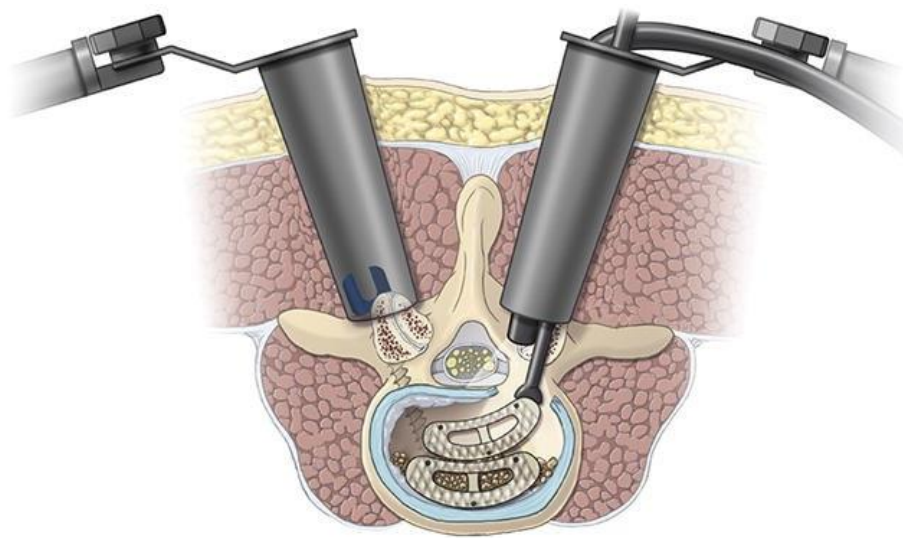
Source of picture: Richard Glenn Fessler, Laligam N. Sekhar "Atlas of Neurosurgical Techniques: Spine and Peripheral Nerves" (2006), ISBN-10: 0865779872, ISBN-13: 978-0865779877 >>

- radical discectomy is performed to cross midline and ensure that contralateral disk is removed:



Source of picture: R. Jandial "Core Techniques in Operative Neurosurgery: Expert Consult - Online and Print", 1st ed (2011), Saunders; ISBN-13: 978-1437709070 >>

- allows disc space to be accessed without need for nerve root retraction, but corridor that is created remains constrained by exiting and traversing roots - size of interbody graft is inherently limited; thus, amount of disc space covered is also limited → resurgence in bilateral access to place bilateral grafts; alternative – unilateral approach with sequential grafts (nested interbody spacers):



Source of picture: R. Jandial "Core Techniques in Operative Neurosurgery: Expert Consult - Online and Print", 1st ed (2011), Saunders; ISBN-13: 978-1437709070 >>

- goal is to place graft in **middle of disk space and as anterior as possible**
- if disk space is significantly collapsed, pedicle screws can be used with distraction retractors to heighten interbody space and enable larger graft placement.
- do on more symptomatic side – if will damage root, it is already worse side; on the other hand, it is greater chance of helping that side by better distraction.
- thoracic interbody grafts – no need to sacrifice nerve roots.

GRAFT / CAGES

Standard solid titanium (ST) vs 3D-printed porous titanium (3DPT) cages

Nathaniel Toop et al. Subsidence Rates Associated With Porous 3D-Printed Versus Solid Titanium Cages in Transforaminal Lumbar Interbody Fusion. Gblal Spine Journal. First published online February 14, 2023

- ST are associated with higher **rates of subsidence** - 24.4% vs 5.5% (p=0.001).
- ST group was more likely to have **higher grades of subsidence** than the 3DPT group (p=0.009).
- **patient reported outcome measures** improved similarly after surgery
- **revision rates** did not differ between groups (both p>0.05).

GLOBUS PORTFOLIO

<https://www.globusmedical.com/solution/spine/posterior-lumbar/>

WAVE O (MEDTRONIC)

Brochures >>
WAVE O Spinal System Animation >>

ELEVATE (MEDTRONIC)

Brochures >>
3737 USD

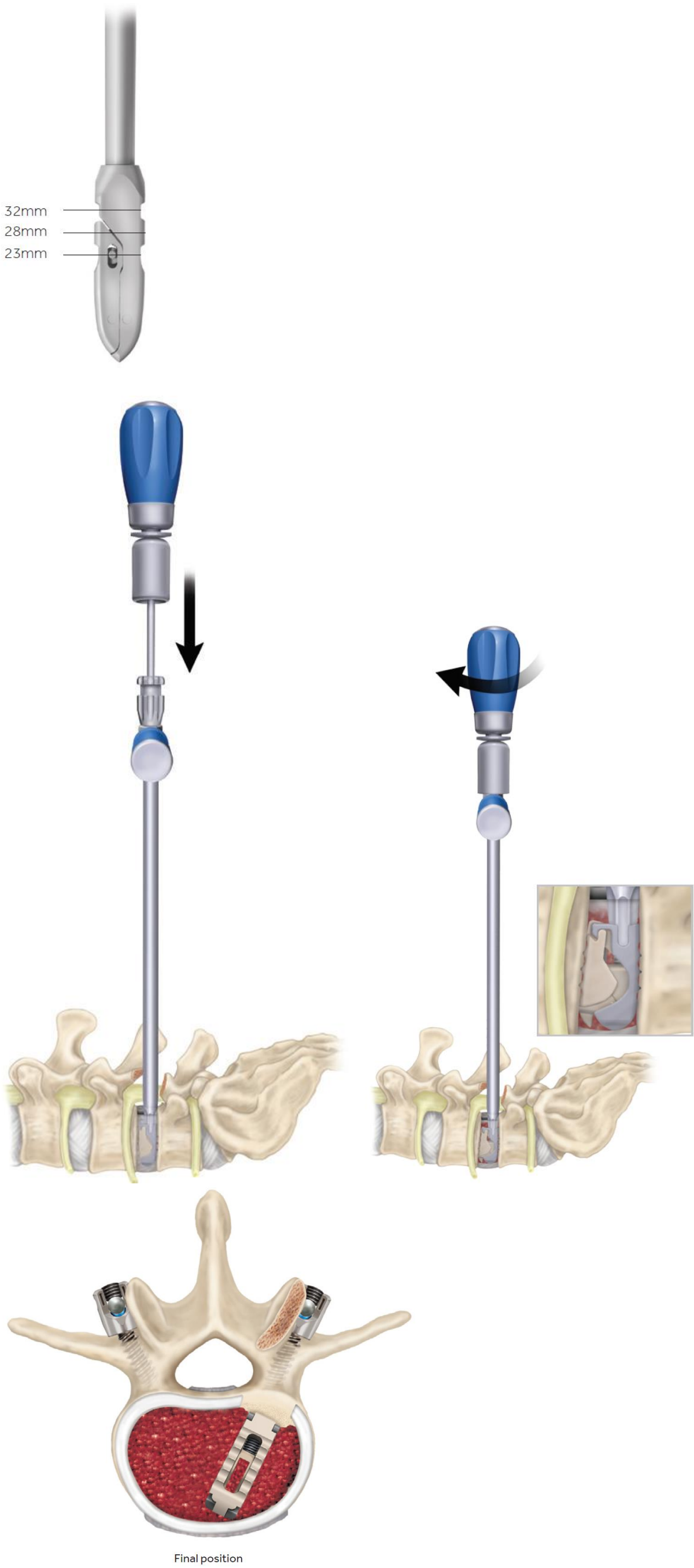


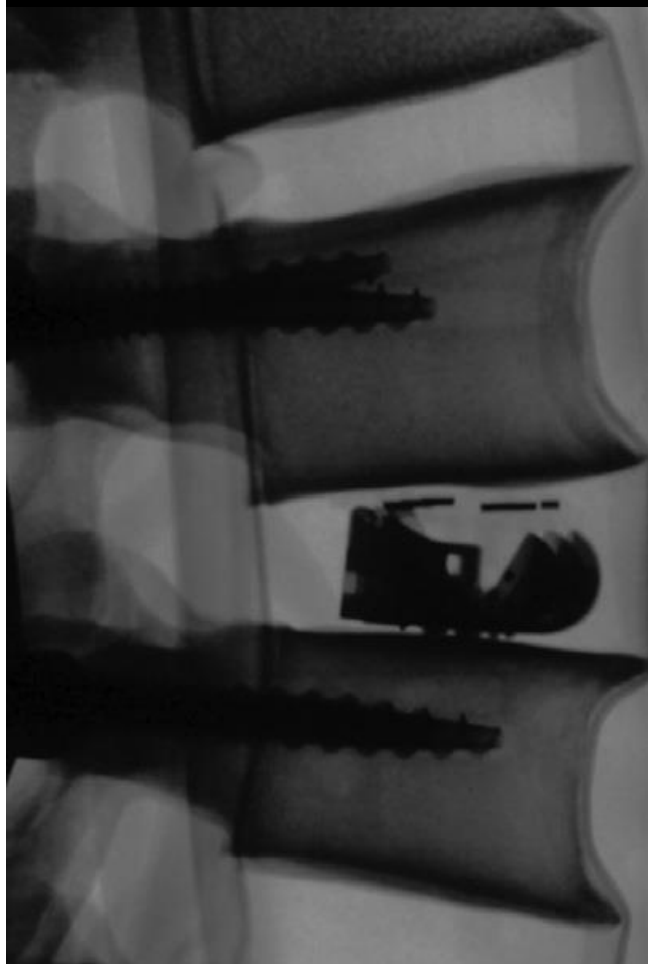
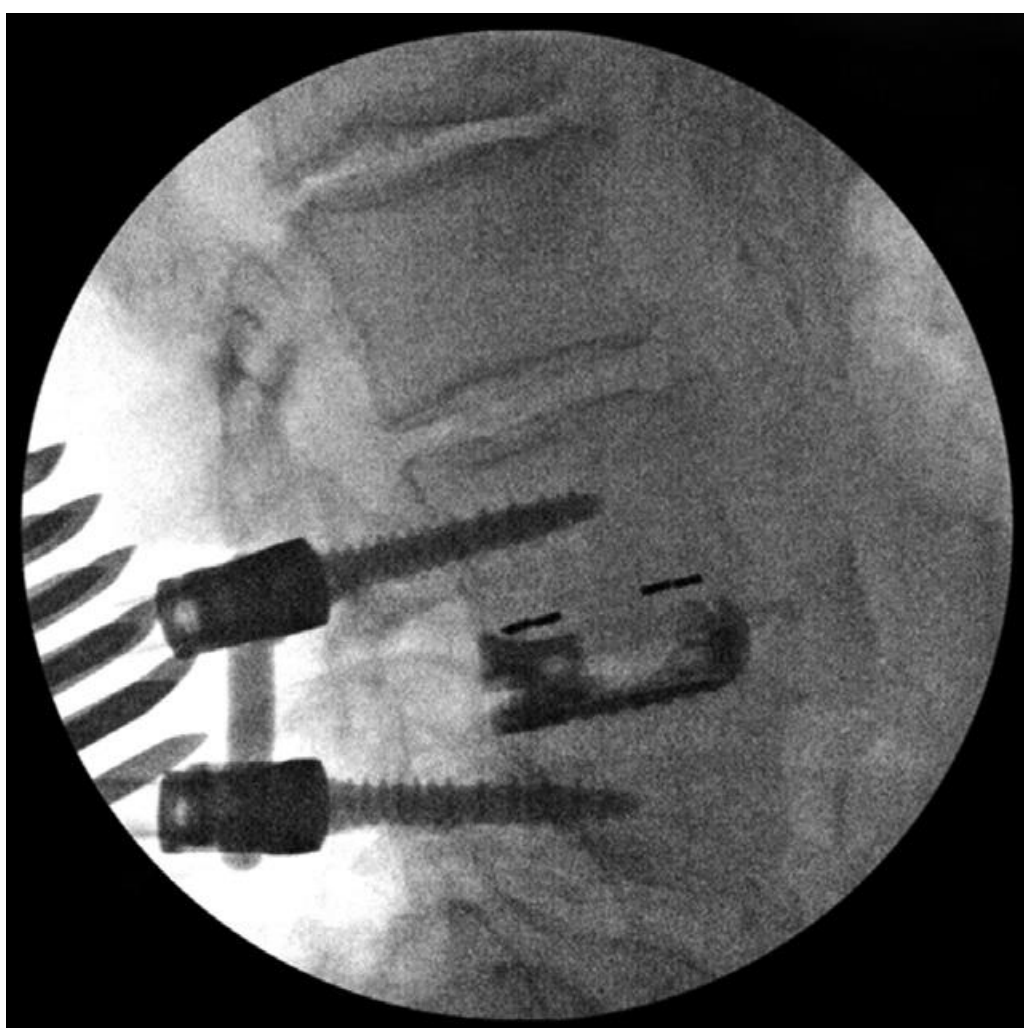
STANDARD IMPLANTS: Approximately 1mm of Posterior Expansion						
Starting Height (mm) - Anterior	Length 23		Length 28		Length 32	
	Max Expanded Anterior Height (mm)	Max Lordosis (deg.)	Max Expanded Anterior Height (mm)	Max Lordosis (deg.)	Max Expanded Anterior Height (mm)	Max Lordosis (deg.)
Starting height 8mm	7770823 Elevate Standard 23 x 8mm		7770828 Elevate Standard 28 x 8mm		7770832 Elevate Standard 32 x 8mm	
	12	8	12	8	13	8
Starting height 9mm	7770923 Elevate Standard 23 x 9mm		7770928 Elevate Standard 28 x 9mm		7770932 Elevate Standard 32 x 9mm	
	13	8	13	8	14	8
Starting height 10mm	7771023 Elevate Standard 23 x 10mm		7771028 Elevate Standard 28 x 10mm		7771032 Elevate Standard 32 x 10mm	
	14	8	14	8	15	8
Starting height 11mm	7771123 Elevate Standard 23 x 11mm		7771128 Elevate Standard 28 x 11mm		7771132 Elevate Standard 32 x 11mm	
	15	8	16	8	16	8



EXTRA-LORDOTIC IMPLANTS: No Posterior Expansion						
Starting Height (mm) - Anterior	Length 23		Length 28		Length 32	
	Max Expanded Anterior Height (mm)	Max Lordosis (deg.)	Max Expanded Anterior Height (mm)	Max Lordosis (deg.)	Max Expanded Anterior Height (mm)	Max Lordosis (deg.)
Starting height 7mm	7770723 Elevate Extra Lordotic 23 x 7mm		7770728 Elevate Extra Lordotic 28 x 7mm		7770732 Elevate Extra Lordotic 32 x 7mm	
	11	13	12	11	12	10
Starting height 8mm	8880823 Elevate Extra Lordotic 23 x 8mm		8880828 Elevate Extra Lordotic 28 x 8mm		8880832 Elevate Extra Lordotic 32 x 8mm	
	12	13	13	11	13	10
Starting height 9mm	8880923 Elevate Extra Lordotic 23 x 9mm		8880928 Elevate Extra Lordotic 28 x 9mm		8880932 Elevate Extra Lordotic 32 x 9mm	
	13	13	14	11	14	10
Starting height 10mm	8881023 Elevate Extra Lordotic 23 x 10mm		8881028 Elevate Extra Lordotic 28 x 10mm		8881032 Elevate Extra Lordotic 32 x 10mm	
	14	13	15	11	15	10
Starting height 11mm	8881123 Elevate Extra Lordotic 23 x 11mm		8881128 Elevate Extra Lordotic 28 x 11mm		8881132 Elevate Extra Lordotic 32 x 11mm	
	15	13	16	13	16	12

Trial:





CONCORDE BULLET (DEPUY)

CONCORDE Bullet >>
 TLIF Surgical Technique >>
 TLIF >>

ROI-T (LDR)

MIS-TLIF

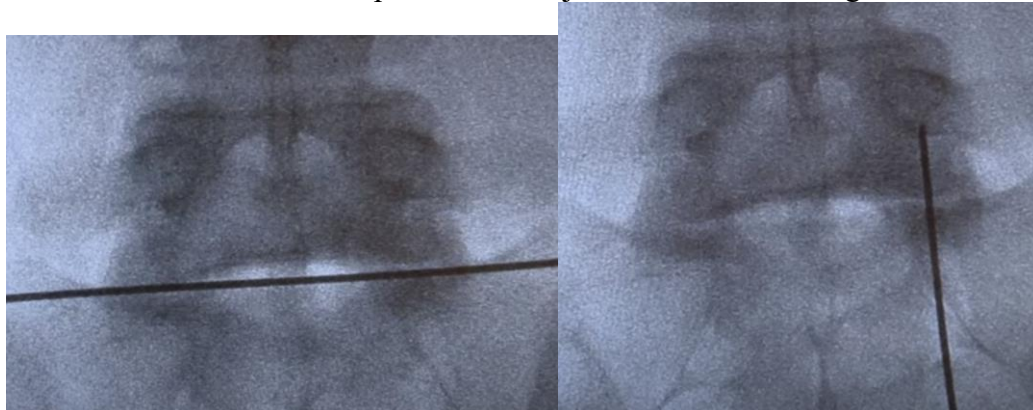
- in the early 2000s, Foley et al introduced a minimally invasive (MIS) modification of the TLIF surgical technique.
- interbody fusion is supplemented with posterolateral instrumentation.
- success of MIS-TLIF relies on a solid interbody fusion since a posterolateral fusion is difficult to achieve given the limited exposure - MIS-TLIF procedures often are done with rhBMP.

Order

1. Contralateral screw placement
2. Interbody placement
3. Ipsilateral screw placement

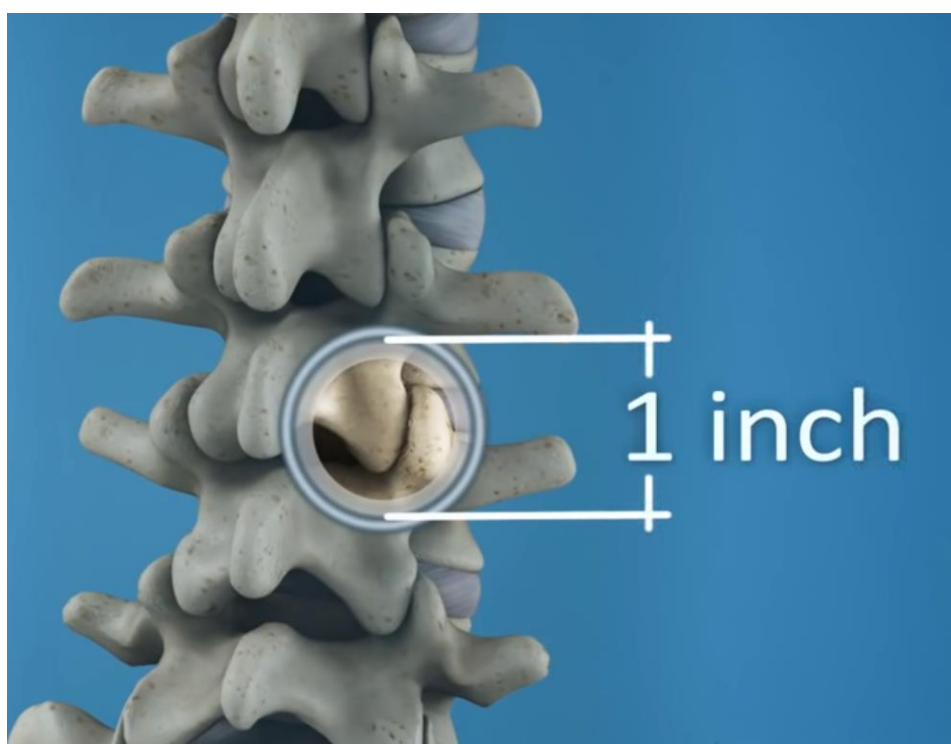
ENTRY POINT

– intersection between disc space and facet joint line; incision length ≈ 1 inch



RETRACTOR

A. Tubular dilators:



B. Pedicle screw based retractors;

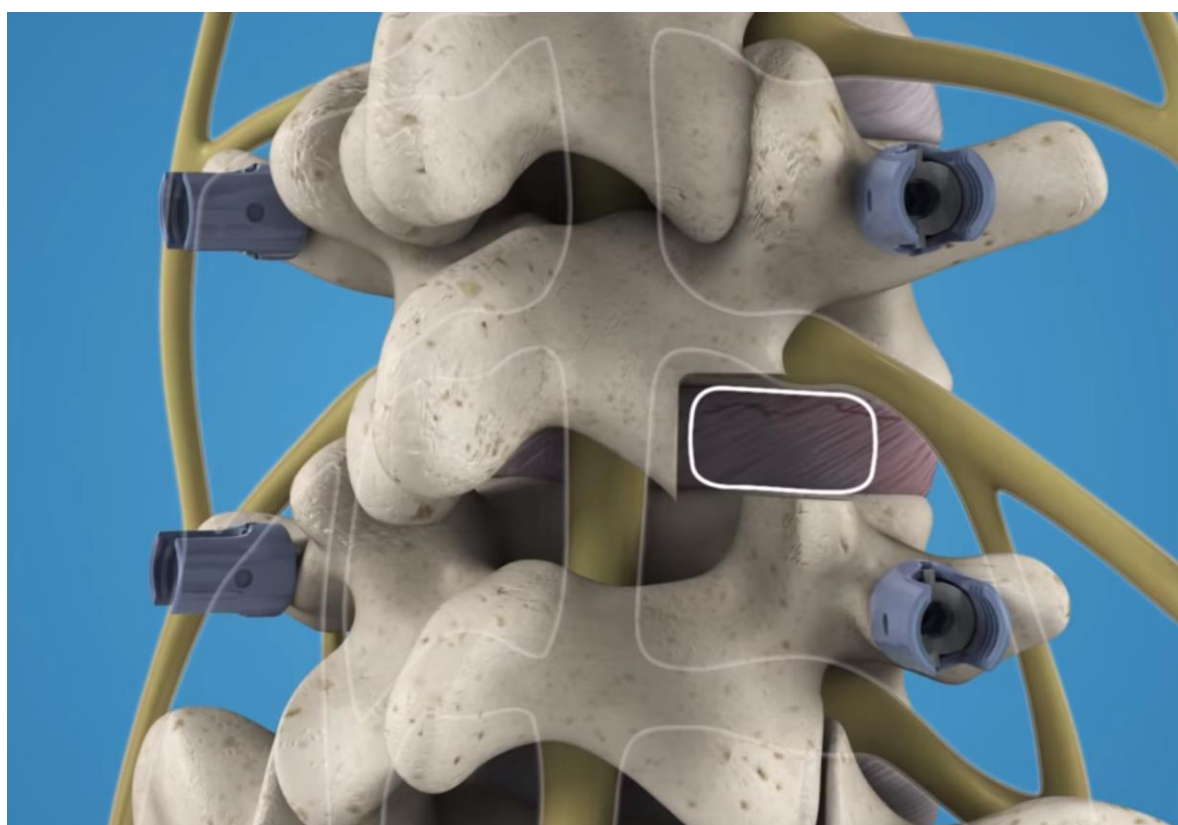
- single instrument for screw post insertion with one instrument pass.
- rigid system anchored in bone.
- provides distraction to access collapsed disc space.
- contoured, dual translating distal end to optimize patient fit.

Globus MARS TLIF retractor:



DRILL FACET JOINT

(save bone shavings for grafting)



OUTCOMES

- MIS-TLIF has similar fusion rates and complication rates compared to open TLIF surgery - regardless of graft material used (utilization of **autologous local bone in combination with both bone extender and rhBMP** showed the highest fusion rate with a 98.8% at 12-mo follow-up; **isolated use of local bone** resulted in the lowest fusion rate of 91.8% at 12-mo follow up. The highest fusion rate without the use of BMP was seen with autologous local bone plus bone extender - 93.1%).

HARDWARE**MEDTRONIC**Interbody Options

- Elevate™ Expandable Interbody Device
- Capstone™ Spinal System

Fixation - CD Horizon™ Solera™ Voyager™ System

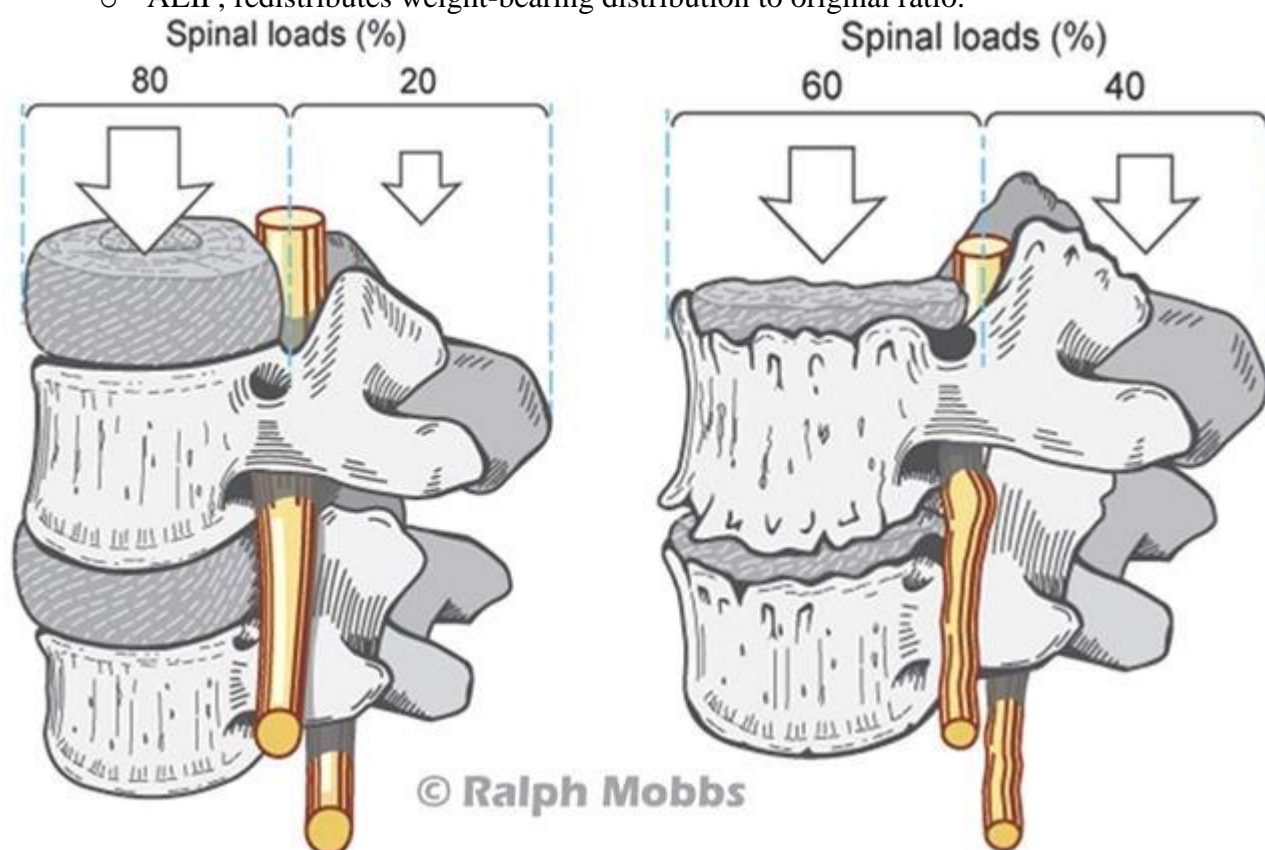
Detailed workflow of MIS-TLIF using Mazor robot – see p. Op42 >>

ALIF (ANTERIOR LUMBAR INTERBODY FUSION)

Rationale:

Weight-bearing distribution

- in normal lumbar spine in upright standing position, anterior and middle weight-bearing columns support 80% of spinal load, and posterior column supports approximately 20%
- with aging and degenerative cascade, including reducing disk height, weight-bearing distribution shifts to posterior column.
- ALIF, redistributes weight-bearing distribution to original ratio.



Advantages over TLIF:

- 1) superior height restoration (additional 5-10 degrees).
- 2) sparing of paraspinal musculature
- 3) direct disc visualization, no need to enter spinal canal – less risks, less scarring

Disadvantages over TLIF: worse cost, blood loss, and operative time.

No data to show superiority to TLIF.

Complications

- 1) **implant migration** - observed in majority of patients
- 2) **retrograde ejaculation and sterility** (2-8%) - from injury of superior hypogastric sympathetic nerve plexus (particularly when operating at L4-S1) that needs to be swept away to access disc; can be temporary or permanent
 - H: avoid using **Bovie** (use bipolar!) around sympathetic chain; avoid **BMP** (role unclear); patient may **donate sperm preop** (if patient wants to try how retrograde ejaculation feels – start α -blockers)
- 3) vascular injury (more common when operating at L4/L5 and above)
- 4) urological injury
- 5) abdominal muscle damage → hernia
- 6) genitofemoral neuralgia, femoral nerve injury
- 7) psoas trauma / weakness
- 8) retroperitoneal hematoma
- 9) mobilization of sympathetic plexus can result in high rate of localized **lower extremity sympathetic dysfunction** - asymmetric feeling of “cold leg” or “warm leg.”

INDICATIONS

- 1) chronic, incapacitating low back pain secondary to degenerative disk disease or degenerative spondylolisthesis in absence of severe neural element compression + at least 6 months of conservative nonsurgical therapies have failed.
- 2) ALIF may also be used in cases of failure of previous posterior approach lumbar surgery.

Pathology at **L4-S1 levels** (at higher levels – use LLIF).

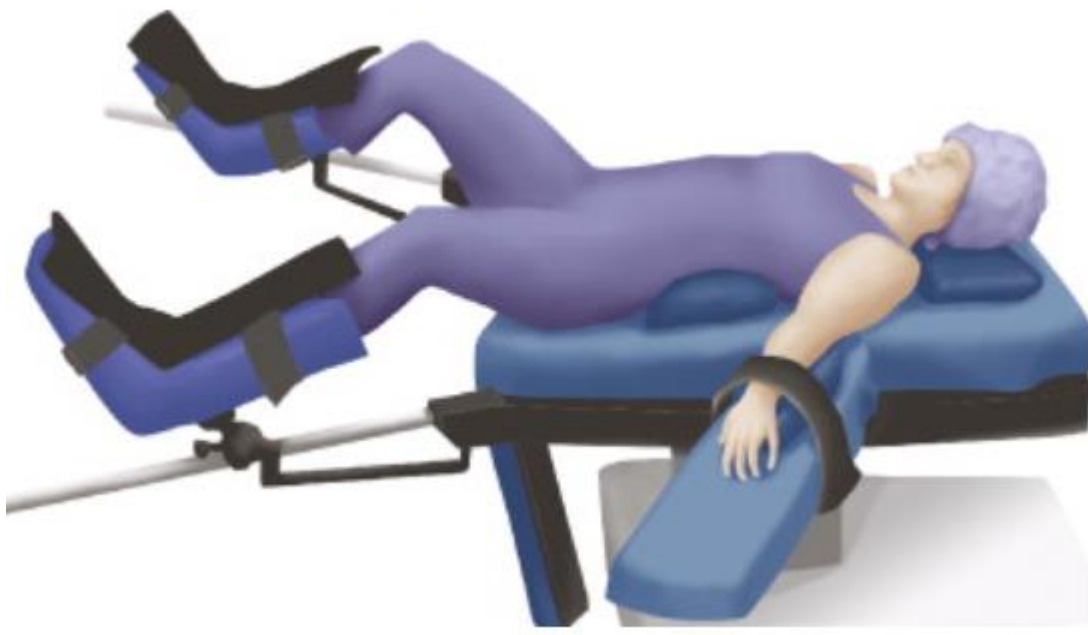CONTRAINDICATIONS

- 1) conditions that limit retroperitoneal access to the lumbar spine: morbid obesity, retroperitoneal scarring from a previous surgery / infection (incl. **osteodiscitis**), or a large infrarenal aortic aneurysm
- 2) neural element compression requiring direct decompression (exception - radicular foraminal compression at level of operation secondary to disk collapse, which may respond to distraction and restoration of disk height)
- 3) history of previous retroperitoneal surgery
- 4) genitourinary anatomic abnormalities, such as an ipsilateral single ureter or kidney
- 5) patients who are unwilling to assume risk of retrograde ejaculation
- 6) severe osteoporosis

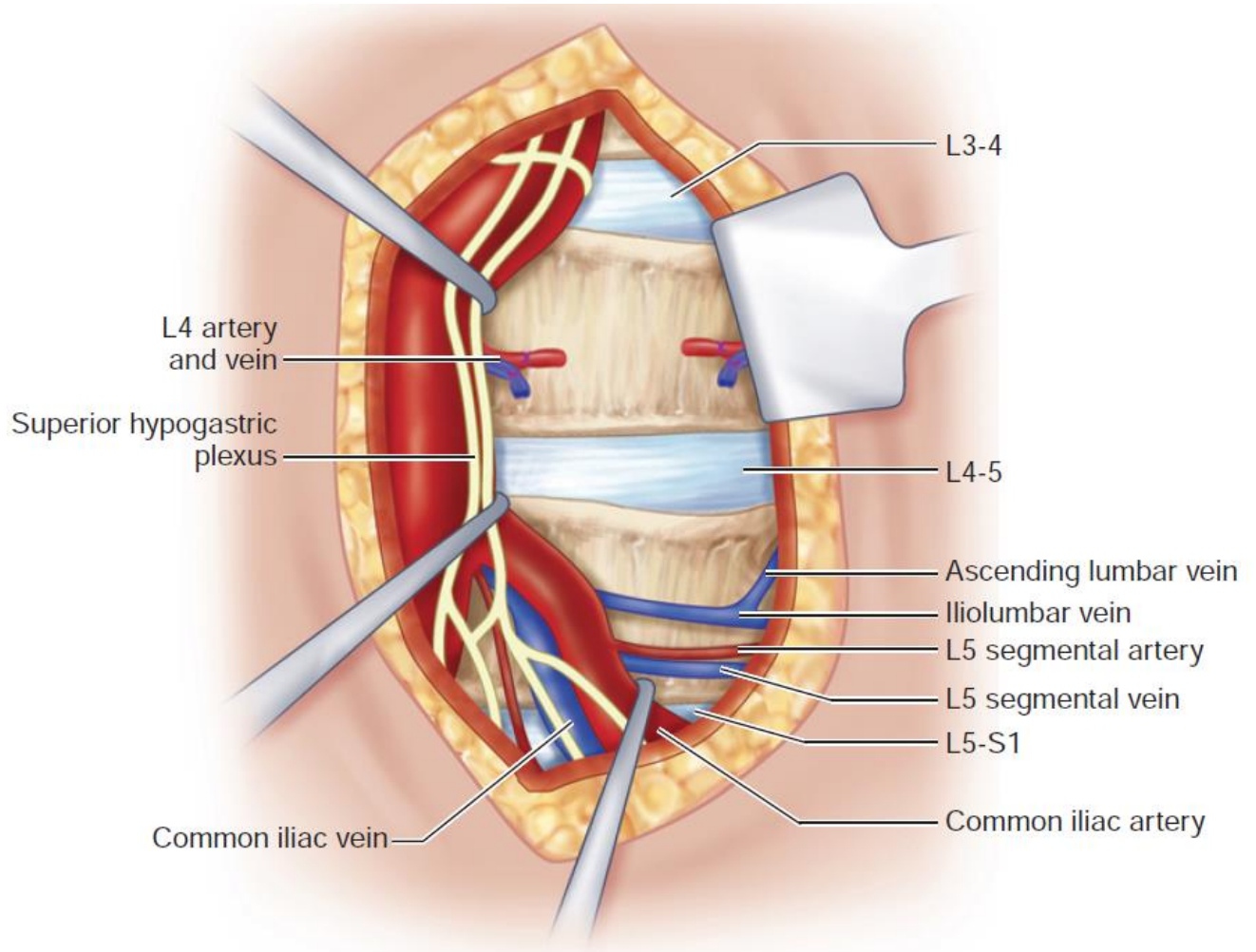
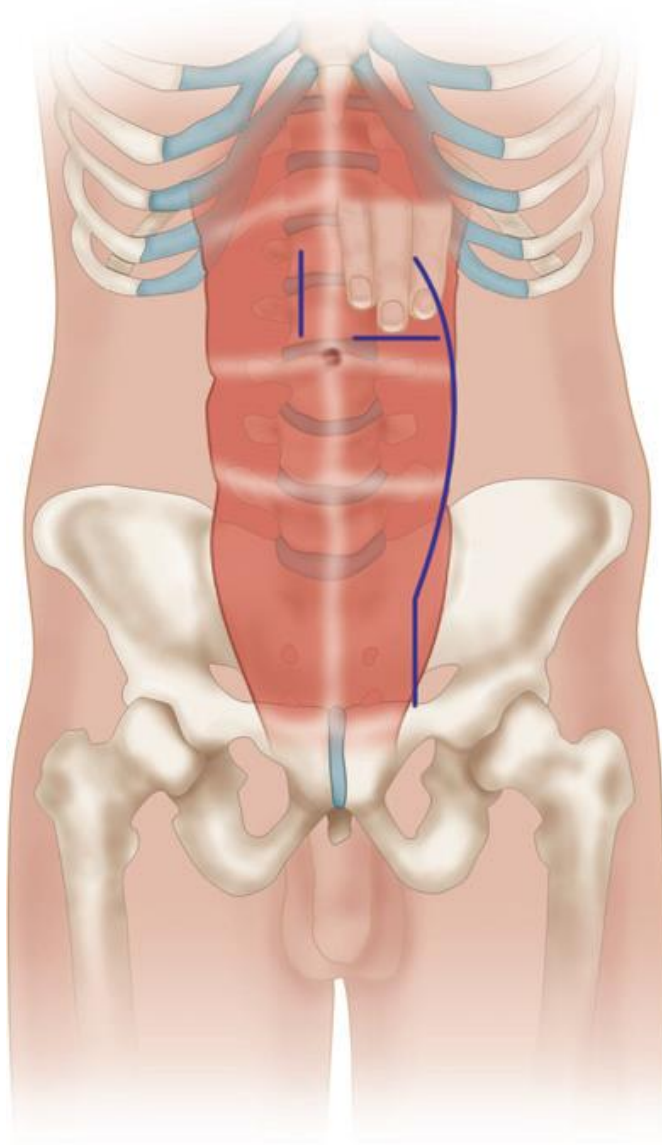
DETAILS

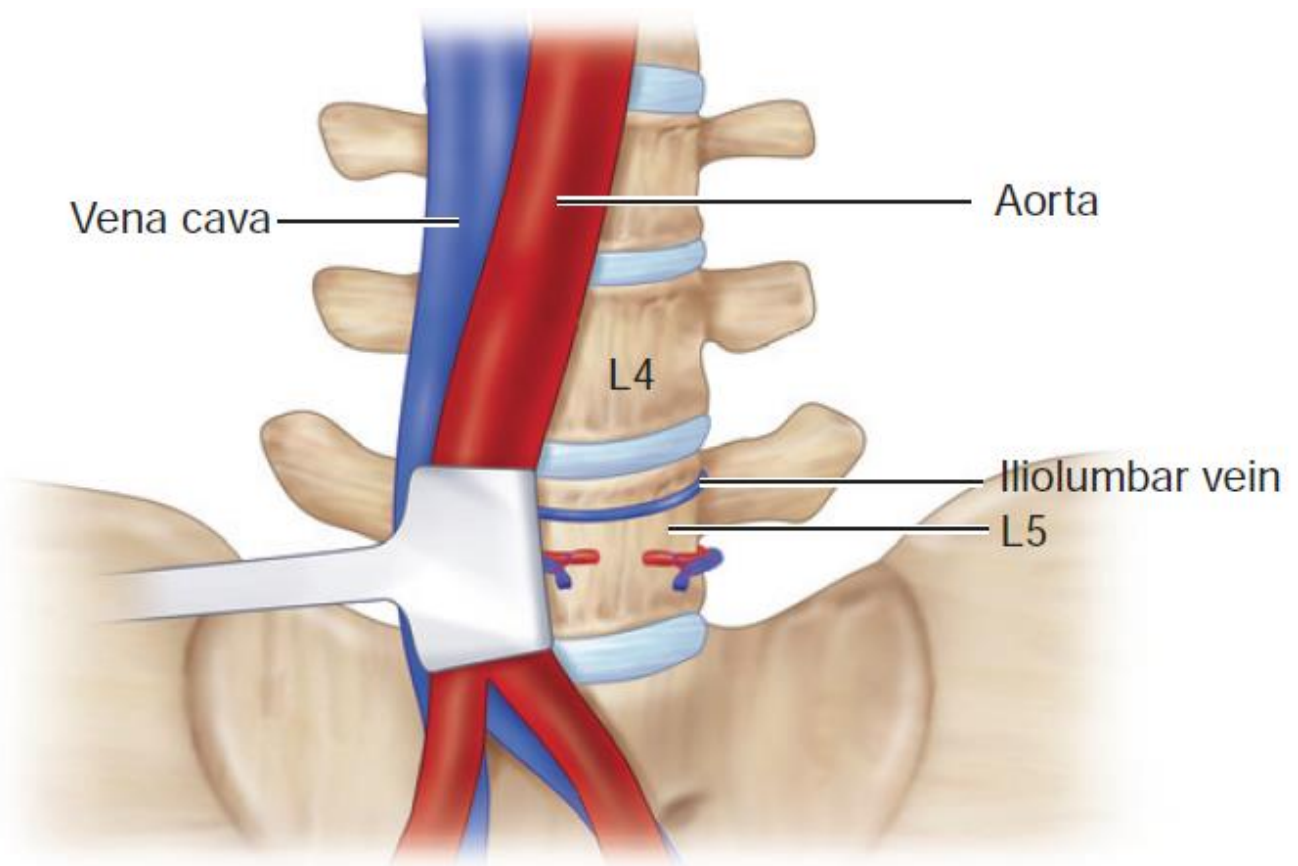
- preop CTA!!!
- for lower disk levels (L4-5, L5-S1), patient is supine, Trendelenburg.
- **inflatable bladder** is placed under the small of the back to increase or decrease lordosis as necessary.
- CellSaver in event of large quantities of blood loss from vascular injury.

- **pulse oximeter** is placed on *each lower extremity* (e.g. each big toe) to monitor for ischemia during vessel manipulation and retraction.
- correct disk space is localized using fluoroscopy, and skin is marked appropriately - incision is centered at this location and marked.



- incisions - midline, paramedian, Pfannenstiel.
- approach:
 - a) **transperitoneal approach** - may be used to access L4-5 and L5-1.
 - b) **muscle-sparing retroperitoneal approach** has become more popular - lower rates of postoperative ileus, easier control of intraperitoneal structures, ability to sweep sympathetic plexus bluntly to the right of disk space.
- approach from left side is generally performed (gentle manual retraction of aorta is more safely performed than retraction of inferior vena cava, which can be difficult to repair surgically in event of vessel wall injury); also – Pfannenstiel incision.





Source of picture: R. Jandial "Core Techniques in Operative Neurosurgery: Expert Consult - Online and Print", 1st ed (2011), Saunders; ISBN-13: 978-1437709070 >>

- at L5-S1, mobilization of large vessels is usually unnecessary because approach can be taken through vascular bifurcation; **pubic symphysis** is access-limiting structure (explore imaging preop).
- at L4-5 level, iliolumbar vein enters common iliac - avulsion at this anastomosis can lead to aggressive, unnecessary bleeding.
- L3-4 disk requires more significant mobilization and retraction of iliac vessels and aorta.
- **discectomy** ("as for ACDF")
 - symmetric incision of anterior disk annulus is performed, taking care to leave lateral annular walls intact.
 - avoid disruption of posterior annulus (→ injury to contents within vertebral spinal canal).
- use graft with significant lordosis, particularly at L5-S1 interspace; graft with 10-15 degrees of lordosis is reasonable.

Cage options (no data to guide decision between PEEK and titanium for ALIF)

Cages Options

- Titanium
- PEEK
- Ti-Coated PEEK
- Bone Dowels
- Femoral Ring Allografts

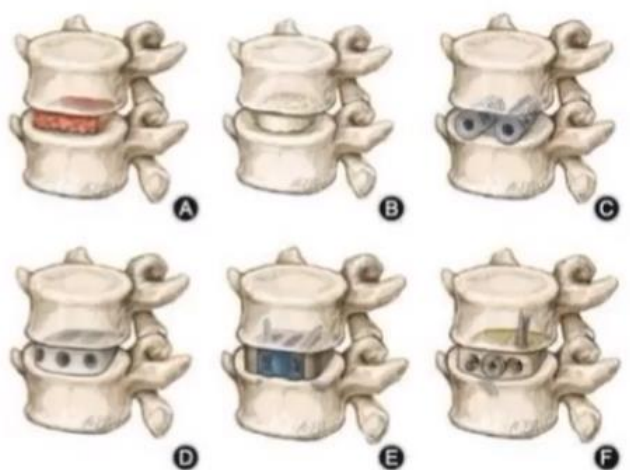
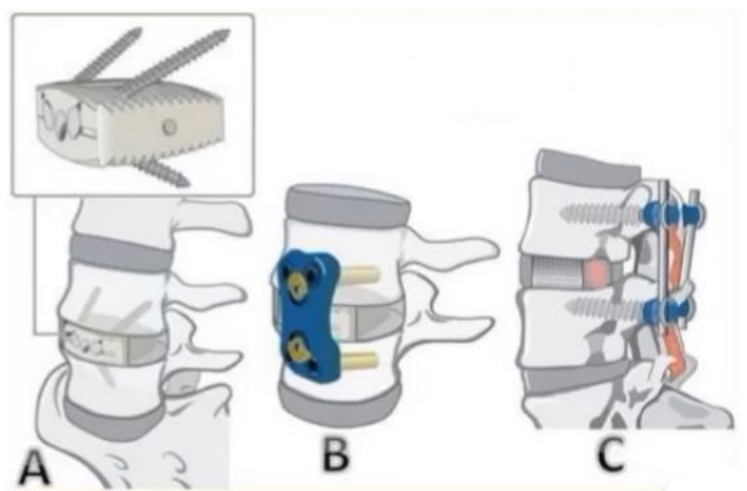


Fig. 3 Evolution of anterior lumbar interbody fusion (ALIF) cage designs. (A) Autograft block; (B) femoral ring allograft; (C) BAK cage; (D) PEEK cage; (E) SynFix implant; (F) Ti-PEEK cage.

3D-printed cages are a promising option

Fixation options

- Internal Fixation
- External Fixation
- Posterior Instrumentation



- **anterior plate** provides minimally increased biomechanical rigidity, but it can be useful to prevent anterior expulsion of intervertebral spacer in stand-alone ALIF.

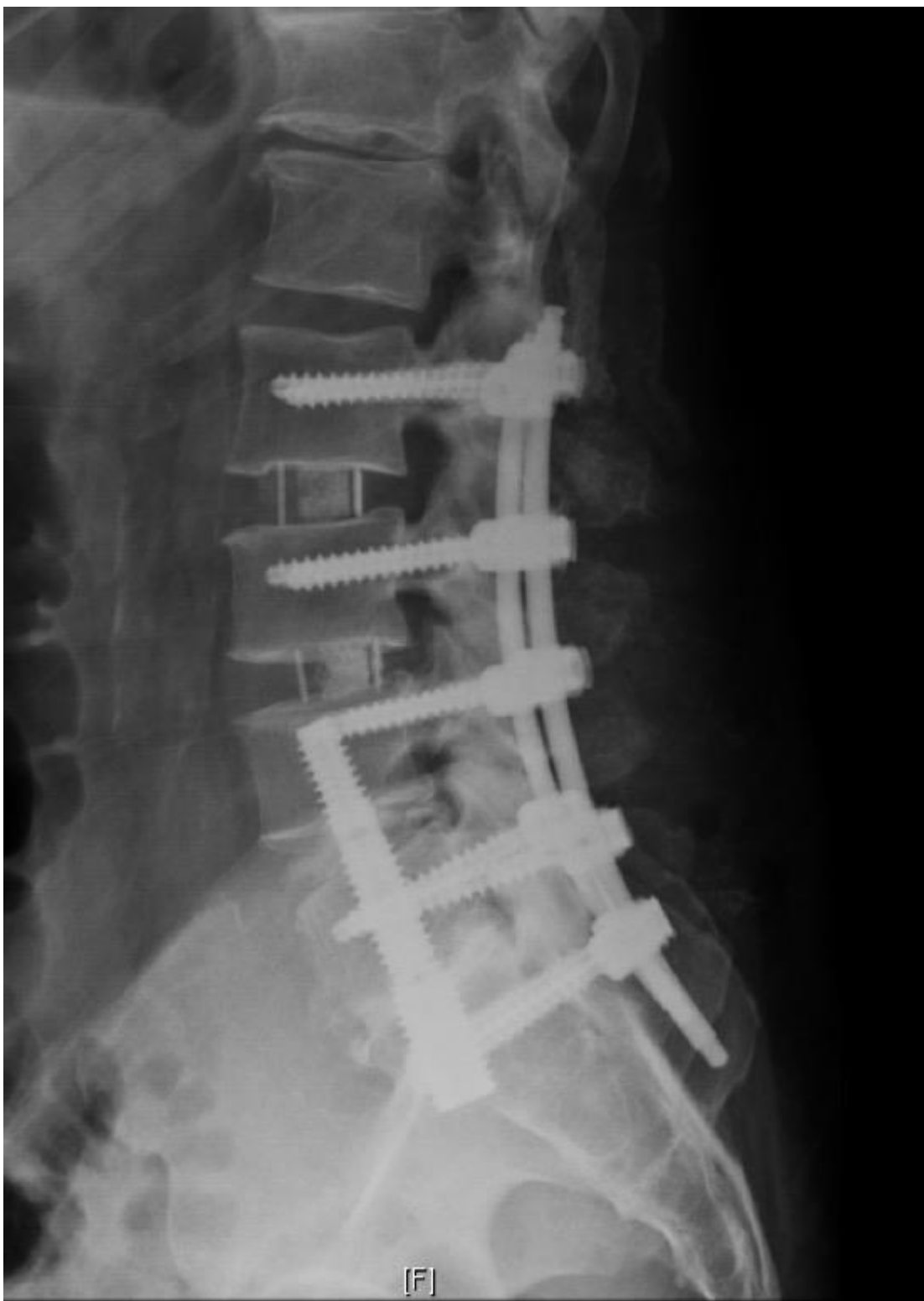Posterior enforcement

- **supplemental posterior percutaneous pedicle screws** lead to comparable clinical outcomes to those undergoing **open posterior instrumentation**.
- addition of fusion levels (cephalad, caudal or iliac) in the setting of a high grade isthmic spondylolisthesis in adult patients improve outcomes.

CAGES

ROI-A ALIF CAGE (LDR)

AxiaLIF



- growing evidence of complications and biomechanical failures as well as the publishing of revision strategies for failed AxiaLIF → the technique ultimately fell into disuse.

POSTERIOR LUMBAR CORPECTOMY

See p. TrS9 >>

LATERAL APPROACH INTERBODY FUSION s. anterolateral retroperitoneal approach to lumbar spine

<http://www.youtube.com/watch?v=3C2fcmDqc0c>

<http://www.youtube.com/watch?v=w7JnZezL6ws>

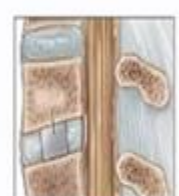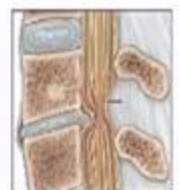
DLIF procedure (Bangkok Medical Journal - Sept 2012) >>

<http://www.spineuniverse.com/professional/research/treatment/surgical/procedure-description-direct-lateral-transpoas-lumbar>

ADVANTAGES (OVER POSTERIOR APPROACH)

Biomechanical Advantages

- Inherently stable¹
- Large area for large footprint interbody implant
- Ligamentotaxis (also assists with indirect decompression^{2,3})
- Optimized fusion environment (stability, loading, surface area⁴)



- avoids epidural space
- less muscle dissection (less back pain, less fibrotic paraspinal musculature).
- less damage to adjacent facets → less ASD?

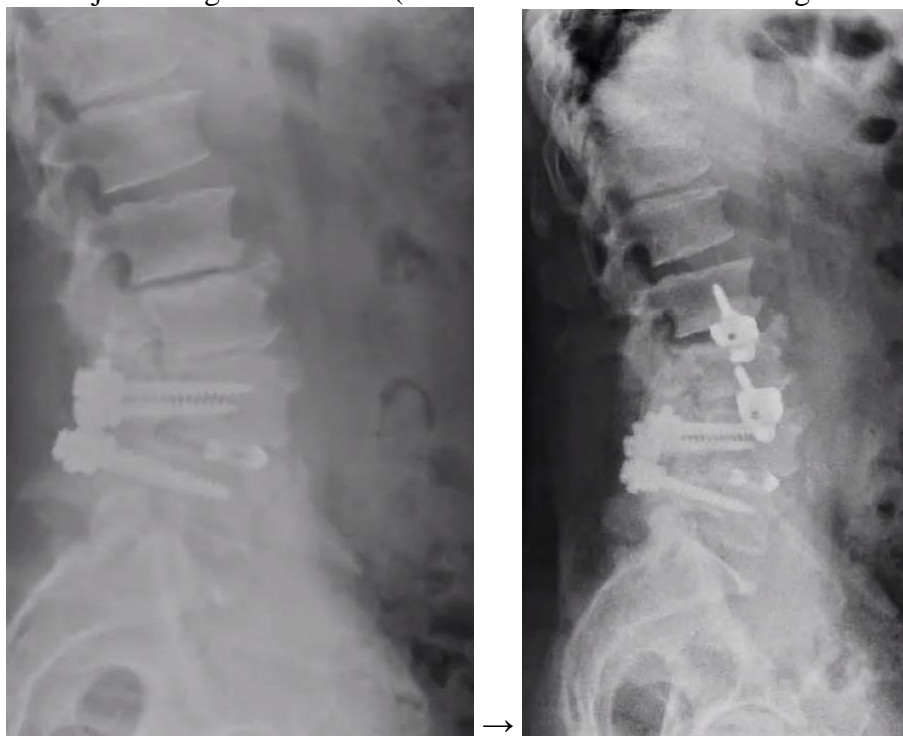
SUITABLE LEVELS

Pathology at **T12-L5 levels** (for levels L4-S1, ALIF may be better).

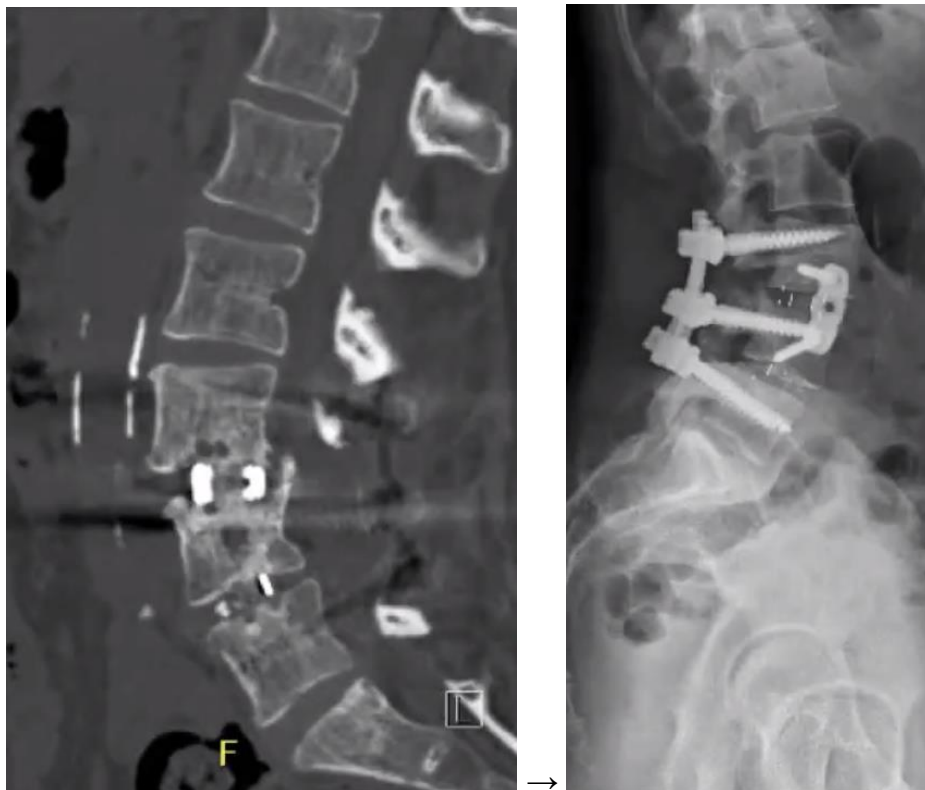- above T12 need pleura retraction
- at L2-3 and above, ribs start getting into way (H: break table to lateroflex patient).
- at **L5-S1** iliac crest is in the way (normally, iliac crest corresponds to L4-5 level) – better ALIF.
- for L1-2 need open thoracotomy approach to dissect diaphragmatic crus (along with 12th rib resection – will be used for second day surgery).

INDICATIONS

1. Adjacent segment disease (LLIF allows to avoid dissecting old hardware)



2. Pseudoarthrosis



COMPLICATIONS, CONTRAINDICATIONS



The Spine Journal 17 (2017) 545-553



Clinical Study

Technical description of oblique lateral interbody fusion at L1–L5 (OLIF25) and at L5–S1 (OLIF51) and evaluation of complication and fusion rates

Kamal R.M. Woods, MD^{a,*}, James B. Billys, MD^b, Richard A. Hynes, MD^c

Complications	OLIF (%)	ALIF (%) [17]	XLIF (%) [18]	XLIF/DLIF (%) [19]	XLIF (%) [20]
Subsidence	4.4	–	0.8	1.7	27.6
Postoperative ileus	2.9	1.4	1	–	–
Vascular injury (arterial/venous)	2.9	3.3	0	0	–
Blood transfusion	1.5	–	0.2	–	–
Retrograde ejaculation	0.7	2.7	–	–	–
Ureteral injury	0	0.2	0	–	–
Superior mesenteric artery syndrome	0.7	–	–	–	–
Neurologic injury	0	2	0.7	13.8*	39.5 [†]
Psoas muscle spasms	0	–	–	10.3 [†]	–
Wound infection	0	1.1	0	–	2.3
Hardware failure	0	2	0.3	–	–
Reoperation	0	3	1.8	1.7	4.7
Overall	11.7	14.1	6.2	22.4	–

Approach complications

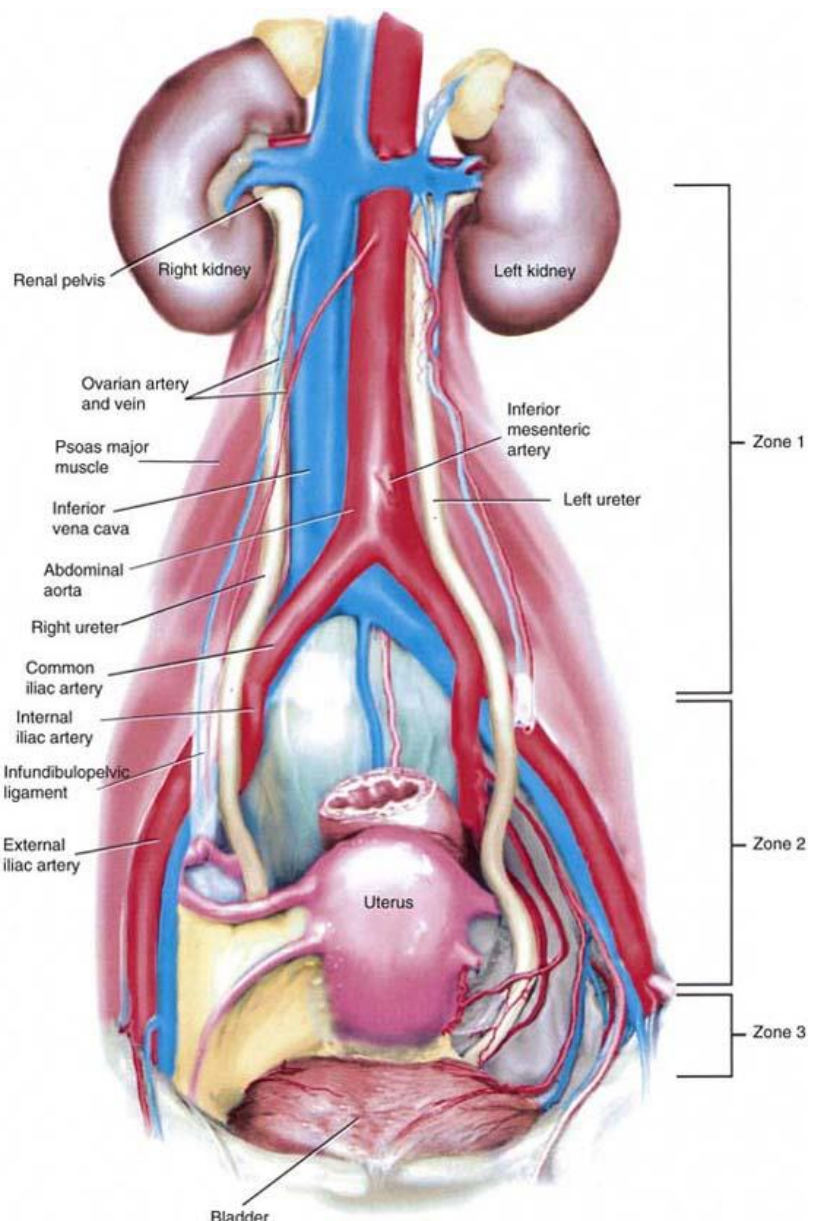
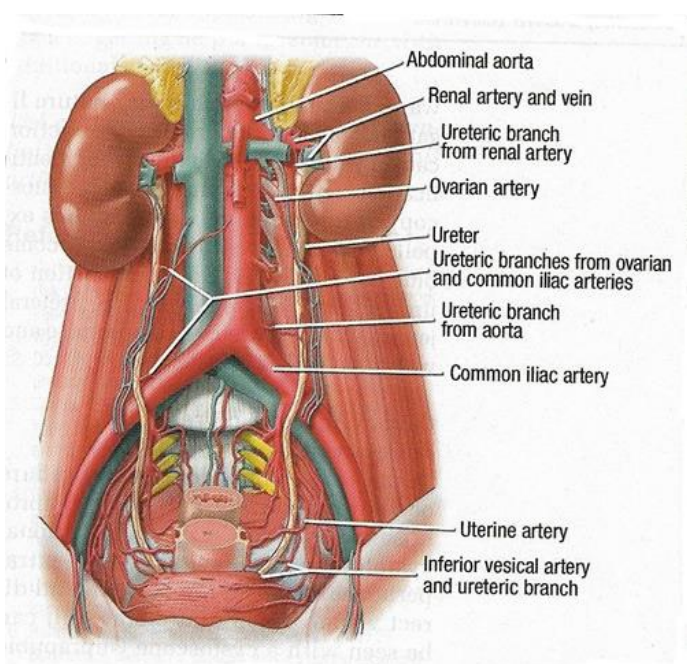
LIF contraindicated:

1. Prior abdominal surgery/infection* (relative contraindication)
*e.g. diverticulitis
2. Prior irradiation of the surgical path
3. Retroperitoneal fibrosis
4. Morbidly obese (retroperitoneal fat falls into view)
5. Very thin patients (no retroperitoneal corridor – high risk of bowel injury)

- consider **access surgeon** (general or vascular surgeon) - for mobilization of the great vessels and handling of the abdominal contents - shortens procedure duration and reduces blood loss.
- **psoas pain** (esp. after trans-psoas approach) lasts 6-10 weeks.

Ureter injury

Ureter courses on anterior surface of psoas:



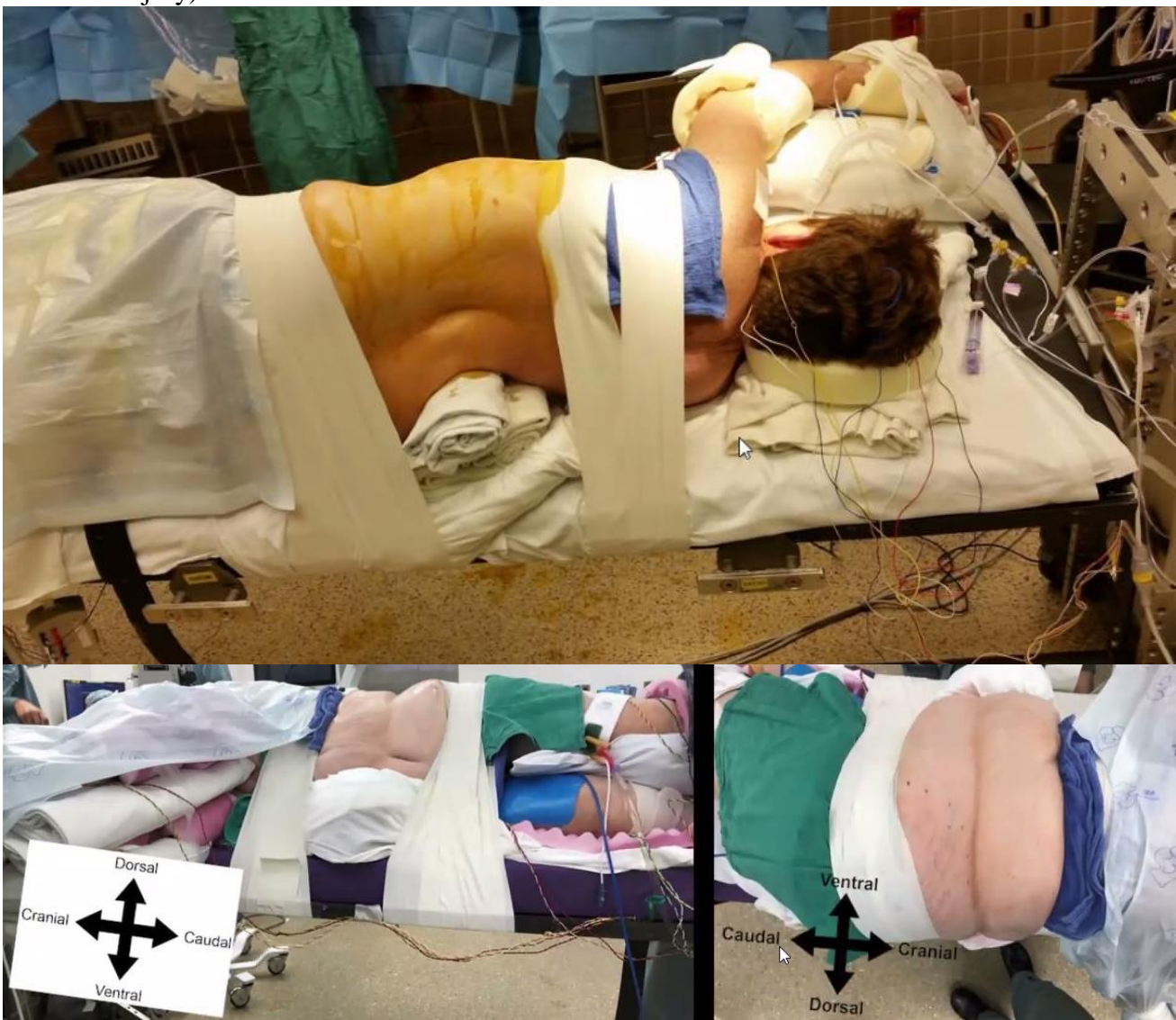- identification of the ureter may be confirmed by **preoperative ureteral stenting*** and by **Kelly's sign** - visible ureteral peristalsis following application of gentle pressure.
- ureter is gently elevated and retracted medially with the retroperitoneal fat pad when possible.
*in cases of related malignancy or fibrosis
- if patient has **one kidney and on the left**, ask for **urologist** for approach or may approach from the right side with DLIF.

Subsidence

- risk if graft height is oversized.
- Globus expandable cage claims less subsidence.
- despite subsidence, fusion typically happens (just lose sagittal balance advantage).

Plexus injury

- highest risk at **L3-5 levels**, thus, prefer to use OLIF there.
Dr. Kazemi: practically, almost every patient will have some retraction injury!
- monitor patients with stim probe (best - directional stim probe) + motor evoked potentials.
- **left hip flexion** reduces tension of psoas muscle (and plexus inside it).
- avoid **breaking the table** (to open the space between iliac crest and rib cage) – flat Jackson table, just place a roll under the patient.
N.B. experts avoid breaking the table as it stretches lumbosacral plexus (more susceptibility to retraction injury)!

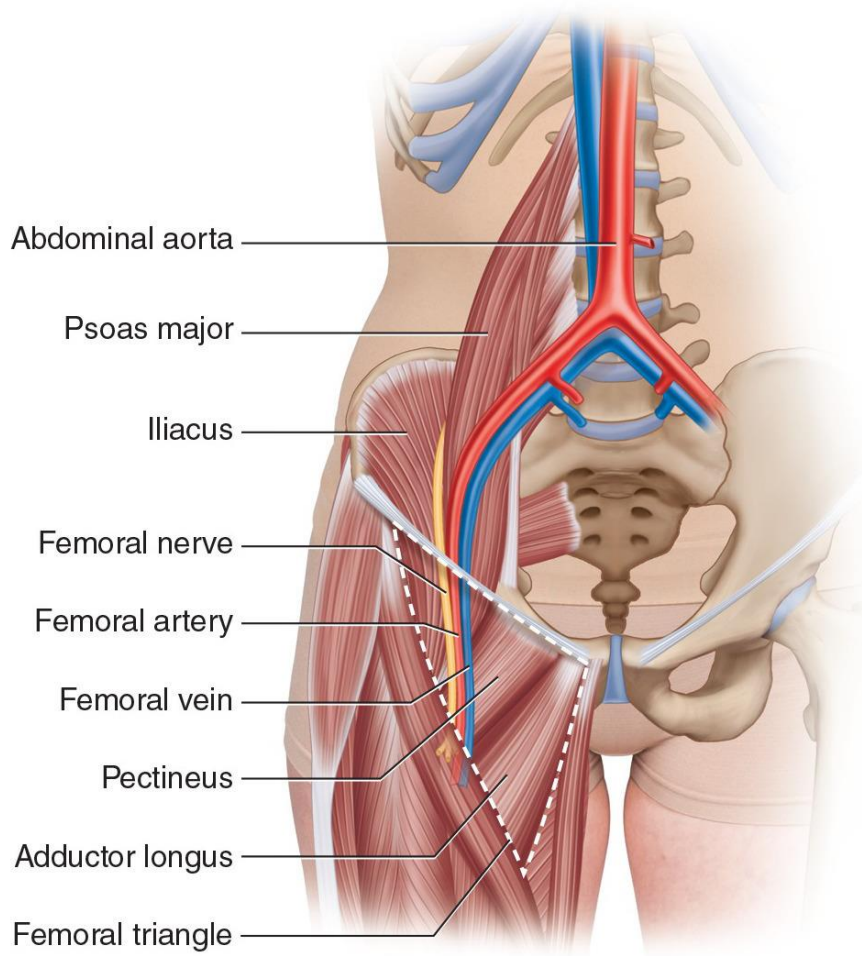


- avoid **fixed (locked to vertebra) retractors**
- **genitofemoral nerve** exits body of psoas medially near level of L3 and should be protected during lateral retraction of psoas muscle to avoid dysesthesia of the anterior thigh and inguinal region.
- evaluate position of plexus on preop MRI (“Mickey mouse ears”)

Vessel injury

- LIF contraindicated - **calcification of great vessels**.
- check for major vessel position on preop MRI; **aortic bifurcation is usually at L4 level**, just above junction of the left and right common iliac veins

Aortic Bifurcation	N	%
Mid Vertebral Level of L-4	41	45.6
L4-L5 junction	23	25.6
L3-L4 Junction	15	16.6
Lower Vertebral Level of L-4	11	12.2



A

Copyright © 2015 Wolters Kluwer Health | Lippincott Williams & Wilkins

- thin patients have aorta riding on anterior vertebral surface – risk of damage (esp. when cutting ALL fibers – use retractor blade right in front of ALL for protection).

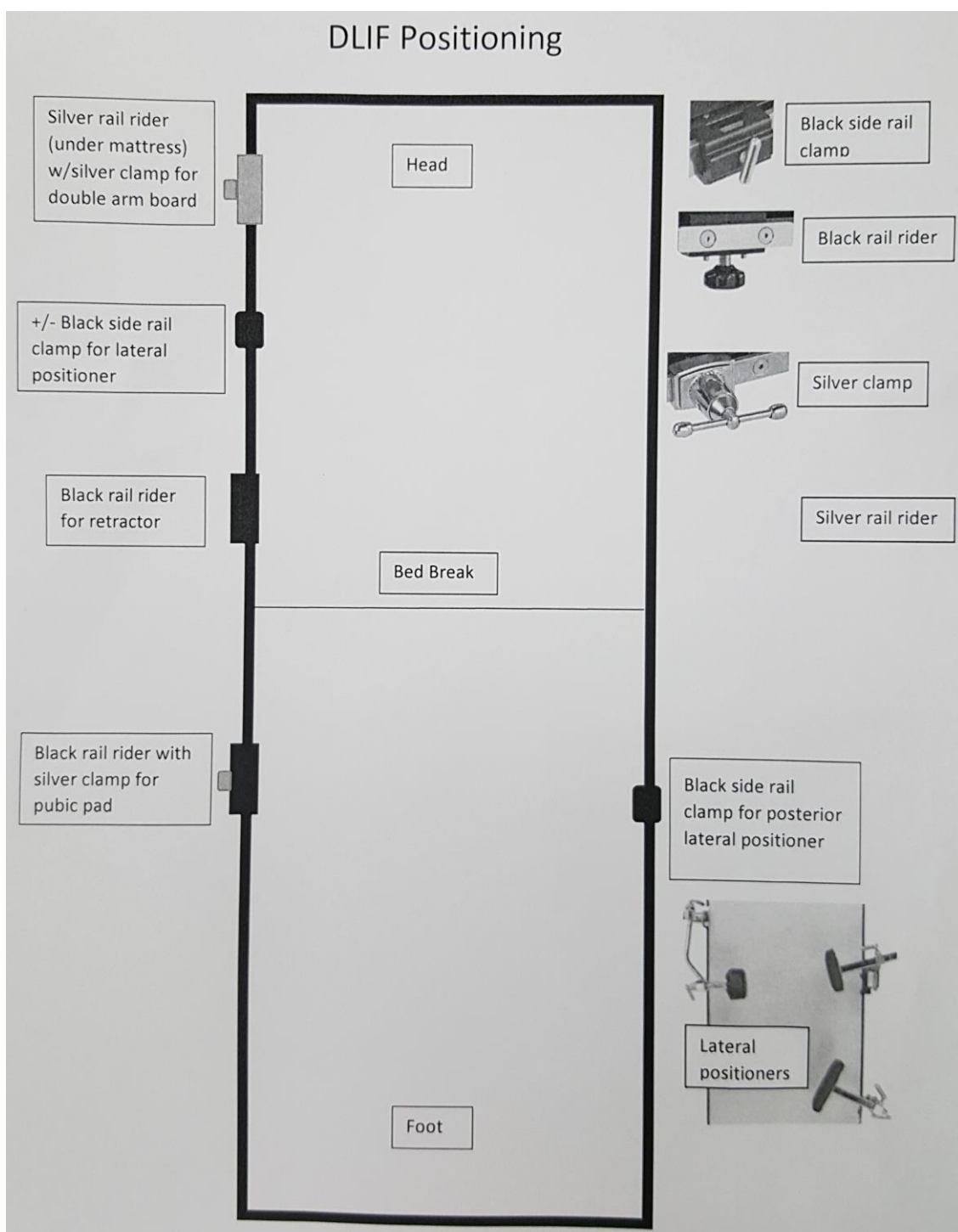
STAGES

- usually posterior reinforcement with pedicle screws is needed - open (if need to access canal or old hardware) or percutaneous;
 - vs. if posterior column is completely intact, may avoid posterior part (then use interbody cage with integrated fixation)
- two stage procedure:
 - a) both stages **during same procedure** (“lateral in prone position”)
 - b) both stages **during same admission**
 - first day – LIF** → bed rest with head of the bed up to 45 degrees until posterolateral fusion is done;
 - second day – posterolateral fusion**; Dr. Mathern likes postop thoracolumbar CT (after second stage - activity as tolerated, scoliosis XR during follow up) dissection and “unlocking” of facets by Smith-Peterson osteotomies, so lets to distract disc space, may be done on first day – practically only if it is revision surgery and need to remove posterior old hardware
 - c) **discharge patient home** between stages (esp. if ALL was kept intact).

POSITIONING

A. LATERAL

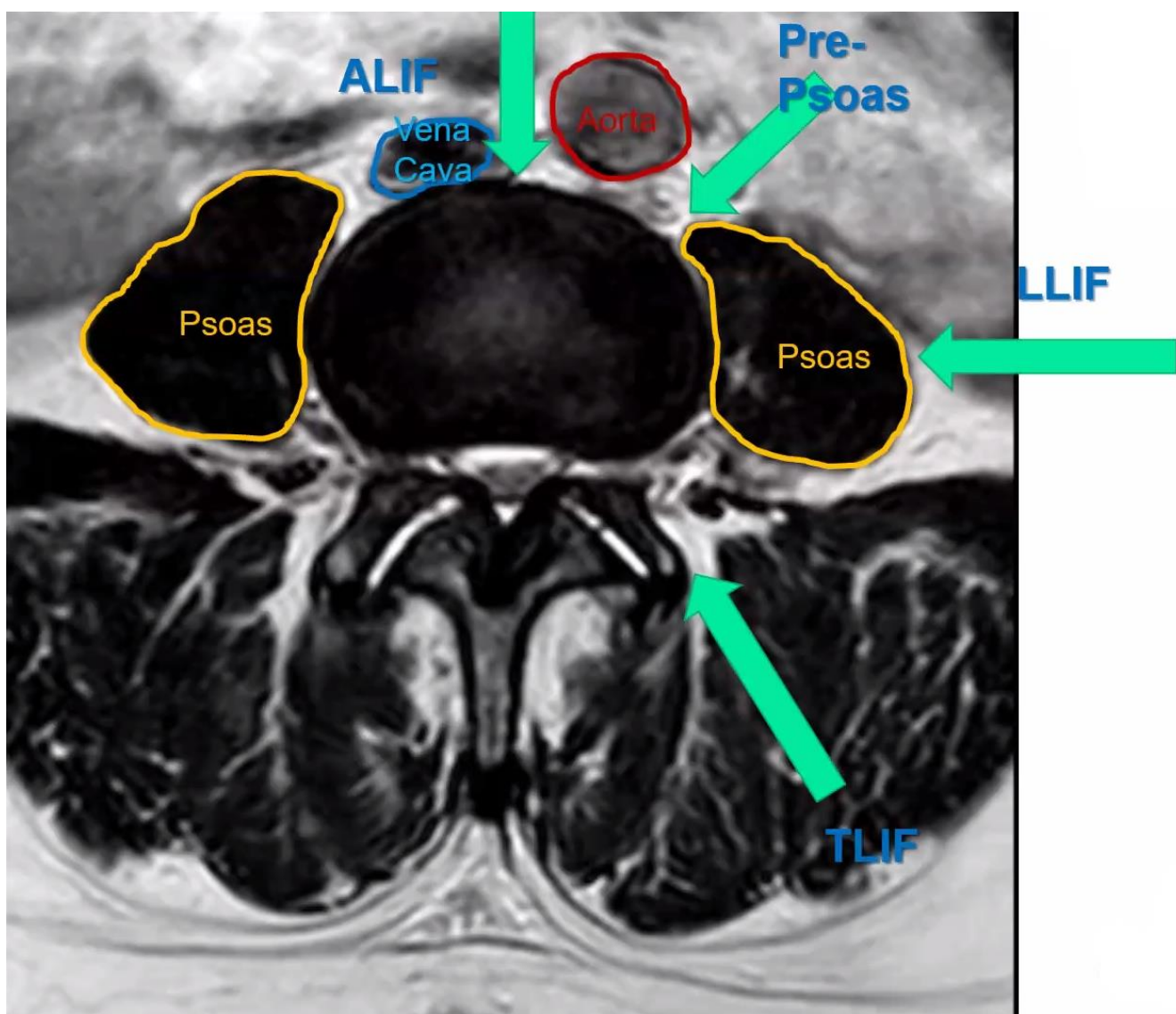
- right lateral decubitus position on Axis table;
 - shoulder roll in axilla.
 - maximum lateral flexion at the intended LIF level (check with your hand if there is space between ilium and ribs).
 - pelvic ring stabilized between posterior and anterior lateral positioners.
 - make sure **patient’s back is absolutely vertical** (if needed for added stability, may also stabilize chest between lateral positioners)



B. PRONE (AKA PRO-LIF)

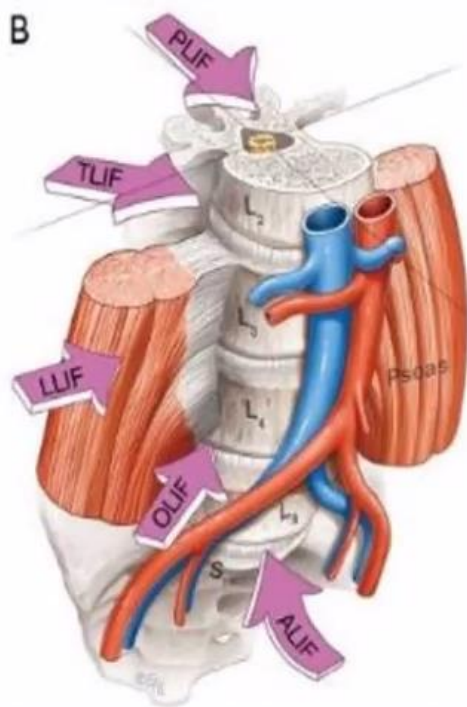
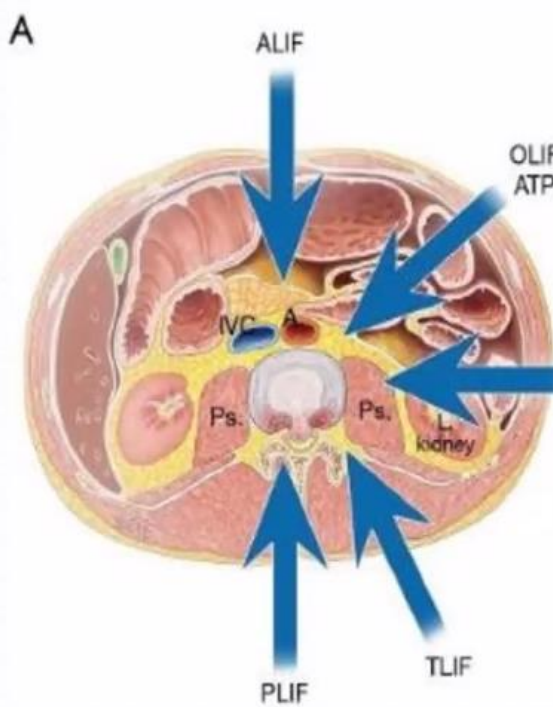
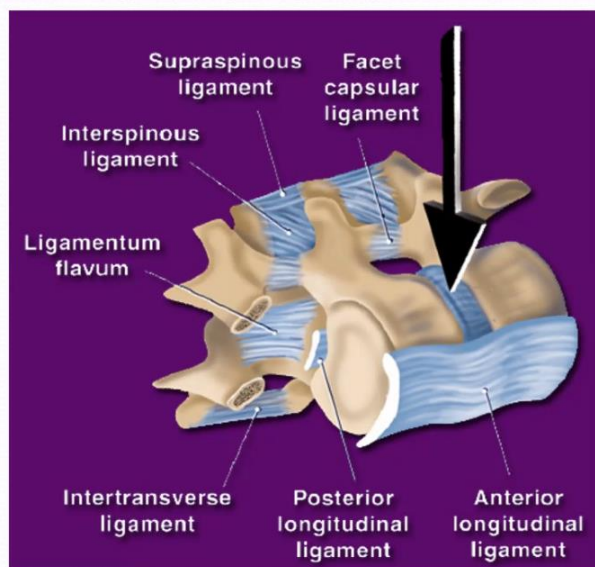
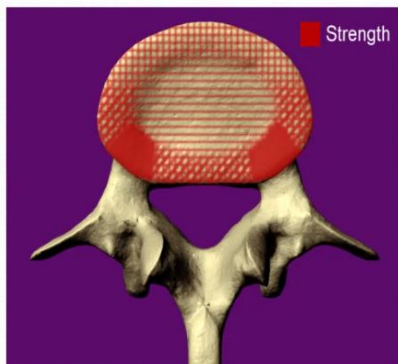
- allows LIF and posterior stages done at once.
- also if LIF fails, straight proceed to posterior fusion.
- patient is prone on spine table and on 15 degree bolster* (together with table rotation 25 degrees gives total 40 degrees rotation – ergonomic ease for a surgeon).
*Globus is developing adjustable positioner that secures patient at chest and hips and allows spine lateroflexion

APPROACHES



Ligament sparing for ligamentotaxis

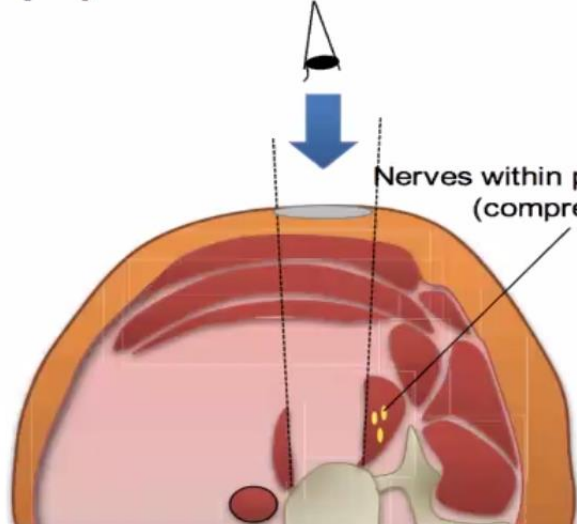
(Grant et al., Spine 2001;26(8):889-896)



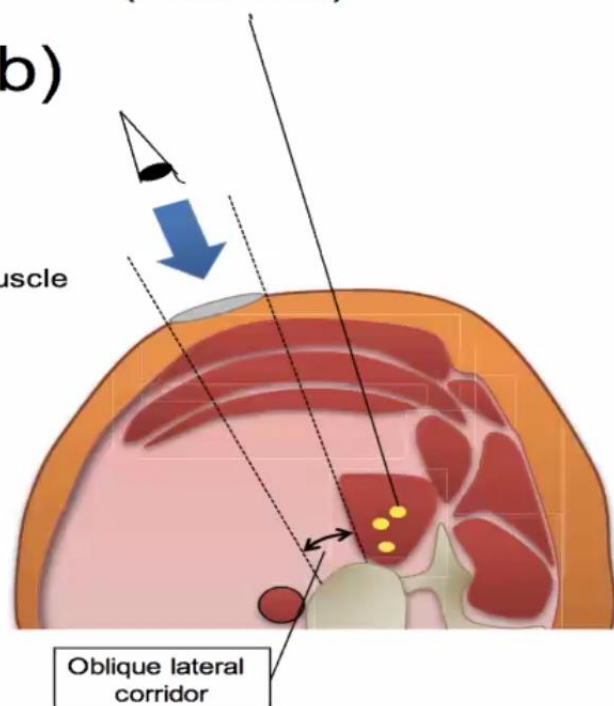
¹Goyal A, et al. *Clin Neurol Neurosurg* 2018;167:122-128.
²Lehmen JA, et al. *Eur Spine J* 2015;24 Suppl 3:287-313.

Nerves within psoas muscle (Preserved)

(a)



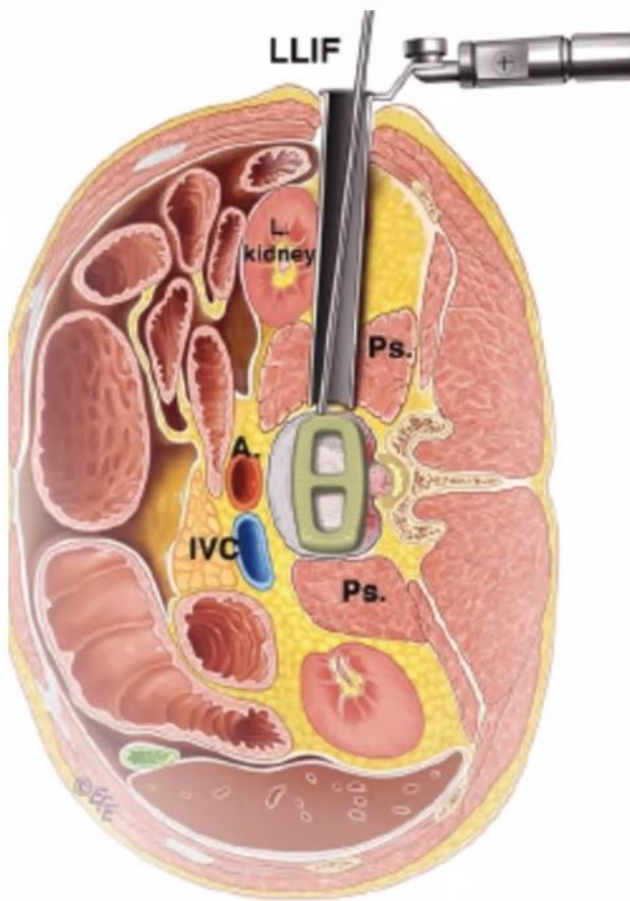
(b)



- A. **Anterior-to-psoas (ATP), e.g. OLIF (oblique lumbar interbody fusion)** – avoids psoas muscle – less potential for lumbar plexus injury (some experts do not use neuromonitoring)
 - mandatory for L4-5 level (trans-psoas may cause severe femoral nerve injury and “high-riding” ilium is often in a way), optional for L3-4

https://www.youtube.com/watch?v=XhsOa23fpmk&feature=youtu.be&list=PLyptnEaqO5i6_ue9U_io_UFy1Ro9bxjrQ

- B. **Trans-psoas, e.g. DLIF, LLIF, XLIF** – acceptable for L1-3 levels (lumbosacral plexus is not well formed yet); some say it has higher risk of plexus injuries others say it is the same.



- **default approach from left side** regardless of scoliosis curve (right side – liver and vena cava); if symptoms unilateral – approach from that side.

TECHNIQUE

- NIM-SPINE free-running EMG monitoring needle electrodes placed into bilateral leg muscles – see above >>

INCISION

- **fluoroscopy to determine incision** (e.g. very convenient – Globus crosshair marker) - in left flank, oblique (along Langer lines), 5 cm length.
 - mark three lines: one parallel to disc space at intended work level; second – longitudinal at posterior vertebral body margin; third - longitudinal at anterior vertebral body margin;
 - implant entry point - splitting vertebral bodies into anterior 2/3 and posterior 1/3; center incision where those two lines cross.

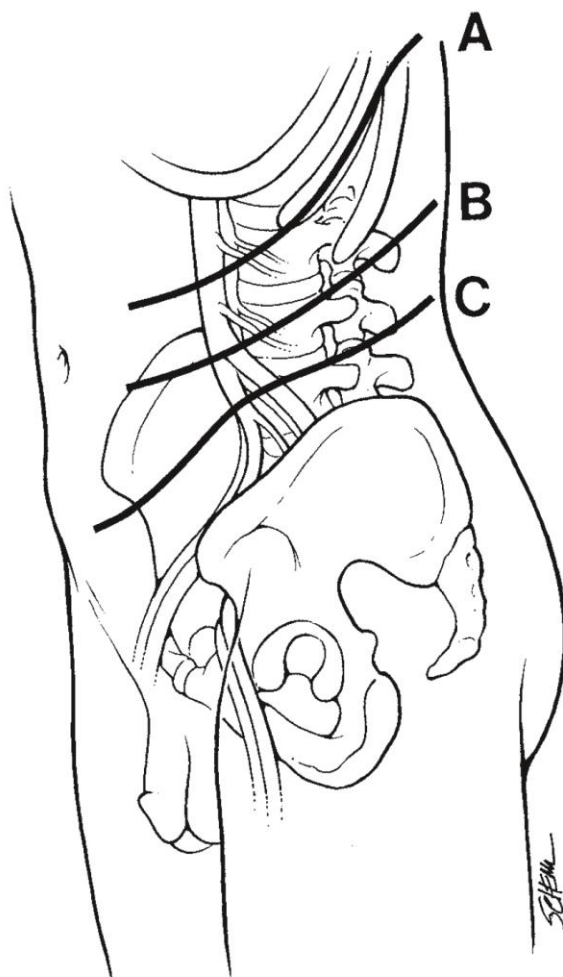
Open approach incisions

To expose L1-L2: incision begins above and two levels rostral to the desired level of exposure and terminates at the lateral border of the rectus sheath above the midpoint between the costal margin and the umbilicus.

To expose L2-L5: incision begins in the posterior axillary line equidistant between the costal margin and the superior iliac crest, and terminates at the lateral border of the rectus sheath. The incision for exposure of L2-L3 extends between the costal margin and the umbilicus; of L3-L4, toward the umbilicus; and of L4-L5, above the midpoint between the umbilicus and the pubic symphysis.

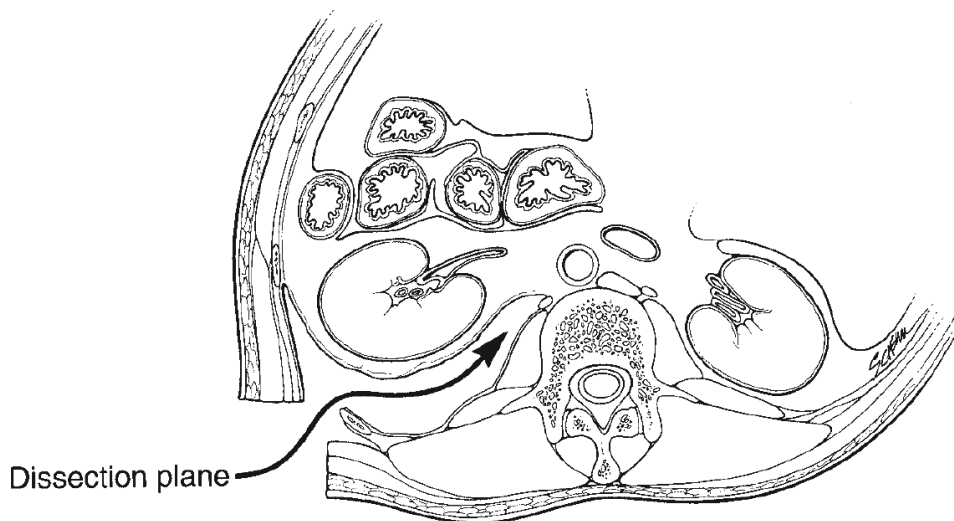
To expose the lumbosacral junction: incision begins slightly superolateral to the anterior superior iliac spine and continues rostral and parallel to iliac crest and inguinal ligament to a terminus at the lateral border of the rectus sheath

Incision A is for L2-L3 lesions, incision B is for L3-L4 lesions, and incision C is for L4-L5 lesions:

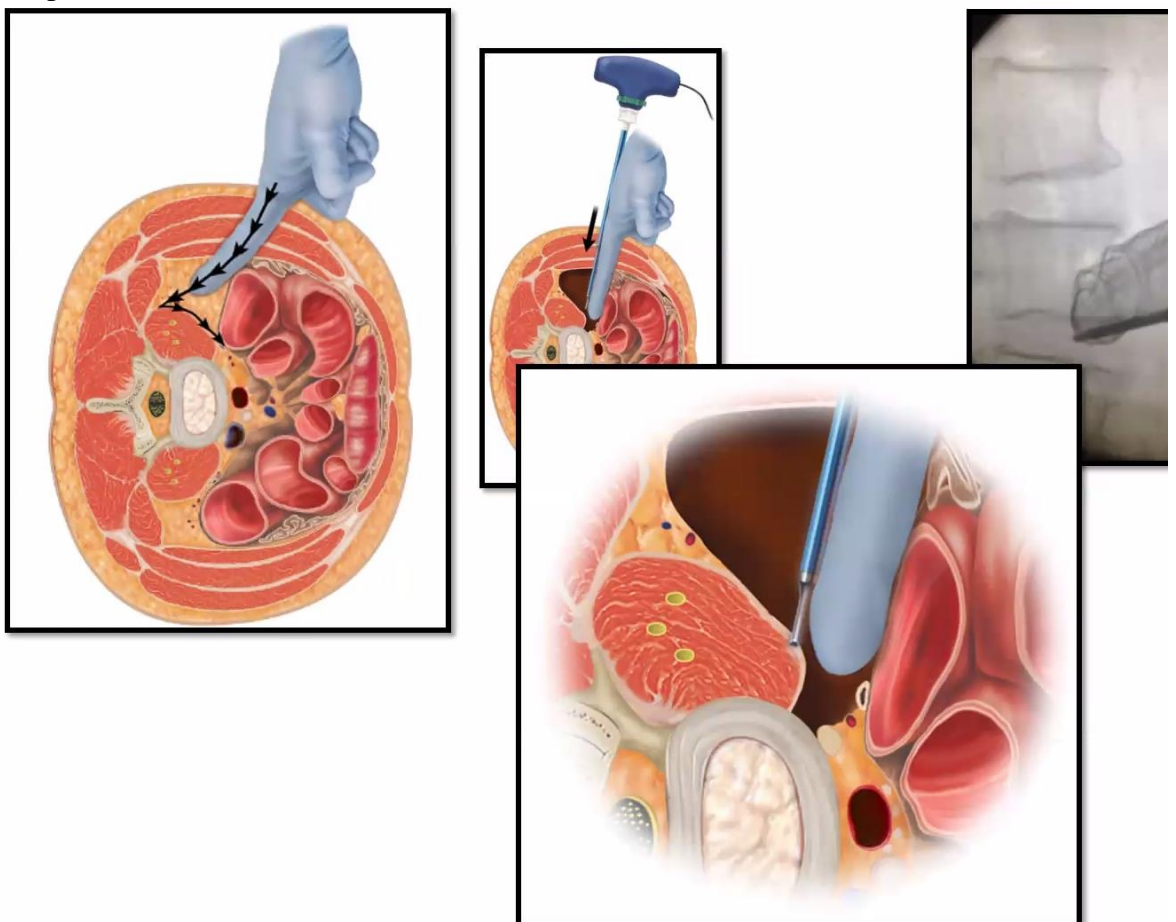


A. APPROACH: MUSCLE-SPLITTING

- division of the abdominal skeletal musculature along anatomic planes and along muscle fibers (preservation of anatomic muscle planes reduces pain and promotes healing)



- dissection with Bovie down through subcutaneous tissue.
- **blunt dissection** (finger, Kelly clamp, Kittner, hand-held retractor blade [maybe with installed light source]) to split abdominal muscles – all three: **external oblique** (runs “put hands into pocket” direction), **internal oblique***, **transversus abdominis** (may be inapparent)
 - *anatomic dissection of the internal obliques limits exposure, rendering this approach most suitable for MIS
- ideally, leave transversalis fascia intact but practically it gets entered and you follow in retroperitoneum:



- peritoneum is usually transparent gray, and if a peritoneal opening is encountered, it should be closed with absorbable suture prior to proceeding; then back off and go more dorsally
- dissect with finger aiming towards transverse processes and feel psoas anterior to it.
- use NIM-PAK Needle probe (holding with Kocher / radiolucent holder so your hand is not in fluoro field) - lateral disk entry point is localized, guidewire (K-wire) needle advanced through probe lumen into disk space and increasing diameter DLIF dilators are inserted.
 - if doing open approach, after disk entry point localization (with simple spinal needle) use Kittner to split psoas along fibers.
- lateral fluoroscopy to obtain appropriate trajectory (center of graft is between 2/3 anterior and 1/3 posterior; however, more anterior is desirable if goal is to correct kyphosis) and placement of retracting system.
- **tubular** or **three-adjustable-blade retractor** is fixed on FlexArm and then docked and attached to table.

Globus MARS 3V retractor (with fiberoptic lights inside blades):



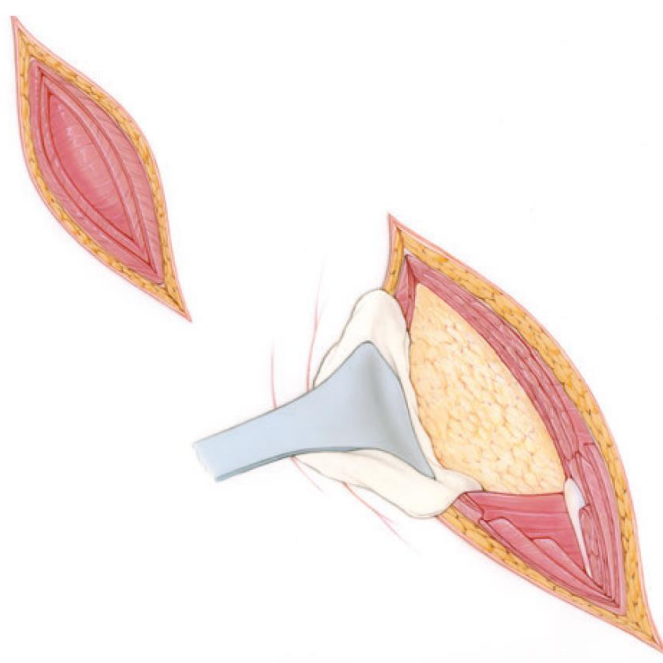


- NIM stimulation using NIM-PAK Needle checks 4 quadrants inside retractor to make sure no lumbosacral plexus nerves are trapped (this step is not needed for open approach).
 - there are *directional stimulation probes* that help to determine where plexus is.
 - goal is to keep plexus posterior.
 - **docking screw** is placed through retractor blade hole (check using NIM-PAK Needle that spot too) – place in blade which does not need more movement (so when opening retractor, the other blade will move).
 - may advance (with mallet) a special **shimmer** into disc space posteriorly (when opening retractor blades, retractor does not migrate posteriorly) and secure it to the vertebral body with pin through the channel inside shimmer.
- resect with Bovie / blunt spread just enough psoas for discectomy exposing disk annulus.

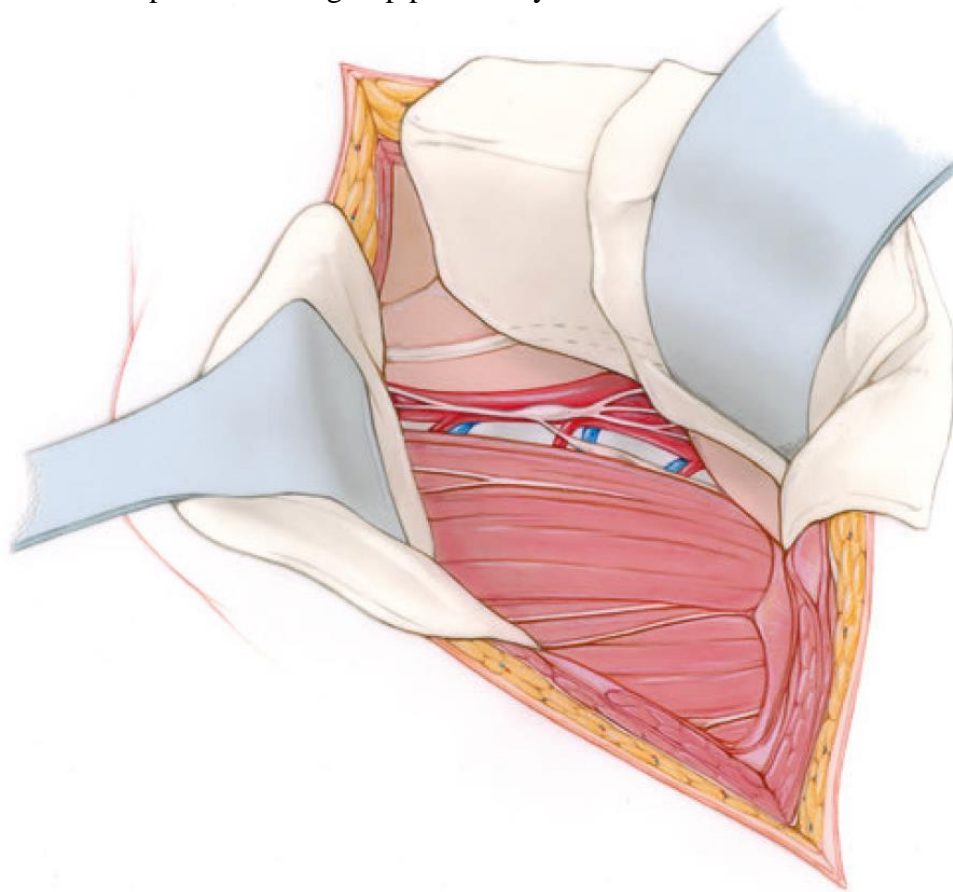
B. APPROACH: OPEN FLANK

- involves linear electrocautery dissection through the anatomic planes of the external oblique and the transversus abdominis muscles

- in contrast to the muscle-splitting approach, the *intervening internal obliques are transected against their anatomic plane to facilitate exposure.*



- transversalis fascia should be opened laterally where the peritoneum is thickest and least likely to be adherent.
- blunt dissection of the retroperitoneal plane between the renal fascia ventrally and the quadratus lumborum/ psoas muscle group posteriorly leads to the vertebral column:



- inferior pole of the left kidney is retracted medially using a Deaver retractor padded with a lap sponge, and longitudinal retraction may be augmented with a Bookwalter retractor.
- exposure of the **rostral lumbar spine** may be augmented by costal resection two levels above the desired vertebral body.
 - resection of 11 and 12 ribs would expose the inferior body of L1.
 - division of the diaphragmatic crus from the anterior longitudinal ligament and subsequently of the arcuate ligament from the transverse process of L1 facilitates exposure of the caudal extent of T12.
 - diaphragmatic dissection should commence at the periphery, 2 cm from the lateral margin, to prevent injury to the phrenic nerve, which originates medially.
- **lumbosacral junction** lies below the iliac bifurcation.
 - hypogastric plexus overlies the middle sacral vessels in the interiliac space, and these structures may be mobilized by fascial dissection medial to the left common iliac vessels.
 - further exposure of the lumbosacral junction may require proximal ligation and division of branches of the internal iliac vessels for mobilization and distraction to the contralateral side over a vertebral body.

DISCECTOMY

- annulotomy using a retractable long-handle **15-blade scalpel** → discectomy with **pituitary rongeurs** and **curettes** (others use Box Cutter for discectomy).
N.B. do not damage endplates by too vigorous curettage!!!!

N.B. do not damage ALL (or graft will migrate anteriorly), unless inducing lordosis, then cut 50% of ALL fibers while protecting vessels with “ALL blade” anteriorly.
 N.B. discectomy just to create channel for graft cage and no more.

- contralateral annulus is disrupted using **Cobb elevators** along each endplate – advance Cobb until it is beyond vertebral body on AP fluoro; some surgeons do it along each endplate but it is enough just in one spot – to allow to distract disc space.

CAGE INSERTION

- aim to place cage in anterior 1/2 (if in the middle – fulcrum of rotation is too posterior → flat back).

CLOSURE

- retractor is removed.
- closure without drain; suture muscle fascia together.

GRAFTS / CAGES

- a) **static** lordotic cage
 - e.g. PEEK cage filled with BMP and wrapped with silk tie to keep BMP in place is.
 - e.g. Medtronic Clydesdale PEEK cage DLIF graft – it is lordotic so has “ANTERIOR” edge marking
 - b) **expandable** lordotic cage
- either type may have **integrated fixation** (especially useful if planning to avoid posterior fixation for support).
 - trial placed into disk space → appropriate graft size is chosen to maximally distract disk space.
 - **too tall graft** may damage endplate; even if endplate is not damaged, too tall graft will subside with time (BMP softens bone and promotes that).
 - cage is placed under lateral → AP fluoroscopy guidance.
 - subsidence prophylaxis:
 - cage with **bigger footprint**.
 - **do not use rasp** for endplates (just remove cartilage with #10 blade).
 - **titanium** much better than PEEK.

ELSA EXPANDABLE (GLOBUS)

Cadaveric testing shows that expandable spacers help preserve endplates during implant insertion, with 30% greater resistance to subsidence compared to static spacers. Additionally, repeated trialing with static spacers may lead to more iatrogenic endplate damage, resulting in less indirect decompression and may predispose the operative level to subsidence.²



Subsidence has been reported in up to 24% of clinical cases in which static spacers are used, within 12 months postoperative¹




30% GREATER RESISTANCE TO SUBSIDENCE

WITH THE GLOBUS EXPANDABLE PLATFORM



CLYDESDALE STATIC (MEDTRONIC)

Brochure >>

0 or 6 or 12 degrees lordosis

Indications: one or two contiguous levels from L2 to S1; patients may also have up to Grade I spondylolisthesis.

AVENUE L (LDR)

XLIF (EXTREME LATERAL INTERBODY FUSION) - NUVASIVE

- same as DLIF just by different company (NuVasive®)
- uses much larger grafts and may achieve impressive lordosis.
N.B. **leave ALL intact to prevent graft migration** (some experts recommend to cut some ALL fibers – but only under direct vision to avoid vascular injury; reminder of ALL fibers will stretch naturally).
- there are grafts also for scoliosis correction.

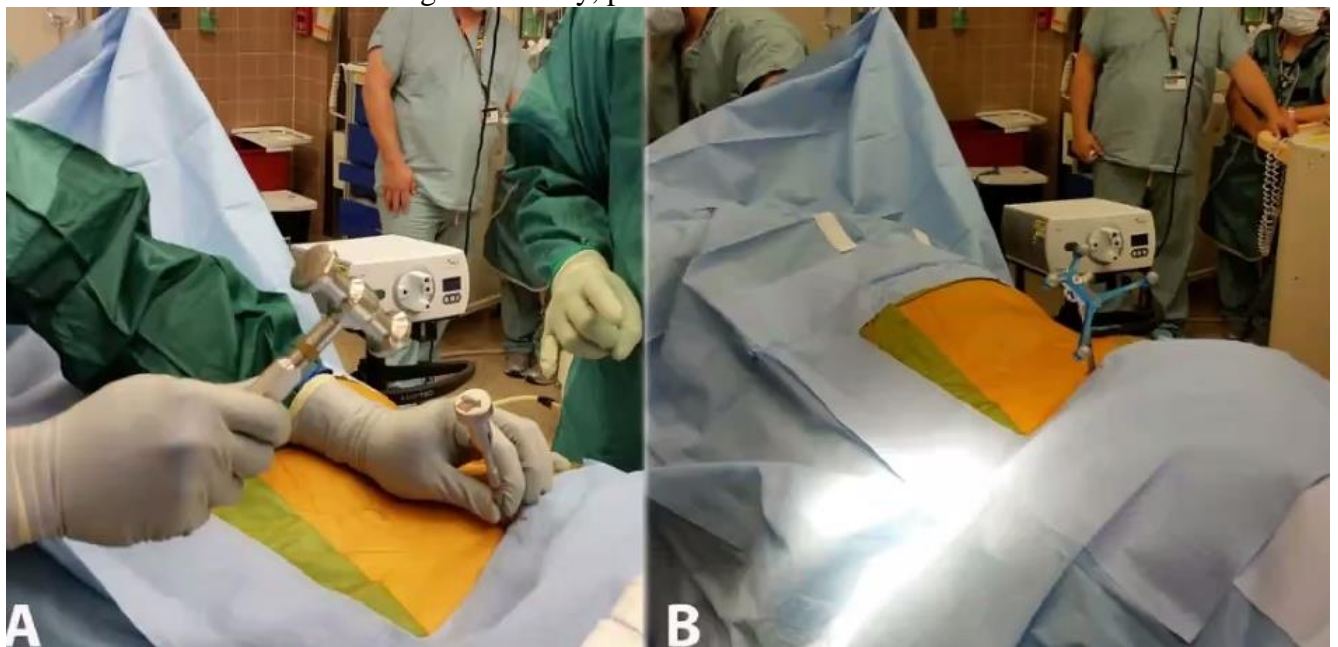
NAVIGATED LIF

"Case Review: Navigation and Robotic Assisted Prone LLIF" by Dr. Paul Park, University of Michigan, Ann Arbor, MI.

Click here to view: [Case Review: Navigation and Robotic Assisted Prone LLIF](#)

It can be done with modern neuronavigation – avoids fluoro exposure to surgeon.

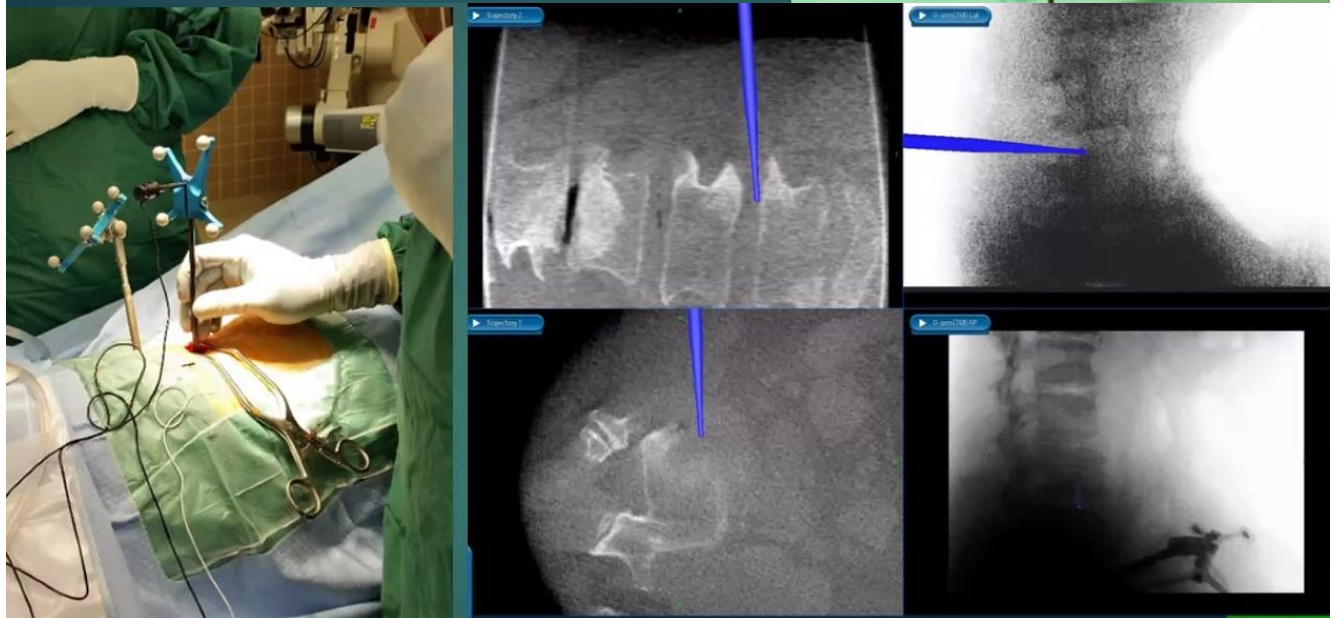
- start with the level **furthest from tracking (reference) frame** – to maintain accuracy as anatomy shifts during interbody grafting.
- reference frame pin in ASIS*.
*if frame gets into way, place into PSIS



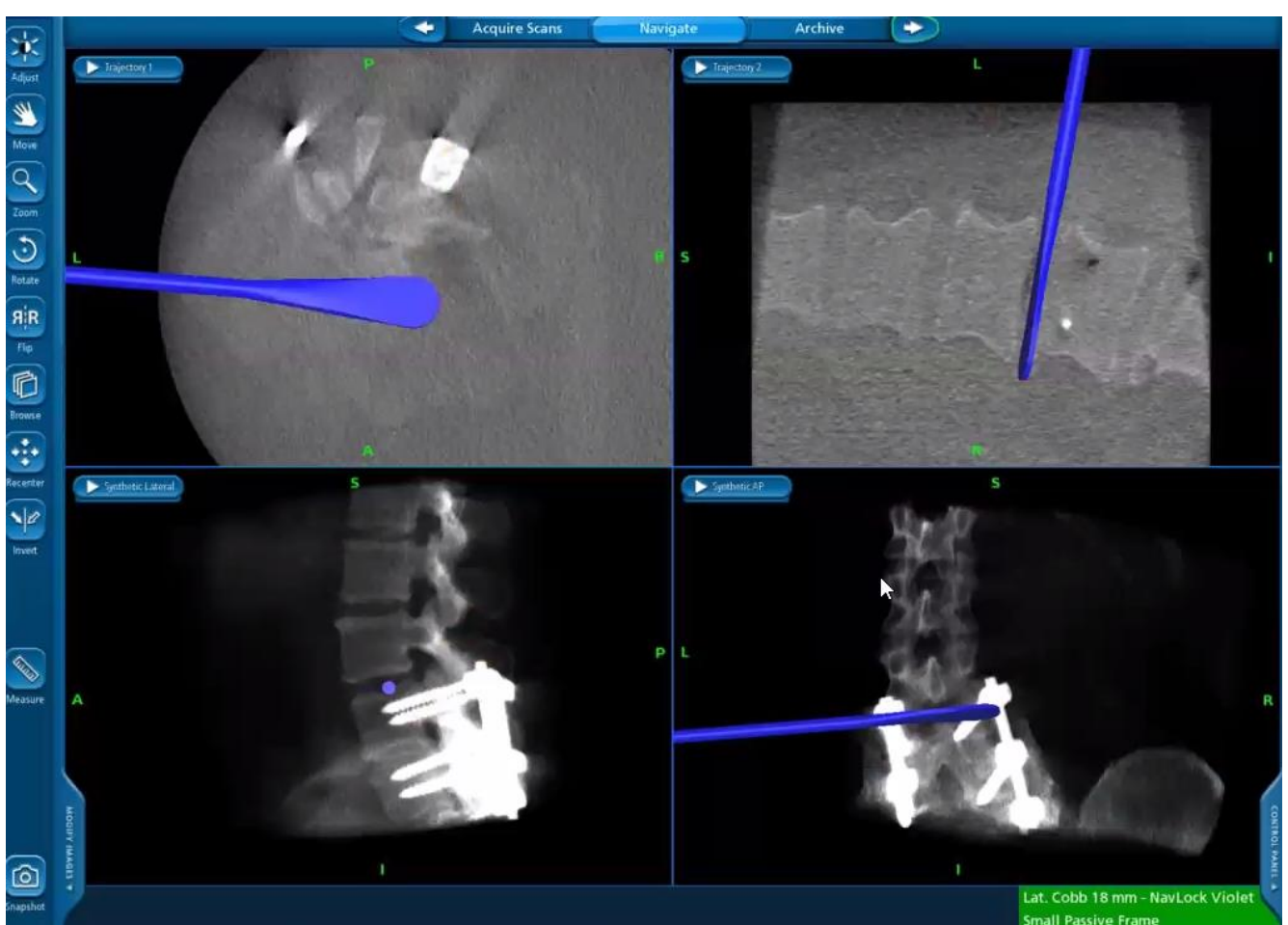
- one O-arm “spin” can include 4 levels (e.g. L1-5).
- use navigated pointer to project skin incision, then to traverse psoas:

Multi-function tool:

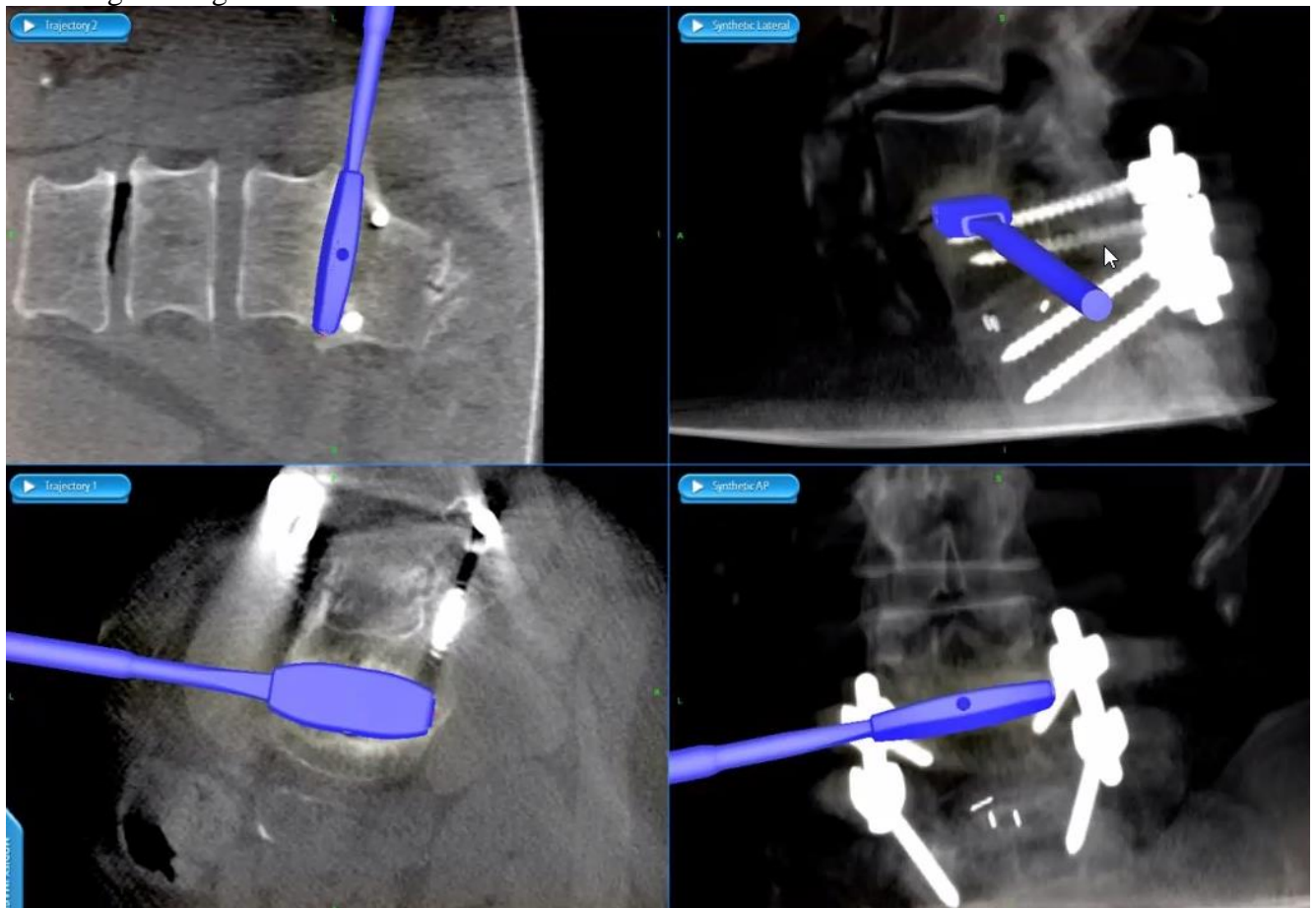
1. Navigation pointer
2. Nerve stimulator
3. Initial retractor dilator



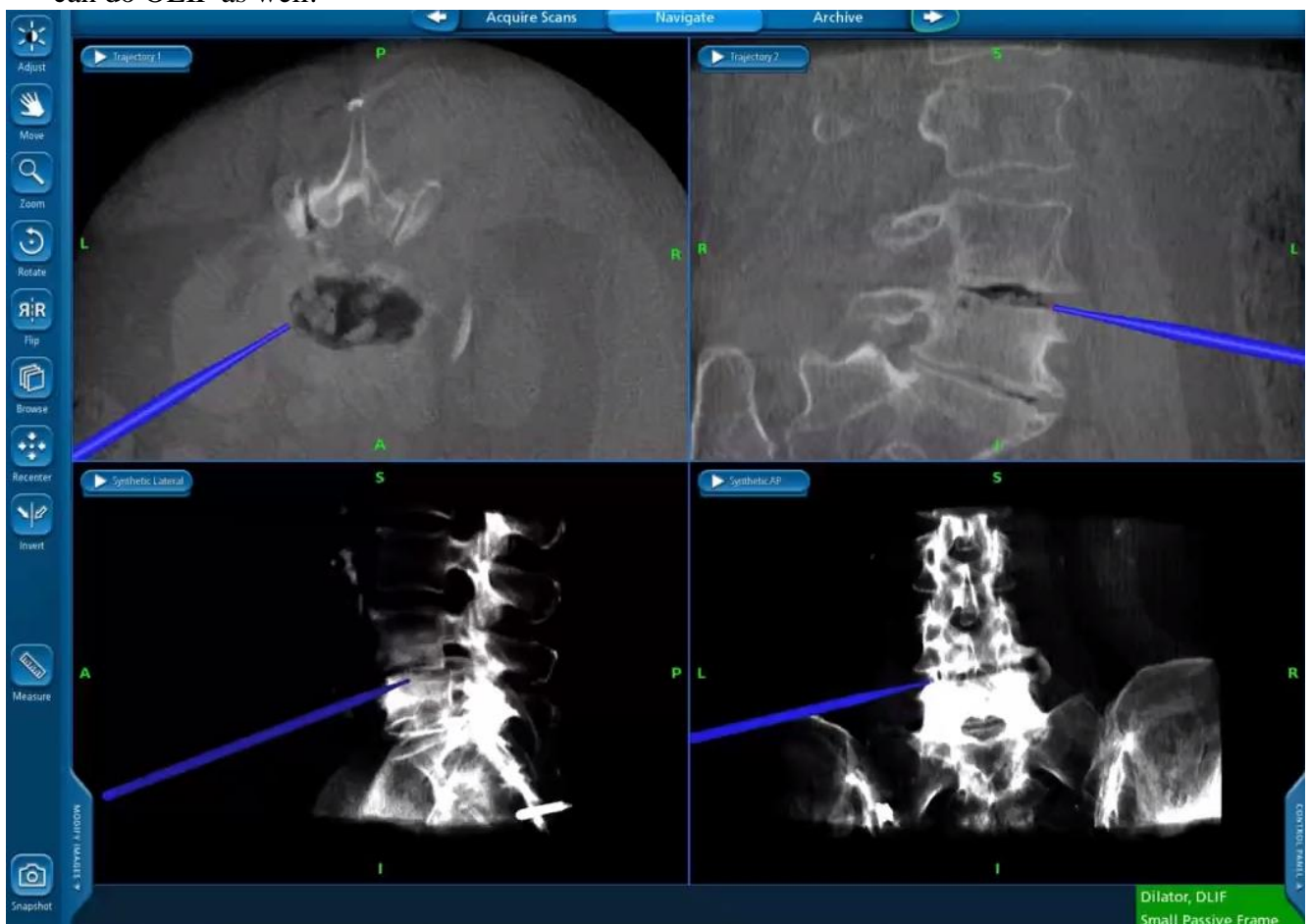
- navigated Cobb for contralateral release:



- navigated cage trials:



- can do OLIF as well:



LATERAL LUMBAR CORPECTOMY

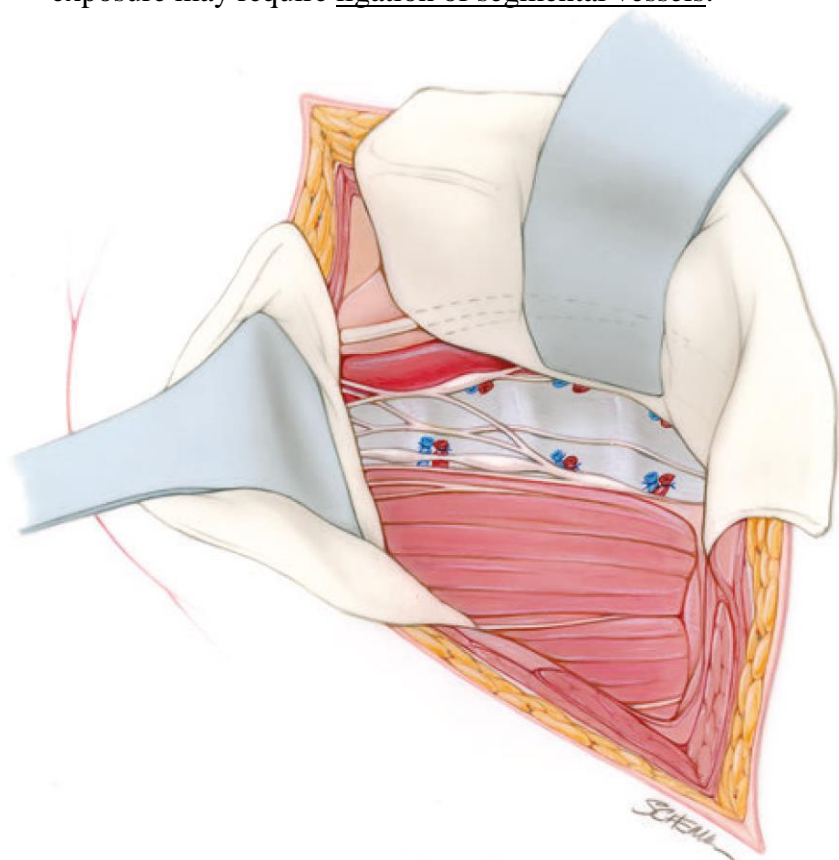
PRONE POSITION

- so can do posterior instrumentation without repositioning the patient.
- practical advice – do posterior part first, place pedicle screws (help to orient on XR, help to distract index level when placing cage), leave navigation frame attached (so can use navigation in addition to XR).
- otherwise, as an adjunct to cage, instrumented stabilization requires lateral exposure of vertebral bodies rostral and caudal to the level of pathology → placing lateral plate.
 - following lateromedial subperiosteal dissection, the lateral vertebral margins may be contoured with a high-speed drill and cutting bur to create flush apposition with the plate.

APPROACH

- Trios spinal table (or any similar modern spinal table).
- tape patient to the table around thighs and chest (plus bed-attached lateral support pads for hip and axilla area – on the patient's right side).
- take lateral XR to mark index lumbar vertebra projection on the flank / chest skin (use cross-shaped radiomarker).
- make 8 cm incision along and over the rib, down to rib bone.
- subperiosteal dissection around the rib using Bovie on low setting (15-20) – neurovascular bundle gets dissected away.

- pass rib dissector (comes in symmetric right and left hand configurations) under the rib – slide up and down the rib to lift off the periosteum.
N.B. parietal pleura is thin and attached to rib – easy to injury (repair it after rib removal with 2-0 Vicryl)
- using rib cutter remove rib segment (later will use it for bone graft).
- using dissector, finger, sponge stick – dissect parietal pleura away from posterior chest wall and towards index vertebra.
- place tubular retractor guides to dock over index vertebra → slide main retractor over → open retractor blades over index pathology under XR control.
- exposure may require ligation of segmental vessels:



- segmental lumbar arterial branches arise at the midvertebral level.
- radiculomedullary artery of Adamkiewicz (RA) is known to have a variable distribution and a tendency to arise from the left thoracolumbar region. As it nears the neural foramen, collateral vascular supply to the RA diminishes, and for that reason segmental lumbar arteries are divided in the midline.
- anterior thoracolumbar spinal cord receives collateral vascular supply, and surgical division of a single segmental lumbar artery at the level of the neural foramen is not known to cause spinal cord infarction. Routine preoperative angiography to evaluate the artery of Adamkiewicz (RA) is not indicated, nor should the occurrence of the RA in the surgical path warrant aborting an indicated thoracolumbar procedure.

CORPECTOMY

- use long instruments.
- requires disc exposure rostral and caudal to the level of pathology.
 - disks flanking the pathological vertebral level are grossly resected.
- bipolarize / clip → divide segmental artery that travels at mid-vertebral body level (if concerned that the caliber is very big and might be Adamkiewicz artery, place temporary clip and watch neuromonitoring signals for change).
- preserve nerve root.
- vertebrectomy proceeds from a lateral trajectory with an osteotome / ultrasonic bone scalpel, followed by curettage to salvage bone for grafting.
 - in cases where vertebral bone is unsuitable for graft, such as infection or malignancy, vertebrectomy is performed with a high-speed drill and a diamond bur.
 - **anterior and contralateral margins of the vertebral body** remain as barriers to the great vessels.
 - fine posterior bone dissection is performed with Kerrison rongeurs and curettage.
 - posterior longitudinal ligament may be excised for thecal decompression.
- flanking cartilaginous end plates are curetted and fashioned prior to fusion.
- distraction pins may be used or the bend in the operating room table or distraction on pedicle screws is used to place the graft cage (filled with bone graft) under compression.
N.B. caution should be used when distracting below calcified vessels, which may rupture!
- recommend expandable cage for the best fit.

CLOSURE

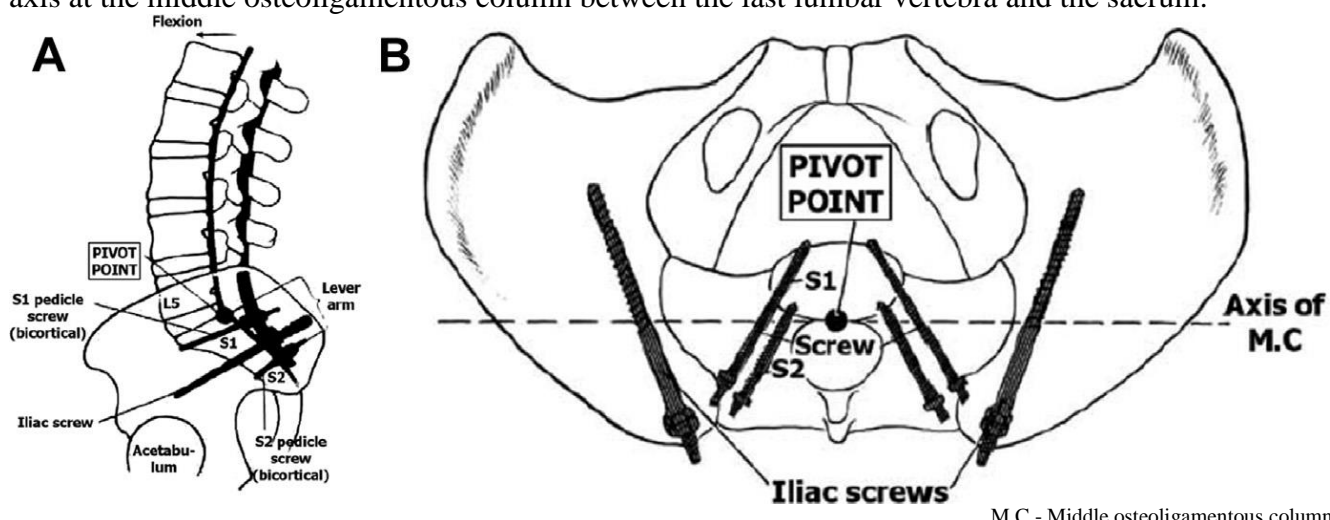
place rubber-red catheter (e.g. pediatric Foley) inside pleural cavity → close soft tissues → put end of Foley into water basin → Valsalva → pull catheter and completely close incision.

(SACRO)PELVIC FIXATION

- large biomechanical stress - fixation between the mobile lumbar spine and the far less mobile sacrum (lumbosacral junction is subject to shear forces as high as 100 N during bending).
- rigid fixation to the pelvis is crucial when maintaining sagittal alignment.
- sacral pedicle screws alone, such as those at S1 and S2, are prone to failure under less load than when they are used in combination with additional pelvic fixation (addition of iliac screws results in the most significant decrease in the strain on S1 screws).

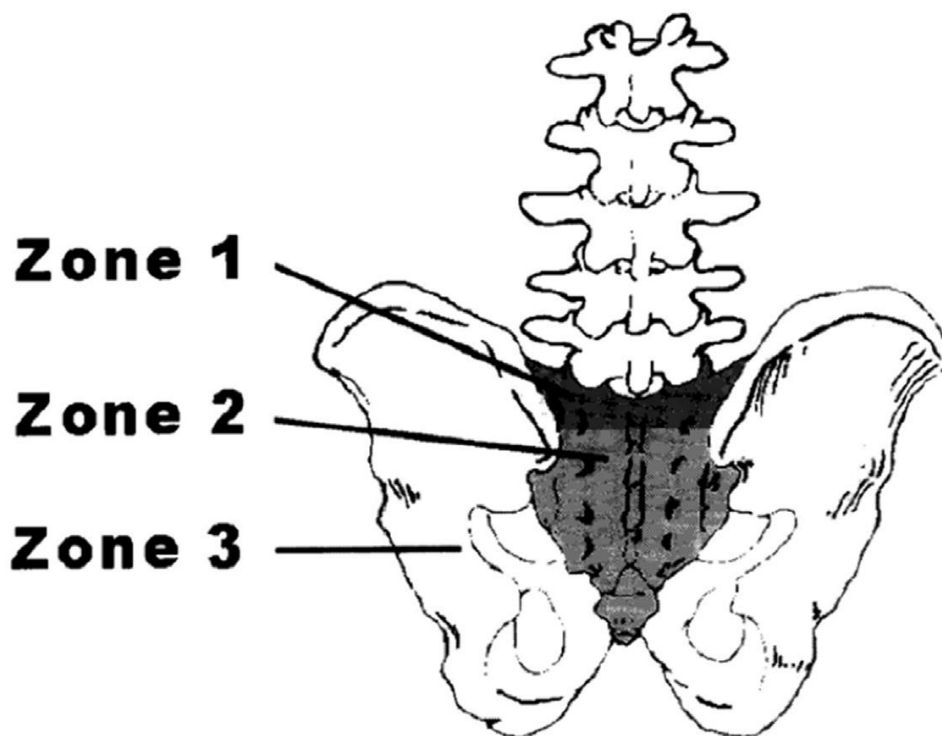
N.B. goal of iliac screws is to offload S1 screws!

McCord and colleagues introduced the concept of a biomechanical **lumbosacral pivot point** - central axis at the middle osteoligamentous column between the last lumbar vertebra and the sacrum:



O'Brien postulated that sacral fixation can be defined in terms of 3 anatomic zones:
 Zone 1 = S1 vertebral body, cephalad sacral alae.
 Zone 2 = from caudad sacral alae, through S2 body down to tip of coccyx.

Zone 3 = ilia.



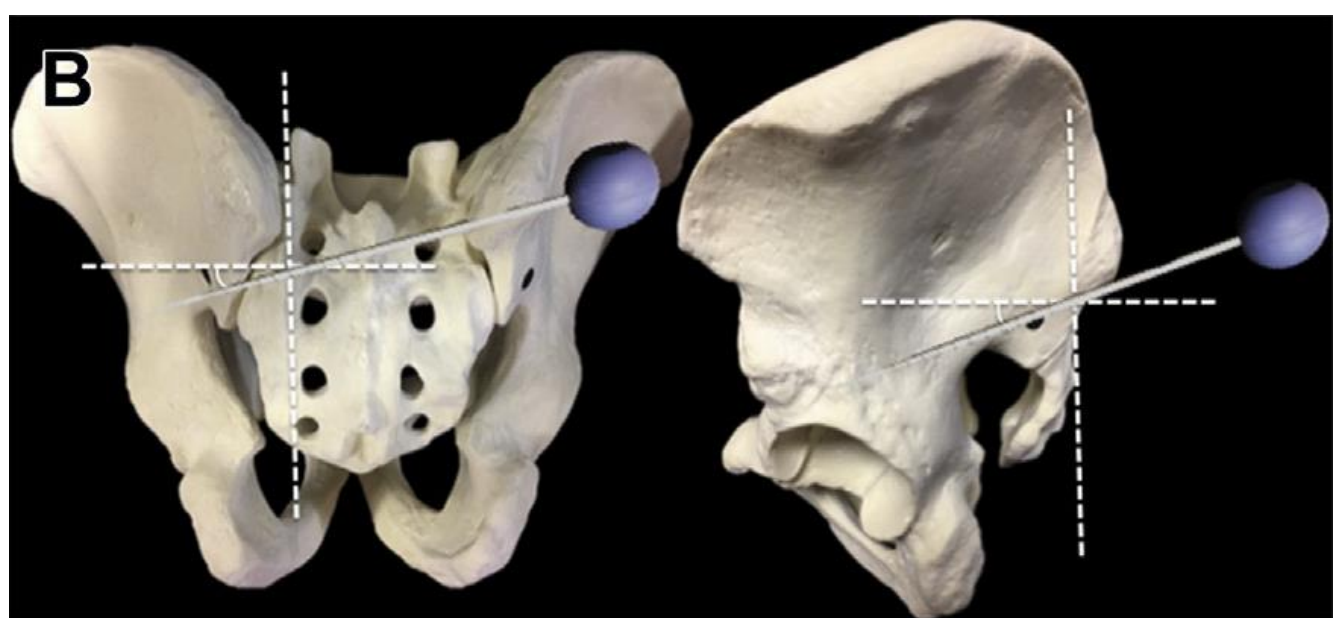
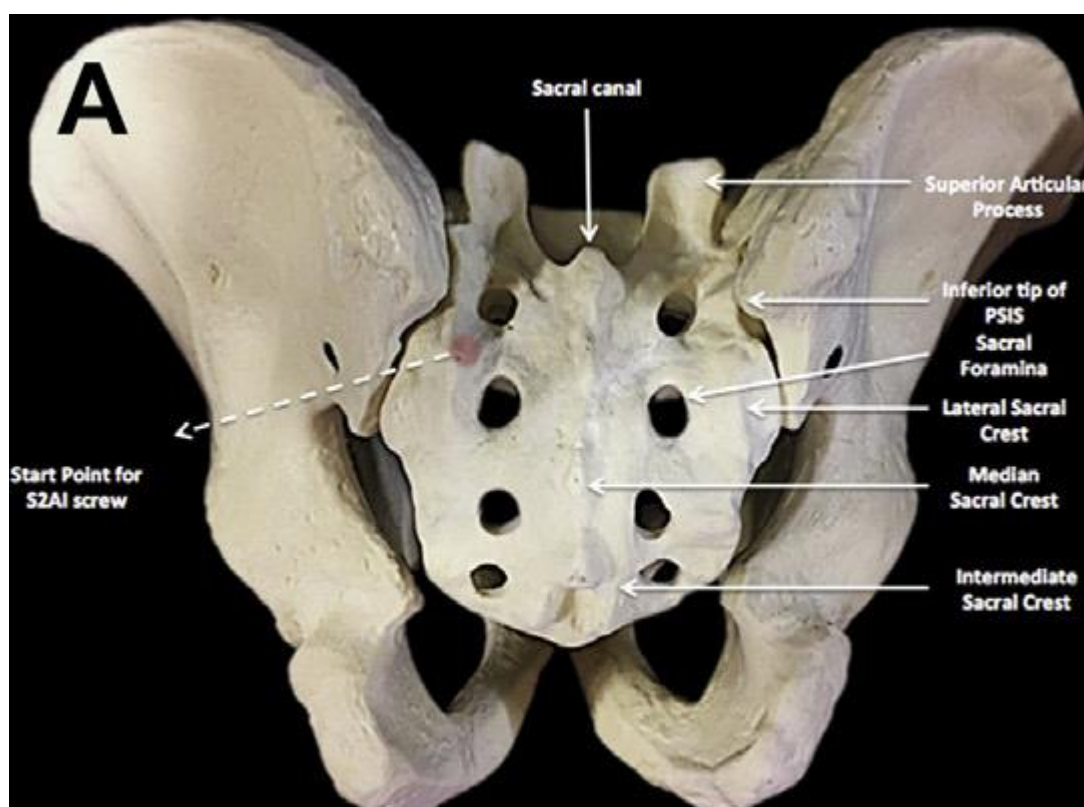
- zones carry clinical significance in that construct stability improves as fixation moves caudally through the zones with zone 3 affording the greatest biomechanical resistance to pull out.
- instrumentation through the ilium allows for fixation points anterior to the lumbosacral pivot point further enhancing stability.

INDICATIONS

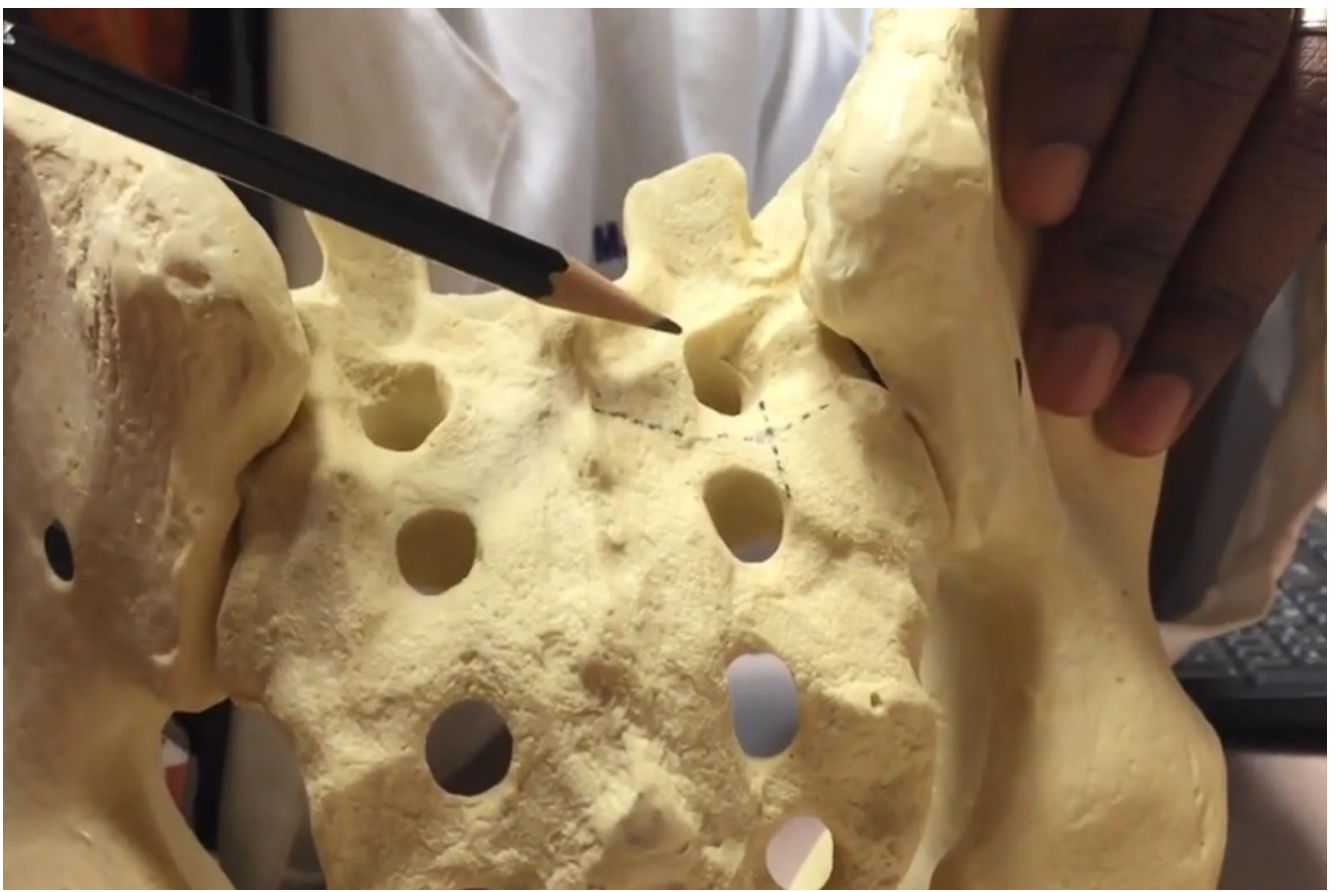
- 1) high-grade spondylolisthesis
- 2) long fusion constructs (extending cranially to thoracolumbar junction or at least to L2)
 - it is a prudent practice to consider sacropelvic fixation anytime instrumentation is extended into the sacrum.
- 3) sacral fractures
- 4) sacral tumors
- 5) flat back deformities
- 6) 3-column osteotomies
- 7) correction of pelvic obliquity

S2-ALAR-ILIAC (S2AI) SCREW

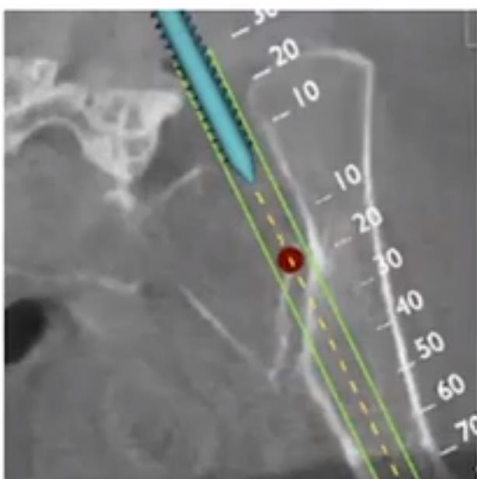
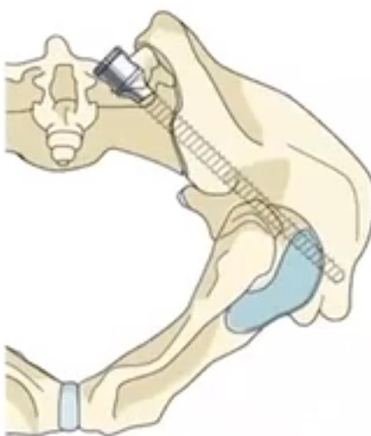
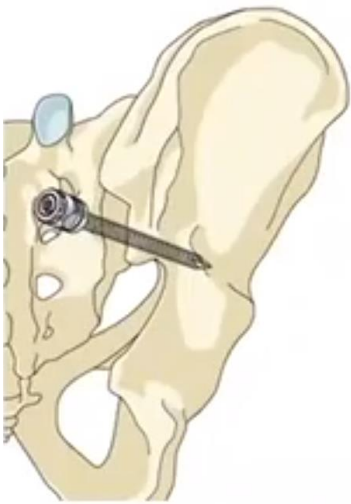
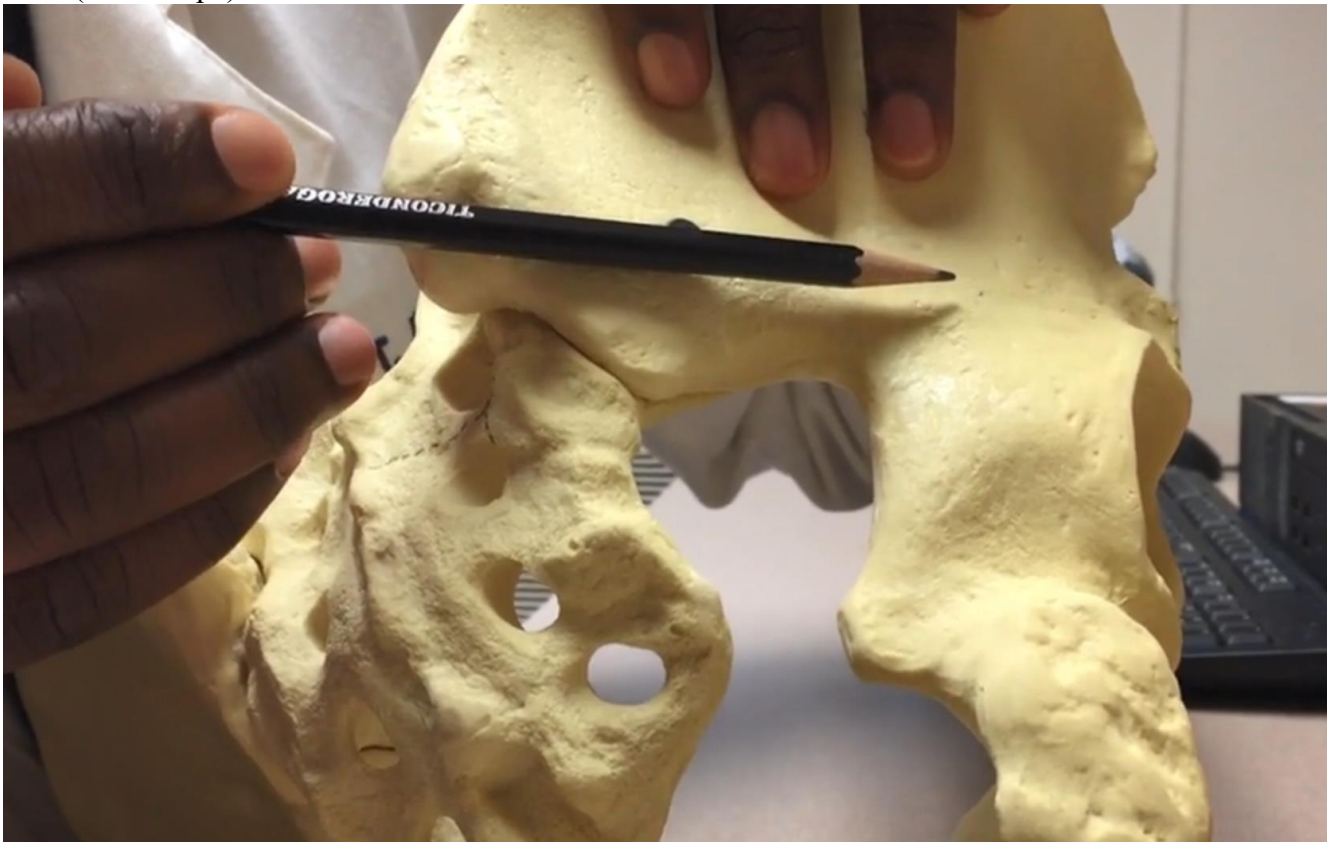- first described by Sponseller and Kebaish in 2007.
- biomechanically the best sacropelvic fixation method!



Starting point – lateral border, midway [err closer to S1] between S1 and S2 dorsal foramina (screw is placed in line with the S1 screw - obviates rod connectors and allows for easier rod insertion):



Trajectory – just above greater sciatic notch (40 degrees lateral and 20-40 degrees caudal), aiming at AIIIS (“tear drop”):



- feel some resistance while crossing SI joint; lots of cortical surfaces to cross!
- trajectory is undertapped 1 to 2 mm less than the desired screw diameter only if more than one screw pathway had been created; tapping is performed with a cannulated tap over a K-wire, ensuring first that a bony floor is present to avoid damage to any soft tissue or neurovascular structures distal to the screw path.

Screw seize:

At least 90 mm length

Diameter 8-10 mm (usually 8.5 mm).

DOUBLE S2-AI SCREW

- space between S1 and S2 foramen is divided in half before screw insertion:
 - first screw insertion site is centered at the top half near the S1 foramen.
 - second screw insertion site is centered at the bottom half near the S2 foramen.

ILIAC SCREWS

Hardware systems

Isola (DePuy)

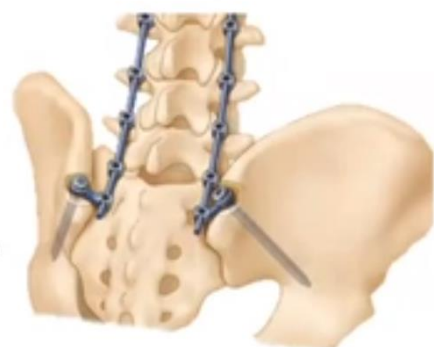Xia (Stryker)

Benefits

- Reduce cantilever forces
- Solid foundation and strong fixation strength¹

Challenges

- Prominent screwheads²
- Linking to previous screwheads within the construct when tulip heads not aligned²
- Offset from rest of the construct which can cause soft tissue irritation¹
- Radiographic halos around rods³



S2AI screws are better – less tissue dissection, less prominent screws, easier rod connection, better biomechanics! >>

INDICATIONS

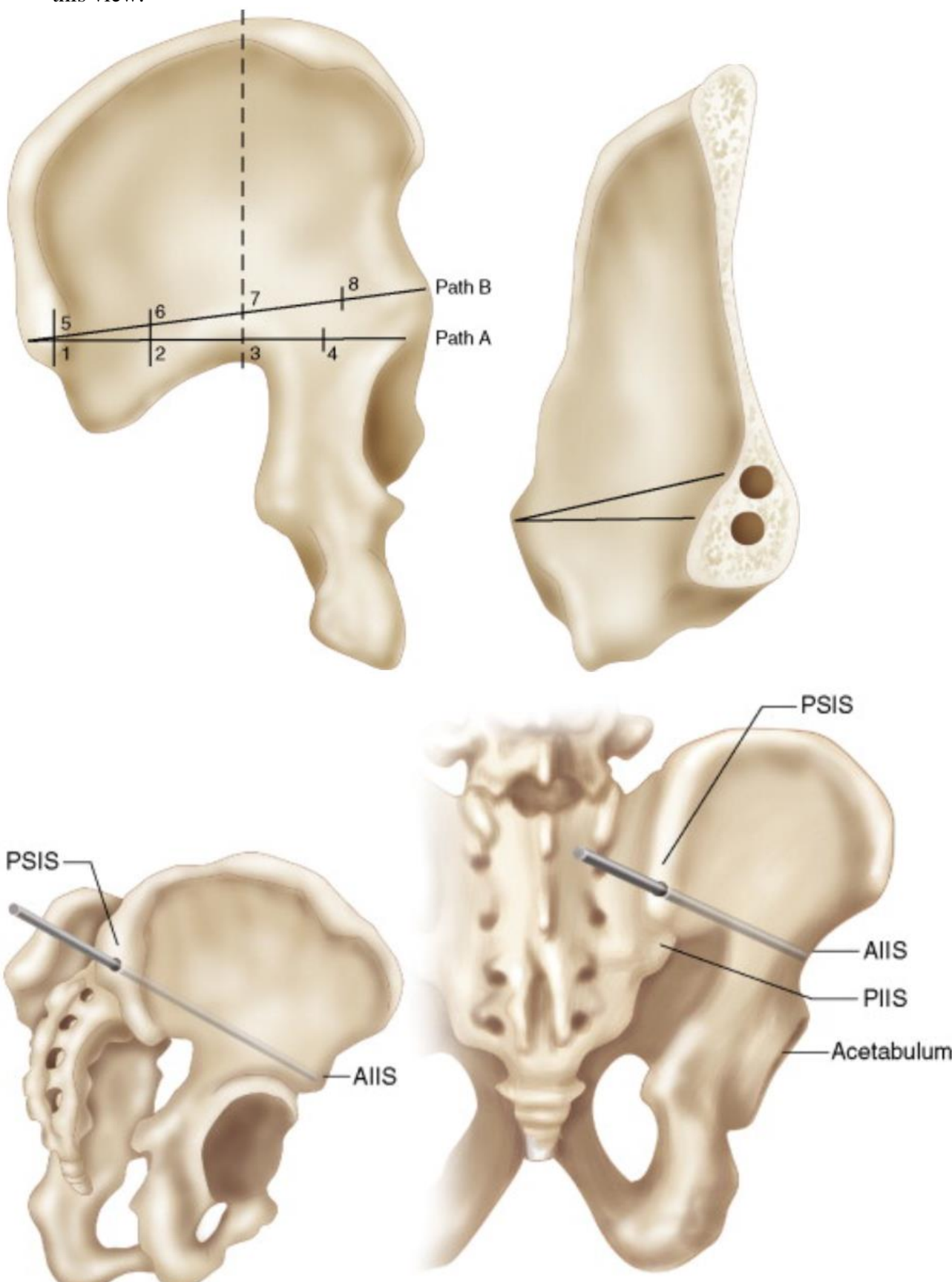
1. Long segment fusions to the sacrum, particularly in patients prone to L5-S1 pseudarthrosis, such as patients with global or lumbar sagittal imbalance or bony deficiency.
N.B. in long T-L-S constructs add L4-S1 interbodies to prevent rod fractures
2. Degeneration caudad to long segment fusions.
3. High-grade spondylolisthesis
4. Correction of pelvic obliquity
5. Correction of flat back syndrome requiring osteotomy

PROCEDURE

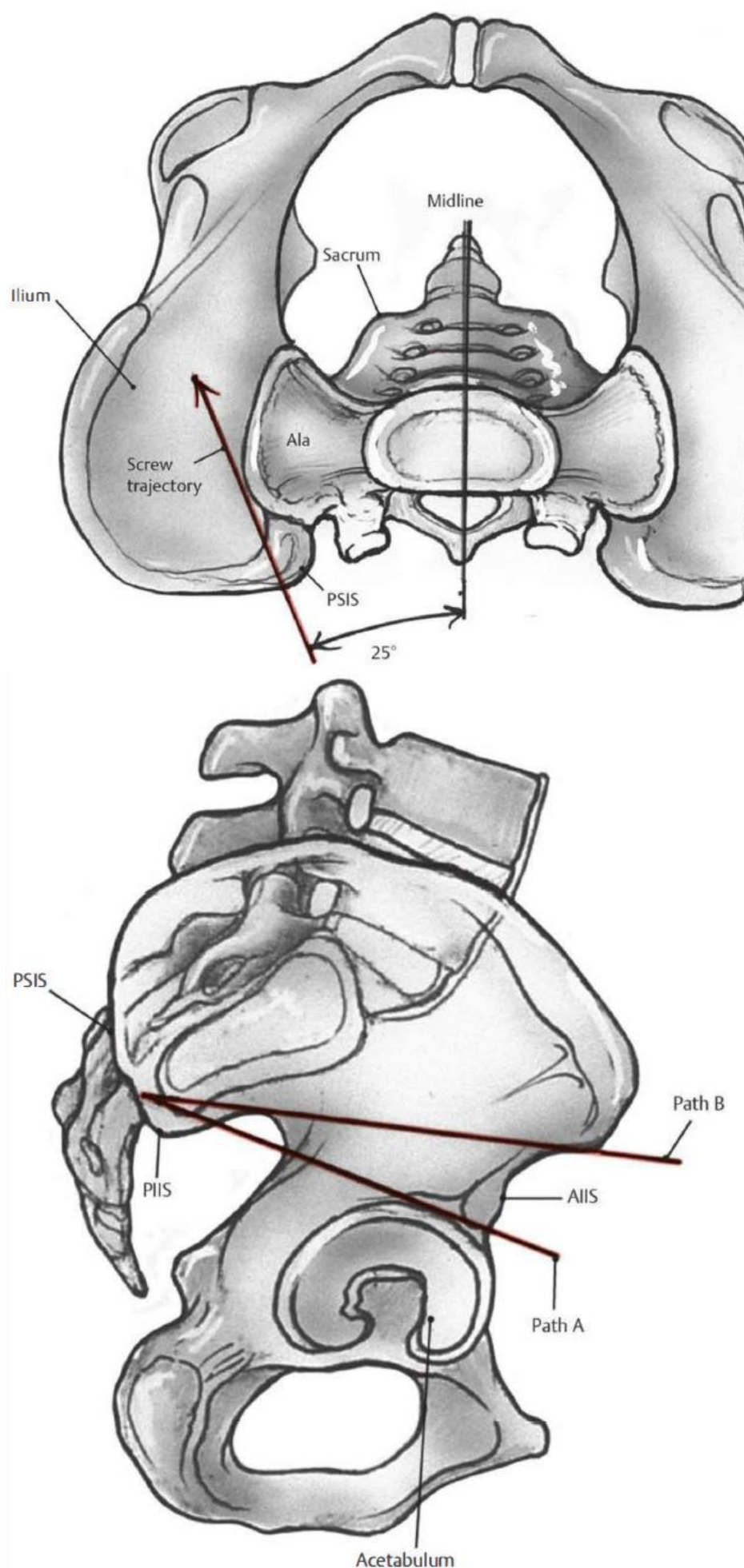
- position – prone on Jackson table; thighs are maintained in extension to maximize lordosis; adding slight relative kyphosis in the sagittal plane allows for better access to the structures of the lower lumbar spine and pelvis.
- iliac screws should be placed last, after all other pedicle screws have been placed; be aware of screw alignment in longer constructs.
- extensive exposure is required increasing the amount of *blood loss*.
- posterior superior iliac spine is identified by finger palpation → slightly oblique incision is then carried through the lumbosacral fascia over the posterior superior iliac spine; Cobb may be used to peel the soft tissue at the outer end plate of the iliac bone up to the sciatic notch, to ensure that the pathway of the screw is superior to the notch.

Galveston technique

- start at **posterior superior iliac spine (PSIS)** – bite with rongeur a 1-2 cm chunk off to accommodate screw head - screw should be recessed more than the remaining bone anterior and posterior to the PSIS to decrease the chance of hardware prominence.
- target trajectory towards:
 - a) **superior rim of the acetabulum** (aiming 35 degrees caudad) – places the hip joint at risk and is less desirable.
 - b) **anterior inferior iliac spine (AIIS)** – accommodates a longer screw and is safer; use live fluoroscopy aiming from PSIS towards femoral trochanter (typically aiming 25 degrees lateral from the midline and 30 degrees caudad) – should see “teardrop” – screw goes perfectly along this view.

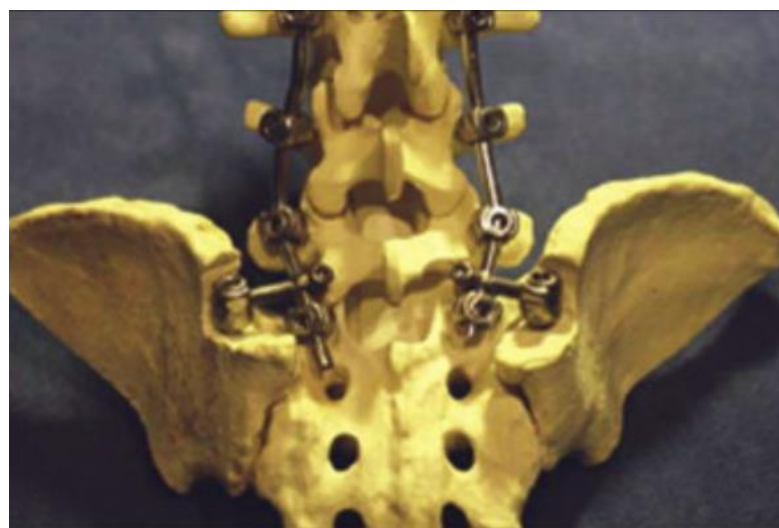


Source of picture: R. Jandial “Core Techniques in Operative Neurosurgery: Expert Consult - Online and Print”, 1st ed (2011), Saunders; ISBN-13: 978-1437709070 >>

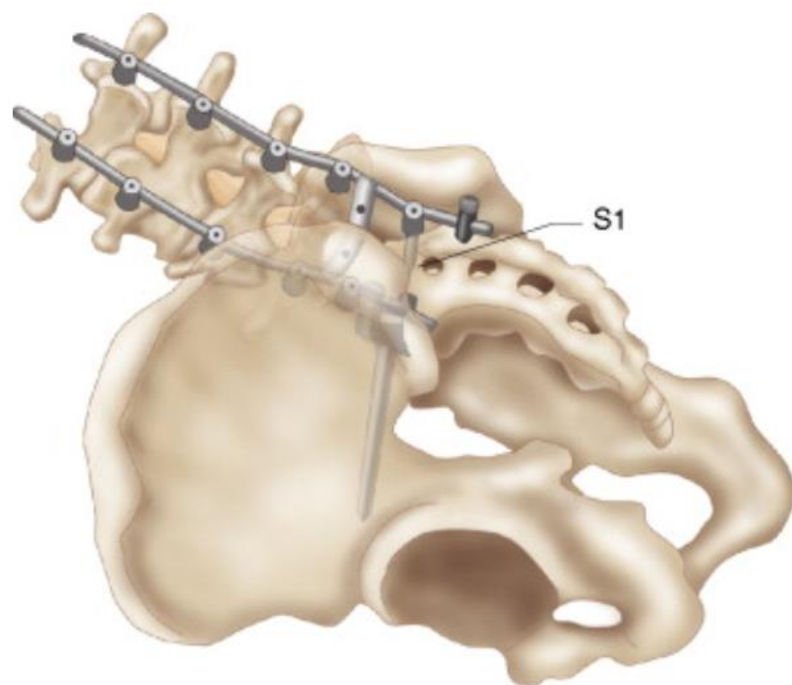


Source of picture: R. Nader "Neurosurgery Tricks of the Trade – Spine and Peripheral Nerves" (2014), ISBN-10: 1604069147, ISBN-13: 978-1604069143 >>

- iliac screws measure 7.5-8.5 mm in diameter; length at least 80 mm.
- Tomlinson et al have shown that little difference exists in construct stiffness and lumbosacral motion between **unilateral** and **bilateral** iliac screws when screw length is at least 80 mm.
- connection to the rest of fusion rod usually requires **offset connector**.
- bone graft is applied after bone decortications.



Source of picture: R. Jandial "Core Techniques in Operative Neurosurgery: Expert Consult - Online and Print", 1st ed (2011), Saunders; ISBN-13: 978-1437709070 >>

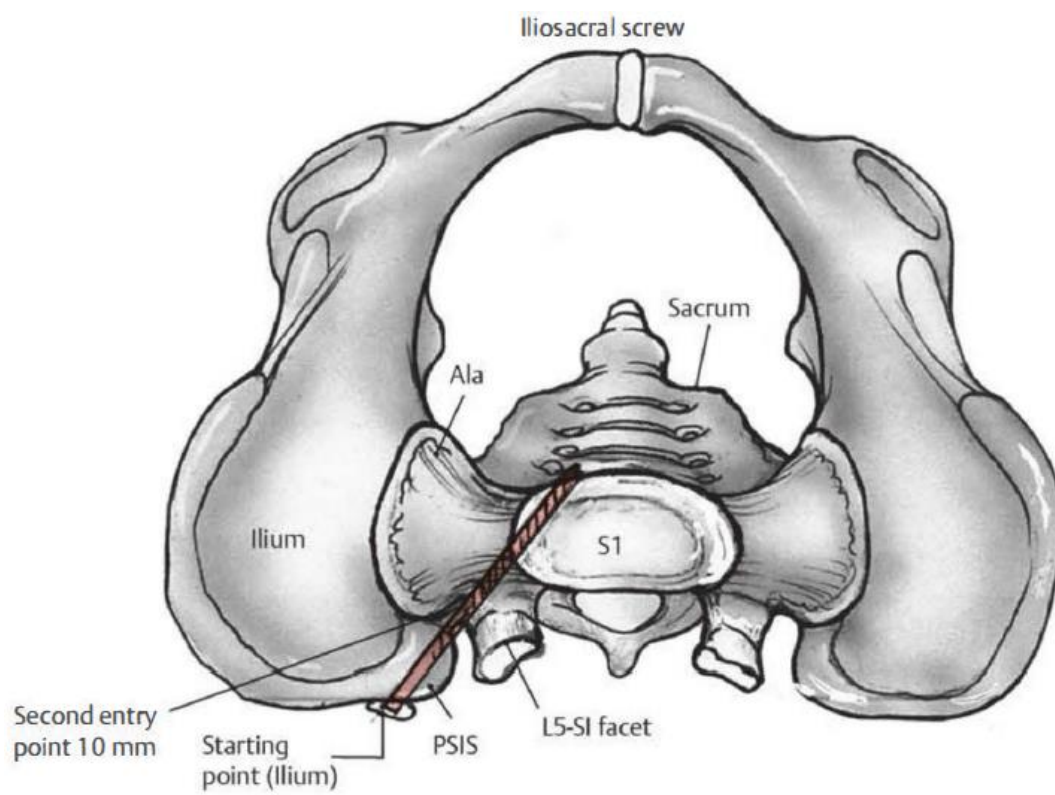


Source of picture: R. Jandial "Core Techniques in Operative Neurosurgery: Expert Consult - Online and Print", 1st ed (2011), Saunders; ISBN-13: 978-1437709070 >>

ILIOSACRAL SCREWS

- starting point is scored at the outer aspect of the ilium, just distal to L5- S1 facet.
- second entry point is marked 10 mm anterior to the posterior superior iliac spine at the posterior gluteal line.

- screw trajectory is toward the L5-S1 facet joint (same trajectory as for a medially placed S1 pedicle screw); guidewire is passed through the iliac wing toward the sacrum to the body of S1; connector is then threaded onto the guidewire as it passes the ilium; screw path is drilled over the guidewire.
- typical screw length is 60- 80 mm.

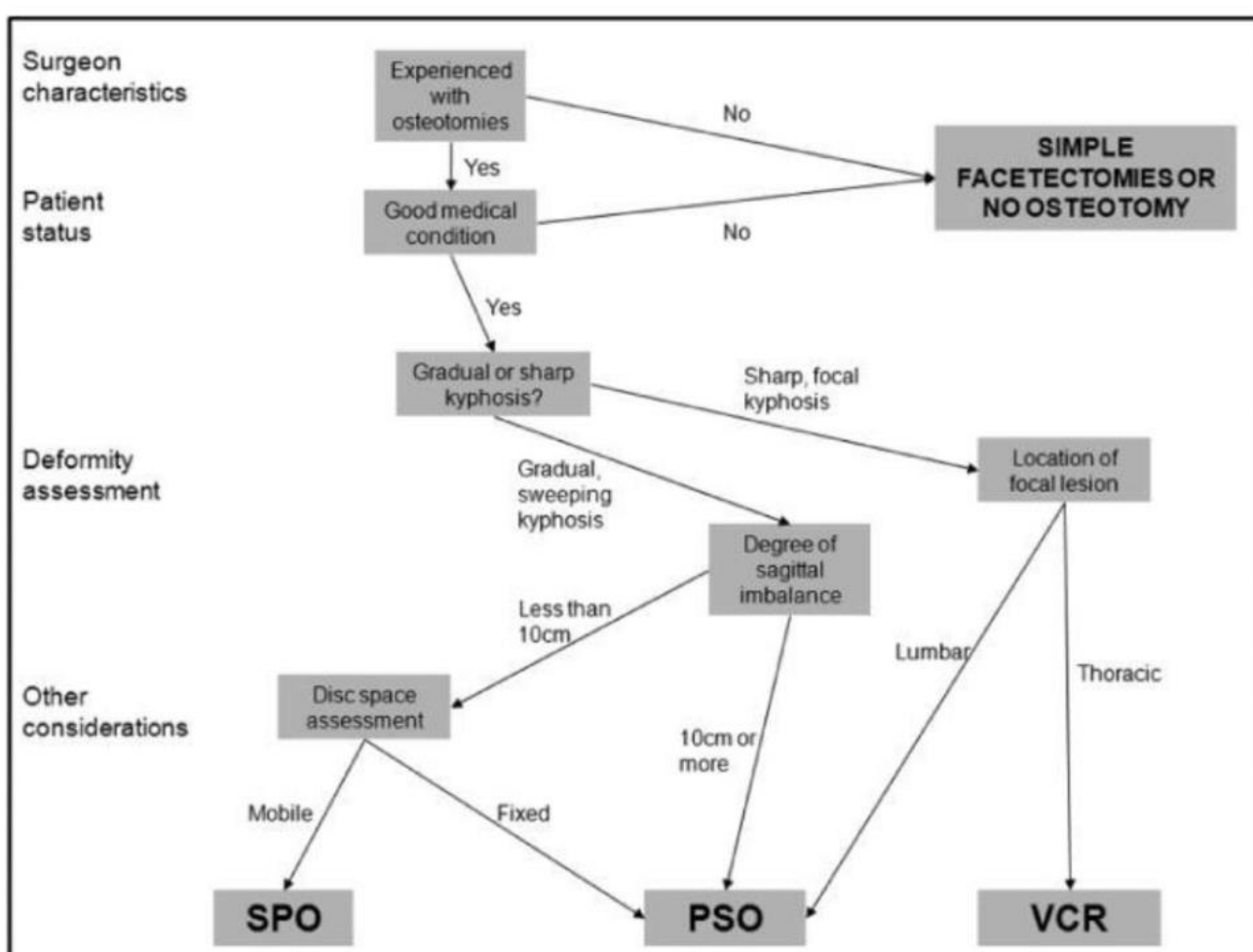


Source of picture: R. Nader "Neurosurgery Tricks of the Trade – Spine and Peripheral Nerves" (2014), ISBN-10: 1604069147, ISBN-13: 978-1604069143 >>

Osteotomies

Spinal osteotomies are generally needed when the deformity is not correctable with the use of instrumentation alone or when facet or ligament releases are insufficient to gain enough flexibility.

- try to avoid osteotomies if you can



Osteotomies in the posterior-only treatment of complex adult spinal deformity: a comparative review. Dorward, IG, Lenke, LG, JNS Mar 2010

Classification #1

Kamil Cagri Kose, Omer Bozduman, Ali Erkan Yenigul, and Servet Igrek. Spinal osteotomies: indications, limits and pitfalls. EFORT Open Rev. 2017 Mar; 2(3): 73–82. Published online 2017 Mar 24. doi: 10.1302/2058-5241.2.160069 PMID: 28507779

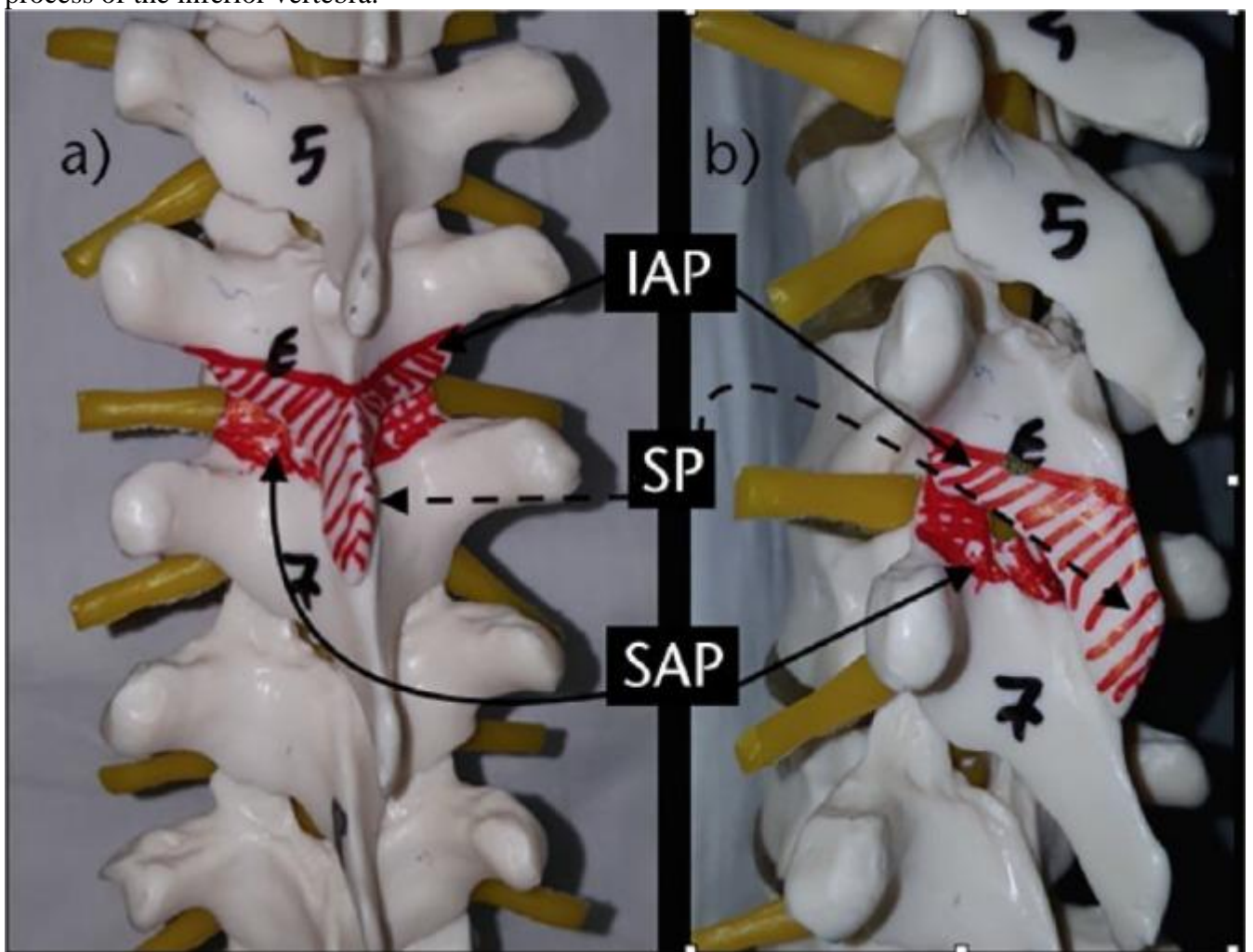
In order of increasing complexity:

1. **Smith-Petersen osteotomy (SPO)** - posterior column osteotomy in which the **posterior ligaments** (supraspinous, intra-spinous ligaments and ligamentum flavum) **and the facet joints** (inferior facets of the upper vertebra + superior facets of the inferior vertebra).
 - correction is performed **through the disc space** - mobile anterior disc is essential.
 - both coronal and sagittal correction can be achieved.
 - best in patients with +6-8 cm C7 plumbline.

- amount of correction is $9.3^\circ - 10.7^\circ/\text{level}$ (1° per millimeter of bone resected).
- if substantial correction is achieved with an extensive SPO opening anterior disc level (greater than 10 mm in height), it may be necessary to graft the disc space anteriorly.
- procedure was first described by **Smith-Petersen** in 1945.
- in 1984, **Ponte** described a very similar technique in Scheuermann's kyphosis cases.

The spinous process and facets of the upper vertebra are removed in addition to the superior facets of the inferior vertebra; areas to be removed are painted in red.

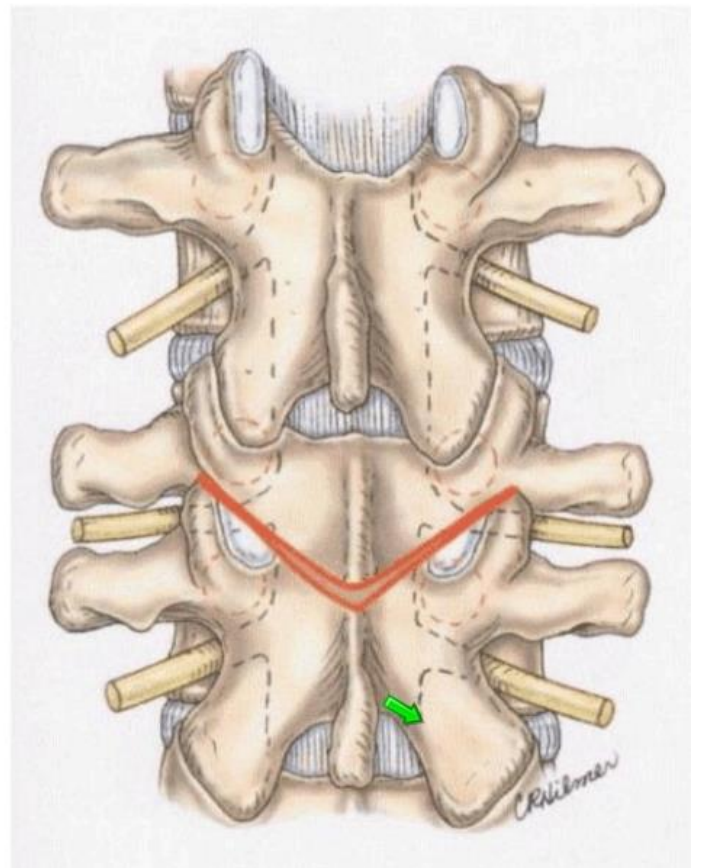
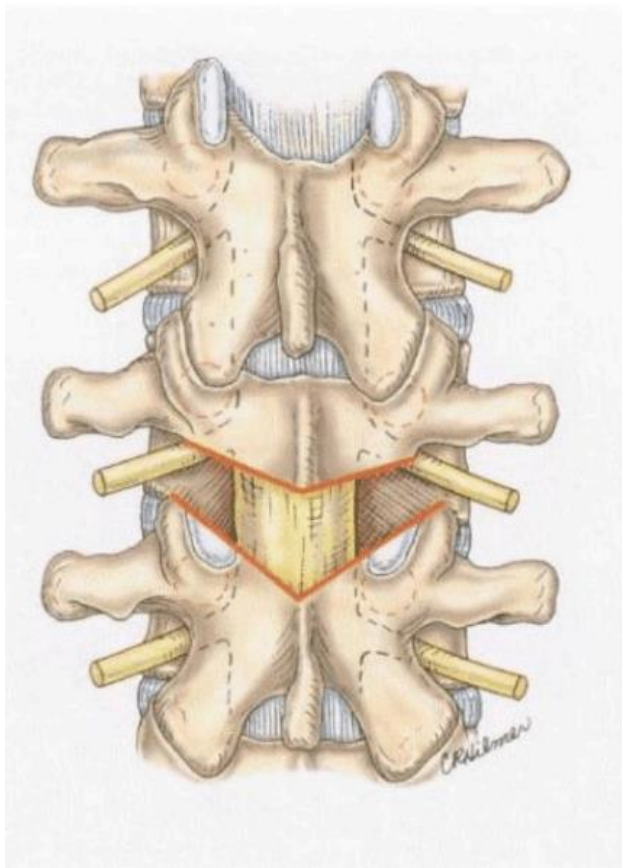
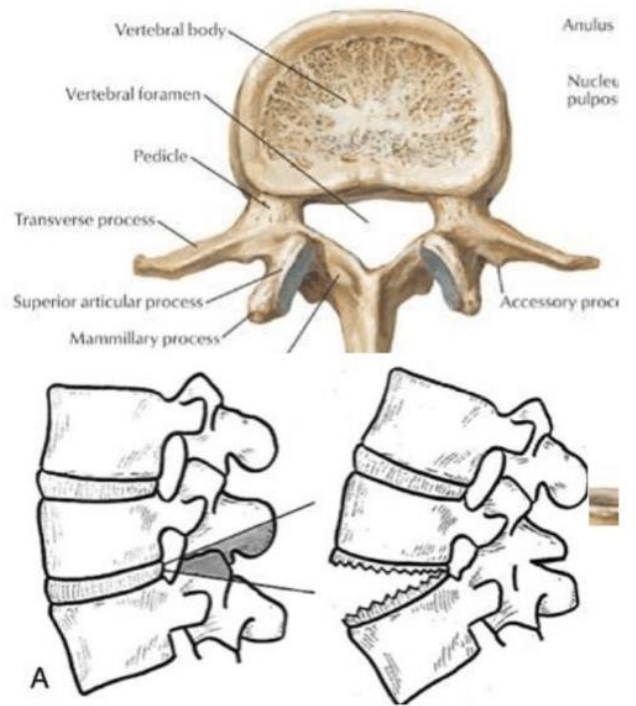
IAP, inferior articular process of the superior vertebra; SP, spinous process; SAP, superior articular process of the inferior vertebra.



- In 1945, Smith-Petersen et al. reported the first spinal osteotomy.
- Most studies reported the correction in ankylosing spondylitis patients with osteoclasts
- Ponte described similar bone resection and mobility through an open disc space

Ponte/Smith-Peterson Osteotomy

- SPO allows for 10° per level
- Remove supraspinous, interspinous, and ligamentum flavum with facetectomy to produce a posterior release.
- Ensure exiting nerves are decompressed
- Posterior compression of the osteotomy brings about kyphosis correction



2. **Pedicle subtraction osteotomy (PSO)** - posterior elements and pedicles are removed.
 - then a **triangular wedge** through the pedicles is removed:
 - a) de-cancellation technique ('eggshell' technique - 1985 Heining et al)
 - b) osteotome (1985 first by Thomasen et al)
 - then posterior spine is shortened using the **anterior cortex as a hinge** (i.e. may be used in patients both with open or fused disc space).
 - most useful if done at the apex of the deformity.
 - although originally defined in the lumbar spine, the technique can be used in all regions of the spine above or below the conus including cervical and thoracic areas.
 - ideal candidates are patients with a severe sagittal imbalance (SVA > 12 cm)
 - single level osteotomy can produce 30° - 40° of correction.
 - single level osteotomy at L3 may restore global sagittal balance by an average of 9 cm with an upper limit of 19 cm (if more correction is needed, the osteotomy level can be changed to L4, or in some cases a two-level osteotomy may be planned).
 - up to **2 litres of blood may be lost during** (Cho et al compared three levels of SPO with single-level PSO in a series of 71 patients, and found that single-level PSO caused nearly twice as much bleeding than three levels of SPO).
 - incidence of neurological injury is 3.6-12%.
 - in order to avoid pseudarthrosis (rate up to 29%) interbody arthrodesis above and below the osteotomy can be carried out (either TLIF or ALIF)
 - laminectomy sites may be closed with a cortical strut allograft both to increase mid-line fusion and to prevent any dural complications if revision surgery is needed.
 - traditionally done at L2-3 (below conus) but that is not where normal physiologic lordosis should be; best PSO at L4-5 levels

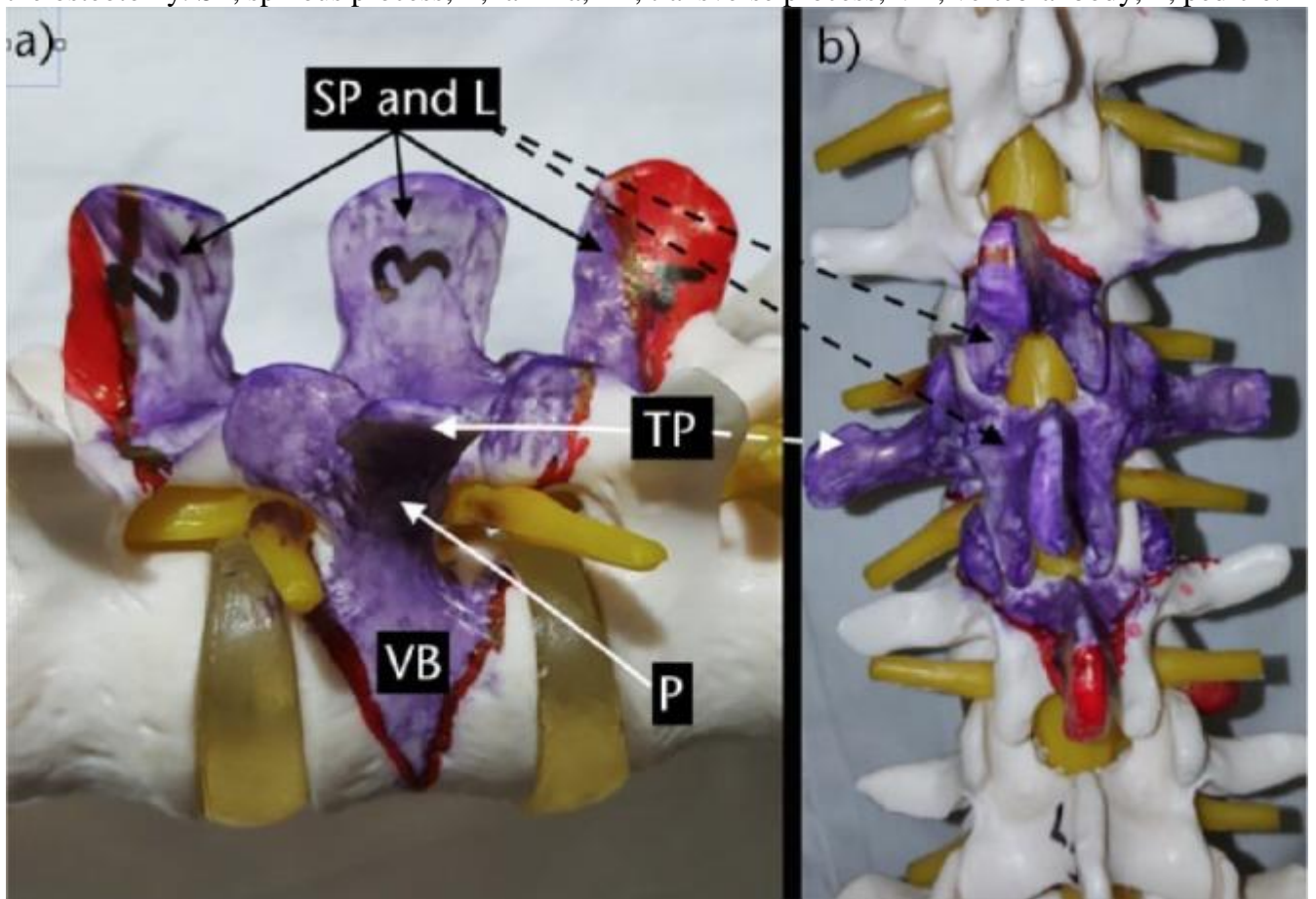
Technique:

- **instrumentation** should be done before any osteotomy attempt - standard pedicle screws are used at least three levels above and below the level of osteotomy.
- **laminectomy** should be one level above and below the planned osteotomy level - **to prevent buckling of the spinal cord**;
 - buckling becomes a more severe problem, especially in cases where a previous laminectomy has been done - peridural fibrosis prevents the gliding movement of the dura as the osteotomy gap is closed.
- in addition to laminectomy, laminar undercutting should be done to widen the spinal canal from within to prevent infolding of ligamentum flavum and bony surfaces.
- all or half of the transverse processes should be removed to gain access to the lateral aspect of the vertebral bodies.
- half of the inferior articular process of the upper vertebra and half of the superior articular process of the lower vertebra can be removed to help create a single foramen to accommodate two nerve roots after completion of the procedure.
- after defining the foramen above and below the pedicles to be excised, the nerve roots with their perineural fat tissue should be protected with a dural retractor.
- pedicles on both sides can be removed using an osteotome or a burr.
- body can then be removed in a wedge-shaped fashion either using the 'eggshell' technique or using an osteotome.
- **transient rod** is placed to prevent sudden collapsing of the spine during these maneuvers (classically, a unilateral rod is used; however, in severe angular kyphotic or kyphoscoliotic deformities, bilateral rods are recommended to prevent spinal subluxation).
- posterior cortex is finally removed before closure of the osteotomy and after the osteotomy is completed including the lateral walls of the vertebral body.

- nuts holding the transient rod are loosened and the osteotomy gap is closed by bending the operating table opposite the deformity.
- **rods** should be angulated acutely at the level of osteotomy and should sit freely in the grooves of the screw heads. Otherwise, when there is a fused spine above and below the osteotomy line, as in ankylosing spondylitis or previous fusion cases, as the rod is not as acutely angulated as the spine, it does not sit into the grooves and pulls the screws just above and below the osteotomy line and causes loss of correction.

a) L3 pedicle subtraction osteotomy plan from the lateral view. Note that a wedge reaching to, but not crossing, the anterior cortex is to be removed. The parts of the laminae painted in red may be preserved if they do not interfere with closure of the osteotomy gap.

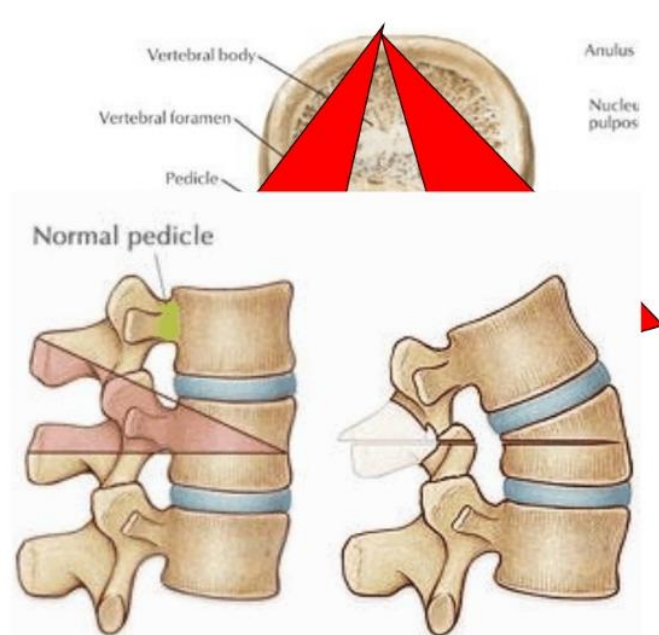
b) While planning an osteotomy, laminectomy of the upper and lower vertebrae should be done to prevent buckling of the spinal cord after correction of the deformity. Again, the area painted in red may not be removed if enough decompression is done and these structures do not prevent closure of the osteotomy. SP, spinous process; L, lamina; TP, transverse process; VB, vertebral body; P, pedicle.



- Pedicle subtraction osteotomy was first described by Thomassen in 1985
- This is an extension of the SPO, and involves resection of the posterior elements and vertebral body
- Particularly useful when anterior approach is not possible

- Set up
- Neuromonitoring
- Measure pre-op, must include pelvic parameters
 - Plan, plan , plan
- Expect blood loss:
 - Cell saver, coagulant (TXA, Amicar), blood products

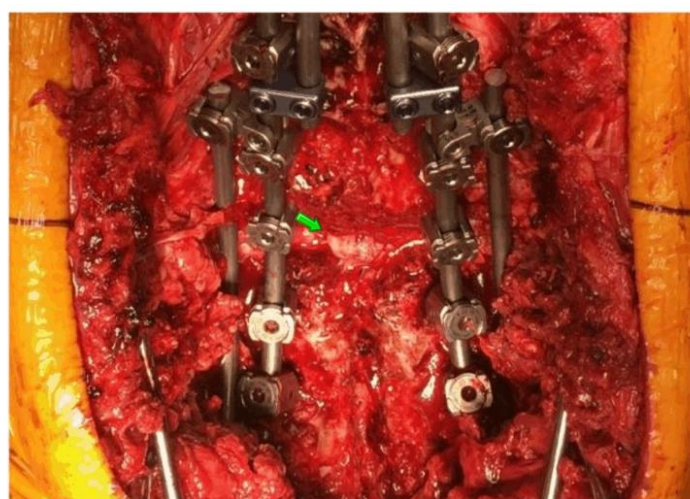
- Typically performed in the lumbar spine
 - Larger correction
 - Can shorten cauda
- Less often in cervical and thoracic spine
- Bony resection determines final alignment



Exposure

- Careful with blood loss
- TXA is MUST
- Place screws first
- If excessive bleeding (>2L, before PSO, plan on staging)
- Instrumentation removal etc...

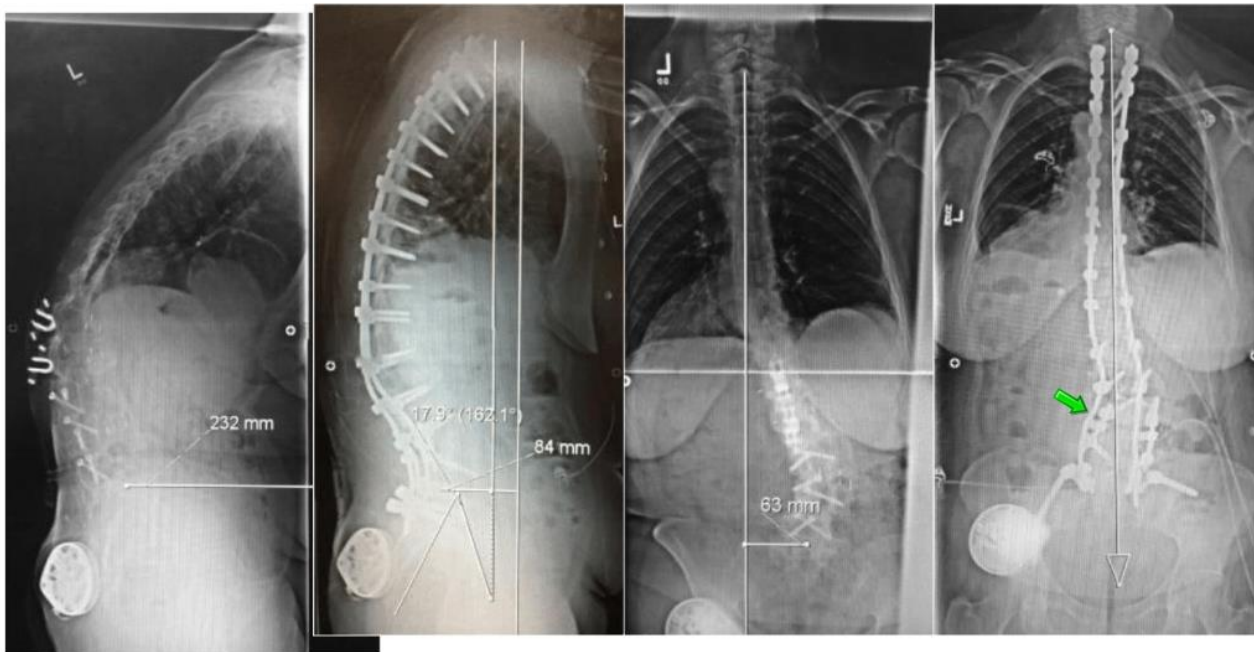
- Dura will buckle
- Verify nerves are free in new foramen
- Feel under the dura
- Check signals
 - Stimulate nerves?



- Neuromonitoring is a must!
- Be careful with shortening the spinal column
 - Duraplasty
 - May want cage in osteoporosis
- Translation causes paralysis!
 - Less of an issue if PSO is in lumbar spine
 - Temporary rods
- Pre-operative planning is the key
 - measure twice and cut once.

Quad-rod technique – two short rods for PSO level, long rods for long support:

L4 PSO, multi PCO, T3- Pelvis



3. **Bone-disc-bone osteotomy (BDBO)** - osteotomy done **above and below a disc level** (resection includes the disc with its adjacent end-plate(s))
- correction rates 35° - 60°.
 - main indications are deformities with **the disc space as the apex** and severe sagittal plane deformities.
 - etiology must be kept in mind when selecting the type of osteotomy (e.g. BDBO may be impossible in ankylosing spondylitis when the anterior annulus is ossified).

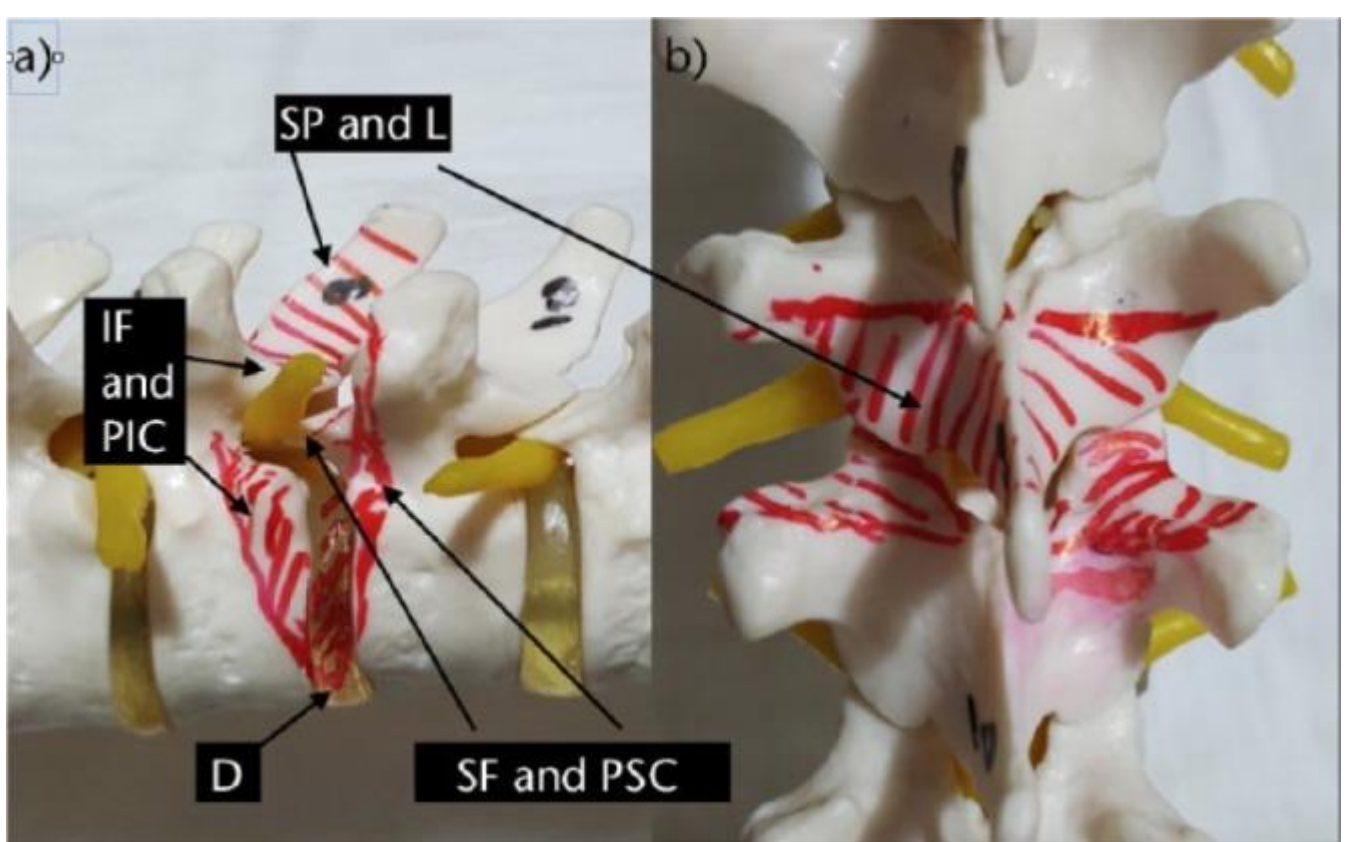
Technique

- pedicle screws are placed at least two levels below and three levels above the planned osteotomy level, followed by wide laminectomies of the vertebrae above and below the disc space planned to be resected.
- wedge osteotomy including the disc end-plate(s) with or without the pedicle(s) is then performed and the wedge including the disc is removed.
- titanium mesh cage can be placed anteriorly if lengthening of the anterior column is desired.
- osteotomy site is closed bone-to-bone to decrease the risk of pseudoarthrosis.

a) Spine from the lateral view. Upper end-plate of T10 and lower end-plate of T9 were included in the area to be resected. Resection should also include the disc space.

b) Spine from the posterior view. Lower facets and spinous process of the upper vertebra and upper facets of the lower vertebra should be removed to gain access to the area to be resected.

SP, spinous process; L, lamina; IF, inferior facet; SF, superior facet; PIC, postero-inferior corner; PSC, posterosuperior corner; D, disc.



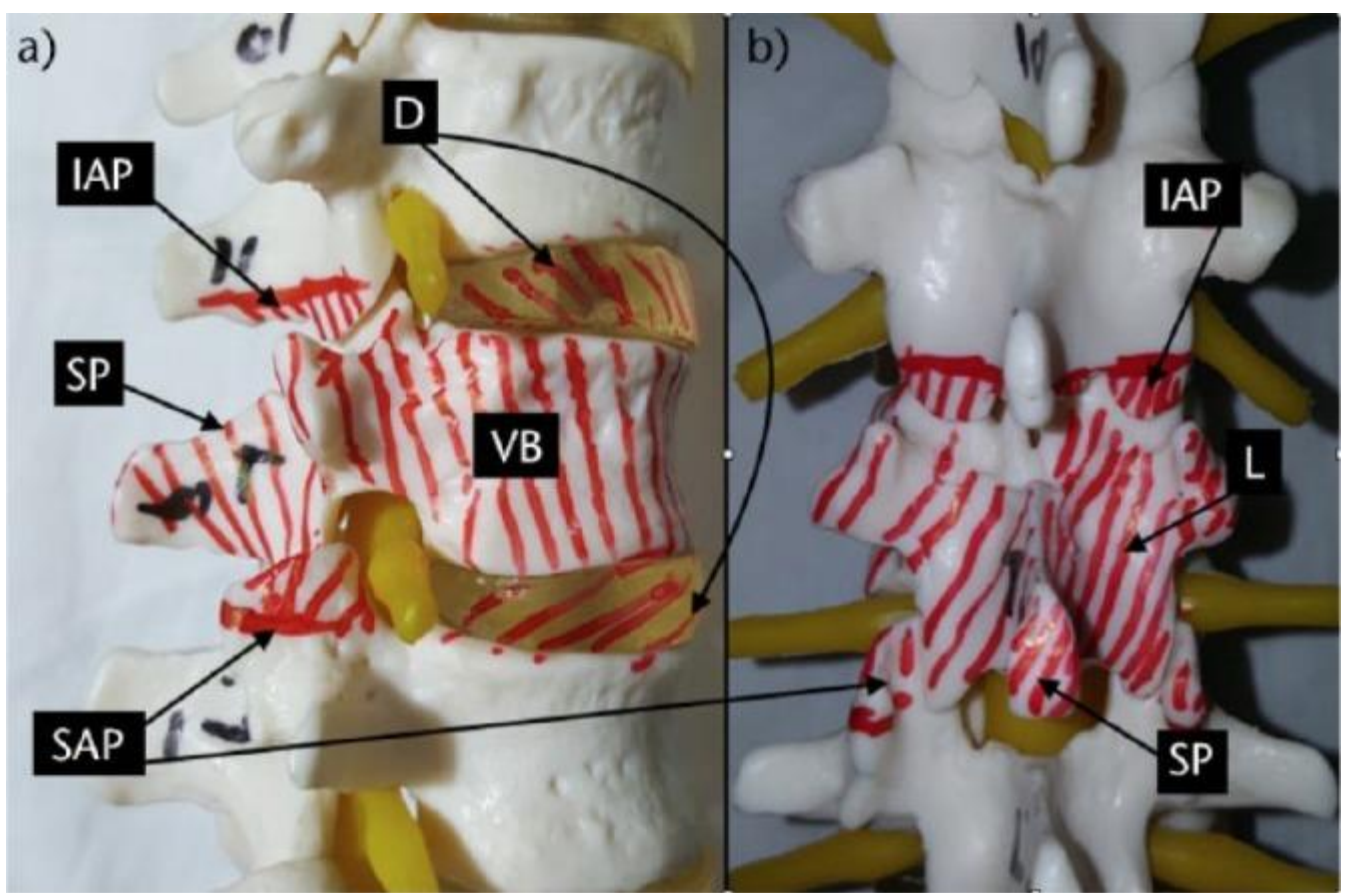
4. Vertebral column resection (VCR)

- a) circumferential
 - b) posterior only (PVCR)
- indicated for rigid multi-planar deformities, sharp angulated deformities, hemivertebra resections, resectable spinal tumours, post-traumatic deformities and spondyloptosis (main indication for a VCR is fixed coronal plane deformity).
 - if you don't start VCR by 1 pm, then you should stage the procedure.

a) Lateral view. Lower facets of the upper and upper facets of the lower vertebrae should be removed to allow removal of the laminae and pedicles of the vertebra to be resected. Discs should also be resected and this should be followed by end-plate preparation for a successful fusion.

b) AP view of the anatomical structures to be resected during a PVCR operation.

IAP, inferior articular process; D, disc; SP, spinous process; SAP, superior articular process; VB, vertebral body; L, lamina.



Classification #2

Osteotomy classification: grades 1 to 6 according to anatomic resection:

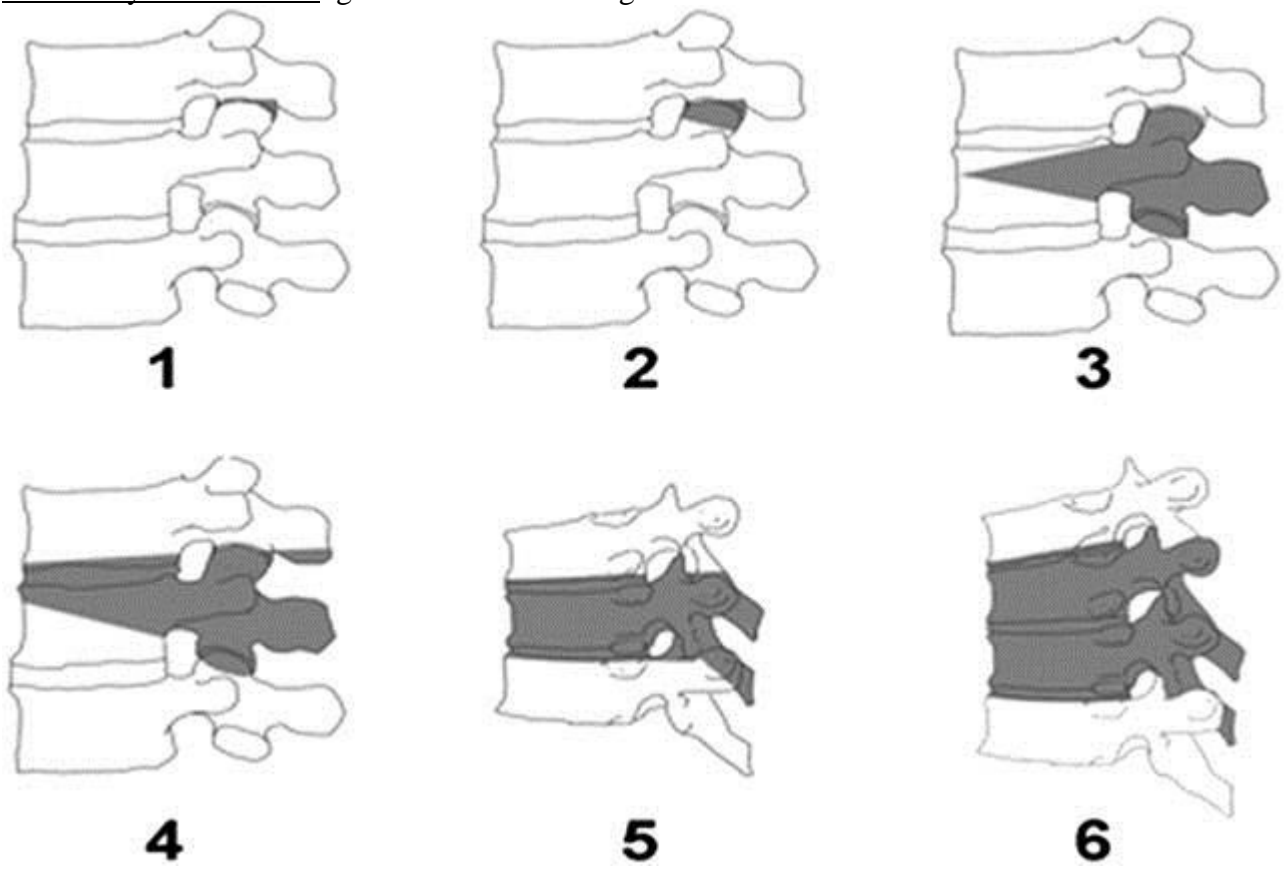
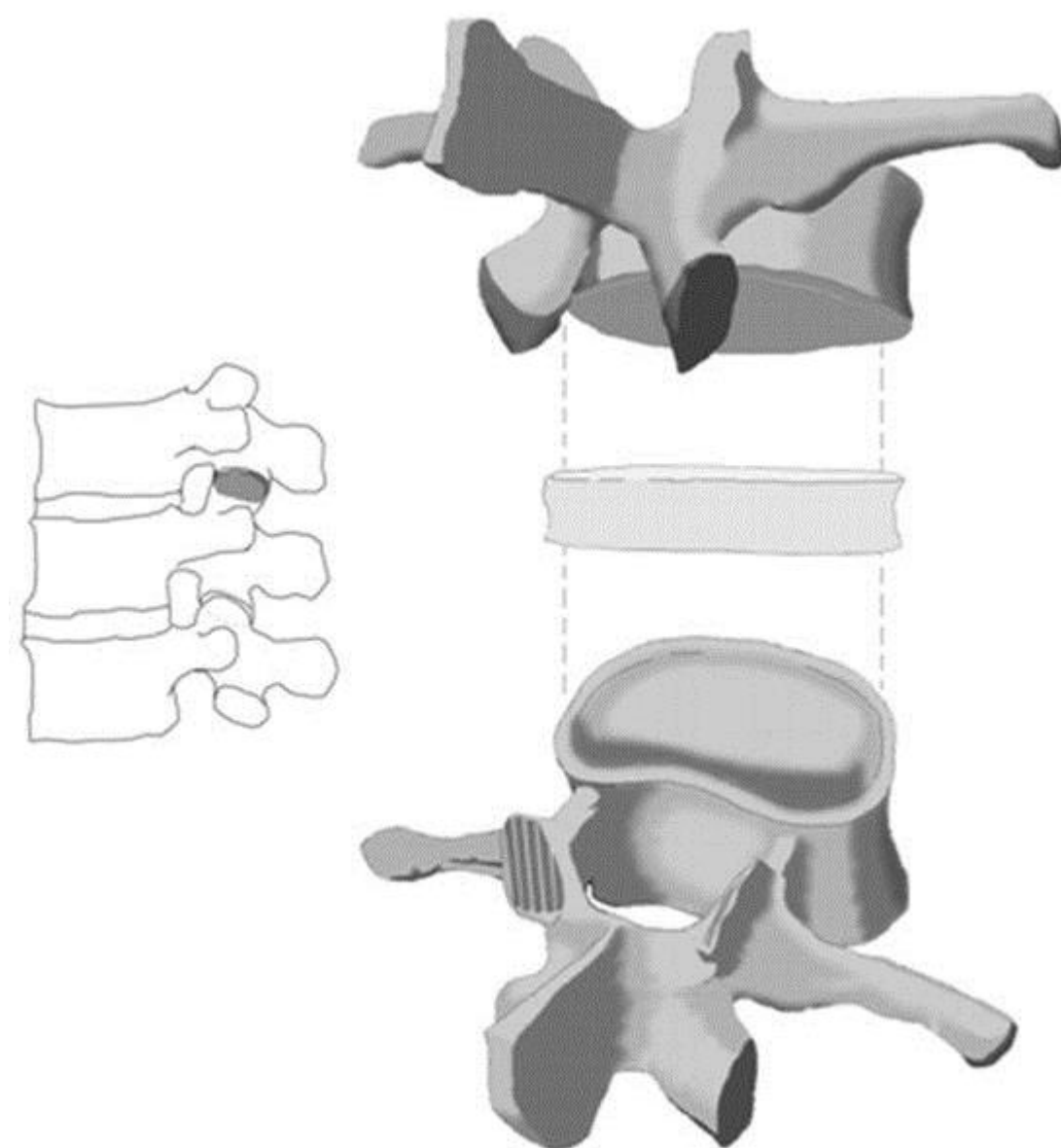


TABLE 1. Spinal Osteotomy Classification			
	Anatomic Resection	Description	Surgical Approach Modifiers
Grade 1	Partial facet joint	Resection of the inferior facet and joint capsule at a given spinal level	P (posterior approach only)
Grade 2	Complete facet joint	Both superior and inferior facets at a given spinal segment are resected with complete ligamentum flavum removal; other posterior elements of the vertebra including the lamina, and the spinous processes may also be resected	P (posterior approach only) A/P (anterior soft tissue release combined with posterior resection)
Grade 3	Pedicle/partial body	Partial wedge resection of a segment of the posterior vertebral body and a portion of the posterior vertebral elements with pedicles	P (posterior approach only) A/P (both)
Grade 4	Pedicle/partial body/disc	Wider wedge resection through the vertebral body; includes a substantial portion of the posterior vertebral body, posterior elements with pedicles, and includes resection of at least a portion of 1 endplate with the adjacent intervertebral disc	P (posterior approach only) A/P (both)
Grade 5	Complete vertebra and discs	Complete removal of a vertebra and both adjacent discs (rib resection in the thoracic region)	P (posterior approach only) A/P (both)
Grade 6	Multiple vertebrae and discs	Resection of more than one entire vertebra and adjacent discs. Grade 5 resection and additional adjacent vertebral resection	P (posterior approach only) A/P (both)

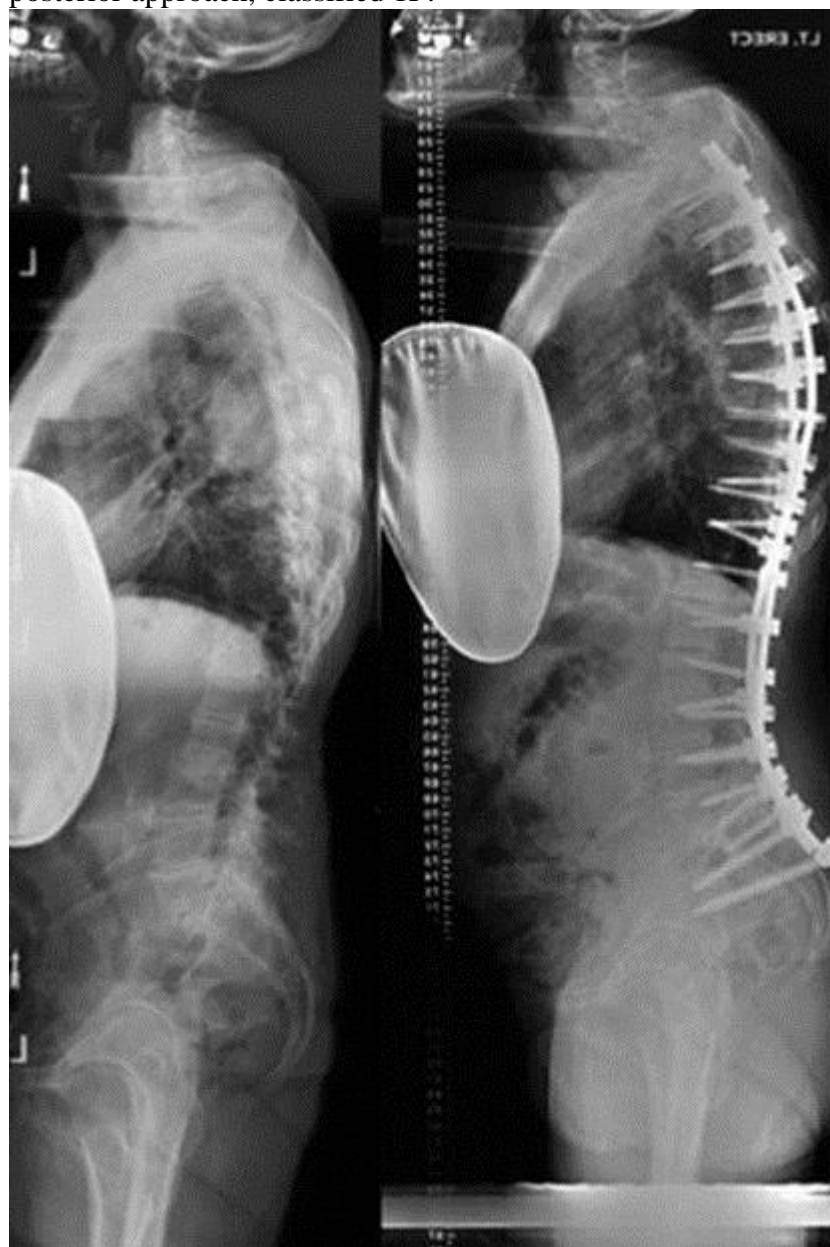
- osteotomies cause large blood loss.
- best level for osteotomies is where normally lordosis should be – at L3, 4, 5.
- patient is placed prone on Jackson table - it must be possible to provide extension of spine and hips to close osteotomy sites.
- rods are placed, compression and cantilever manipulation helps close osteotomy sites.

GRADE 1 OSTEOTOMY (PARTIAL FACET JOINT RESECTION, S. SMITH-PETERSEN OSTEOTOMY, OPENING WEDGE OSTEOTOMY, CHEVRON OSTEOTOMY, EXTENSION OSTEOTOMY)

- resection of inferior facet and joint capsule at given spinal level.
- limited deformity correction and is often applied to offer limited change in alignment and potential for fusion through cartilage removal of the superior facet.
- anterior column mobility (nonfusion) is a prerequisite for performing a grade 1 osteotomy.
- done by using posterior approach only (modifier P)
- 5-10° of correction can be achieved at each level, but lack of anterior column mobility can lead to vascular and neurological sequelae.

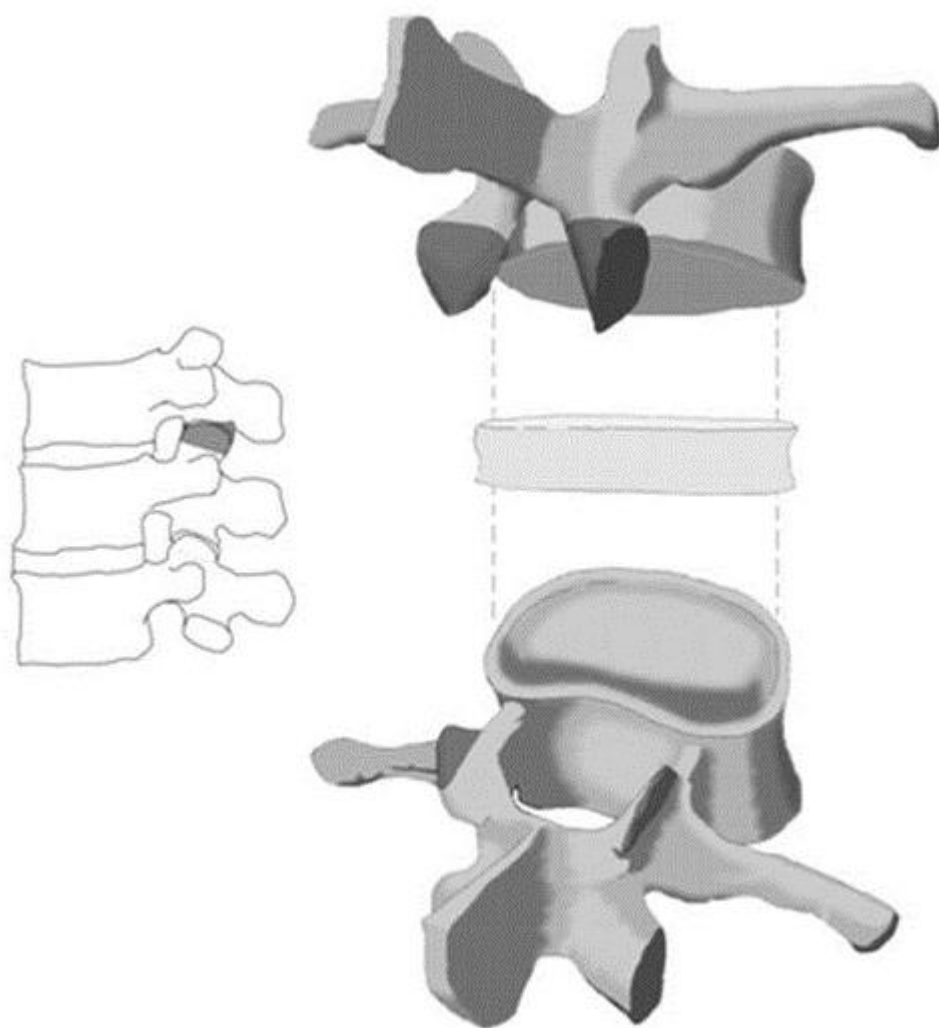


Pre- and postoperative clinical aspect of multiple lumbar partial facet joints resections by using a posterior approach, classified 1P:

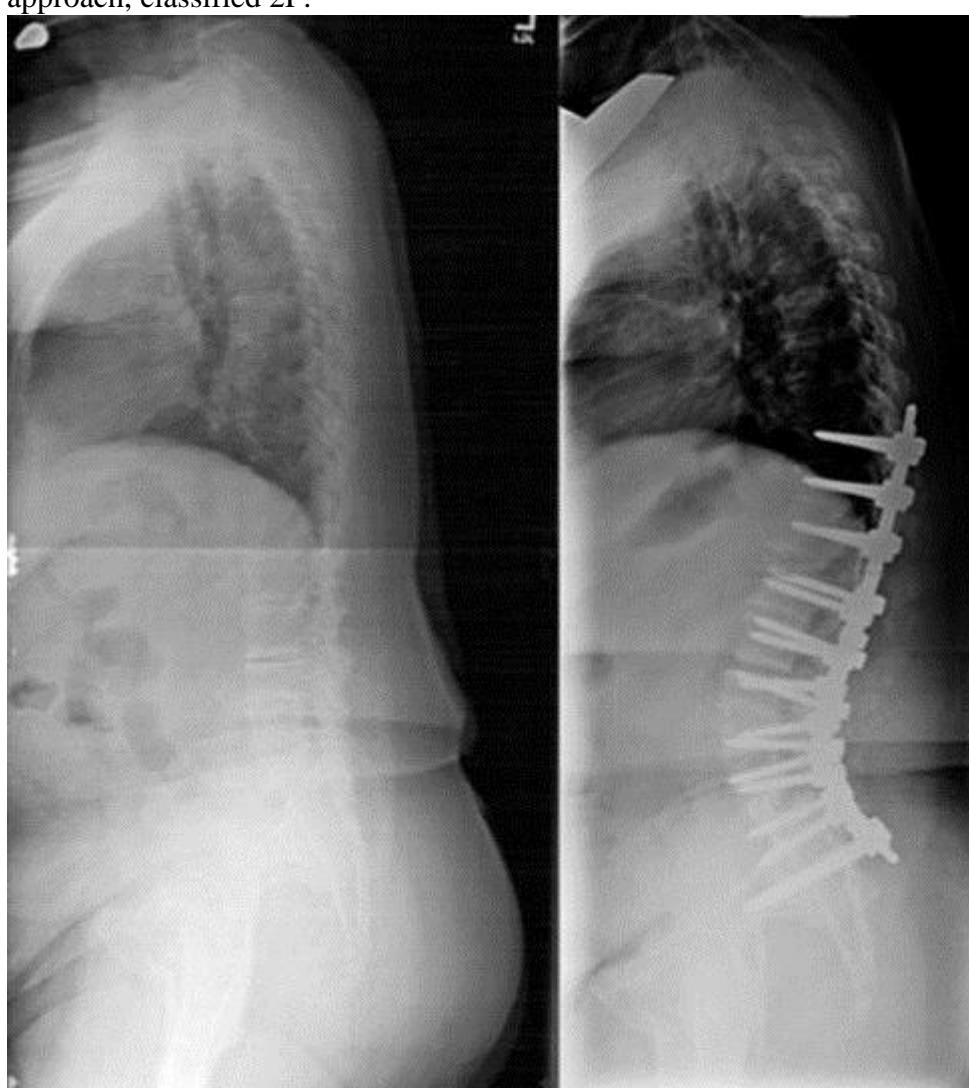

GRADE 2 OSTEOTOMY (COMPLETE FACET JOINT RESECTION)

- both inferior and superior facets of articulation at given spinal segment are resected (i.e. beyond what was described by Smith-Petersen), as well as ligamentum flavum.
- other posterior elements of vertebra including lamina, or spinous processes, may also be resected.
- similar to grade 1, grade 2 osteotomies require preexisting anterior column mobility (i.e. adequate disk height are required for this type of correction because posterior segment of disk acts as pivot point).
- any osteotomies that remove bone from the vertebral body are excluded from this grade.
- commonly done by using a posterior approach alone (modifier P), but may also involve a combined anterior soft tissue (anterior longitudinal ligament and/or disc) release and may be further denoted by the modifier A/P.
- in polysegmental osteotomy, bone is removed from articular processes and interlaminar space adjacent to articular processes at multiple levels to create gradual lordosis.
- **Ponte procedure** - resection of multiple facets along with the resection of spinous processes and involves substantial amount of bone and ligament resection to afford deformity correction.

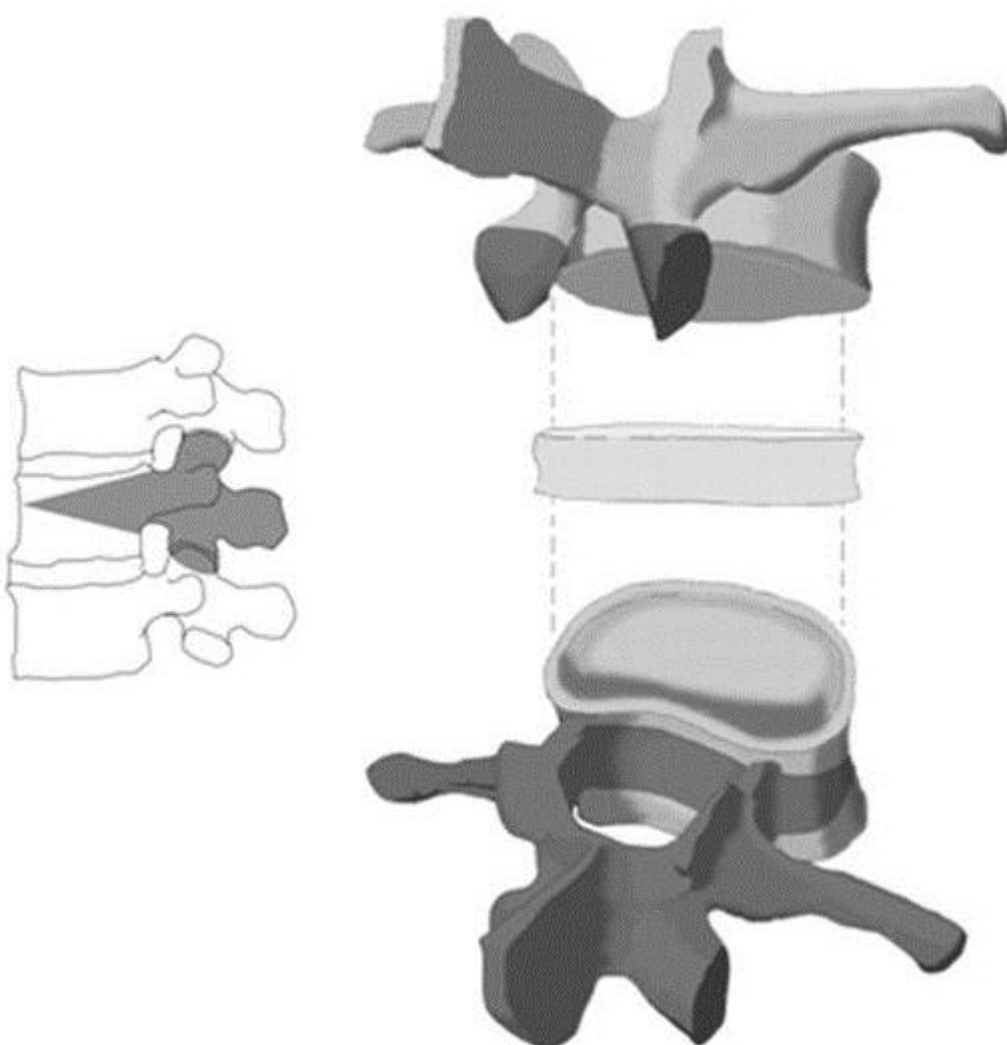


Pre- and postoperative aspect of multiple lumbar complete facet joints resections by using a posterior approach, classified 2P:



GRADE 3 OSTEOTOMY (PEDICLE AND PARTIAL BODY RESECTION, S. PEDICLE SUBTRACTION OSTEOTOMY, PSO, CLOSING WEDGE OSTEOTOMY, TRANSPEDICULAR WEDGE RESECTION)

- wedge resection of posterior and middle portions of vertebral body and posterior elements with pedicles + both sets of articular processes and detachment of transverse processes.
- portion of vertebral body and discs above and below level of osteotomy remain intact.
- further described as involving only posterior approach (P) or combining approaches (A/P).

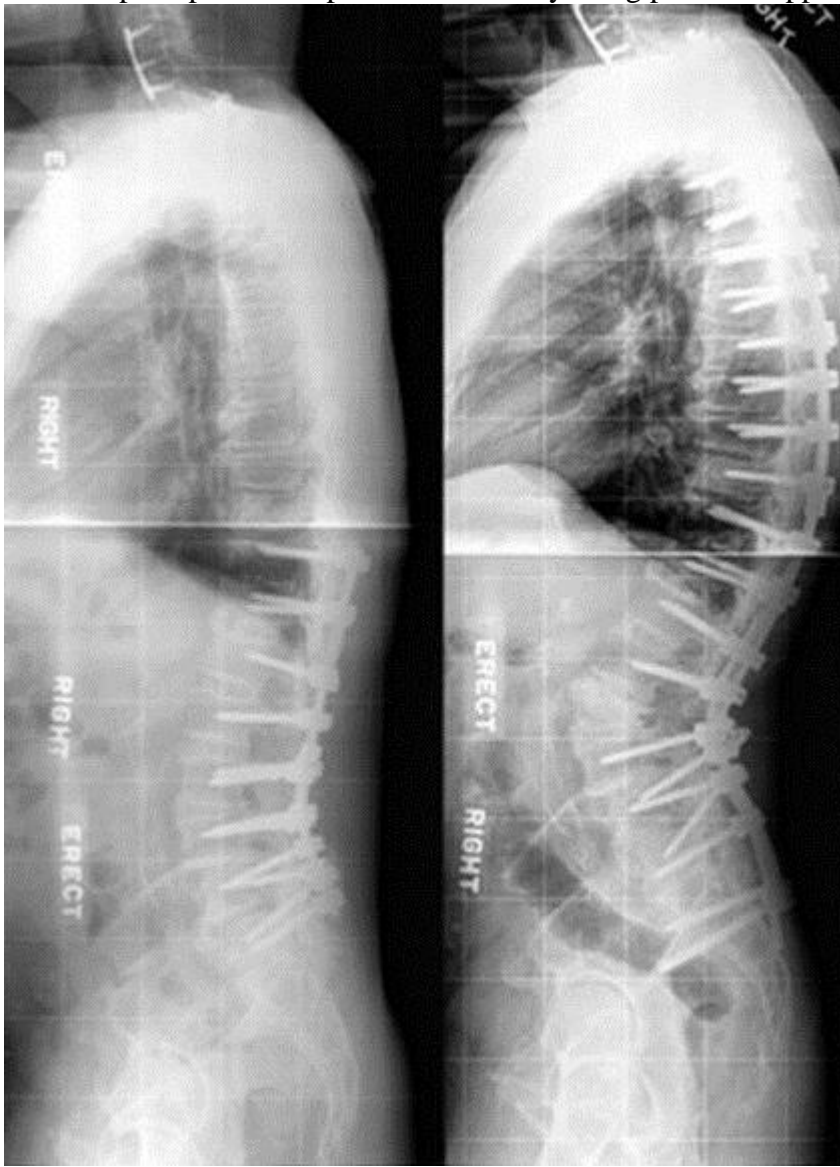


- no anterior column lengthening is performed.
- 25-35° of correction can be reasonably achieved at any given level.
- of note, PSO that extends into adjacent disc spaces would be termed grade 4P resection.

Circumferential wedge bone resection - variant with wedge-shaped apical vertebral body bone resection in addition to apical laminectomy and laminectomies of vertebrae directly superior and inferior to apex; apical facets and pedicles are removed completely.

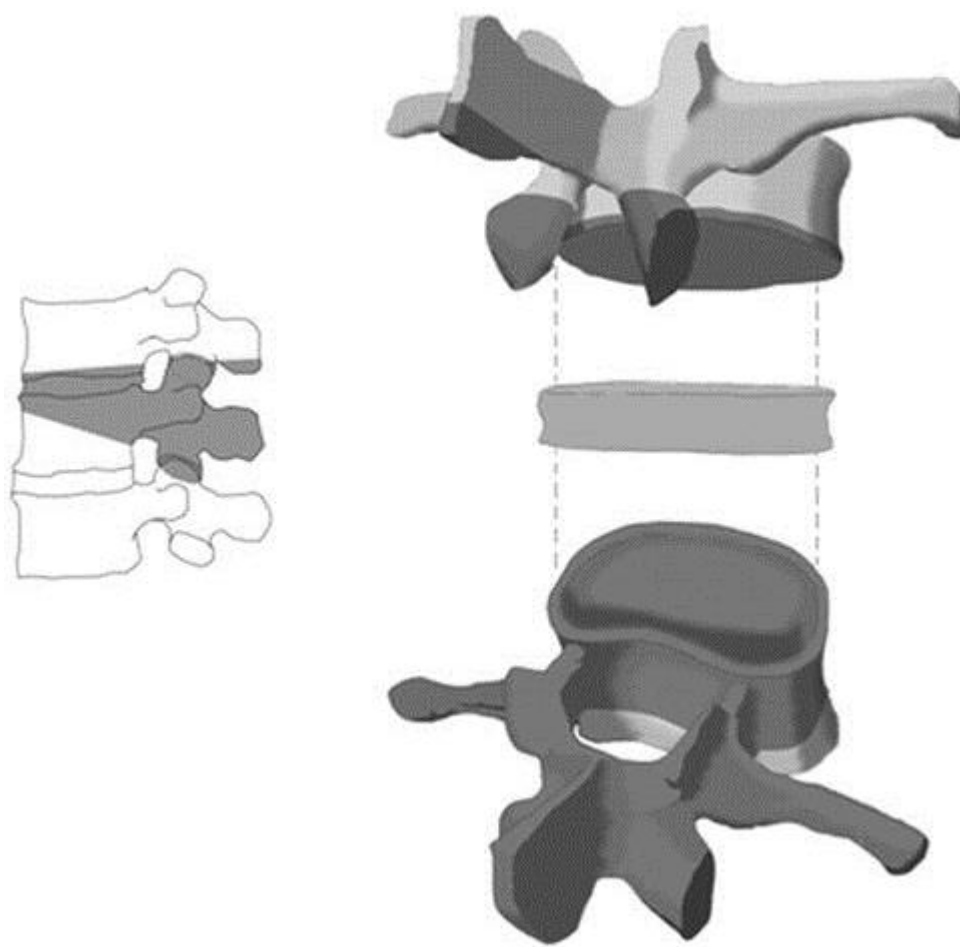
Closing opening wedge osteotomy (posterior approach that provides more sagittal alignment correction than PSO): resection of posterior elements while initially preserving anterior, posterior, and lateral cortices of vertebral body; posterior cortex is then pushed into body, and anterior and lateral cortices are removed. This allows hinging to be over posterior vertebral body rather than anterior cortex, resulting in greater correction.

Pre- and postoperative aspect of L3 PSO by using posterior approach, classified 3P:

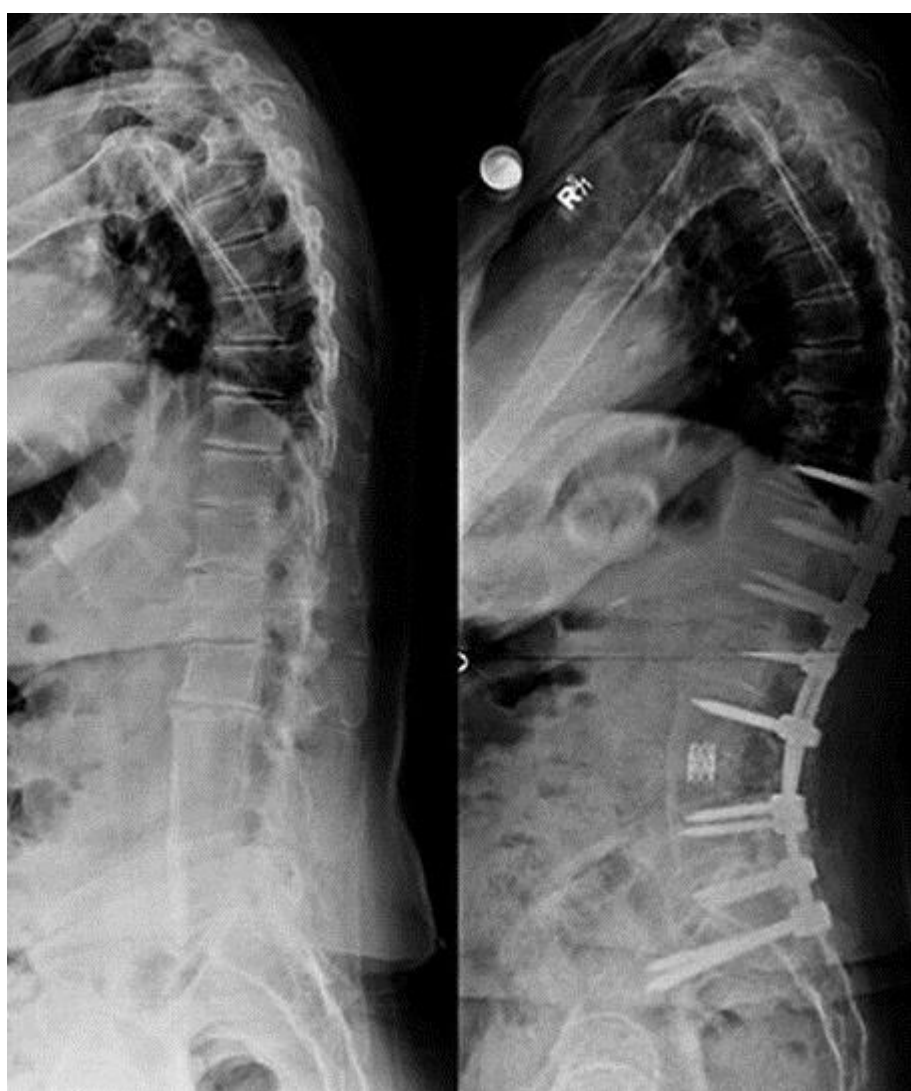

GRADE 4 OSTEOTOMY (PEDICLE, PARTIAL BODY AND DISC RESECTION)

- wider (than for grade 3) wedge resection through vertebral body; includes posterior vertebral body, posterior elements with pedicles, and sufficient body resection such that an endplate and at least portion of 1 adjacent disc (associated with rib resection in thoracic region) is removed.
- less aortic or inferior vena cava obstruction secondary to stretching.
- portion of vertebral body at level of osteotomy remains intact, but anterior support may be necessary in cases of marked shortening.
- further labeled as posterior release (P) or both (A/P).

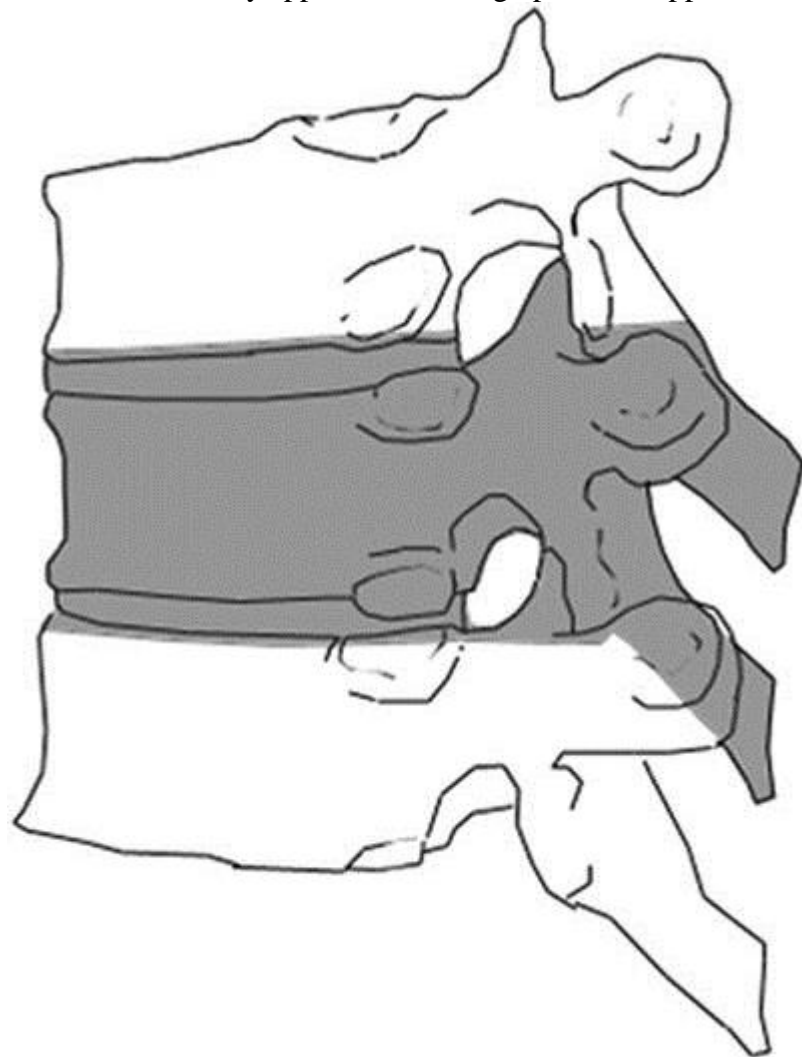


Pre- and postoperative aspect of L4 PSO including disc by using combined approach, classified 4A/P:

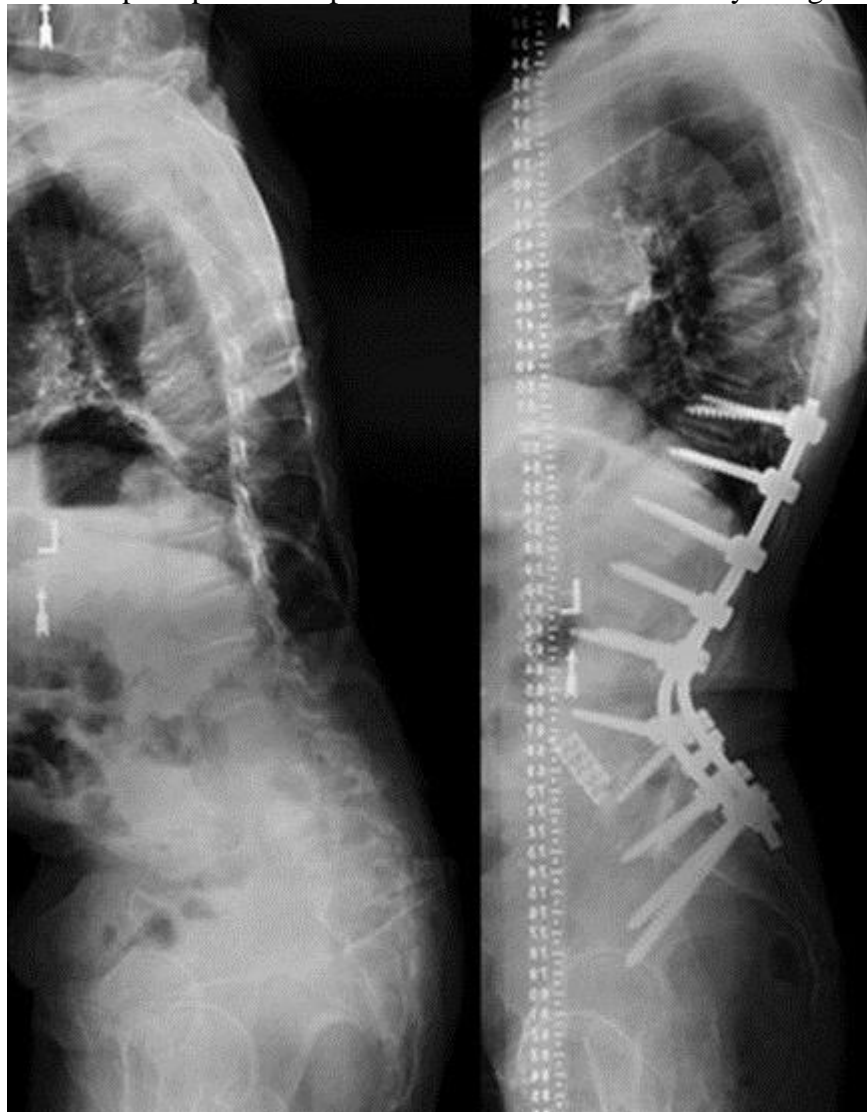


GRADE 5 OSTEOTOMY (COMPLETE VERTEBRA AND DISCS RESECTION)

- complete removal of vertebral level and both adjacent discs (+ rib resection in thoracic region).
- because of anterior shortening, anterior support is frequently applied.
- most commonly approached through posterior approaches only (modifier P)

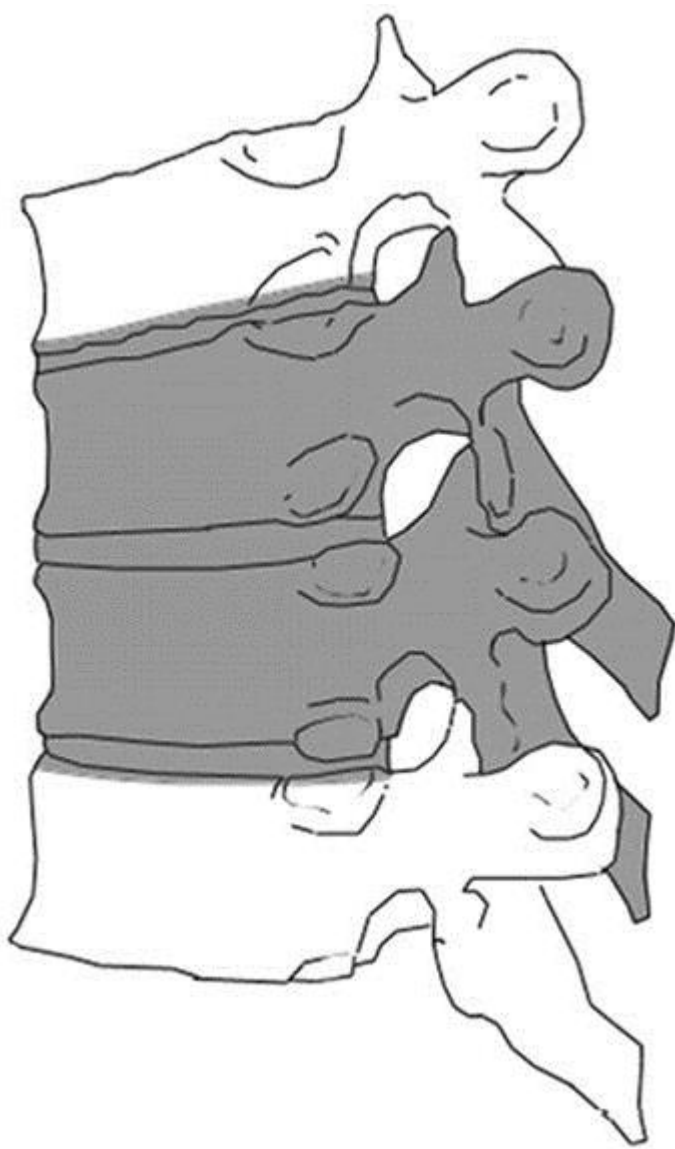


Pre- and postoperative aspect of L4 vertebral resection by using combined approach, classified 5A/P:



GRADE 6 OSTEOTOMY (MULTIPLE ADJACENT VERTEBRAE AND DISCS RESECTION)

- resection extends focally beyond scope of grade 5 resection - removal of several adjacent vertebrae, at least 1 complete vertebral body and partial or complete second vertebra.
- commonly, osteotomy will involve multiple complete vertebrae, some of which may be only partially developed (e.g. congenital malformation) or partially present (e.g. infection/tumorous destruction or remodeling).
- posterior-only approach is possible (modifier P).
- substantial coronal and sagittal plane correction can be achieved.



Pre- and postoperative aspect of T11-12 vertebral resection by using posterior approach, classified 6P:

