

Cord and Spine Developmental Anomalies (techniques)

Last updated: February 16, 2023

TETHERED CORD RELEASE	1
INTRAMEDULLARY SPINAL LIPOMA	12
LIPOMYELOMENINGOCELE	13
MYELOMENINGOCELE CLOSURE	25
PREOPERATIVE, CONSERVATIVE MEASURES.....	25
SURGICAL MANAGEMENT.....	25
Closure Procedure	25
Patient position	25
Technique	25
Postoperatively	28
Complications.....	28
SPLIT CORD MALFORMATIONS.....	40
ETIOPATHOPHYSIOLOGY	40
INDICATIONS FOR SURGERY	44
PREOPERATIVE.....	45
OPERATIVE PROCEDURE	45
Type I SCM.....	45
Type II SCM.....	50
Special Circumstances.....	52
COMPLICATIONS	56

Progressive cord dysfunction may be caused by fixation or by compression:

- a) **tethered spinal cord** - **fixation** by filum terminale on the distal spinal cord.
 - b) **intramedullary lipomas** - **compress** cord but do not have a component of fixation.
 - c) **lipomyelomeningocele** - both cord **fixation** and **compression**
- **Dr. Ritter** does not like marking skin – leaves color under DermaBond
 - **Dr. Ritter** does not inject local anesthetic – interferes with Colorado incision.
 - do not use Ioban for little kids with faint skin.
 - postop place “mudflap” to protect lumbar incision from soiling: yellow strip of stoma bag adhesive material horizontally just above butt crack, then strip of clear plastic attached to it – replacing clear plastic requires to peel it from stoma material (saving skin from adhesive trauma).
 - if lumbar incision closure required undermining of skin flaps, postop keep flat prone or on the side (not supine!).

TETHERED CORD RELEASE

- anesthesia: general oral endotracheal.
- monitoring for the procedure: EMG, ± SSEP, MEP
- prone on chest rolls (transverse).
- Foley catheter
- if there is **dermal sinus**, incise lumbar midline in elliptical fashion thus excising skin dimple → dissect it all the way down (needs to be excised in entirety)
- dissect down to laminae (beware spina bifida occulta).

- young kids - use craniotome (footplate) for laminotomies in one block – cut on both sides of spinous processes; laminotomies extended laterally with Kerrison rongeurs where needed; reflect entire block (still attached proximally to intact vertebrae) proximally.
- older kids – normal laminectomy or laminotomies (to widen interspace)
- epidural venous bleeding stopped with bipolar cautery ± SurgiFoam.
- obtain absolute hemostasis (e.g. place Surgicel into lateral gutters) – blood in thecal sac will cause arachnoiditis.
- in meticulous stepwise fashion open thecal sac longitudinally in midline: 15 blade → Potts scissors → dura tacked up using 4-0 silks.
- find filum → dissect away nerve roots → stimulation using bipolar probe fork → coagulate (with bipolar) and transected the filum below the point where no EMG responses are obtainable (if activates only anal sphincter, it is OK to cut).
- irrigated out subdural space with copious amounts of saline out of clots.
- durotomy closed watertight with simple running 4-0 silk / 5-0 Prolene (with Hemo-Seal needle) suture → inject **DURAMORPH** (preservative-free morphine) and **CLONIDINE** intradurally → Valsalva maneuver → durotomy suture line reinforced with Tisseel and Surgicel layers.
- **LAMINOPLASTY** - block of laminae and spinous processes replaced and fixed back in place with 2-0 Dexon sutures (suture interspinous ligaments to ligamentum flavum bilaterally).
- no drain.
- 4-0 simple running Monocryl suture and Dermabond for skin.
- postop – flat for 1-3 days (so keep Foley and sedated in PICU).

From Goodrich (2008)

The concept that fixation of the distal spinal cord by a thickened filum terminale can cause progressive spinal cord dysfunction has become accepted during the past 50 years. Surgical procedures to section the filum have only become common in the past 30 years. The dysfunction of the spinal cord occurs from a combination of repeated small injuries or contusions as the cord is put under tension with movement (especially spinal flexion) and by apparent vascular compromise. The change in the superficial vasculature of the cord as well as its disturbed ability to metabolize oxygen has been demonstrated both in laboratory animals and in humans. The vascular changes that occur with tension of the cord seem to improve following release of the tension.

Patient Selection

Patients may present for clinical attention with a variety of complaints. One group of patients will present for clinical attention only as a result of cutaneous evidence of occult spinal dysraphism. This may take many forms including a fl at capillary hemangioma or a small dermal appendage. When one of these cutaneous findings is present, it suggests further investigation. The majority of patients with a fl at capillary hemangioma will have normal intradural anatomy; however, a significant minority (as high as 10%) will have a tethered spinal cord. Waiting for the patient to demonstrate the clinical findings of a neurogenic bladder is likely to result in a fixed neurogenic deficit that may not be reversible with surgical intervention. Prevention of further bladder dysfunction by early investigation and prophylactic surgery is warranted. Commonly, the initial clinical symptom in patients with tethered cord syndrome is the gradual and progressive loss of coordinated bladder activity. This may become manifest as repeated bouts of urinary infection or primary or secondary urinary incontinence. The urinary symptoms may be combined with evidence of spasticity of the lower extremities. The lower extremity involvement is frequently a combination of hyperactive deep tendon reflexes with upgoing toes and muscle wasting, fasciculations, and shortened foot or leg length. The combination of upper and lower motor neuron disturbances in the lower extremities is the signature of this problem. Even though the tension could be thought to be relatively symmetric on the distal cord, the leg findings are typically asymmetrical. Rectal incontinence is usually delayed until late in the course. Nonradicular pain in the back and legs may be the primary cause of presentation in the adult population. Occasional precipitous deterioration has been recognized. Sudden lower spinal flexion as

in patients assuming the lithotomy position under anesthesia has resulted in dramatic worsening and even abrupt onset of paraplegia in occasional patients. In at least 10 to 20% of patients with congenital anorectal atresia, a tethered spinal cord will also be found. This group of patients clearly warrants early investigation in an effort to prevent the development of a neurogenic bladder and to improve the neurological input into the dysmorphic rectal sphincter. Many patients with a thickened filum terminale are seen to have some other form of neural tube abnormality. This may range from an obvious myelomeningocele to the combination of intact normal skin and an occult split cord anomaly or terminal syringohydromyelia. The suspicion of a tethered spinal cord is confirmed with magnetic resonance imaging (MRI). The use of computed tomography (CT) myelography in this patient population has been almost entirely replaced by MRI. In general, three criteria are necessary to radiographically confirm the clinical impression of a tethered spinal cord: caudal descent of the conus, fatty infiltration and thickening of the filum terminale, and a drawn-out or "funnel-like" appearance of the distal conus. Normally the conus should not descend below the L1-2 disk space. The conus progressively ascends within the spine throughout embryological development and early infancy. It normally attains its "adult" position by 3 to 6 months of age and maintains this position throughout adult life. In patients with tethered cord syndrome, the thin delicate structure of the normal filum terminale is lost. It becomes thickened (usually more than 3 mm in diameter) and is typically infiltrated by fat, which is easily appreciated by MRI on the axial T1 sequences. This thickening results in tension on the conus and a loss of the normal bulbar lumbar enlargement of the distal cord. The cord assumes a funnel-like appearance, dorsally displaced within the subarachnoid space and under tension. When all radiographic findings occur in a patient with an appropriate clinical setting, the diagnosis is secure. Unfortunately, there are occasions when patients present with progressive clinical symptoms that could easily be attributable to a tethered cord, but the radiographic findings are confusing. The conus may be in a normal position but the filum may be thick, infiltrated by fat, and dorsally displaced under tension. As with many clinical situations, judgment in analyzing the clinical and radiographic findings is essential to arrive at an appropriate decision for the patient. The natural history of the condition is not well understood. Many believe that the constant small trauma associated with tension on the distal cord by the thickened filum is associated with the relentless loss of neurological function in most patients. This loss may occur within the first few months of life or more typically over a much longer time. Occasional adult patients will demonstrate many decades of symptom-free survival only to come to clinical attention with irreversible bladder dysfunction. Pain-free adolescents and adults with normal neurological function but clear radiographic abnormalities attest to the incomplete ability of the clinician to predict the natural history of this condition. Patients with progressive symptoms and classic MRI changes are easily counseled to accept operation in an attempt to prevent further loss of function. Asymptomatic patients can be approached with a risk-versus-benefit analysis depending on the strength of the radiographic abnormalities and other evidence of dysmorphism, that is, anorectal atresia, hemivertebrae, etc.

Preoperative Preparation

Once a decision to operate has been offered and accepted, the patient is positioned prone with bolsters placed under the iliac crest and thorax to allow free excursion of the abdomen (Fig. 10-1A). Some surgeons feel more comfortable utilizing intraoperative monitoring of rectal and/or urethral electromyography. Ultra-short-acting muscle paralysis is necessary to allow appropriate interpretation of these electrical parameters.

Operative Procedure

An incision is made from the spinous process of the tip of the L5 vertebra to the mid sacrum (Fig. 10-1B). The dorsal bony elements of S1 are removed by standard laminectomy technique, and the sacral dura is exposed. There is rarely need to expose more than 2 to 3 cm of the subarachnoid space to allow adequate visualization of the distal filum terminale. The dura is opened in the midline and the arachnoid is opened somewhat off the midline. The thickened filum can be recognized by the infiltration of fat within it, by its midline dorsal position, and by the size differential between this structure and the surrounding thin delicate roots that exit in a ventrolateral direction. Additionally, the filum has a characteristic vessel on its ventral surface that may be appreciated by rotating the filum. Once the fi

lum is identified it is carefully separated from all adherent nerve roots, particularly those on the ventral surface (Fig. 10–2A). One must rotate the fi lum to visualize the undersurface and to ensure that no small roots are left adherent to the capsule of the fi lum. When this is confirmed the fi lum is coagulated and cut (Fig. 10–2B). This is done at two levels to allow the excision of a section of 5 to 8 mm that can be sent for histological analysis and to ensure that the two ends of the fi lum will not adhere to one another. Care is taken to ensure a watertight closure of the dura and the superficial soft tissues.

Figure 10–1 (A) Prone position of an infant undergoing sectioning of the fi lum terminale. (B) The typical skin incision for exposure of the sacral dura. The skin incision extends from the spinous process of L5 to the mid sacrum.

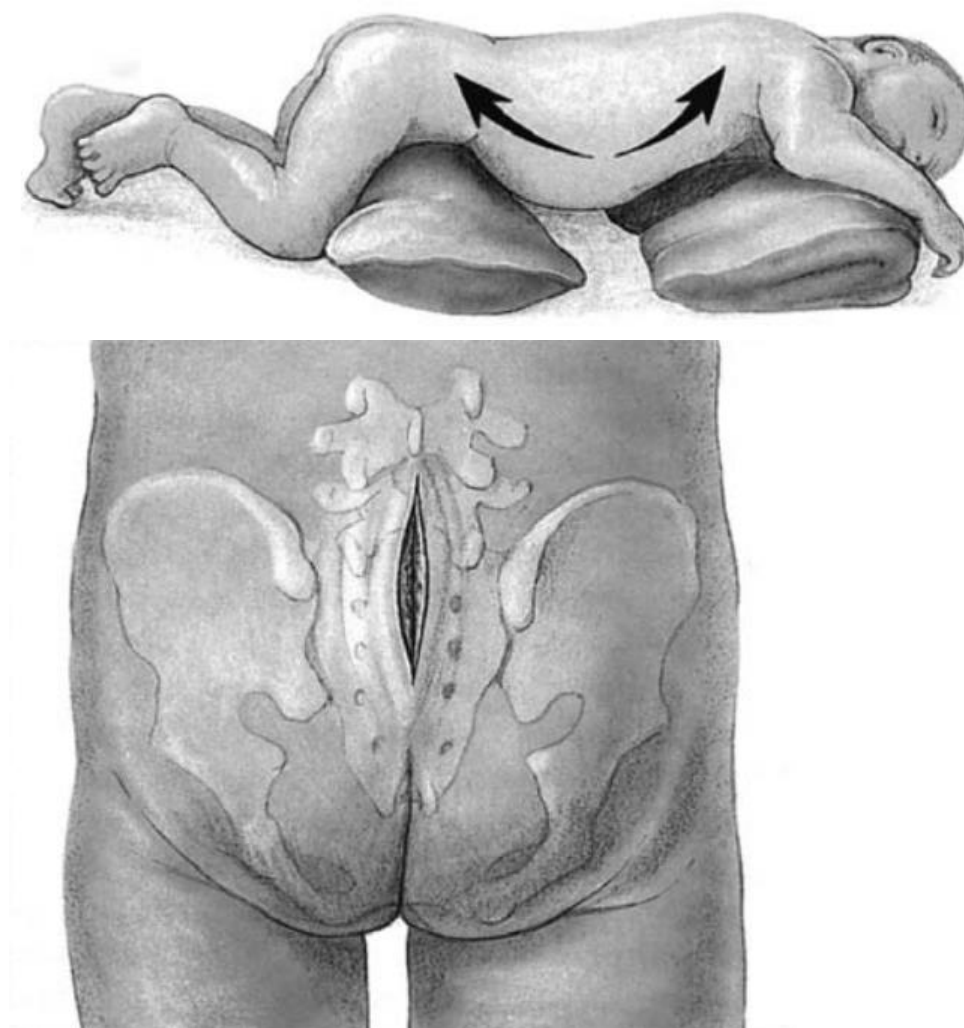
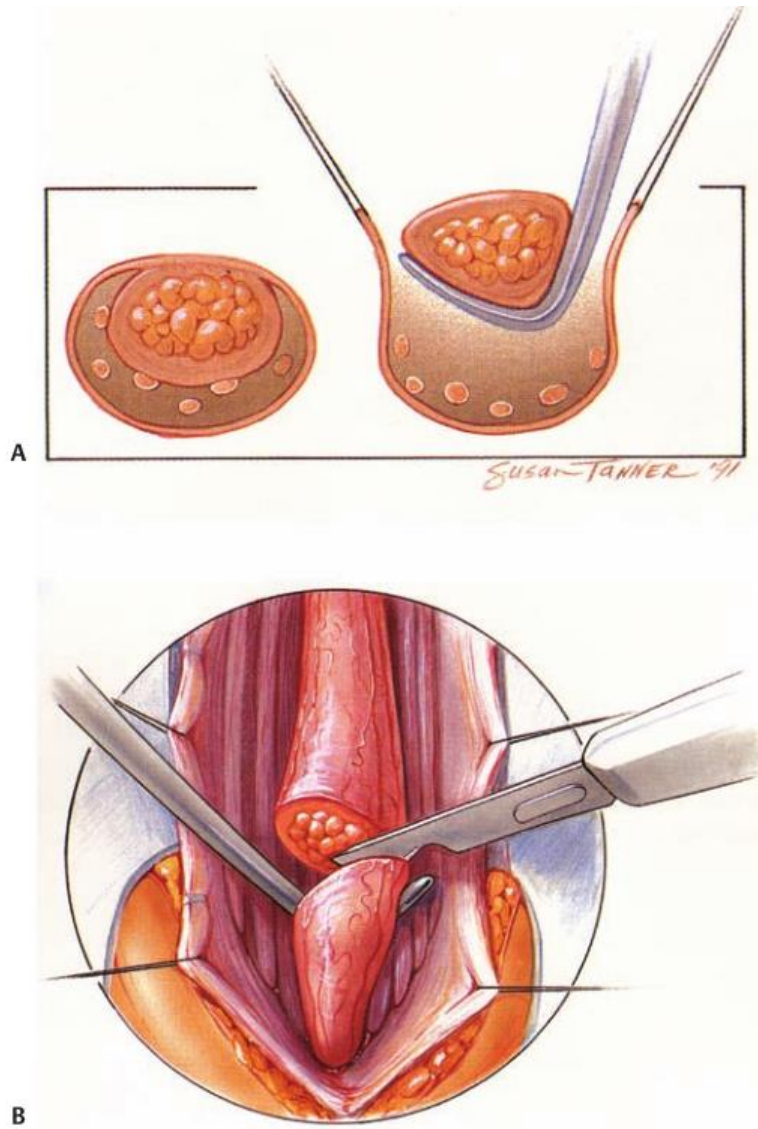


Figure 10–2 (A) Axial views through the sacrum before and after the adherent roots ventral to the thickened fi lum terminale have been dissected. (B) The initial section through the fi lum terminale showing fat in the center of the fi lum.



Postoperative Management

Patients are routinely nursed flat for several days to allow adequate dural healing without the additional tension of orthostatic force of the cerebrospinal fluid (CSF). The likelihood of adherence of the cut ends of the filum is extremely small. Long-term complications are very rarely seen. Results with regard to blunting of the previous rate of loss of neurological function are quite favorable. The ability to restore lost function, particularly bladder synergy, is poor. Relief of pain and sensory loss is gratifying. Progressive moderate scoliosis may be arrested. Restoration of motor function is less likely than sensory improvement or the relief of pain. Urologic dysfunction, which is the most common cause of clinical presentation, remains the least likely to improve once it is firmly established.

From Goodrich (2008) (2-adalis)

Sectioning of the Filum Terminale

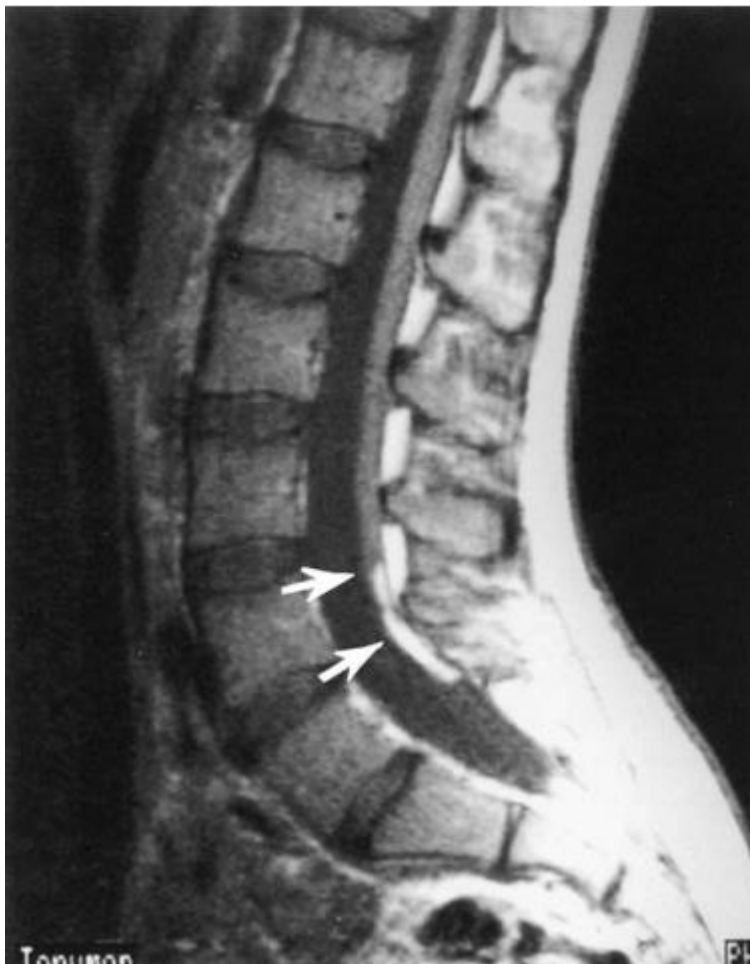The tethered cord syndrome is a complex of neurological symptoms and orthopedic deformities associated with a low-lying conus medullaris (below L2–3). Embryologically, abnormal retrogressive differentiation of caudal cell mass presumably gives rise to the hypertrophied filum terminale leading to a tethered cord. Recent radiological advances have improved our knowledge and understanding of the pathogenesis and associated pathologies. It is a common feature in many congenital malformations such as spinal lipoma, diastematomyelia or split cord malformation, myelomeningocele, cloacal malformations, and tight filum terminale. Symptomatic tethering may also occur after longitudinal growth in patients with scarring after myelomeningocele repair, spinal tumor resection, or trauma. The

tethered cord syndrome may be seen at any age; however, symptoms usually begin in childhood without gender predilection. Clinical signs and symptoms of the tethered cord syndrome may vary and commonly include spina bifida occulta, lower extremity weakness with gait difficulty, muscle atrophy, a short limb, ankle abnormality, perineal or lower extremity sensory deficits, bladder dysfunction, pain (back, leg, or foot arches), and kyphoscoliosis. Occult tethering may have delayed onset of symptoms into adulthood, with a peak incidence in the fourth decade of life. The advent of magnetic resonance imaging (MRI) has led to increased awareness of the tethered cord by pediatricians, orthopedists, and urologists, allowing for more frequent diagnosis. Many cases of tethered cord are incidental findings in neurologically normal patients due to imaging studies performed for other reasons. Surgery for the release of a tethered cord has become one of the most common operations done by pediatric neurosurgeons. Ninety percent of pediatric patients presenting with pain have complete relief or improvement following surgical sectioning of the filum terminale. Seventy-five percent of patients presenting with motor symptoms have improvement in motor function following surgery. However, only 50% presenting with bowel and bladder dysfunction improve following surgery. Patients with progressive scoliosis may experience stabilization or improvement of their scoliotic curvature with early untethering; therefore, release of a tethered cord should generally be considered prior to scoliosis correction.

Patient Selection

The diagnosis of a tethered cord in the newborn usually occurs after the recognition of a midline cutaneous anomaly such as an intergluteal sinus or dimple, tuft of hair, hemangioma, cutis aplasia, or subcutaneous lipoma. The diagnosis is also often made when infants with cloacal malformations (cloacal exstrophy, anal atresia, omphaloceles) are studied with spinal ultrasound. Beyond the first few weeks of life, ossification of the dorsal elements may limit the use of ultrasound, therefore requiring MRI. Loss of continence after toilet training and an associated history of constipation are the most common symptoms beyond infancy. Complaints of intermittent back and leg pain, especially evoked by exertion, may be associated. These patients most commonly have a normal neurological exam, but physical findings may include pes cavus deformity, calf wasting, atrophy of a gluteus muscle, asymmetry of foot size, lower sacral hypesthesia, and mild scoliosis. Spinal radiographs may show spina bifida occulta and urodynamic studies may reveal a neurogenic bladder. Myelography is usually not necessary and MRI is the diagnostic study of choice (Fig. 20–1). Children symptomatic for 6 months or less can generally expect improvement in their symptoms following surgery. On the other hand, those symptomatic for 1 year or more may often have stabilization of their symptoms or deficits but a lower chance of neurological improvement. Once a child becomes symptomatic, the natural history is usually one of symptomatic progression. The best management for asymptomatic, neurologically normal children with incidental findings on imaging remains controversial. It is the responsibility of the surgeon to discuss with the family the information available on the natural history and chances of recovery once the child becomes symptomatic. Fat in the filum is a frequent incidental MRI finding, and if the conus is at a normal level and there are no clinical indications of a tethered cord, surgery is usually not recommended; however, these children should be followed clinically.

Figure 20–1 A sagittal T1-weighted magnetic resonance image through the lumbar region demonstrates a thickened filum terminale. The hyperintensity (arrows) indicates fatty infiltration of the filum.



Preoperative Preparation

Careful evaluation of the axial MRI through the lumbar spine is necessary preoperatively to document any associated pathology such as a dermal sinus tract. When this is noted, the filum may not traverse the length of the spinal canal but attach to the thecal sac dorsally. MRI is helpful in determining the appropriate level of the laminotomies. Patients are instructed to bathe well the night prior to surgery and receive perioperative antibiotics. Patients who already have an active infection of a sinus tract or meningitis should be treated adequately for such infection prior to any surgical intervention.

Anesthesia Considerations

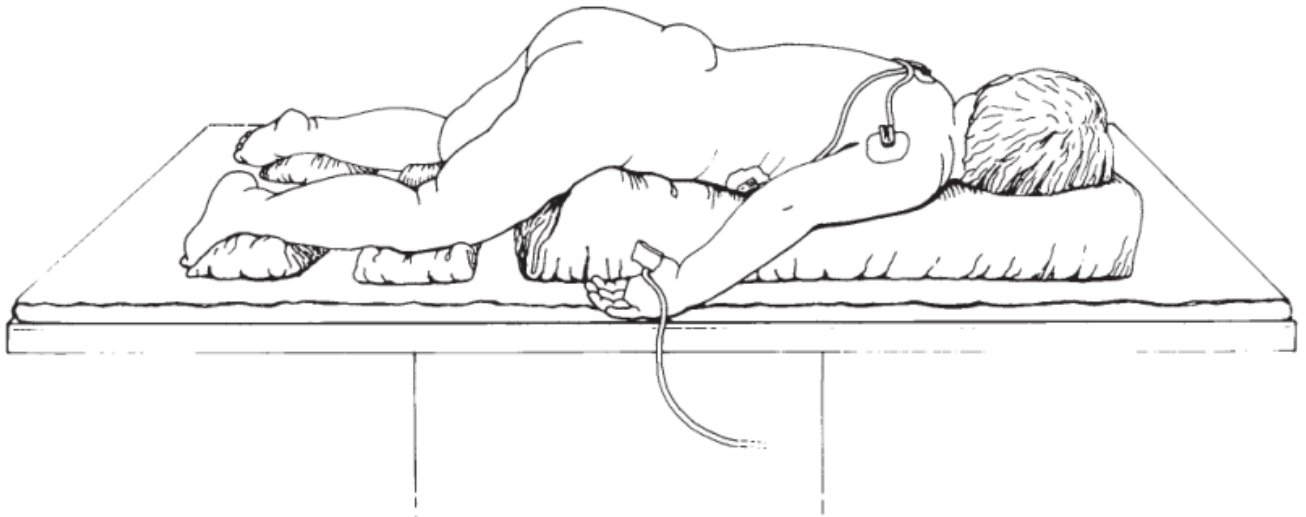
It is recommended that the anesthesiologist use a short-acting muscle relaxant during induction to allow for intra-operative stimulation of nerve roots, if necessary, and to allow for the recognition of motor response with inadvertent stimulation of nerve roots. Intraoperative spinal cord monitoring is not routine for a simple sectioning of a thickened filum terminale; however, it may be useful in other pathologies such as repair of a diastematomyelia.

Operative Procedure

Positioning

After securing the endotracheal tube and placement of a Foley catheter, if warranted, the patient is placed in the prone position on chest rolls extending from chest to the iliac crest (Fig. 20–2). This prevents abdominal compression and secondary distension of the epidural venous plexus, reducing venous bleeding. Arms are placed on arm boards for anesthesia access, and all pressure points are padded. The patient is then placed in a slight Trendelenburg position to reduce loss of cerebrospinal fluid during the procedure, which can be especially problematic in a patient with ventriculomegaly.

Figure 20–2 The patient is positioned prone on bolsters with padding of all extremities. A slight Trendelenburg position prevents the overdrainage of cerebrospinal fluid.



Surgical Technique

An extended caudal-to-rostral sterile preparation and draping should be performed to allow for extension of the incision as needed. The planned incision is marked on the skin in the midline, and the dermis is injected with lidocaine with epinephrine. An incision is made and dissection is carried down to the level of the thoracolumbar fascia incorporating any existing dimple or sinus tract by ellipsing around the opening in the skin (Fig. 20–3). Hemostasis is obtained with the bovie and bipolar cautery. The surgeon must keep in mind that in spina bida patients and infants that the lamina and spinous processes may not be fully developed or ossified. Care must be taken not to inadvertently pass instruments into the spinal canal. The paraspinous muscles are dissected away from the lamina in the subperiosteal plane out to the facets, leaving the facet joint capsule intact. A self-retaining retractor is then placed. The partial laminectomy is then performed removing both the inferior half of the superior lamina and the superior half of the inferior lamina at the level of pathology. Following the laminotomy, the dura is cleared of ligamentum flavum and epidural fat using sharp dissection and bipolar cautery. A 2 cm segment of exposed dura is adequate for simple filum sectioning. At this point, hemostasis is imperative to prevent excessive bleeding from epidural veins once the dura is opened and the thecal sac decompressed. A midline durotomy is next performed using a sharp scapel and hook. 4–0 Surgilon suture is then placed in the dura to retract the edges (Fig. 20–4A). Next, microscissors are used to open the arachnoid and expose the filum. The filum is located in a dorsal midline position and has a different texture and color (purple hue) in comparison with nerve roots due to fatty infiltration and associated veins. Upon identification of the filum, it is elevated with a nerve hook and the undersurface inspected for possible adherent nerve rootlets (Fig. 20–4B). The filum is carefully isolated from all nerve roots. The filum may be stimulated with low electrical current if desired. Higher current is avoided because current spread may stimulate other roots and give a false impression. Once it is clearly identified, the filum is coagulated with bipolar forceps and sectioned with microscissors (Fig. 20–4C). After sectioning, the ends of the filum will retract up into the spinal canal, so one must be sure of hemostasis prior to completing the sectioning.

Figure 20–3 The surgeon's view demonstrates the skin incision (straight dashed line) and the underlying laminectomy (dashed rectangle).

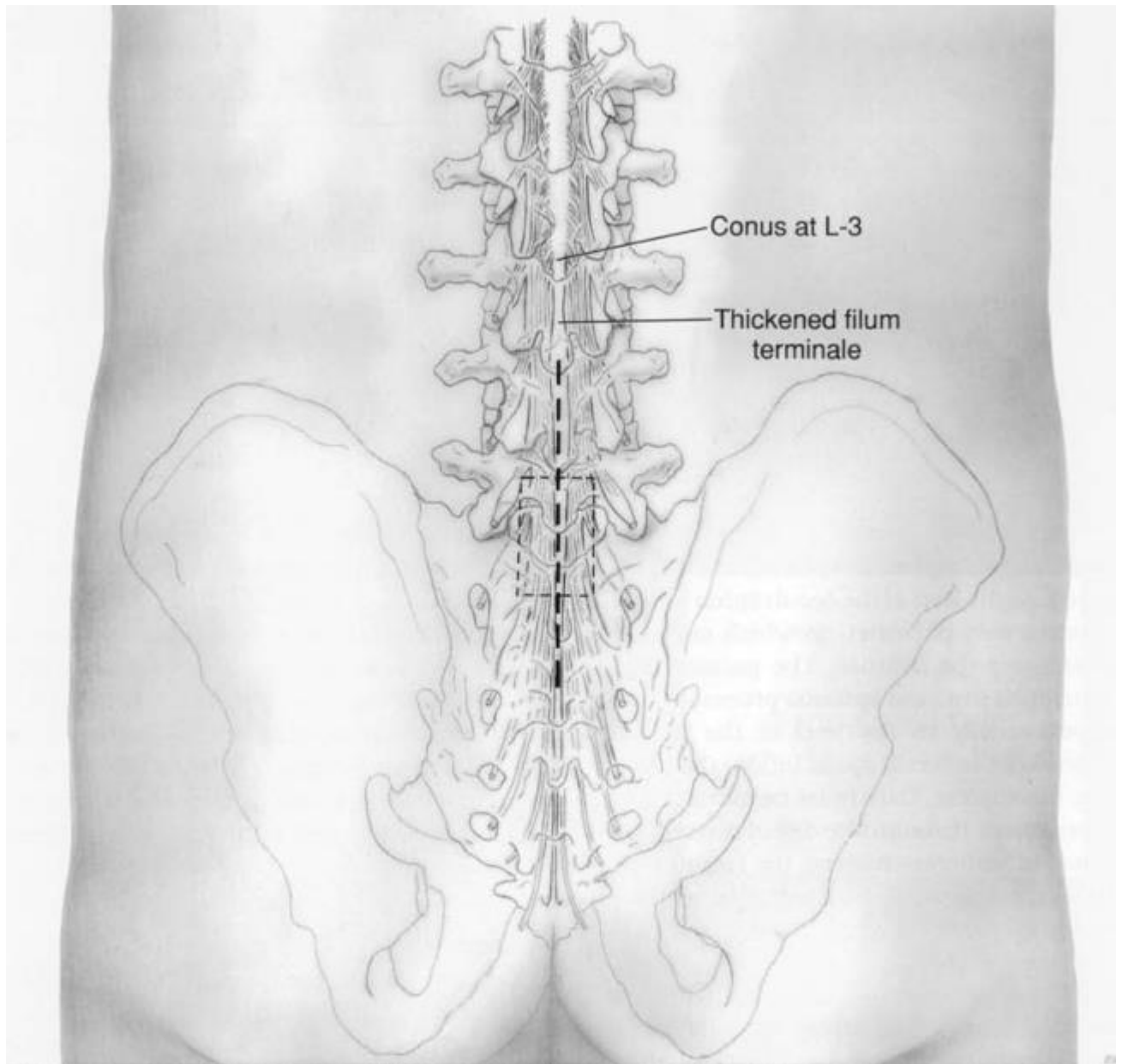


Figure 20–4 (A) The dura is opened longitudinally and the filum terminale is exposed. (B) The thickened filum is elevated using a sharp nerve hook. It is inspected carefully for adherent nerve rootlets. Electrical stimulation may be necessary to differentiate this structure from a nerve root.

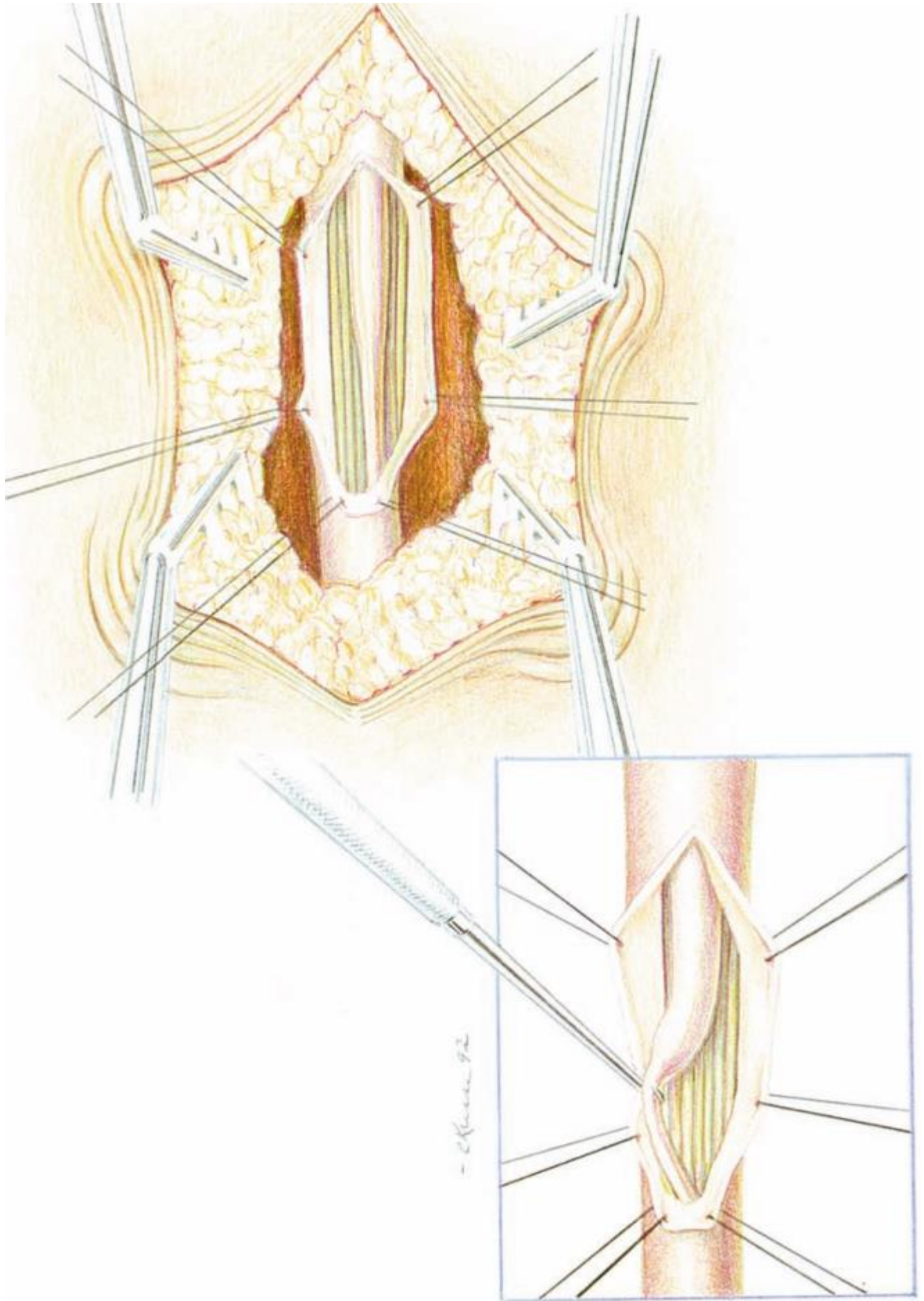
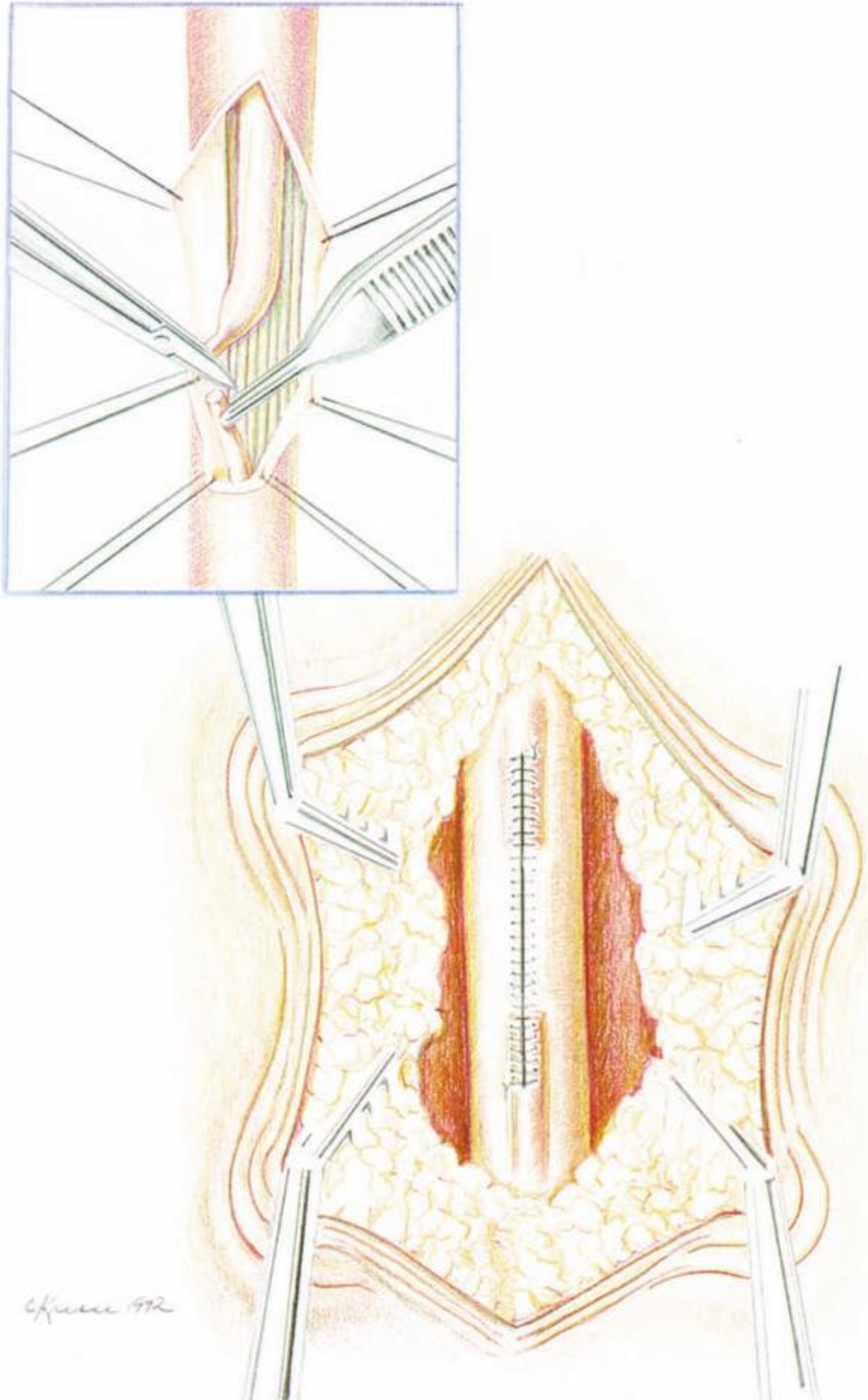


Figure 20-4 (cont'd) (C) Bipolar coagulation prior to sectioning prevents bleeding from the retracted ends of the dura following transection. (D) The dura is repaired in a watertight fashion with 4-0

braided nylon or silk. Note the rostral migration of the conus medullaris following sectioning of the filum.



Closure

Prior to closure of the dura, the intradural space is thoroughly irrigated with sterile saline to wash out any blood. Once hemostasis is obtained and the irrigant is clear, the dura is closed with 4–0 Surgilon sutures (Fig. 20–4D). A Valsalva maneuver is performed to verify the integrity of the dural closure. The epidural space is irrigated with bacitracin in saline. Gelfoam is then placed in the epidural space to serve as a blood patch to prevent spinal headaches. A dural sealant such as Tisseal or DuraSeal (Confluent Surgical Inc., Waltham, MA) placed in the epidural space may allow earlier mobilization of the child. Quarter percent bupivacaine can then be infiltrated in the paraspinous muscles and wound edges for postoperative pain control. The paraspinous muscles and fascia are then reapproximated with 2–0 or 3–0 interrupted Vicryl sutures. The subcutaneous tissues are reapproximated, and the skin is closed with subcuticular Monocryl sutures.

Postoperative Management Including Possible Complications

Dermabond (Ethicon Inc., Somerville, NJ) skin glue is applied to the wound to allow for early bathing without wound contamination. The patient is also left horizontal for up to 8 hours, thereby preventing spinal headaches. The patient's diet is advanced as tolerated and fluids are encouraged. Patients are generally discharged home on the first postoperative day once ambulatory and voiding.

Complications and Prognosis

Low-grade fevers or symptoms of meningismus may occur secondary to intradural blood. Occasionally children may develop difficulty with urination requiring intermittent catheterization from manipulation of the lower nerve roots. All of these symptoms may prolong hospitalization; however, most resolve spontaneously within a few days. There is a very low risk of infection and also minimal blood loss occurs during this procedure. Spinal fluid leak is a risk but uncommon with good watertight wound closure. Souweidane and Drake have reported two cases in which the sectioned filum terminale scarred into the wall of the dura and, over time as the children grew, led to recurrent tethering. Aside from these two cases, it is generally felt that sectioning of a symptomatic filum is curative. Orthopedic and motor deficits should stabilize and sensory symptoms are likely to resolve. However, follow-up MRI imaging will always demonstrate a low-lying conus and, in the absence of clinical history, will be interpreted by the radiologist as showing a tethered spinal cord.

Acknowledgment

This chapter is a revision of the chapter, "Sectioning of the Filum Terminale" by Frederik A. Boop, M.D., and William M. Chaddock, M.D. The chapter appeared in the Neurosurgical Operative Atlas, Volume # 3 , edited by Setti S. Rengachary and Robert H. Wilkins. The Neurosurgical Operative Atlas was published by the American Association of Neurological Surgeons (AANS) from 1991 to 2000. We would like to acknowledge and thank William M. Chaddock, M.D., for his help and efforts on the original chapter published in the first edition of this work.

INTRAMEDULLARY SPINAL LIPOMA

Patient Selection

- rare congenital lesions that **may lay dormant** for many years or decades.
- predilection for involvement of the dorsal aspect of the cord, but the fat is not connected with a defect of the arachnoid, dura, laminae, or skin - **not associated with spina bifida occulta**
- **symptomatic lesions** (myelopathy or pain) are approached as any other intramedullary tumor.

Operative Procedure

- goal of the operation is not to remove every pocket of fat but rather to debulk significant mass effect leaving the interface between the spinal cord and the lipoma unmanipulated.

- CUSA or CO2 laser at very low wattage - fat removed and the fibrous septa between the various compartments of fat can be disrupted
- cord may be reconstructed into a tube
- redundant dura is closed primarily and tented dorsally in an effort to prevent adhesion from the resection site to the undersurface of the dura.

LIPOMYELOMENINGOCELE

- SSEP and EMG monitoring.
- prone position on the chest rolls in transverse position.
- Colorado Bovie tip to incise the midline skin to visualize normal anatomy.
- laminectomy to expose normal dura.
- dura is opened in midline and distal exposing fibrolipomatous mass intermingling with conus and nerve roots.
- operative microscope.
- nerve roots are dissected free from fibrolipomatous mass using **Beaver blade**.
- nerve stimulation helped to identify functional nerve roots.
- fibrolipomatous mass is cauterized and amputated distal to the level where no more functional nervous tissue was present.
- proximal fibrolipomatous mass is debulked using **KTP laser** (up to 5 W continuous regimen) as well as **CUSA**.
- irrigation and bipolar cauterization to provide a hemostatic field.
- thecal sac reconstructed with continuous running 4-0 silk and triangular **Dura-Guard patch** leaving ample space for CSF to bathe distal spinal cord (to prevent tethering).
- distally if no normal dura present - patch is secured to lumbosacral fascia edges.
- covered with Tisseel and Surgicel in two layers.
- remaining fascia is closed with 3-0 Vicryl interrupted sutures.
- skin - running subcuticular 4-0 Monocryl suture → Dermabond.
- flat for 3 days in PICU.

From Goodrich (2008)

Subcutaneous fatty tumors over the midline lumbosacral region usually emerge through a fascial, bony, or dural defect and ultimately involve the caudal spinal cord. These lesions are best described by where they grow into the cord (dorsal or caudal). Lipomyelomeningoceles are part of the larger group of conditions termed occult spinal dysraphism and may be found in conjunction with a split spinal cord, tethered spinal cord, or other forms of this broader group. They do seem to have an enhanced genetic predisposition and may be associated with a Chiari I malformation or occasionally hydrocephalus. The special circumstance of a fatty mass associated with a terminal syringohydromyelia will be discussed later.

Patient Selection

Symptoms related to these lesions range from a cosmetic presentation at birth with a significant subcutaneous fatty mass in the midline over the lumbosacral region to a subtle subcutaneous lipoma associated with primary or secondary urinary incontinence. It is unusual today to have children present primarily with evidence of pain or motor disturbance involving the lower extremities. In large part this is due to an increased awareness of the progressive natural history of this lesion and the ease of confirmation of spinal cord involvement by MRI. Decreased or absent rectal tone combined with a neurogenic bladder is a clinical indication of lower sacral root involvement from a neurogenic cause and should be investigated further. Today the procedures of choice to confirm the pathological anatomy are MRI and radiographs of the lumbar spine. These two modalities have almost totally

replaced CT myelography. Additionally, useful information can be obtained from urodynamic testing and occasionally from electromyography of the lower extremities. The **natural history of patients with a lipomyelomeningocele is a progressive loss of neurological function**. Occasional exceptions to this natural history can be demonstrated, but the vast majority of infants followed prospectively without operative treatment will develop progressive and relentless deterioration. Some forms of lipomyelomeningoceles can more clearly be positively influenced by surgery than others. These would include simple dorsal tubes of fat having a discrete point of fixation with the spinal cord. Lesions associated with a blending of the neural elements with the lateral aspect of the dural cul-de-sac benefit less certainly from operative intervention.

Although most North American pediatric neurosurgeons continue to favor early intervention for all infants, other well-respected pediatric neurosurgeons have questioned this approach and may wait for the individual patient to demonstrate clear loss of neurological function before recommending intervention.

Surgical exploration should include release of the traction on the cord and resection of a significant amount of the intramedullary lipoma. **Reversal of bladder dysfunction is unlikely once it is established**. For this reason alone, early aggressive surgery is logical and justified if felt to be feasible. It should be mentioned that there is no place for a superficial excision of the subcutaneous lipoma without disturbing the intradural contents. A superficial excision seriously complicates the eventual intradural procedure by the development of significant intradural adhesions.

Preoperative Preparation

A patient chosen for exploration of the lesion is positioned prone with soft supports under the iliac crest and chest to allow free excursion of the abdomen. This significantly lessens epidural bleeding. The hips are flexed and, again, intraoperative rectal and urethral monitoring may be utilized.

Operative Procedure

The skin incision is made in the midline directly over the subcutaneous mass and extends both above and below the mass (Fig. 10-3A). A common error is not to allow sufficient distal room for adequate exposure of the lesion. For routine lesions it is necessary to have access from the lower sacrum to two segments above the level of the fascial defect. The subcutaneous lipoma is almost always easily separable from the lumbodorsal fascia and the skin. As the neck of the lesion is circumferentially developed, large amounts of superficial lipoma may be excised, reducing the bulk of the lesion. The neck of fat coursing through the fascial defect is retained at this point (Fig. 10-3B). The soft tissues and muscle adherent to the last intact spinous process and laminae are reflected laterally (Fig. 10-3C). The muscles and other soft tissues circumferentially adherent to the rudimentary laminae surrounding the neck of the lesion are also dissected. Immediately caudal to the last intact laminae a band of fibrous tissue corresponding to the periosteum of an incompletely formed bony element will commonly be encountered. With sectioning of this band the dura may expand significantly into the area. This band may be associated with acute angulation of the malformed cord as it is drawn dorsally toward the subcutaneous lipoma. Sectioning this band may significantly relieve the tension on the cord and reduce its posterior angulation (Fig. 10-3C). With adequate exposure of the dural tube cephalad to the lipoma, it is opened in the midline. Asymmetrical exiting roots can then be seen. The junction of the dura to the neck of the lipoma as it emerges through the dural defect is a key landmark for further dissection. Special care must be given at this point to appreciate the relationship of the dorsal roots that have been displaced laterally by the lipoma and the dura-lipoma complex (Fig. 10-4A). Obviously, no roots should be sacrificed, and yet the dura needs to be circumferentially dissected away from the dorsally displaced cord (Fig. 10-4B). The asymmetrical arrangement of exiting roots combined with rotation of the cord may further complicate this maneuver. Once this critical maneuver is complete and the cord has been moved into a relaxed ventral position within the dura, attention is turned to the intramedullary component of the lipoma. With the ultrasonic aspirator or the CO₂ laser, the lipoma is progressively thinned until a smaller layer of fat remains against the neural tissue. No attempt is made to completely excise all fat, but the bulk of the lesion is removed,

which then allows reconstitution of a neural tube in most patients. This is done with fine inverted nonreactive suture (Fig. 10–5). Attention is then directed to the filum terminale, which may be thickened. Again, it is separated from the surrounding exiting roots and sectioned. The dura is reapproximated, allowing a capacious CSF space dorsal to the newly formed neural tube. The superficial soft tissues are reapproximated, but not at the expense of the dorsal CSF space. Numerous variations on this anatomical theme exist. One that deserves special comment occurs when the subcutaneous lipoma is asymmetrically situated off the midline and opposite to it is a cleft of grayish blue, thin epithelium. The thinned epithelium is seen to be blue from an underlying CSF collection being formed by a terminal syringohydromyelia (Fig. 10–6). Operatively, this lesion is approached in a similar manner, with circumferential dissection of the subcutaneous lipoma and cyst. With the last intact lamina removed, the dura is opened to expose the caudally displaced spinal cord. The plane between the dura-lipoma complex and the fatty infiltrated cord is again key. The cord may be quite expanded by the combination of fatty infiltration and enlargement of the central canal. Draining the cyst at this point may facilitate the circumferential dissection around the dural attachment to the neck of the lipoma. The dura, too, may be infiltrated by fat. This makes adequate dural closure technically demanding. With careful dissection and constant changing of perspective, eventually the circumferential opening of the dura-fat interface can be accomplished. The dorsal roots may be seen to be adherent to the undersurface of the dura, and prior to each maneuver they should be sought. These roots are laterally displaced and will be seen to exit in an asymmetrical fashion. Excessive fat growing into the neural tissue will then be excised. The very caudal portion of the conus can be reconstructed into a neural tube. This may lessen the likelihood of secondary readherence at the site of separation. At times, a dural graft may be necessary. This can usually be harvested from the two-ply lumbodorsal fascia. Again, watertight dural closure with preservation of a capacious CSF space around the reformed neural tube is ideal. The soft tissue closure superficial to the dura is performed in such a manner that the intradural contents are not constricted and, therefore, are less likely to become adherent.

Figure 10–3 (A) A typical skin incision over the dome of a lipomyelomeningocele. (B) The subcutaneous aspects of the lipoma dissected, the neck of the lesion coursing through the fascial defect is fully developed. Excessive lipoma can be removed safely to allow additional exposure (dashed lines). (C) After excessive circumferential fat is removed, the paraspinal muscles are then dissected off the last intact lamina. The constricting periosteal band immediately cephalad to the neck of the lipoma can then be sectioned.

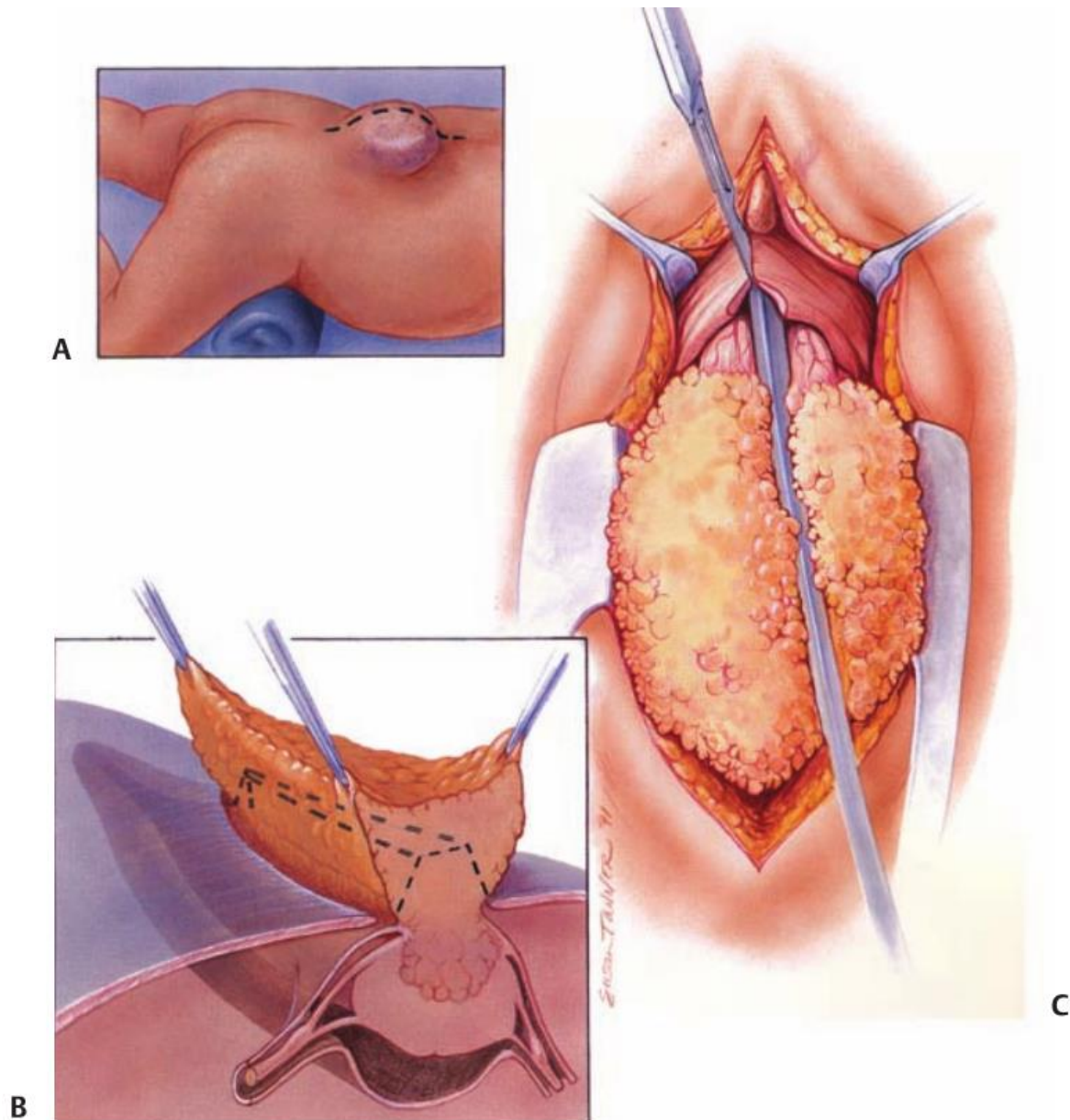


Figure 10–4 (A) A three-dimensional view of a lipomyelomeningocele demonstrating the dura-lipoma complex and the position of the exiting dorsal roots. This relationship varies somewhat from patient to patient and with the degree of rotation of the cord. (B) A surgical view showing a hooked knife being used to open the dura while the cord is rotated slightly for better exposure of the dorsal roots. The upper part of the lipoma is also being excised by the CO₂ laser.

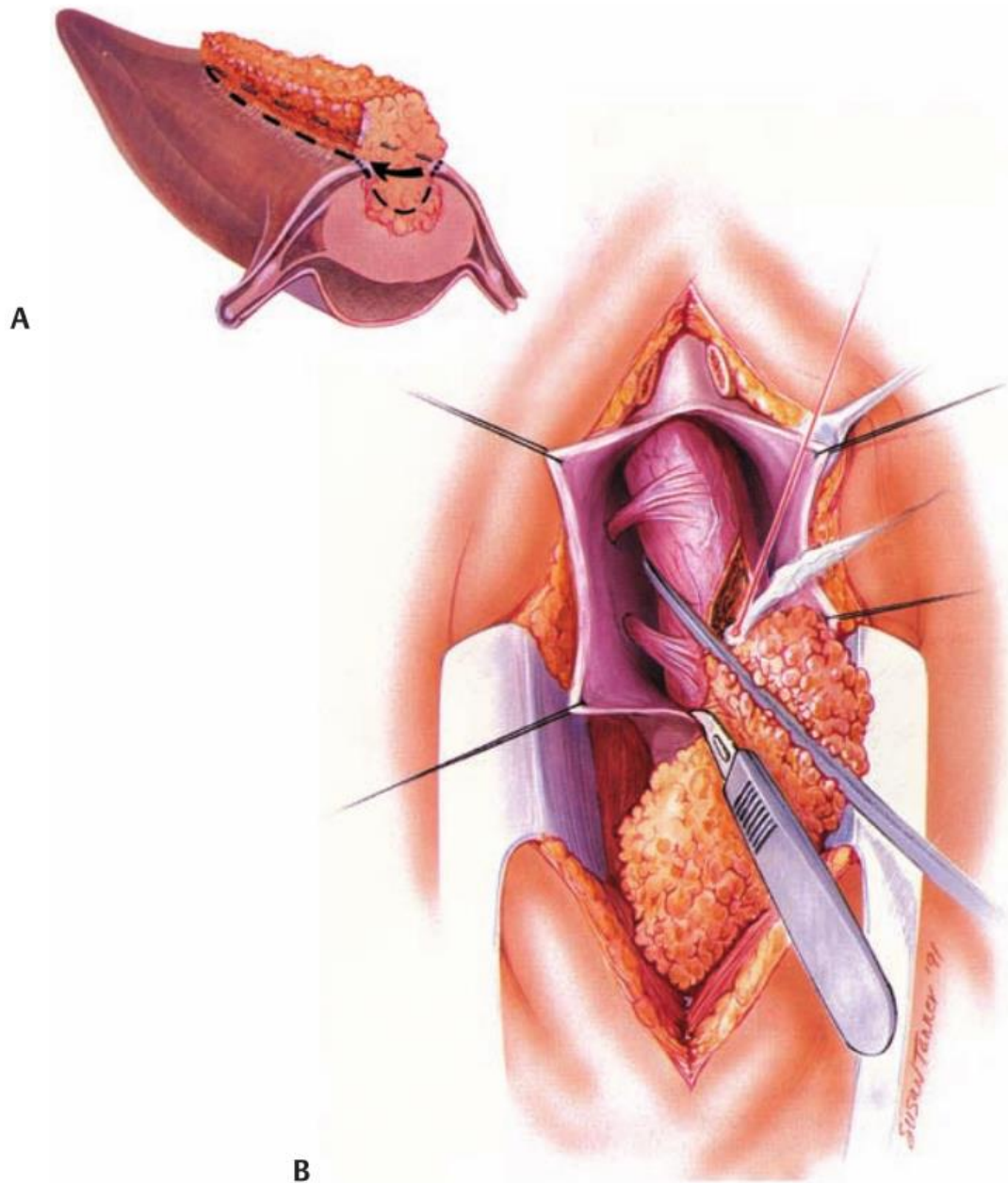


Figure 10–5 Following resection of the bulk of the intramedullary lipoma, the distal cord is reconstituted into a neural tube with inverted fine nonreactive sutures (upper inset). Last, the thickened filum terminale is sectioned. The dura is closed and a capacious CSF space dorsal to the newly formed neural tube is created (lower inset). This lessens the likelihood of retethering at the operative site.

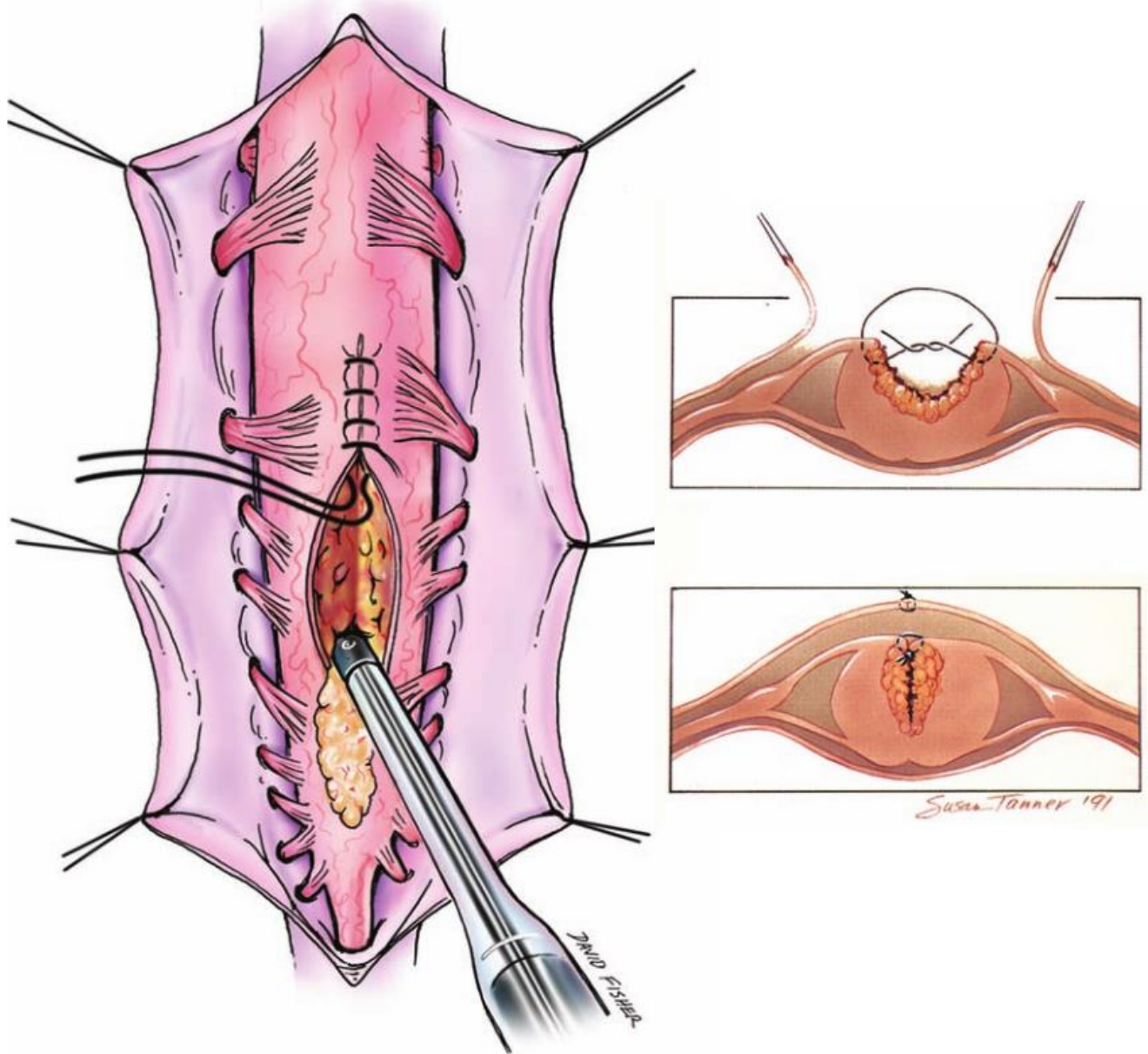
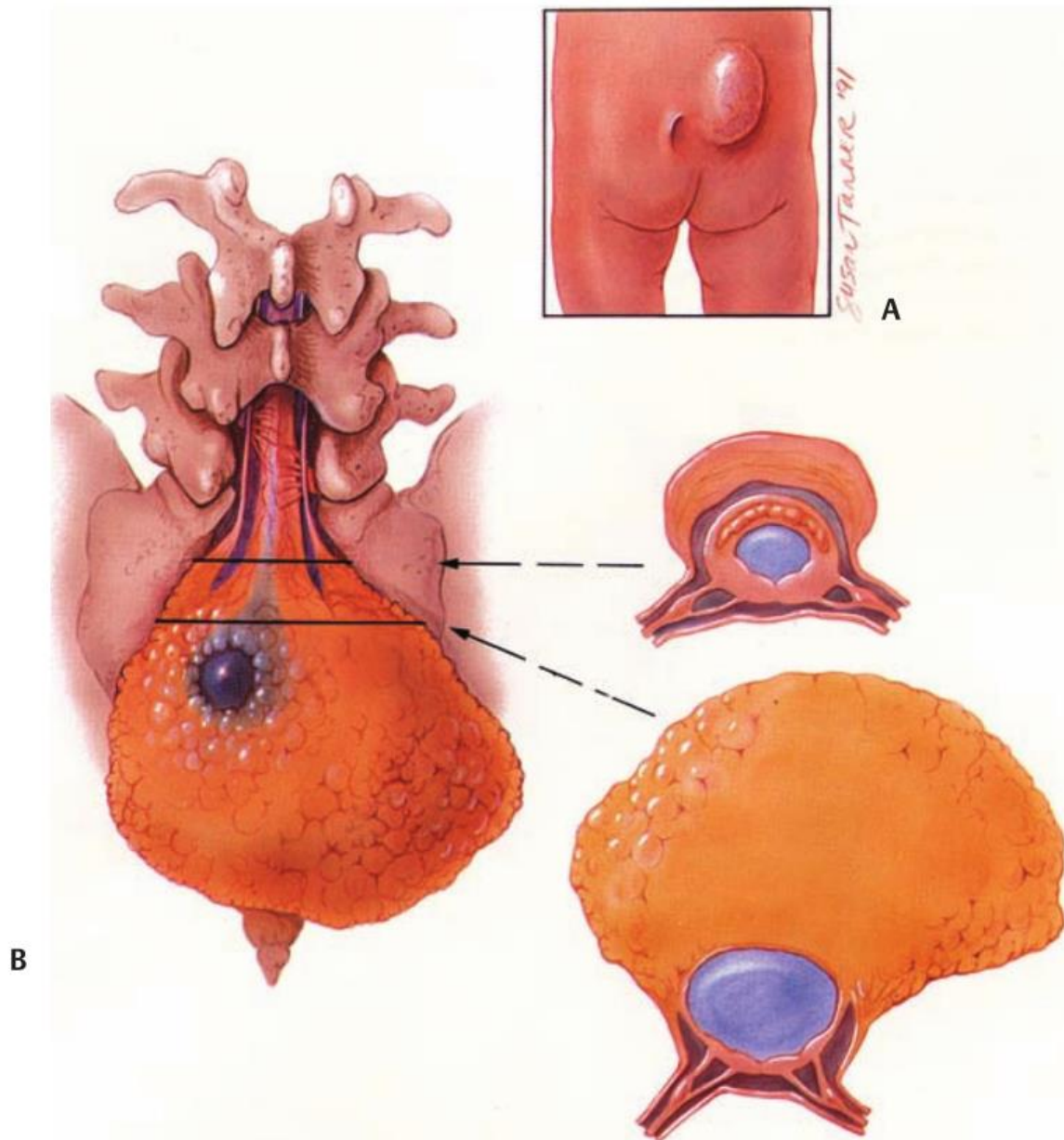


Figure 10–6 (A) Surface landmarks of a cystolipomyelomenin- gocele. Asymmetrical position of the lipoma to the right of midline and a thin epithelial veil over the terminal syringohy- dromyelia on the left are apparent. (B) Anatomical relationships demonstrating the explosive expansion of the caudal lipoma and its infi ltrative nature with respect to the dura and terminal cord. Expansion of the distal central canal (terminal ventricle) into a syringohydromyelia is easily appreciated.



Conclusion

Long-term results following aggressive resection and repair of lipomyelomeningoceles are still being accumulated. What does seem clear is that the risk of a serious permanent injury from the operative manipulation is low in experienced hands and should be much less than 10%. The risks of spontaneous worsening without operation are high, probably greater than 90% within the first two decades of life. The likelihood of 5 to 10 years of clinical stability without further loss of neurological function following surgery is also high. If these are the representative risks and benefits, then early surgical intervention is reasonable and appropriate for most patients with this lesion. There are many anatomical variations within this category of congenital lesions. The experience and judgment necessary in the successful operative manipulation of this lesion are significant. This particular lesion should not be operated on by the surgeon who deals with it only occasionally. Serious loss of bladder and/or bowel function will occur with the inadvertent sacrifice of functioning nerve roots by the surgeon who does not perform this procedure regularly.

From Goodrich (2008) (2-adalis)

Patient Selection

A lipomyelomeningocele is a subcutaneous lipoma that passes through a midline defect in the lumbar fascia, vertebral neural arch, dura, and meninges associated with an abnormally low spinal cord. It is believed to be caused by a failure of dysjunction of the cutaneous and neural ectodermal layers

during secondary neurogenesis. More than 50% of patients will present with a midline cutaneous abnormality overlying the defect, 30% with bladder problems, and 10% with orthopedic deformities and/or neurological deficits in the lower extremities. Most patients are diagnosed at or before birth. Spinal ultrasonography or magnetic resonance imaging (MRI) should be performed on newborns with a subcutaneous lipoma or midline cutaneous birthmark. In infants with normal neurological function, MRI can be delayed until just prior to elective surgery. The appropriate timing of surgery is still debated; however, it has been said that all children by the age of 6 years will have some neurological deficit if the lipomyelomeningocele is not repaired. This remains contentious. It is clear that prophylactic surgery should be entertained only if the risk of surgical complications is small. For those who remain unrepaired, close neurological and urological follow-up is mandatory. It is not uncommon to see newly diagnosed patients present with neurological deterioration in their fourth or fifth decade of life.

Preoperative Preparation

MRI of the entire spine should be performed to rule out other associated abnormalities of the spine and better define the levels of exposure needed, as intradural extension of the lipoma may progress several segments rostral to the point of dural penetration. Although ultrasound is a good screening tool, it does not define the needed anatomical detail in preparing for surgery. Plain films of the spine will likely show spina bifida, fusion abnormalities, and sacral defects in most cases. However, computed tomography (CT) and plain films add little additional information to that supplied by high-resolution MRI. All patients should have a detailed preoperative urological evaluation to document any voiding deficits. This is true whether or not there is a clinical history of voiding dysfunction. There is no longer a role for myelography in the evaluation of these children.

Anesthesia Considerations

The anesthesiologist should use a short-acting muscle relaxant during induction and no muscle relaxant during the surgery to allow for intraoperative stimulation of nerve roots. This also allows for the recognition of motor responses in inadvertent stimulation of nerve roots. Intraoperative monitoring of spinal cord, bladder, or rectal sphincter should be considered during the procedure.

Operative Procedure

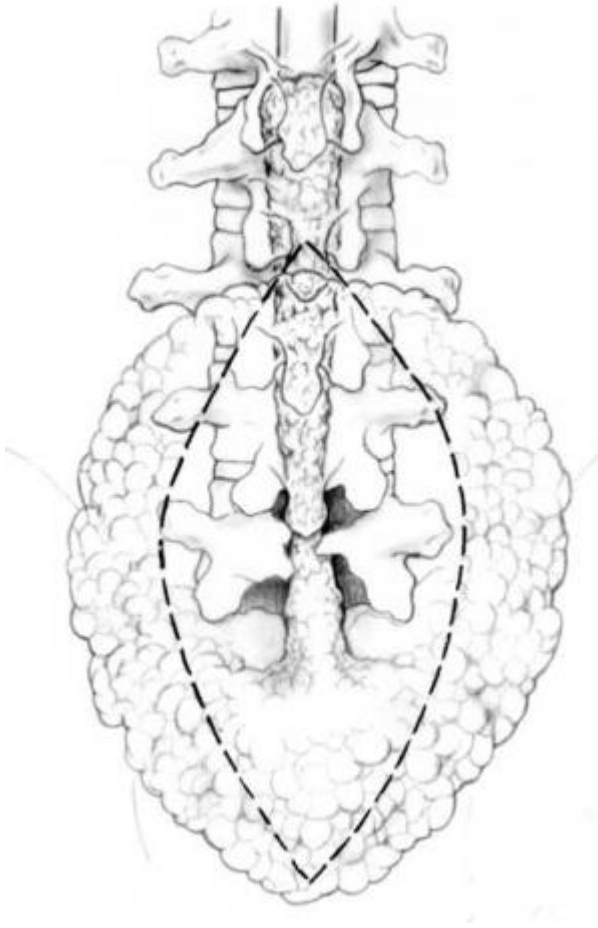
Positioning

After securing the endotracheal tube and placement of a Foley catheter, the patient is placed in the prone position on rolls extending from the chest to the iliac crest. This prevents abdominal compression and secondary distension of the epidural venous plexus, thereby decreasing venous bleeding. The arms are placed on arm boards and all pressure points are padded. The patient is then placed in slight Trendelenburg's position to prevent excessive loss of cerebrospinal fluid (CSF) during the procedure.

Surgical Technique

Following sterile preparation, the skin is covered with an iodine-impregnated drape allowing for extensive caudal to rostral exposure. The skin incision begins midline and cephalad to the subcutaneous lipoma continuing inferiorly, ellipsing the mass. This allows for removal of excessive skin and adipose tissue (Fig. 22–1).

Figure 22–1 An elliptical skin incision (dashed lines) allows for easy removal of the subcutaneous lipoma and later skin closure without redundant tissue.



The incision returns to mid-line caudal to the mass and is extended low enough to expose the cauda equina below the lipoma. Dissection of the subcutaneous lipoma is then performed down to the lumbar fascia (Fig. 22–2A). It is important during the dissection to provide only light retraction on the lipoma as the mass is attached to the dorsum of the spinal cord. The lipomyelomeningocele is then amputated at its area of fascial penetration (Fig. 22–2B). Occasionally, neural elements may extend up into the lipoma, as is seen in a lipomyelocystocele. Therefore, care should be taken to study the preoperative MRI and during the dissection to avoid amputating neural elements should they extend above the level of the fascia.

Figure 22–2 (A) After the skin incision has been made, the subcutaneous lipoma is dissected free from the underlying thoracolumbar fascia. Caution should be used in retracting upon the subcutaneous lipoma because it is attached to the spinal cord. (B) Once the penetration of the lipoma through the fascial defect has been defined, the subcutaneous mass can be removed and the remaining stalk followed through the fascial and dorsal dural defects. (continued)

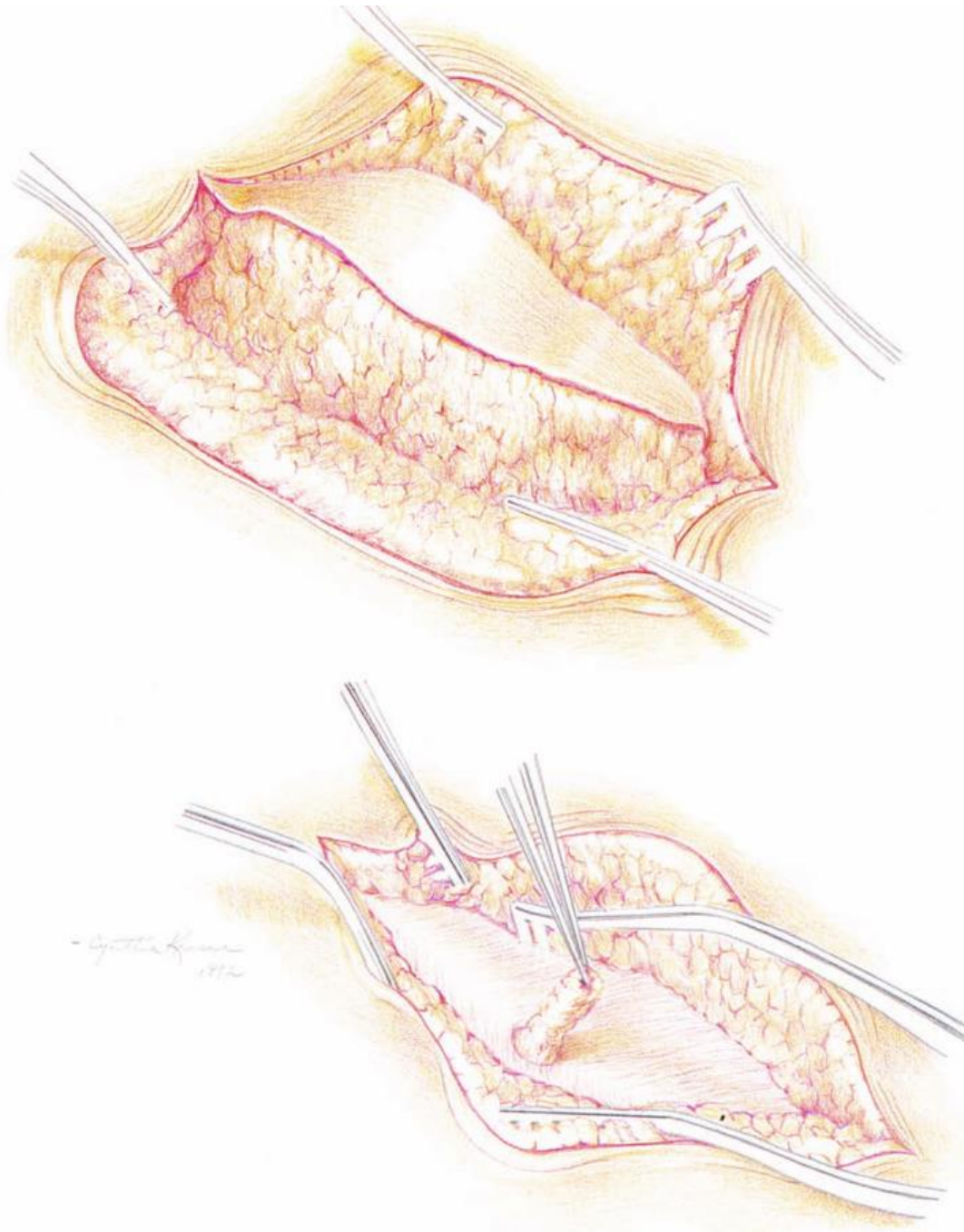
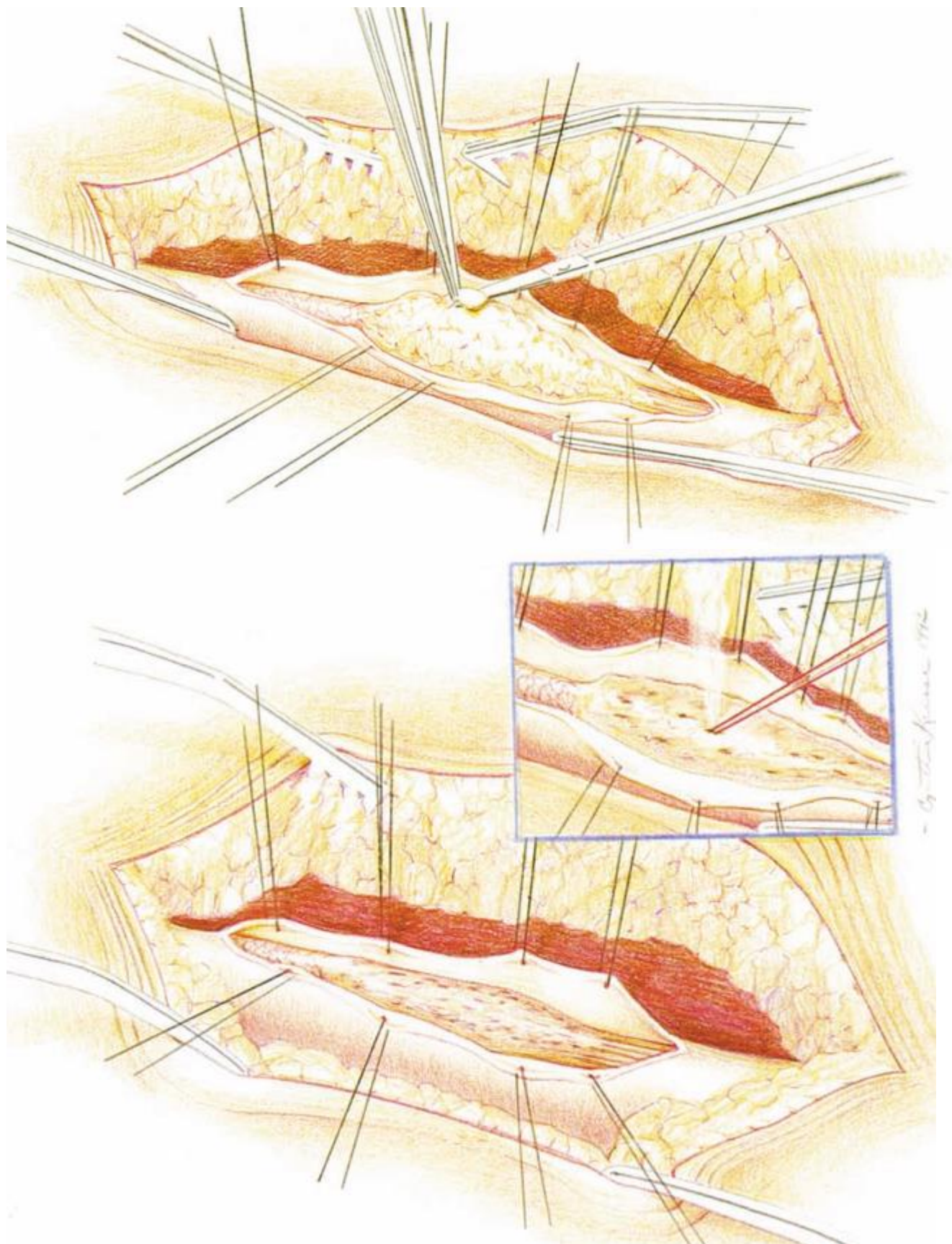


Figure 22–2 (continued) (C) Microscissors and bipolar coagulation are used to debulk the intradural mass. (D) Because the residual lipoma attaches to the neural elements, the CO₂ laser is used to vaporize the remaining fatty tissue. (E) There is an indistinct blending of fibrous and neural tissue at this juncture, and conservatism at this point is wise.



Understanding that neural arches will be malformed or incomplete, the lumbar fascial attachments to the lipoma are carefully dissected free and the fascia is opened in the midline caudal to the mass. The lamina is then exposed with meticulous dissection, avoiding inadvertently passing an instrument through a defect. A laminectomy is then performed both rostral and caudal to the dural defect created by the lipoma. Once normal-appearing dura is encountered, the dissection continues in the epidural plane to the area of abnormality. Similarly, normal dura can be exposed caudally and dissected up to the defect. Once the epidural space both rostral and caudal to the lipoma is defined, the dura is then

opened with a scalpel in the midline rostral to the lipoma. Dural sutures are then placed for retraction of the dura. The dural opening is then extended to the stalk and dura-lipoma interface is defined with microdissection. In the case of a terminal lipoma, the stalk will appear as a fatty extension of the spinal cord, taking the place of the filum terminale. In such cases, the nerve roots are usually free both ventral and lateral to the lipoma. Once the nerve roots are clearly identified, the lipoma may be surgically removed at its exit from the dorsal defect in the thecal sac. During the dissection the use of a nerve stimulator may prove valuable in differentiating aberrant nerve roots from scar tissue. Rectal sphincter electromyography (EMG) and pudendal nerve monitoring may also be of use. In other cases, the so-called dorsal lipoma usually attaches to the dorsum of the spinal cord, just rostral to the conus medullaris. Dorsal lipomas may occur anywhere along the spinal cord and have been seen in the cervical and thoracic regions as well. The nerve roots will typically exit ventral to the lipoma. It is not unusual for nerve roots to infiltrate the lipoma or be adherent to the undersurface of the lipoma. Again, intraoperative neurophysiological monitoring can be of help in distorted anatomy. Remembering that one is working over the spinal cord; the use of intraoperative somatosensory evoked potentials may be useful as well. These lipomas may at times extend several centimeters rostrally or distally within the pia of the normal spinal cord. In such cases, their expansion may act like an intramedullary spinal cord tumor, causing injury by compression. The recognition of this pathology may require one to perform a myelotomy, following the lipoma and debulking it with the laser to completely decompress the involved spinal cord. The untethering requires meticulous dissection of the nerve roots from the mass with the use of microscissors and irrigating bipolar forceps (Fig. 22–2C). An ultrasonic aspirator or contact yttrium-aluminum-garnet (YAG) laser is useful for careful and meticulous debulking of the lipomatous remnants (Fig. 22–2D). Once again, caution must be taken as the transition from lipoma to neural tissue is indistinct; therefore, conservative partial resection is preferred (Fig. 22–2E). Care must be taken to completely free the lipoma from the dural attachments to allow for successful untethering.

Transitional lipomas are a mixture of the dorsal and terminal variants with the rostral portion mimicking the dorsal variant with a transition ventrally as one moves caudally in the canal. In such cases, the conus is often bulbous or misshapen. These are particularly difficult as the nerve roots exiting the malformed conus often travel through the lipoma and are intermingled with the fatty tissue. They may be long on one side and short on the other. In some instances, these malformed roots may even serve as a source of tethering. Transitional lipomas at times may be too extensive to allow for safe untethering of the patient. In the patient with minimal deficits, one must at times terminate the procedure rather than risk injuring the child. Once the lipoma has been debulked, careful inspection of the cauda equina is performed. This allows for lysis and removal of adhesions that could potentially cause tethering. Sectioning of the filum terminale should be performed if it appears to have an abnormal or thickened appearance. Meticulous hemostasis is achieved and irrigation of the intradural space performed. The dura is closed primarily if there is redundant tissue. Otherwise, a dural patch should be placed with interrupted 4–0 Gore-Tex sutures. After watertight closure of the dura, irrigation of the epidural space is performed with bacitracin in saline. A Valsalva maneuver is performed to assess the dural closure. A dural sealant may then be placed over the suture line to lessen the risk of a spinal fluid leak. The fascia is then closed with interrupted absorbable sutures. The subcutaneous tissues are also closed in a watertight fashion with interrupted Vicryl sutures. Finally, the skin is closed with interrupted 4–0 Surgilon sutures or 4–0 Vicryl Rapide. Dermabond (Ethicon Inc., Somerville, NJ) skin glue is placed over the incision to prevent soilage.

Postoperative Management Including Possible Complications

If the dural closure is tenuous, the patient should be nursed in the horizontal position for 48 to 72 hours postoperatively. This will theoretically avoid spinal headaches and will allow the suture lines to begin healing without any additional stress. The Foley catheter is left in place while the patient remains flat. Once removed, the patient may require intermittent catheterization if voiding is difficult to initiate. Bladder function almost always returns to normal within 1 week of surgery. It is important to begin stool softeners postoperatively to avoid constipation and straining at stool. Some patients may have paresthesias or dysesthesias in the lower extremities during the first few postoperative days,

which generally resolve in a few days in the pediatric population. In adults, this neuropathic pain tends to persist and can be very problematic.

Acknowledgment

This chapter is a revision of the chapter, "Repair of a Lipomyelomeningocele" by Frederick A. Boop, M.D., and William M. Chaddock, M.D. The chapter appeared in the Neurosurgical Operative Atlas, Volume # 3, edited by Setti S. Rengachary and Robert H. Wilkins. The Neurosurgical Operative Atlas was published by the American Association of Neurological Surgeons (AANS) from 1991 to 2000. We would like to acknowledge and thank William M. Chaddock, M.D., for his help and efforts on the original chapter published in the first edition of this work.

MYELOMENINGOCELE CLOSURE

PREOPERATIVE, CONSERVATIVE MEASURES

– see p. Dev3 >>

SURGICAL MANAGEMENT

- **closing** all but prognostically worst cases.

- if child is not critically ill, *early treatment is preferable* (no data to support that emergency closure improves outcome) - reduces rate of infectious complications.

Operation within first 24-48 hours postnatally is standard.

- closure delay for several days (with exception of cases with CSF leak) under antibiotic coverage does not affect outcome adversely.
- experimental *intrauterine repair* of myelomeningocele reduces neurologic sequelae.
- surgical goals: elimination of CSF leakage (prevention of meningitis), preservation of neurologic function.

CLOSURE PROCEDURE

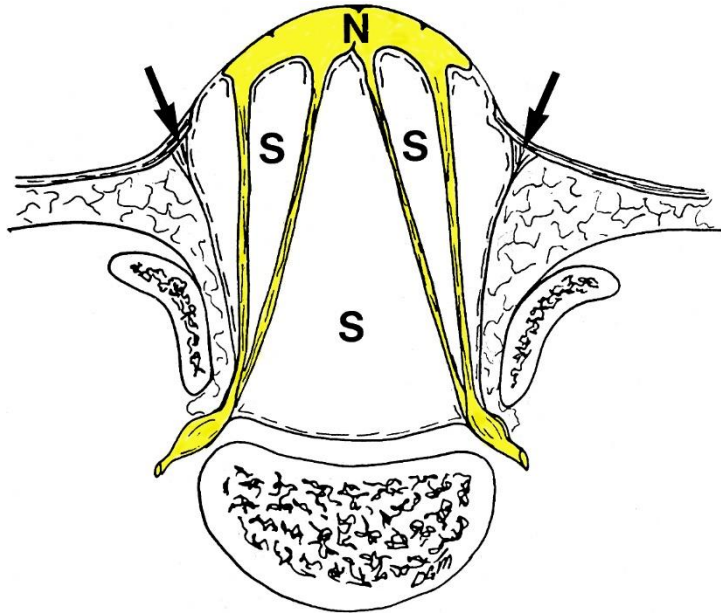
PATIENT POSITION

(on BairHugger)

- transverse rolls support and suspend chest and pelvis
- head rotated to side; "doughnut" under head for support, without compression of external ear
- arms at sides
- Mepilex on knees

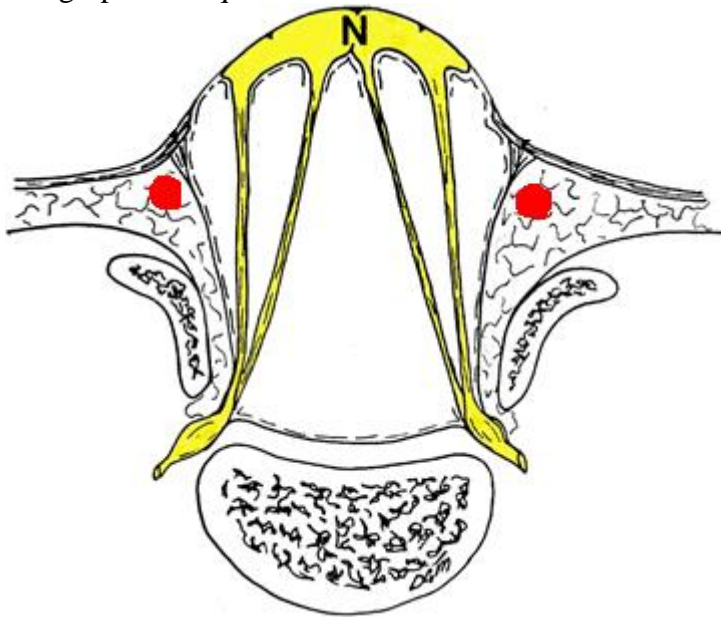
TECHNIQUE

Transverse section through myelomeningocele: arrows demonstrate junction of neural placode (N) with dura mater and skin; subarachnoid space (S):

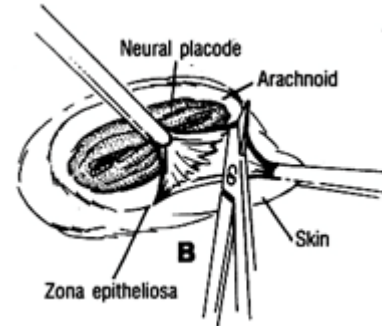
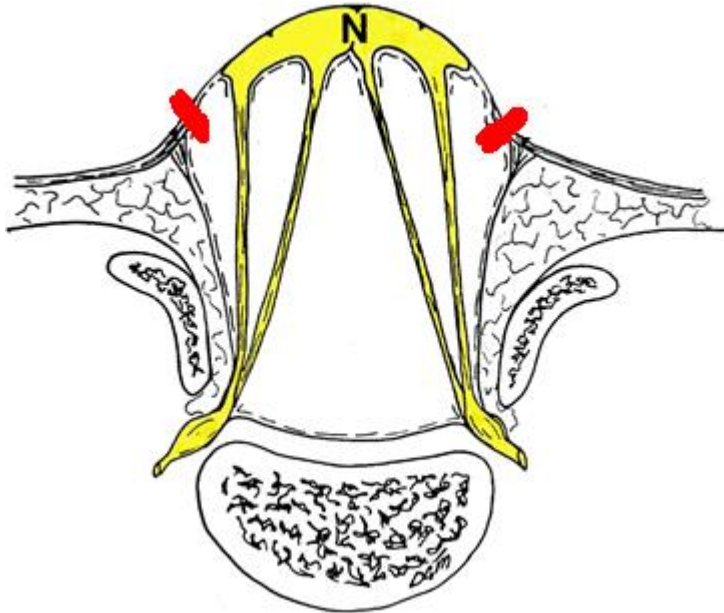


Source of picture: David C. Sabiston "Sabiston Textbook of Surgery: the Biological Basis of Modern Surgical Practice", 15th ed. (1997); W.B. Saunders Company; ISBN-13: 978-0721658872 >>

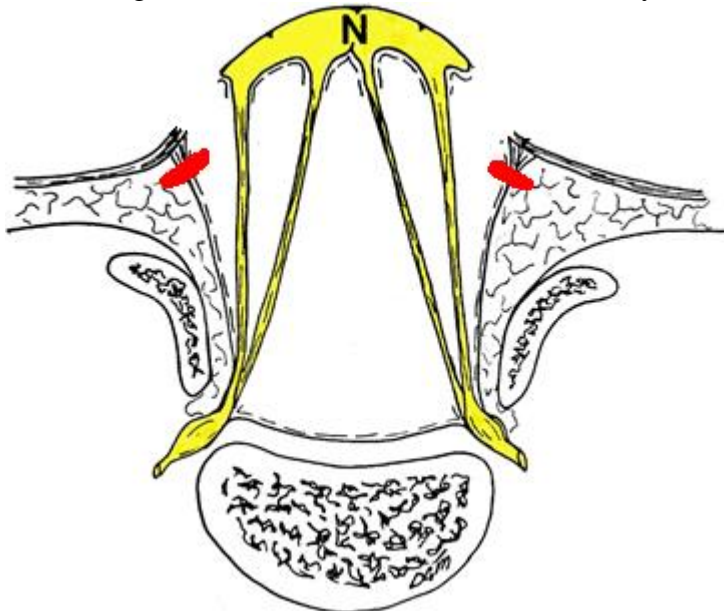
- midline normal skin incision just distal to MMC
- using tip of mosquito find distal dural sac end and tunnel on both sides of dural sac (epidural fat):



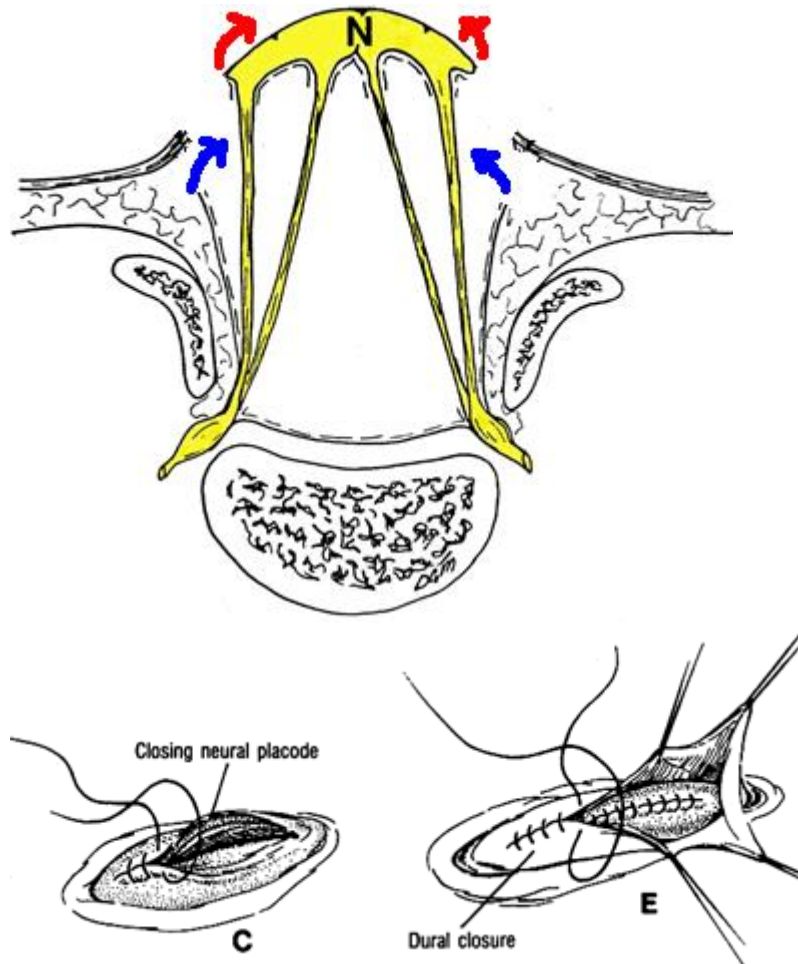
- careful **separation of neural placode** from surrounding epithelial tissue - open MMC sac with fine scissors and dissect placode circumferentially (both sides, caudally; cranially dissect over the spinal cord where it comes to join placode):
 N.B. trim placode sides from any dermal / epidermal remnants (will form inclusion dermoid if left in place)!



- then disconnect dura from dermis just at junction with it (one leg of scissors in epidural space, another leg on subdural side) - both sides, caudally, and cranially:



- **placode anatomic repair** by formation of tube with fine sutures (imbricate placode with 8-0 Prolene) - creating surface which is covered in pia arachnoid (to prevent rethethering in scar tissue when dura is closed); then **close dural sac** over it (cover with Tisseel; occasionally thin dura needs to be reinforced with muscle and fascia):



- skin defect needs **plastic surgery closure**: undermine skin flaps; best to use skin-fascia flaps (subfascial dissection - uninterrupted blood supply); rotated skin flaps and relaxing incisions may be necessary

POSTOPERATIVELY

- child is nursed **prone** while closure heals
- monitored for development of **hydrocephalus**.

COMPLICATIONS

- 1) **hydrocephalus** - develops rapidly after myelomeningocele closure (many become symptomatic *within first few weeks* after closure).
 - after repair of myelomeningocele, most infants (> 90%) require **hydrocephalus** shunting!
 - surgical management of **Chiari malformation** itself (suboccipital craniectomy & cervical laminectomy) may become necessary when prominent brain stem signs develop / persist despite adequate treatment of hydrocephalus.
- 2) **cord infarction**
- 3) **cord compression** by subarachnoid cysts, inclusion cysts from trapped skin appendages.
- 4) **cord re-tethering** in scar tissue (late complication after meningomyelocele repair)!

Patient Selection

- prenatal ultrasound and serum AFP.
- unless the newborn is critically ill, repair of the myelomeningocele should proceed.
- delays increase both morbidity and mortality (although studies have not documented any increase in the deficits in the survivors of briefly delayed closure, our experience with patients transferred late and requiring delayed closure in the face of infection has been a decrease in motor function in some and an increased rate of ventriculitis (37%), as compared with that in patients with early closure (7%). The natural history of unrepaired newborns who are fed but denied antibiotics would indicate that 40 to 60% will survive, often much more significantly impaired. If antibiotics are added to the care of the unrepaired children, the mortality and morbidity fall to levels similar to those of neonates repaired in the first 24 hours. Optimally, we operate on the neonate soon after birth, preferably in the first few postnatal days. Prenatal diagnosis makes this increasingly more possible. The operation may safely be deferred for up to 72 hours without an increase in complications. This delay is particularly important for the unstable or critically ill newborns. These babies can usually be stabilized within 72 hours, and this time is usually well spent. A search for coexistent anomalies of other organ systems should be undertaken during this time. Severe anomalies or absence of vital organs or unreparable cardiac defects may portend a poor outcome. Renal anomalies are common but not usually life-threatening. Although the neonate may not produce significant amounts of urine during the first 24 hours, the presence of urine in the bladder implies the presence of functioning kidneys. Ultrasonography can delineate most major renal anomalies. Syndromes related to chromosomal anomalies may not be obvious upon initial inspection but should be sought out. Although most coexisting anomalies are not immediately life-threatening and may be dealt with without much difficulty, it is important to remember that a few newborns with myelomeningocele may have potentially fatal associated malformations and may not be saved. Intervention to prolong the lives of these infants in the setting of a dismal outlook makes little sense. They should be kept comfortable, and their families should be supported.

Preoperative Preparation

most have a high hematocrit and an adequate intravascular volume, and fluid resuscitation is therefore usually not necessary. Common perioperative complications include hypothermia and hypoglycemia, both of which are easily prevented through the judicious use of heating and monitoring of serum glucose. The placode may become desiccated with prolonged exposure to the air and should therefore be protected. Covering the placode with sterile, saline-soaked gauze is preferable. The dressing may be covered with plastic wrap to prevent rapid evaporation of the saline. Substances that are toxic to tissues and result in inhibition and delay of wound healing should not be used directly on the malformation. The use of perioperative antibiotics is left to the discretion of the surgeon. We have tended to use them.

Operative Procedure

Preservation of Neurological Function

Preservation of Neural Tissue

Prior to closure, the infant should be kept on his or her abdomen to reduce mechanical trauma to the neural tissue. During the subsequent surgical repair, great care must be taken to avoid drying, traction on neural elements, irrigation with hot saline, and excessive use of electrocautery. With magnification and microinstrumentation, the opening of significant blood vessels can be avoided. Occasionally, the entire closure can be performed **without cautery**. It has clearly been shown that the exposed neural tissue is functional. Movement of muscles subserved by spinal cord segments involved in the placode as well as the presence of somatosensory evoked potentials conducted through the placode both point to the functional nature of this tissue. Even when the initial examination fails to demonstrate movement of muscles innervated by the placode, the placode should still be considered

functional because more than one third of these patients subsequently gain motor functions not previously detected. Therefore, all neural tissue must be preserved.

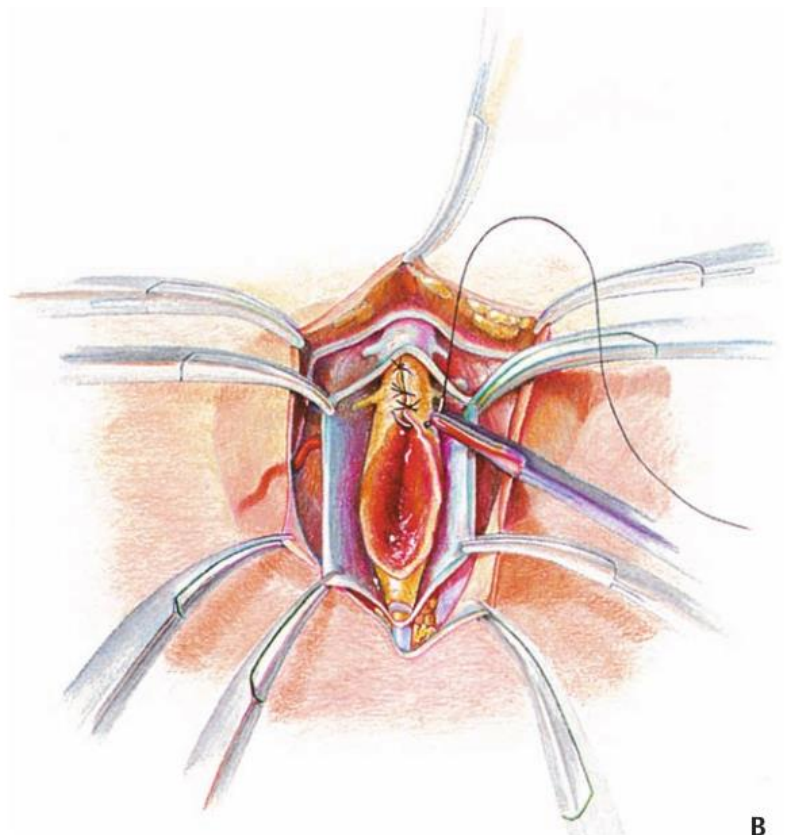
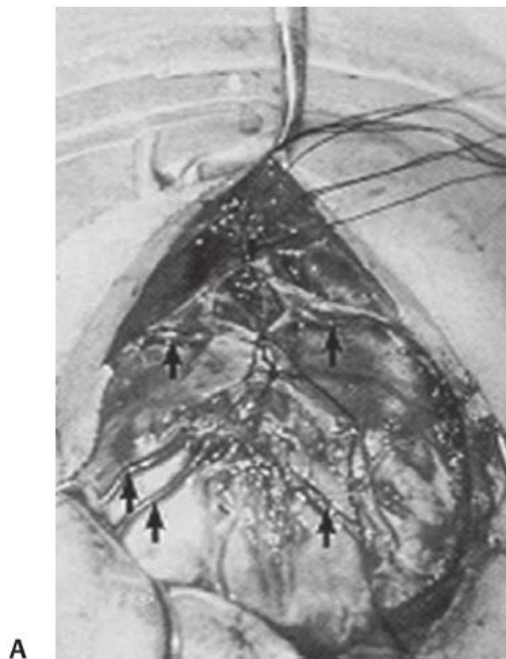
Preservation of Vascular Supply

Preservation of the vascular supply to the placode is essential if this tissue is to survive. Unlike the normal spinal cord, the blood supply to the placode does not enter exclusively through the vertebral foramina along the nerve roots. Many large vessels pass directly through the laterally reflected dura mater and supply the myelomeningocele. Those supplying the junction between the neurulated spinal cord and the placode seem to be at greatest risk. Rarely is it possible to preserve all of these vessels, and, fortunately, they can sometimes be sacrificed if necessary without apparent injury to the placode. Nonetheless, **great care must be exercised to preserve these vessels while mobilizing the dura for closure** (Fig. 15–1A).

Inclusion Dermoid

Great care should be exercised in separating the edge of the placode from the contiguous cutaneous epithelium (Figs. 15–2A and 15–2B). Some pearls of epidermoid tumors may already reside within the placode. Retained fragments, possibly even a single cell, could, if imbricated within the closure, produce an inclusion epidermoid tumor (Figs. 15–3A and 15–3B). These inclusion dermoids produce not only tumors but associated desquamation debris, which may also stimulate an intense arachnoiditis. Later in the child's life, a tethered cord release in the face of the scar produced by this inflammatory process can be extremely difficult.

Figure 15–1 (A) Vessels entering the placode (arrows) are preserved during reconstruction of the neural tube. (B) A drawing shows the free edges of the dura being held open as the neural tube is reconstructed. The arrow indicates the point where the thickened filum was cut. (C) A photograph showing the beginning of reconstruction of the neural tube at the rostral portion of the myelomeningocele. (D) The epidural space lateral to the neural tissue is opened; it is important not to carry this dissection ventral to the neural tissue.



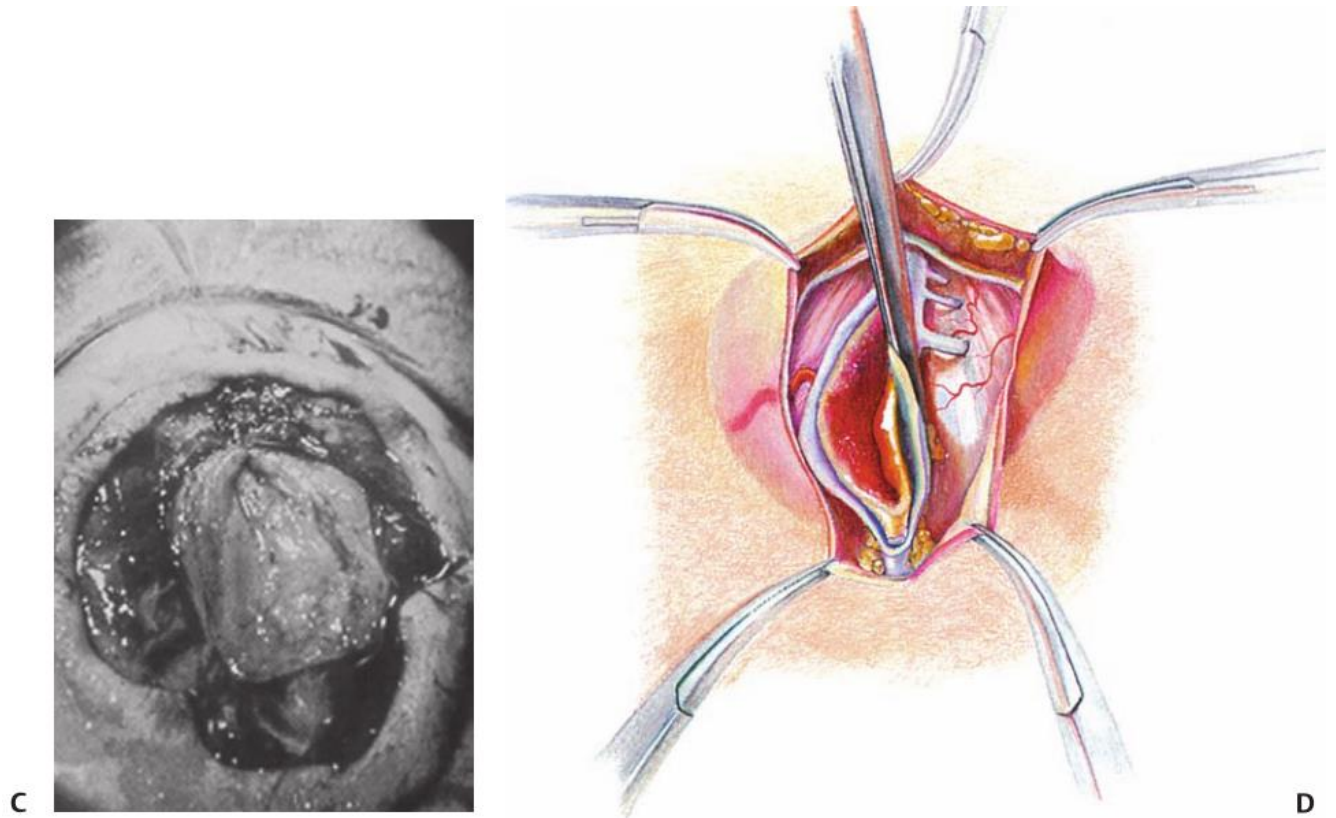


Figure 15–2 (A) A drawing shows the incision being made at the junction of normal and abnormal thin skin. (B) A photograph at surgery shows the abnormal thin skin being cut free at the junction (arrows) of the abnormal skin and the placode.

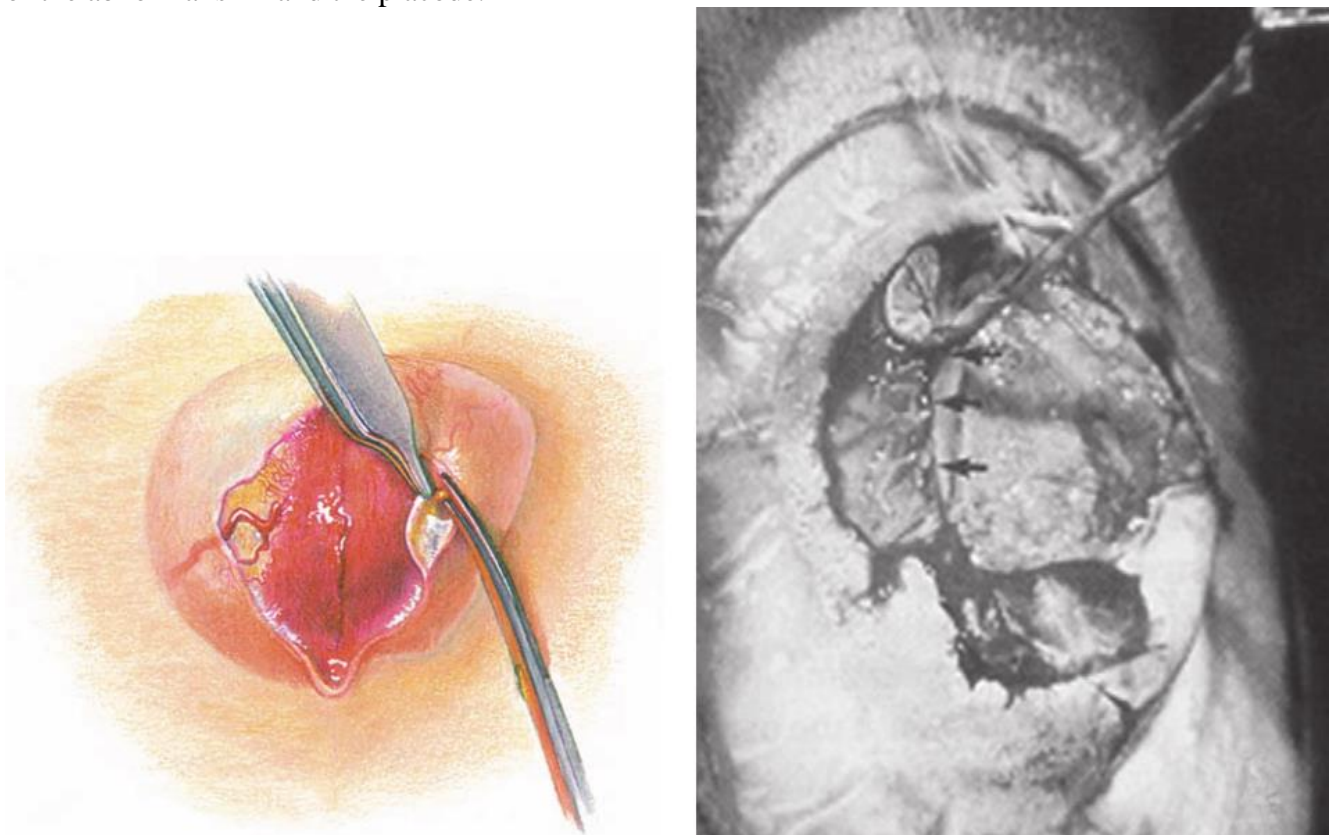
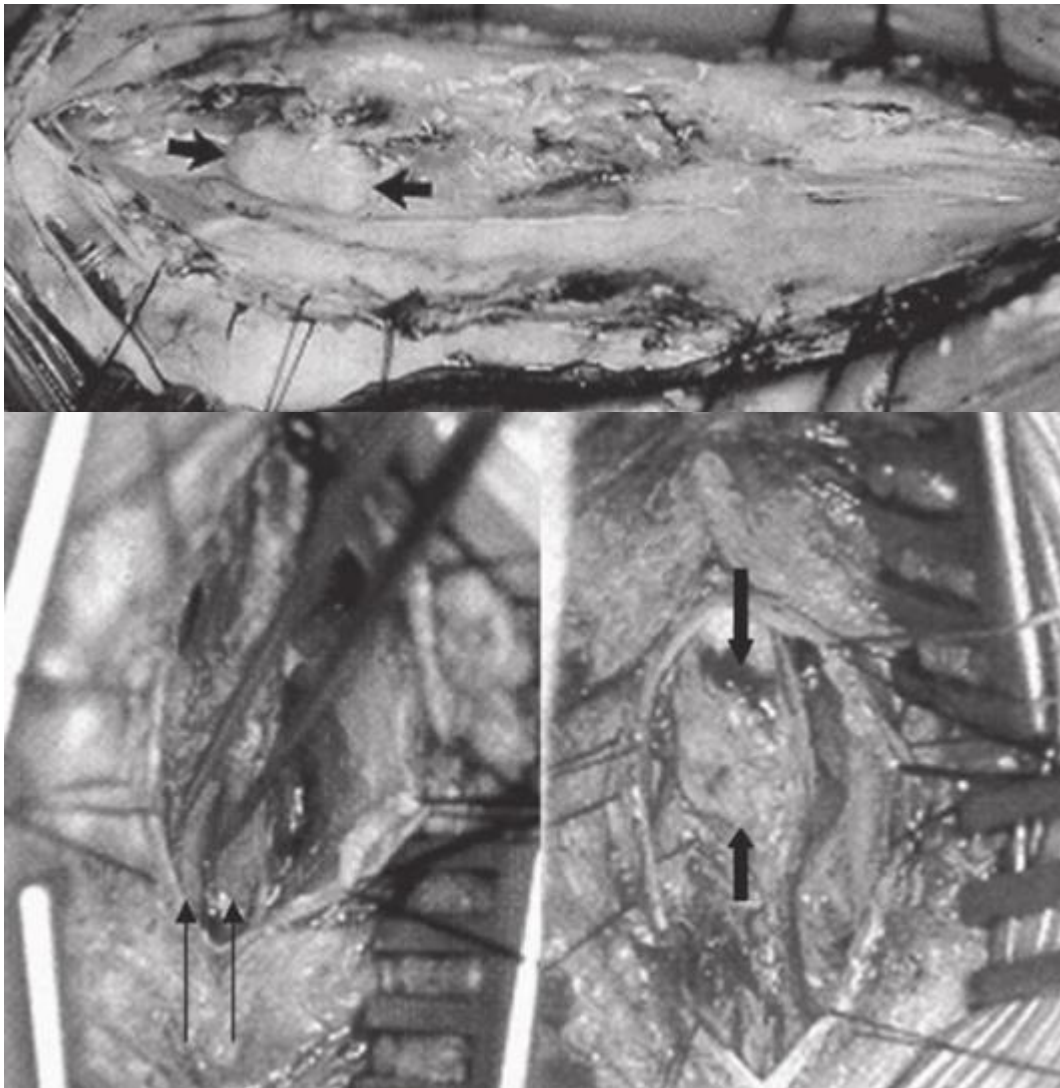


Figure 15–3 (A,B) Intraoperative photographs show inclusion dermoid tumors with marked arachnoiditis. (C) Photo- graph shows a split cord malformation (arrows) proximal to the myelomeningocele.



Missed Abnormalities

Split Cord (Diastematomyelia)

Both the rostral and caudal ends of the closure site should be closely inspected prior to the closure of the placode to identify associated tethering, bony spurs, or fibrous bands. Cranially, removal of an additional lamina may be necessary to adequately visualize the adjacent spinal cord (Figs. 15-3C and 15-4). Hemimyelomeningoceles may also be readily visualized by examining the adjacent spinal cord. The presence of an asymmetrical neurological deficit preoperatively should alert the surgeon to the possibility of a hemimyelomeningocele or an associated split cord malformation.

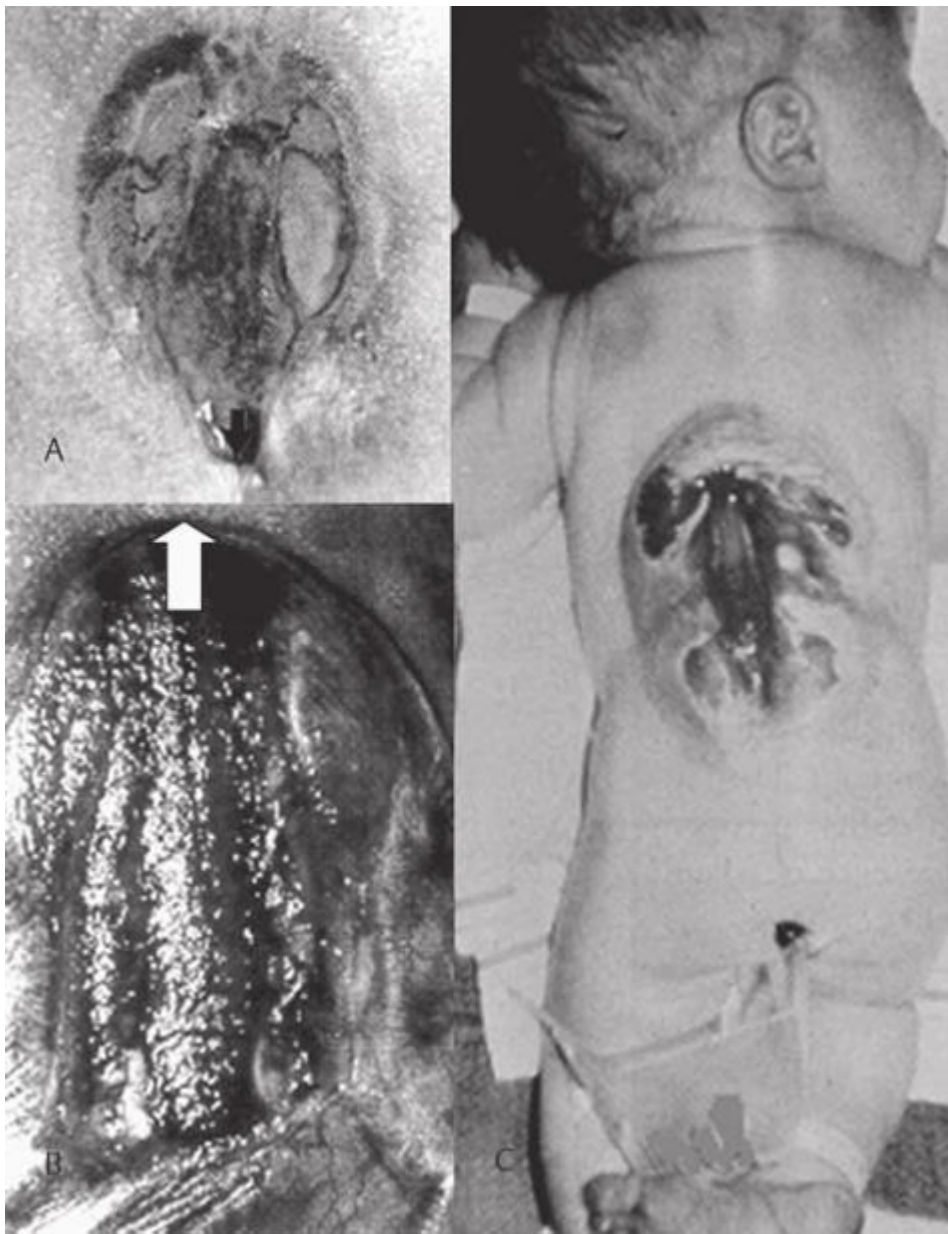
Thickened Filum Terminale

Caudal to the placode a thickened filum terminale may often be present (Figs. 15-1B, 15-5A, and 15-6A). This should be sectioned if present. Spinal cord tethering in these patients may result as much from a missed thickened filum as from adhesions to the placode.

Figure 15-4 A contrast computed tomography scan shows a hemimyelomeningocele, a split cord malformation; the hemi cord on the left had a myelomeningocele.

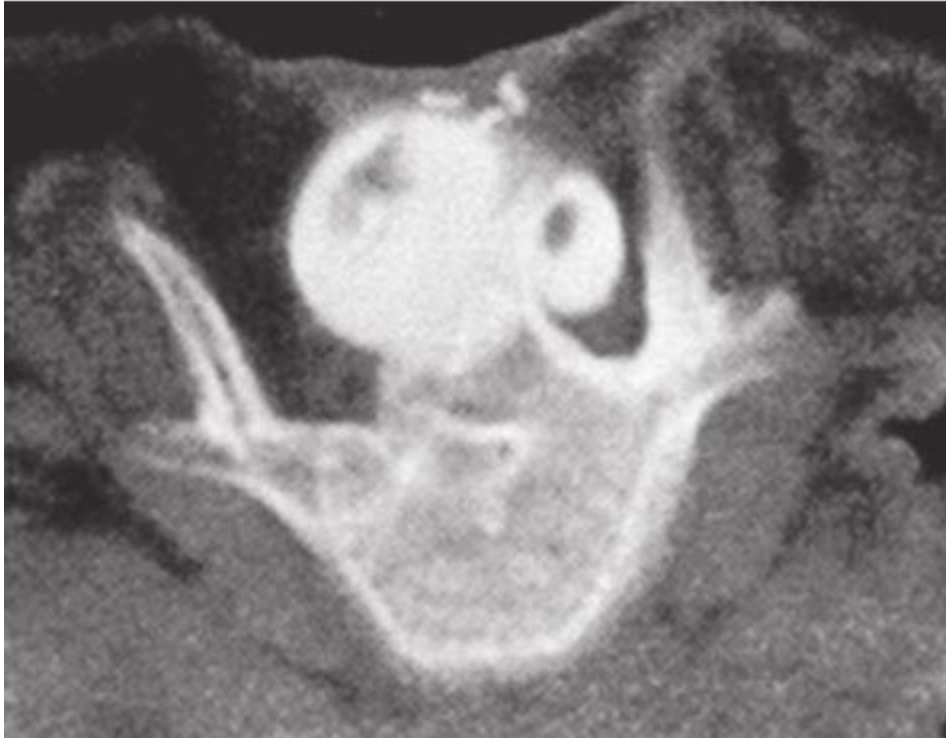

Figure 15–5 (A) A terminal myelomeningocele; the arrow indicates the area of a thickened filum terminale. (B) A larger myelomeningocele shows the ventral sulcus in the midline and the arrow indicates the entrance to the central canal of the adjacent normal cord. (C) An infant with a large thoracolumbar myelomeningocele and a kyphotic deformity at the junction of the thoracic and lumbar spines.



Anatomical Reconstruction

The “different types” of myelomeningocele are best understood in terms of an archetypal anatomical deformity and variation about that archetype. The basic deformity consists of an open neural placode, which represents the embryologic form of the caudal end of the spinal cord prior to neurulation (Fig. 15-5A—15-5C). A narrow groove passes down the placode in the midline. This represents the primitive ventral sulcus, and it is directly continuous with the central canal of the closed spinal cord above (and occasionally below) the neural placode. Cerebrospinal fluid passes down the central canal of the spinal cord and discharges from a small pit at the upper end of the placode to bathe the external surface of the exposed neural tissue. This fluid does not indicate rupture of subarachnoid space ventral to the myelomeningocele. The size of the sac on the baby’s back at the time of birth is dependent upon the amount of spinal fluid that is collected ventral to the neural placode. The majority of lesions will be flush with the baby’s back. A smaller number of placodes are raised far above the surface of the back by marked expansion of the subarachnoid space. Generally, however, both types are grouped under the myelomeningocele heading. In most cases, the spinal cord rostral to the neural placode is normal in gross form. Anomalies such as split cord and absence of a segment of the spinal cord can exist above the neural placode, however. Concurrent arteriovenous malformations and lipomas of the spinal cord are also possible. Occasionally, the neural placode is in a totally disorganized state. In these cases, the neural placode appears to have undergone intrauterine infarction so that portions of it are severely dysplastic and reduced to a simple membrane. This would support the concept that myelomeningocele is indeed a progressive intrauterine disease.

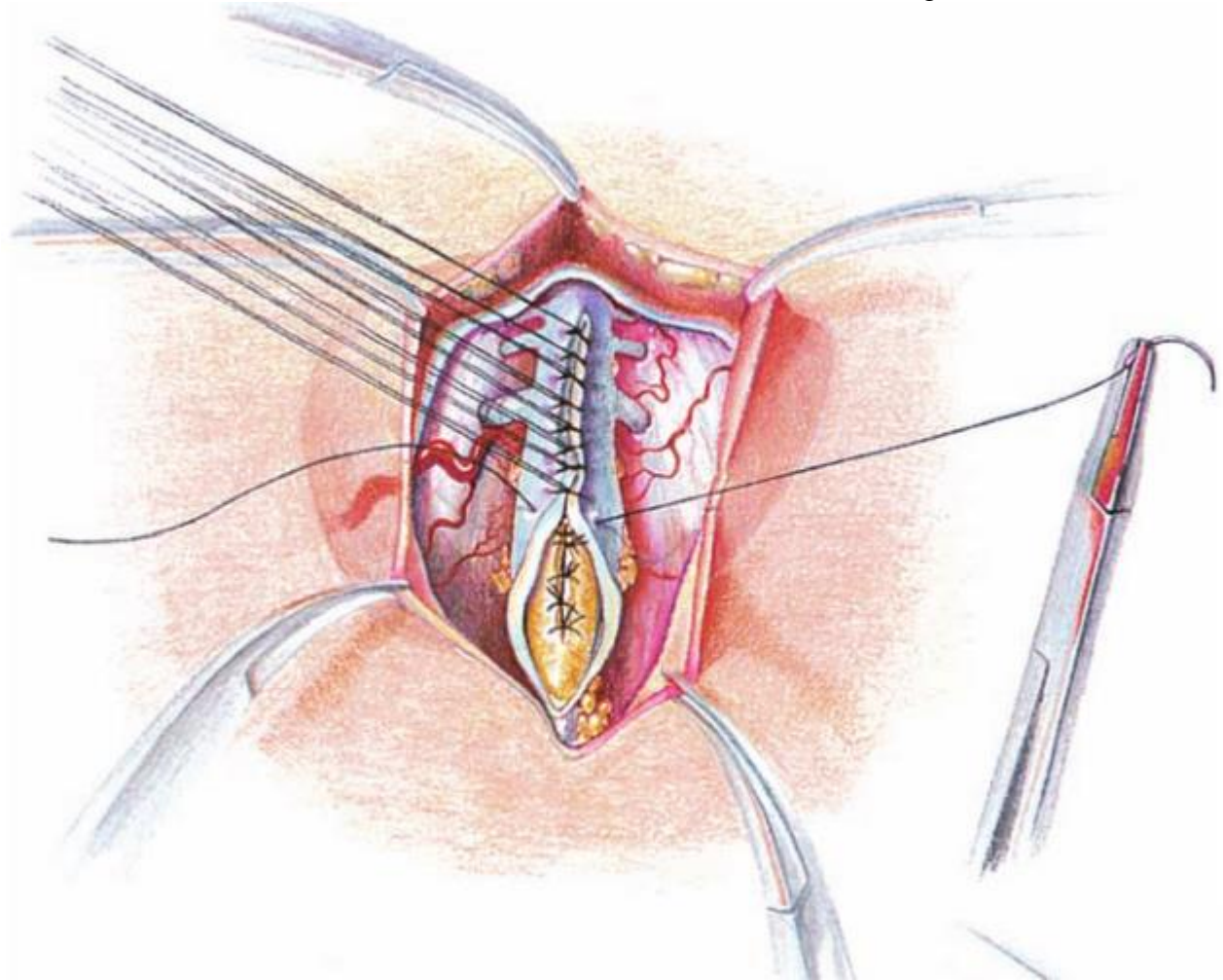
The functional motor and sensory levels are related to but not always consistent with the anatomical level of the lesion. Often, function is preserved below the anatomical segments involved. Again, functional asymmetry occurs and should raise the question of an additional lesion such as a split cord. The normal anatomical structures derived from the neural tube are almost always present but are open in the midsagittal plane (unneurulated), and the dorsal roots are therefore displaced laterally. Because the neural crest is usually involved in the defective neurulation, the dorsal roots are often attenuated or absent. The exposed neural surface is the ependymal surface of the neural placode and is continuous with the central canal of the spinal cord rostrally. The lateral edges of the neural tissue are developmentally the alar (sensory) plate with the dorsal root entry zones at the lateral edge. The medial portion of the placode is basal (motor) plate and contains the anterior motor horns. Ventral to the placode along either side of the midline the motor roots exit from the placode. The sensory roots enter the cord at the periphery of the placode lateral to the motor roots. The dorsal root ganglions are usually reduced or absent, so the dorsal roots are small or absent. The ventral surface of the placode is covered with pia-arachnoid, which is directly contiguous with the arachnoid membrane of the sac. The sac usually encloses an intact subarachnoid space. An understanding of this anatomy is essential to reconstituting the spinal cord and its coverings.

Dissection of the myelomeningocele begins at the junction of the abnormal covering epithelium and the normal skin near the rostral end of the placode (Figs. 15–2A and 15–2B). This junction should be incised around the entire circumference of the myelomeningocele. Once this has been completed, the dissection is carried toward the neural placode. Dividing the epithelial junction from the neural tissue requires care because on the one hand, this is the region where dorsal roots and segmental vasculature enter the neural placode, and on the other hand, any residual skin elements may grow to become inclusive epidermoid tumors (Figs. 15–3A and 15–3B). The use of magnification enables one to dissect free any nerve roots that are adherent to surrounding tissues. When this has been completed, the neural tissue may float freely on an arachnoid enclosed sac of cerebrospinal fluid. Once the neural tissue is freed, every attempt should be made during anatomical reconstruction of the spinal cord to prevent later retethering of the placode. Although pial-to-pial closure of the placode into a tubular structure has not completely prevented retethering, it may reduce the incidence of this complication (Figs. 15–1B and 15–1C). More importantly, it makes untethering of the spinal cord later considerably easier to perform. The reapproximated neural tube is usually adherent only along the dorsal closure line (Figs. 15–7A—15–7D). In contrast, leaving the placode open allows the unclosed neural tissue to become densely adherent over the entire exposed ependymal area of the placode; the laterally displaced dorsal roots are usually caught in the scar and require tedious dissection to free them (Figs. 15–7E—15–7G). The central canal is reconstructed throughout its entire length so that the neural placode becomes a tube. Closing the neural placode into a neural tube and folding the arachnoid sac around the tube encloses the cord within an envelope of cerebrospinal fluid. By suspending the closed neural tube in an intact cerebrospinal fluid compartment, we hope to decrease the possibility of scarring and adherent neural elements that might later result in tethering of the spinal cord as the child grows.

Magnetic resonance imaging has become the imaging modality of choice, and a postoperative study can demonstrate the reconstructed neural tube (Figs. 15–8A—15–8D), but not as clearly as a contrast computed tomography myelogram. The open edges of the dura mater attach to the underside of the skin lateral to open skin edge. To ensure adequate dura mater for closure, the most lateral extent of the dura must be found and detached at that point (Fig. 15–1B). No dissection in the epidural space ventral to the neural tissue should be attempted (Fig. 15–1D). The dura is usually very thin under the spinal cord, and if torn is difficult to repair. During dural closure, the neural tissue may become included in the suture. Therefore, care should be taken to avoid this preventable complication. Once the dura mater is free, it is closed in the midline. This layer should be closed “watertight” if possible. We prefer a running locked nonabsorbable suture of 5 or 7–0 (Fig. 15–6A). The dural closure must not constrict the underlying neural elements or interfere with the blood supply to the reconstructed cord. Potential recovery may be lost to ischemia or infarction if dural or fascial coverings constrict the underlying tissues. Mobilization and midline approximation of lateral paraspinal muscle fascia are

optional and not essential (Fig. 15– 6B). It may not be easy to obtain significant lateral tissues. Muscle closure at the lumbosacral level is often difficult because the fascia of sacrum and ileum are densely adherent to the bones. Thoracic and upper lumbar myelomeningoceles can be difficult to repair if associated with a kyphotic deformity (Fig. 15–5C). To allow skin closure without compression may require a kyphectomy. It has the benefits of making the closure easier, giving the patient a flat back, and converting muscles from flexors of the spine to extensors, which prevents progression of the deformity. Closure of the skin should be performed in the midsagittal plane whenever possible. Future untetherings or orthopedic procedures will be facilitated by a simple midline closure (Fig. 15–6C). Mobilization of the skin should also include the subcutaneous fat layer because the vascular supply to the skin comes through this layer. Blunt dissection in the plane between the muscle and subcutaneous fat is the best method to preserve the blood supply (Fig. 15–6B). Some consideration of cosmesis should be given here, but this is not a major consideration if it poses any added stress to neural tissue.

Figure 15–6 (A) A drawing shows the suturing of the dura. We now prefer a running locked suture rather than the interrupted suture. (B) Dissection in the plane between the subcutaneous fat and the muscle fascia allows the skin to be mobilized to aid closure. (C) A drawing shows closure of the skin.



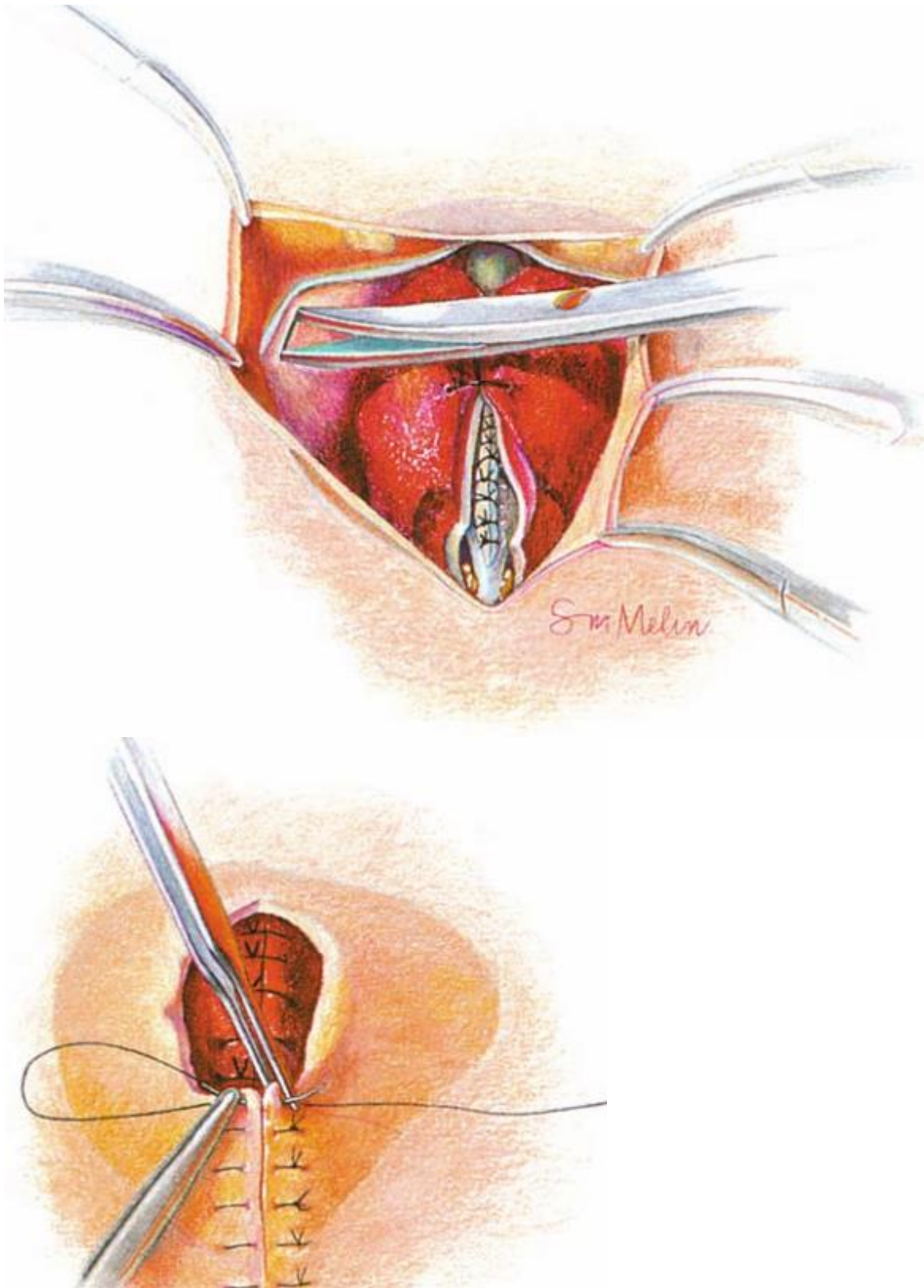


Figure 15-7 (A-D) A contrast computed tomography (CT) myelogram shows a reconstructed neural tube that has retethered along the suture line to the overlying dural closure. (F-G) Contrast CT myelograms showing neural placodes adherent to the overlying dural closure. (H) A contrast CT myelogram showing a free-floating reconstructed neural tube.

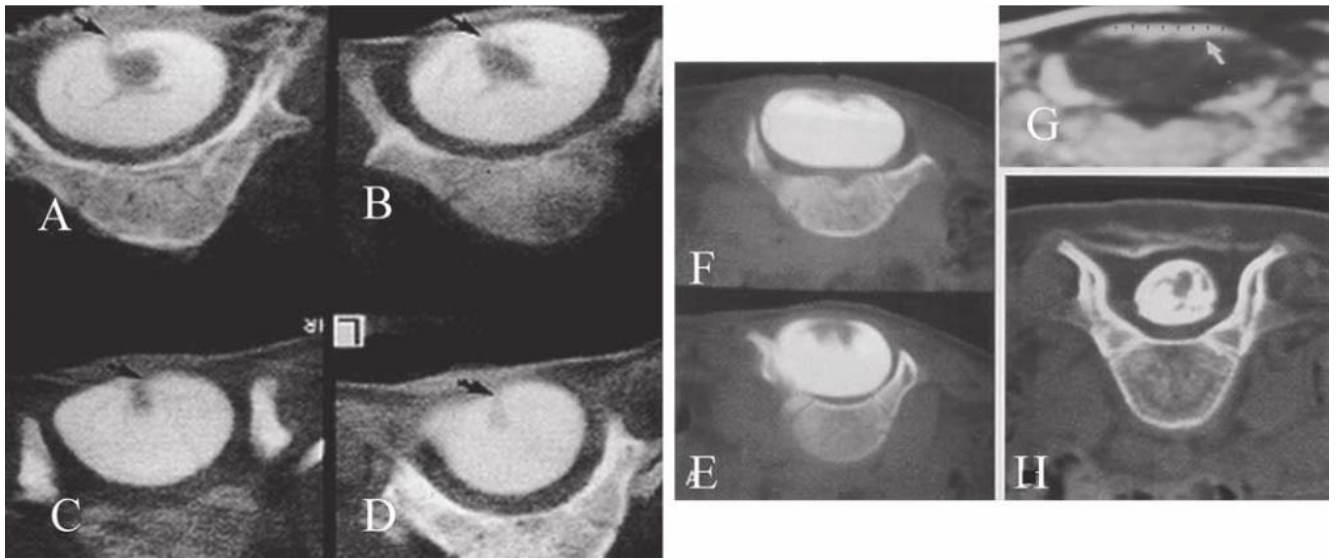
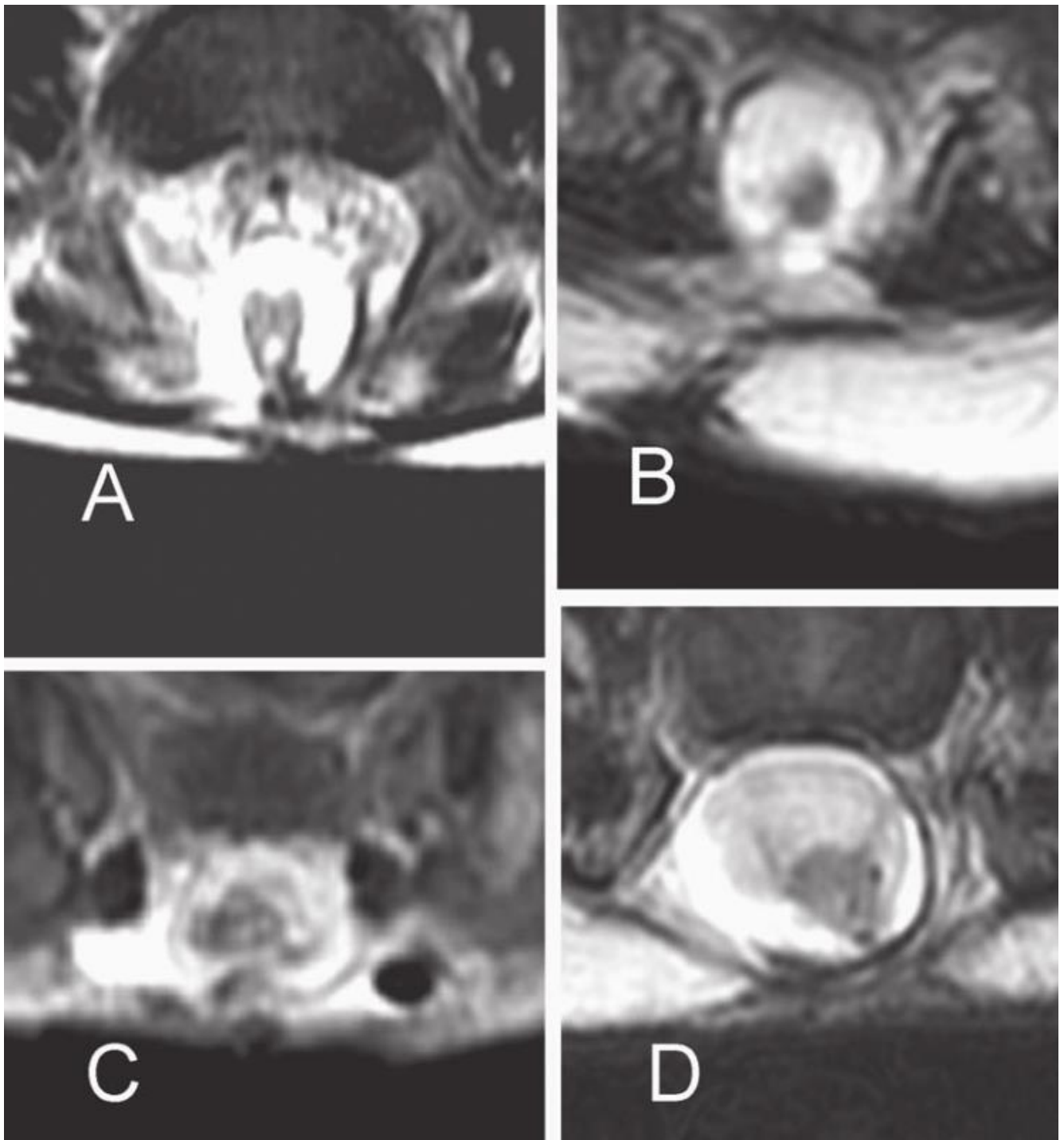


Figure 15–8 (A–D) Four neonates with myelomeningoceles. Postoperative magnetic resonance imaging axial T2 scans show the reconstructed neural tubes .



Hydrocephalus

The timing of shunt placement is a matter of some debate. Approximately 20 to 30% of patients with myelomeningoceles do not need a shunt, and therefore we have advocated delaying a shunt procedure until well after the initial closure. In the presence of obvious severe hydrocephalus at birth, however, it would seem to make little sense to delay and subject the patient to a second anesthetic. Placement of the shunt at the time of initial closure in these cases is safe and reduces the risk of cerebrospinal fluid leakage or wound breakdown postoperatively.

Postoperative Management

Management of the Closure Site

A variety of techniques have been employed to protect the closure site postoperatively, including placing the patient prone or suspending the patient from a sling. These maneuvers are of little value. We simply place the patient in a bassinet postoperatively and allow him or her to be held in the mother's arms without restrictions. We have not encountered any significant problems using this regimen.

Care of the Patient

At present, the patient is given intravenous fluids with 10% dextrose for the first 24 hours and then is given to the mother for feeding. Daily inspection of the closure is recommended for signs of infection, separation of the skin edges, or leakage of cerebrospinal fluid. During the hospital stay, instruction is given to the parents to prepare them for caring for the baby in the home. This is the ideal time for the parents to become familiar with the team that will assist them in the care of the baby as an outpatient. It is essential that the parents gain confidence in their own ability to care for the baby and are aware that the team is always available for support.

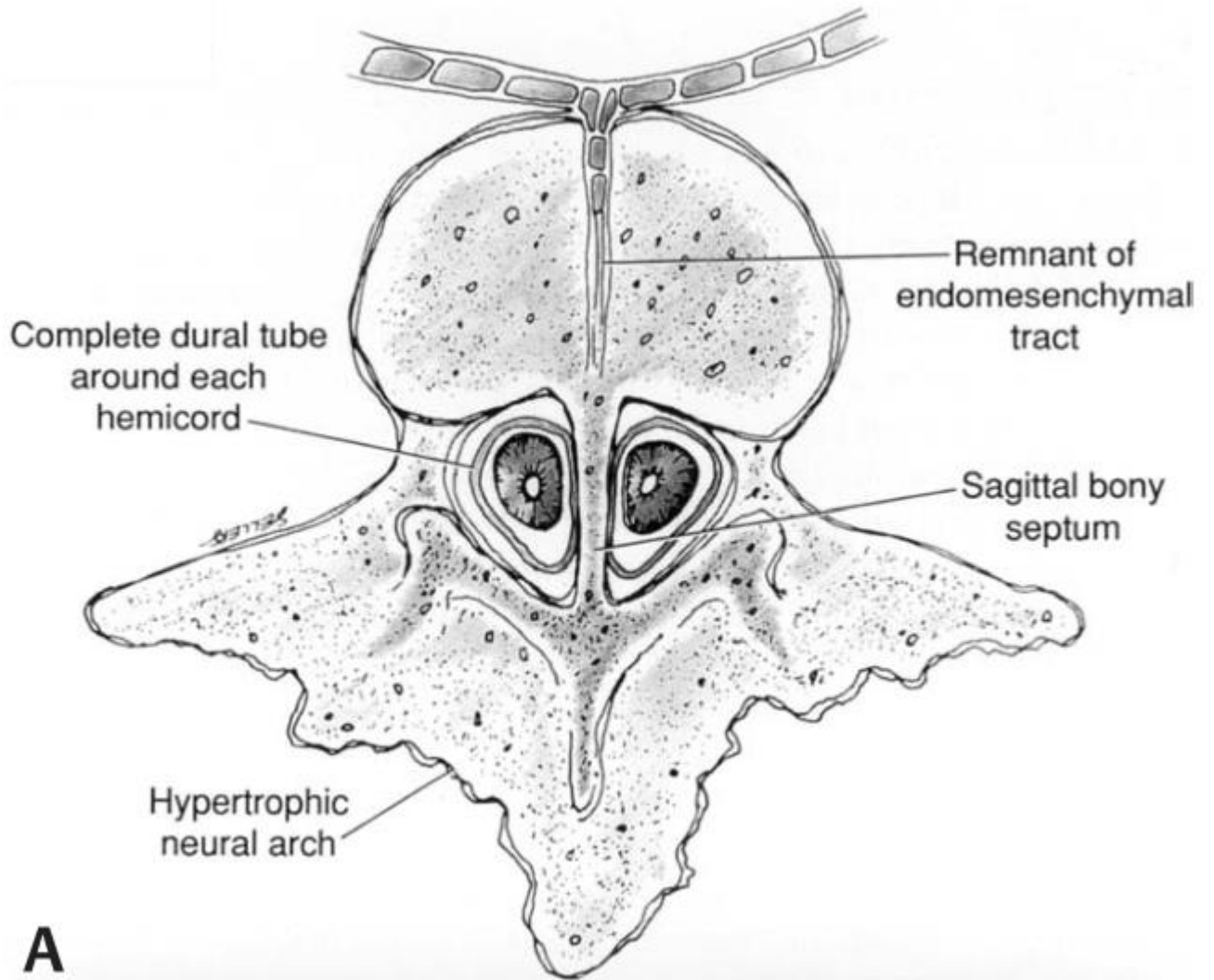
SPLIT CORD MALFORMATIONS

ETIOPATHOPHYSIOLOGY

Recently, Pang et al described a unified theory of embryogenesis that holds that all double spinal cord malformations arise from a common embryogenetic error: a failure of prospective notochordal cells to achieve midline integration following their ingress through Hensen's node, allowing the simultaneously lengthening ectoderm and endoderm to form adhesions across this central fenestration in the notochord. The subsequent incorporation of multipotential mesoderm (mesenchyme) into this adhesion constitutes the endomesenchymal tract, which not only permanently bisects the notochord but also forces each overlying hemineural plate to neurulate against its own heminotochord in a severely compromised manner. The basic malformation, therefore, consists of two heminotochords and two hemineural plates separated by a midline tract containing ectoderm, mesenchyme, and endoderm. Further evolution of this basic form into the full-grown malformation depends on four factors: (1) the ability of the heminotochords and hemicords to achieve midline healing; (2) the interaction between each heminotochord and hemineural plate during neurulation; (3) the persistence of the endomesenchymal tract; and (4) the developmental fates of the three germ elements. Variable healing of the notochord results in the spectrum of associated vertebral anomalies ranging from bifid vertebral bodies ("butterfly" vertebrae), to widened bodies with midline tracts, to plain widened bodies. Partial healing of the hemineural plates results in the so-called cleft cord, a single cord with double central canals and a deeply indented midsection. Abnormal neurulation of the hemineural plate, hinged to the cutaneous ectoderm on only one side and receiving mechanical and inductive influence from only one (lateral) set of paraxial mesoderm, results in a misshapened hemicord with unpredictable internal cytoarchitecture varying from four healthy gray horns to a single rudimentary gray column. Complete inability of one or both hemineural plates to neurulate, perhaps due to an untenable relationship with the heminotochord(s), results in an associated hemimyelocoele or myelomeningocele, respectively. Persistence of the dorsal (ectodermal) portion of the endomesenchymal tract causes a patent dermal sinus tract to maintain continuity with the midline septum; the tract sometimes encysts to form a dermoid between the hemicords. Persistence of the ventral (endodermal) portion of the mesenchymal tract and its connection with the embryonic gut explains the associations of split spinal cords with intestinal duplication and malrotation. Finally, and in some respects most importantly, the developmental fates of the germ elements within the midline endomesenchymal tract determine the state of the meningeal investment of the hemicords, the nature of the mature septum, the presence of ganglion cells and nerve roots bridging between a hemicord and the septum, the tethering of the hemicords to the dorsal dura by fibroneurovascular bands (myelomeningocele manqué), and the rare occurrence of an enterogenous (neurenteric) cyst in the midline cleft. Based on their proposed theory, Pang et al suggested replacing the terms diastatomyelia and diplomyelia (which would imply different embryogenetic mechanisms for the two types of double cord malformations) with the nomenclature split cord malformation (SCM). They introduced a new classification of double spinal cords founded on two easily identifiable features: the dural arrangements of the hemicords and the nature of the midline septum. If specialized mesodermal cells destined to form dura and neural arch (from the meninx primitiva), normally found in the region between the notochord and neural tube, are incorporated into the endomesenchymal tract, a median dural layer forms next to the medial aspect of the hemicord and joins the dura that normally grows

around the lateral aspect of the hemicord to complete a separate dural tube for each hemicord. Additionally, in accordance with their sclerogenic function, the meninx primitiva cells within the endomesenchymal tract facing away from the hemicords also form a midline bone spur between the two median dural walls, continuous with the bone of the developing vertebral centrum. This configuration, called type I SCM, therefore consists of two hemicords, each contained within its own dural tube, separated by a dura-sheathed rigid osseocartilaginous median septum. Inasmuch as the endomesenchymal tract frequently reaches the neural arches, the median bone spur bisects the spinal canal into two separate compartments. The spinal cord is transfixed solidly to the spinal canal by the bony and dural septa. The sclerogenic effect of the meninx primitiva cells when these admix with cells of the developing neural arches accounts for the often massively hypertrophic fusion of several adjacent laminae at the level of a type I SCM (Fig. 18–1). In contrast, the endomesenchymal tract in a type II SCM does not recruit meninx primitiva cells. A thin fibrous septum, texturally different from dura, will form from the “ordinary” mesenchyme in the space between the hemicords. Here also, no arachnoid, bone, or cartilage will form. Both hemicords will lie within a single arachnoid and dural tube inside a noncompartmentalized spinal canal, separated by a fibrous rather than a rigid osseocartilaginous median septum (Fig. 18–2). However, this fibrous septum is always adherent to the medial aspect of the hemicords, and by virtue of its firm peripheral attachment to the ventral and/or dorsal dural wall, it is as real a tethering lesion as the bone spur of a type I SCM. The determining features of this classification do not overlap between the two types; there is never a type I SCM with dual dural sacs that does not have a rigid midline bone or cartilage within the median dural cleft, nor is there ever a type II SCM with a single dural sac but a naked piece of bone or cartilage unlined by dura. Typing is thus easily made with high-quality neuroimaging studies, an important preoperative step because the surgical techniques are different for each of the two types of SCM. The other commonly associated features of SCM such as paramedian nerve roots, myelomeningocele manqué, dermoids, dermal sinus tracts, centromedian blood vessels, thickened filums, and intestinal anomalies occur not only in both types of SCM but also in relatively similar frequencies.

Figure 18–1 Type I SCM. (A) The typical features are depicted. (B) Axial view from computed tomographic myelogram showing a sagittal bony septum (BS), double dural sac, and hypertrophic neural arches



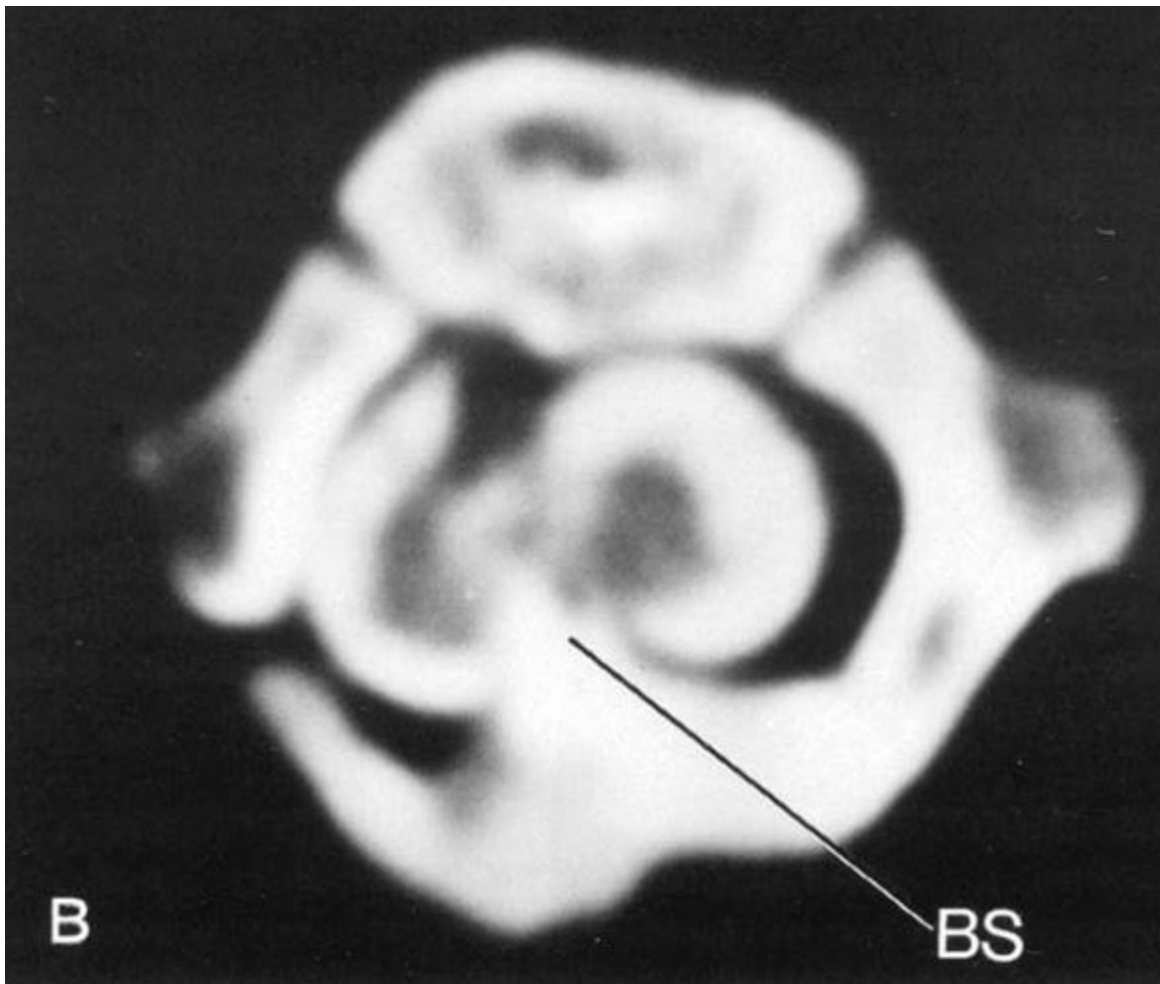
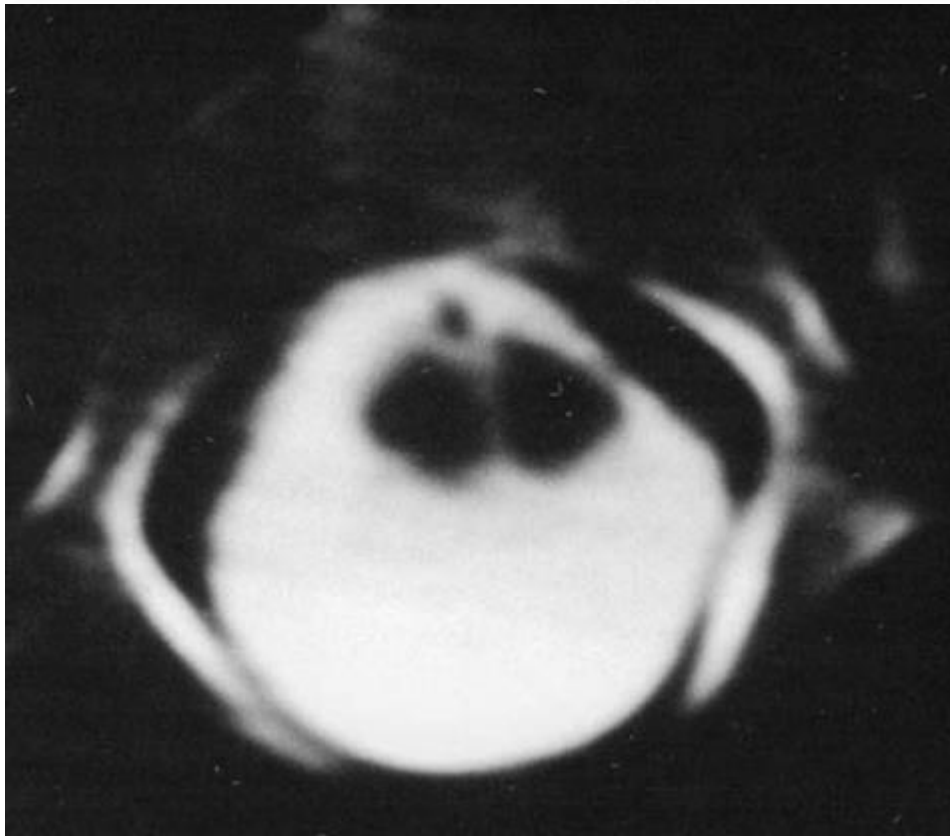
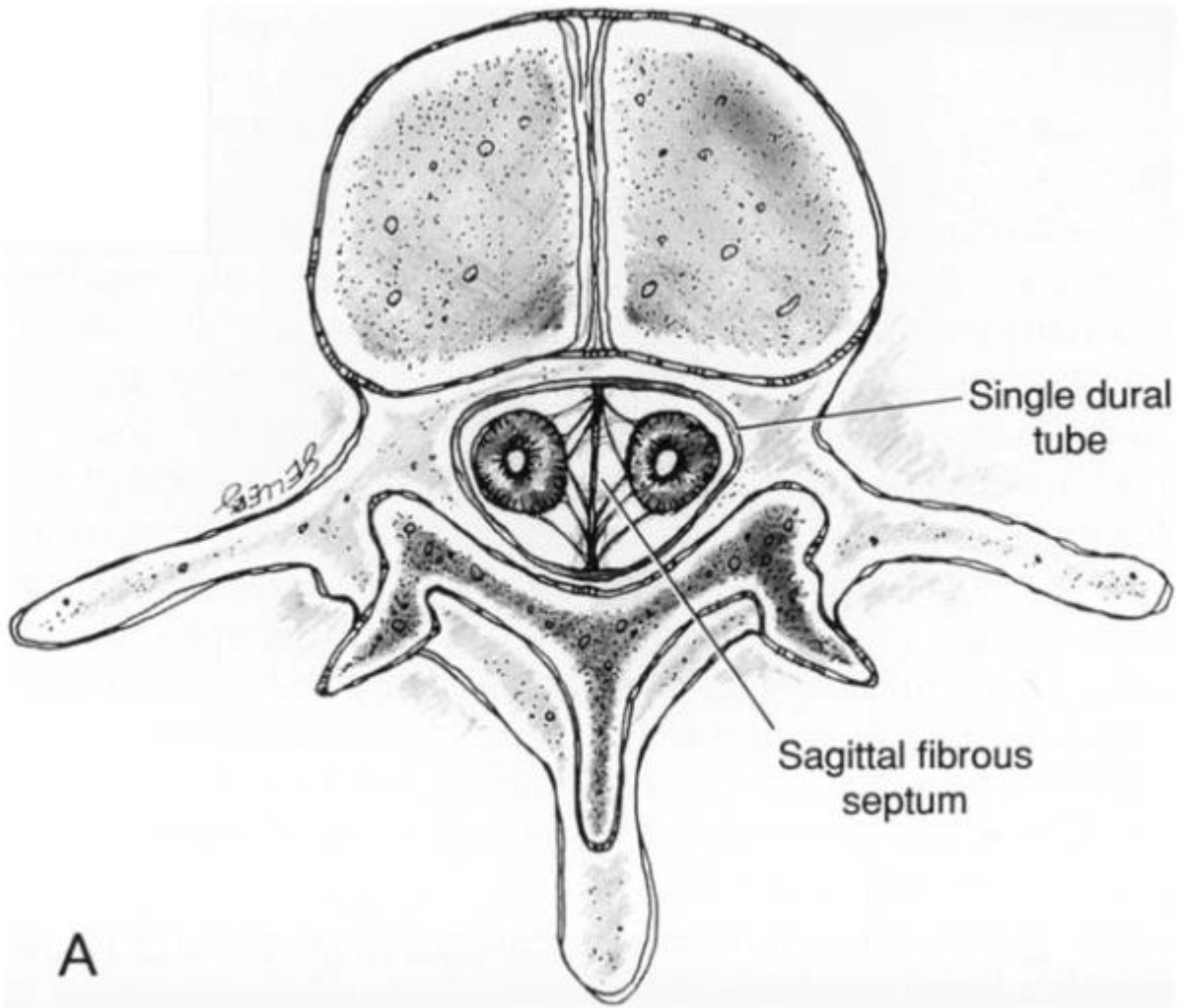


Figure 18–2 Type II SCM. (A) The typical features are depicted. (B) A midline filling defect just ventral to the hemicords, representing an axial view from a computed tomographic myelogram showing a single dural sac and a small ventral fibrous septum.



INDICATIONS FOR SURGERY

- **children** - both types of SCM are tethering lesions - indication per se for surgical release (neurological deterioration is very common and lost function is seldom reclaimable).
- evidence to support prophylactic surgery in asymptomatic **adults** is much less convincing*, and most adults have been operated on for symptoms and/or progressive deficits.
 - *no available data on natural history but it is known that neurological deterioration can be precipitous after a fall or strenuous exercise.
 - a) asymptomatic adults who are healthy and lead a physically vigorous life → operate.
 - b) old or infirm, sedentary lifestyle → conservative.

PREOPERATIVE

Preoperative Neuroimaging Studies

MRI - excellent screening test.

Computed tomographic myelography - “surgical roadmap” for all SCMs.

Intraoperative Neurophysiological Monitoring

Real-time intraoperative somatosensory evoked potentials (SEPs) are measured on all patients using standard needle electrodes overlying the common peroneal, posterior tibial, and median nerves. For monitoring the lower sacral sensory nerves and the S-2 to S-4 segments, pudendal SEPs are also obtained using pairs of disk or needle electrodes on either side of the penis in the male, and on the preclitoral skin and labia majora in the female. Occasionally, the lower sacral motor roots and the ventral conus segments need to be evaluated separately from the corresponding sensory pathways; for this, external urethral sphincter electromyography and external anal sphincter manometry using an anal balloon are also used during surgery. The latter techniques are especially useful to distinguish functioning lower sacral roots from taut fibrous bands that tether the conus.

OPERATIVE PROCEDURE

- operation aims to relieve the cord of the tethering effect by removing the median septum and all other associated bands, dermoids, lipomas, and enterogenous cysts that might be attaching or otherwise anchoring the hemicords to the surrounding dura.
- unlike obvious bony dural septum in type I lesion, thin fibrous septum in type II SCM may not show up on preoperative neuroimaging studies - this should not deter an exploration, because in every case of type II SCM the author has explored, a taut fibrous or fibrovascular septum has been found to tether the hemicords.
- most *SCMs located in low thoracic or lumbosacral region* have at least one associated lesion tethering tip of conus, which must also be removed during same procedure.

Patient Positioning

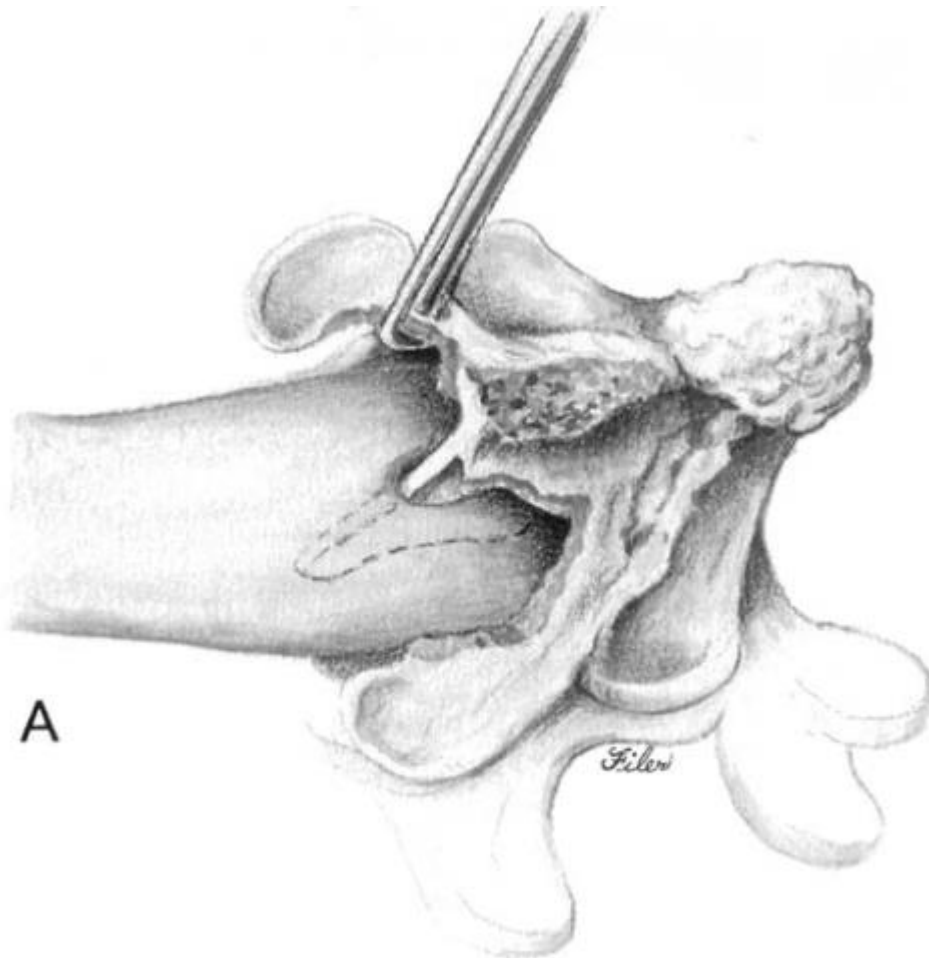
- prone position with parallel chest rolls / Wilson frame.
- abdomen must hang freely between rolls to minimize venous bleeding.

TYPE I SCM

- midline incision is made to span at least two laminar levels above and two below laminae bearing septum.
- bony septum is always extradural, being completely surrounded and excluded from CSF by medial walls of double dural tubes - medial dural walls form complete dural sleeve for bone in sagittal midline.

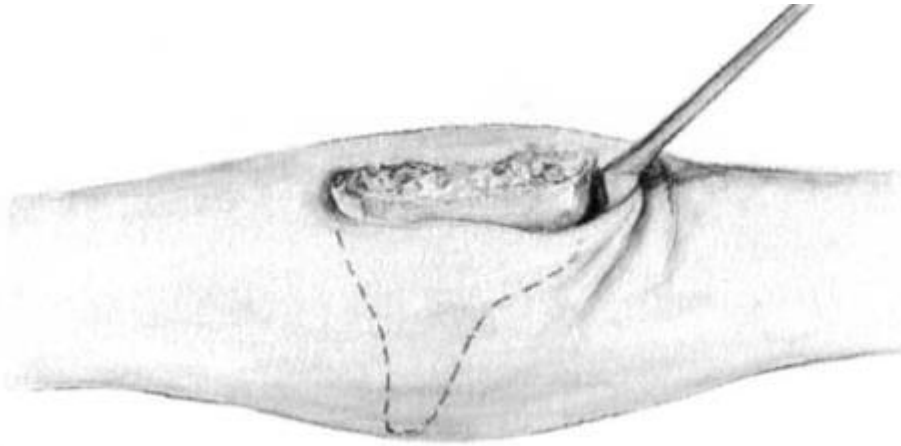
- septum is frequently fused with, and thus hidden under neural arches so that it is not immediately visible after subperiosteal exposure of posterior bony structures.
 - noting peculiar bony anatomy of adjacent neural arches such as bind state, eccentric spinous processes, exostoses, and abnormal fusion helps to guide surgeon to right level.
 - another useful hint is that septum is often located where spinal canal is widest, or where neural arches and spinous processes are hypertrophic and fused with adjacent laminae into knobby mass.
- optional - extent of laminectomy should include at least one level rostral and one caudal to septum-bearing laminae.
- septum-bearing hypertrophic lamina is carefully rongeur'd away piecemeal around attachment of septum until only a small island of lamina is left attached to dorsal end of septum:

Lamina is removed around dorsal “stump” of septum where it is attached to ventral surface of hypertrophic neural arches:



- this affords circumferential view of bone spur still within its dural sleeve so that its dural attachment can be safely dissected off bone deep within cleft.
- it must be understood that once dorsal support of septum (by lamina) is eliminated, septum is no longer anchored rigidly at both ends and might be pushed from side to side depending on its ventral anchorage - excessive lateral movement of septum may injure subjacent hemicords!!!
- Woodson dental elevator with a thin, angulated, sharp edge is well suited to peel off the dura with minimal lateral “wedging” motions:

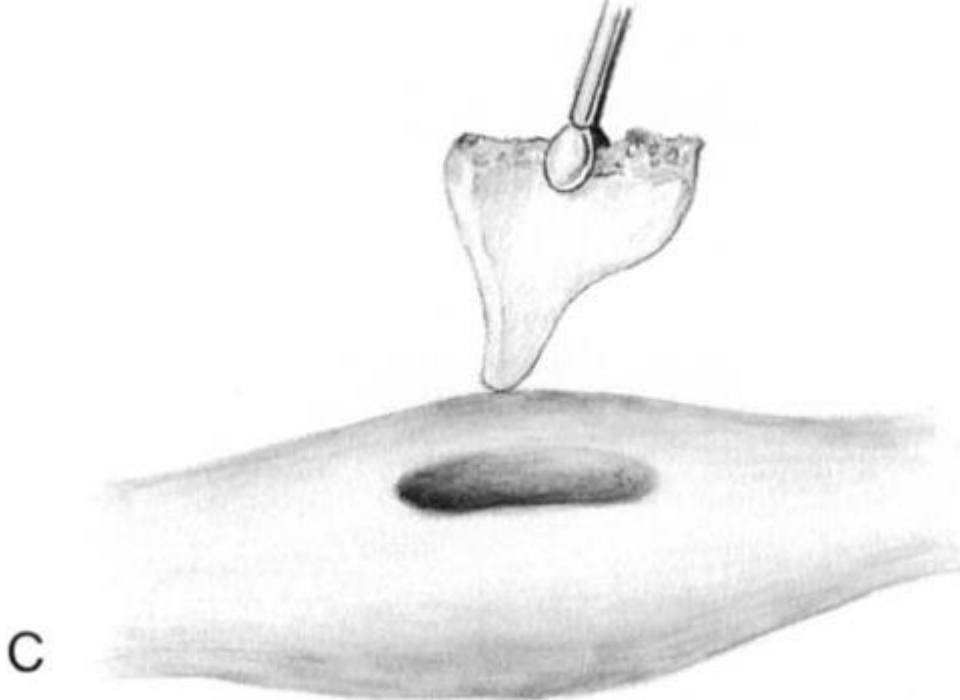
Subperiosteal separation of median dural sleeve from bony septum with small dental elevator:



B

- in majority of cases, broader attachment of septum is dorsal; its ventral junction with vertebral body is usually narrow or even fibrocartilaginous rather than bony, which makes it easy to avulse septum from its deep attachment:

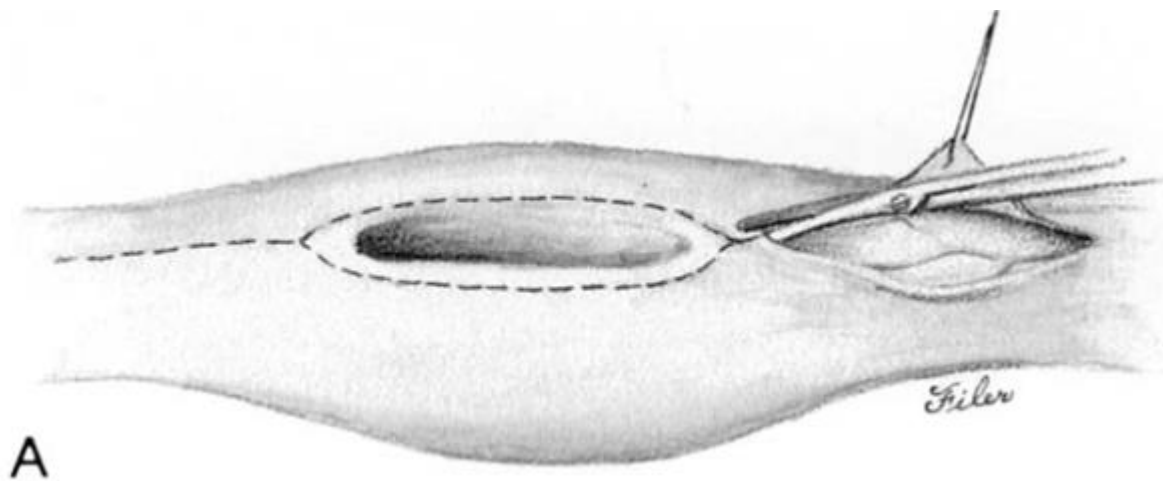
Bony septum is avulsed from its ventral attachment, which is often slender.



C

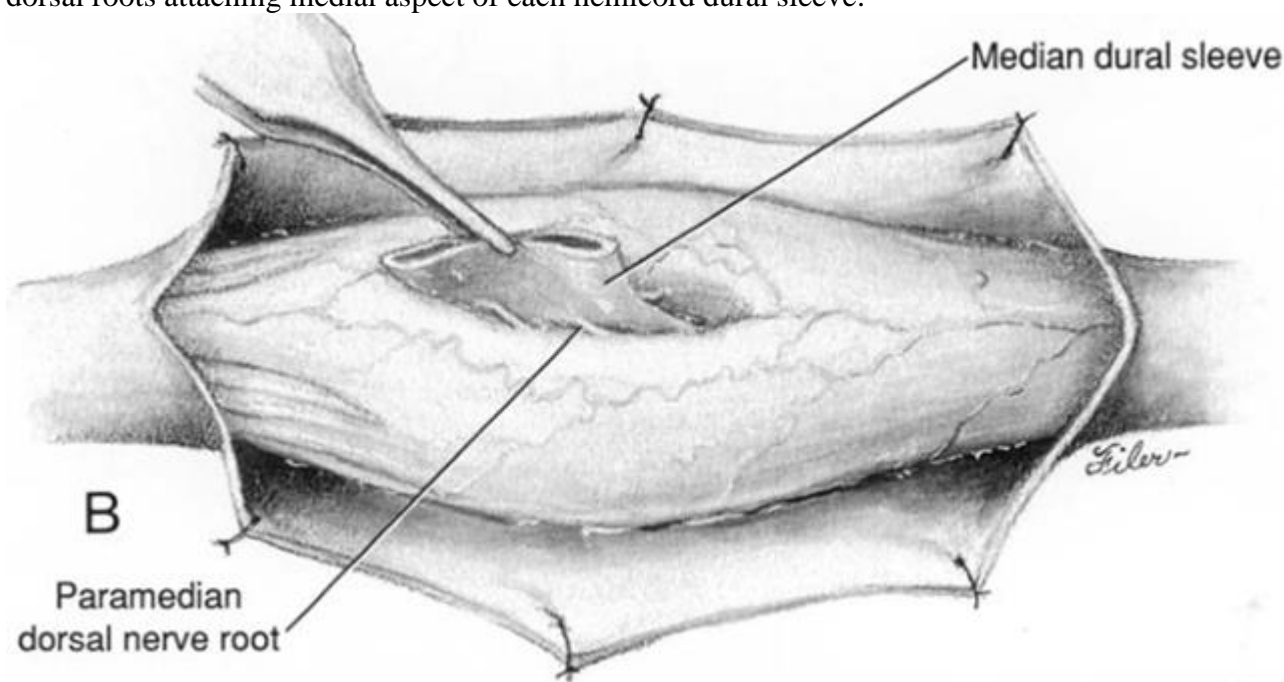
- if ventral attachment happens to be broad and bony, ventral stub of septum may be removed by small pituitary rongeur or microdrill; time is well spent during this part of operation because complete extradural removal of bone spur greatly facilitates later resection of dural sleeve.
- septum always encloses one or more prominent **central blood vessels**, which can give rise to brisk bleeding if torn; H: quick plunge with small piece of bone wax on cotton patty deep into cleft should handle bleeding adequately.
- dura is opened on both sides of the now-empty dural cleft to isolate sagittal dural sleeve.

Dural opening is made from rostral to caudal along medial edge of median dural sleeve (*dashed line*) with Potts scissors.



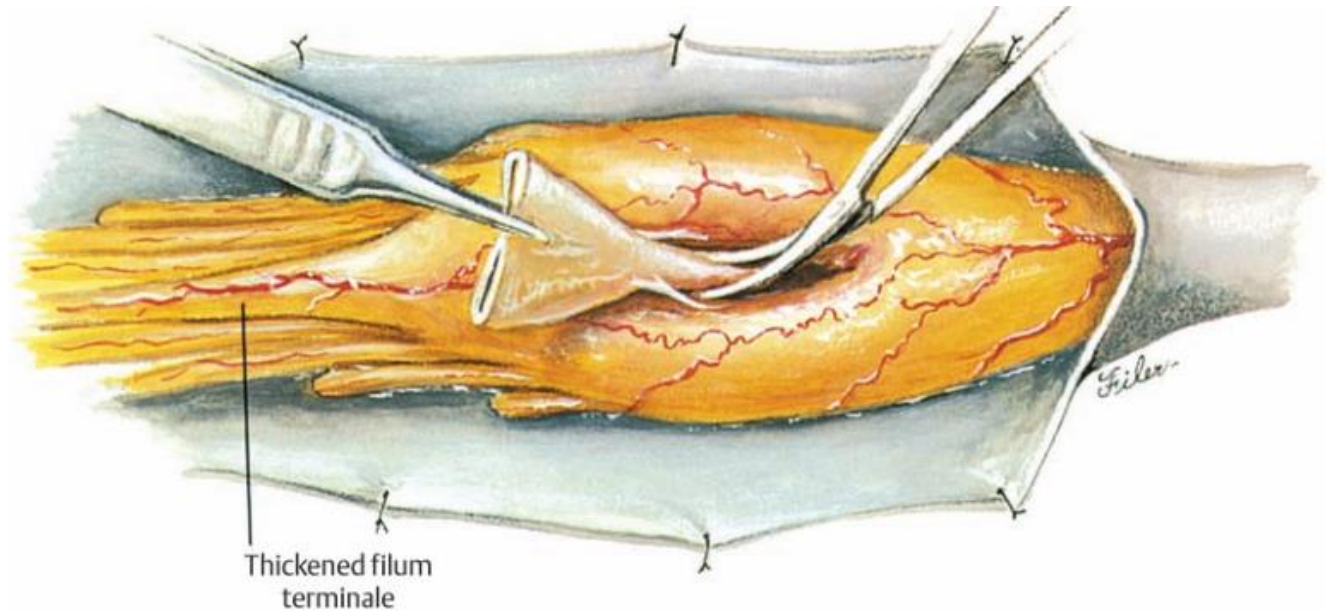
- medial aspect of each hemicord is often tightly adherent to dural sleeve by fibrous bands that must be cut.

After lateral retraction of dura, median dural sleeve is isolated except ventrally. Note paramedian dorsal roots attaching medial aspect of each hemicord dural sleeve:



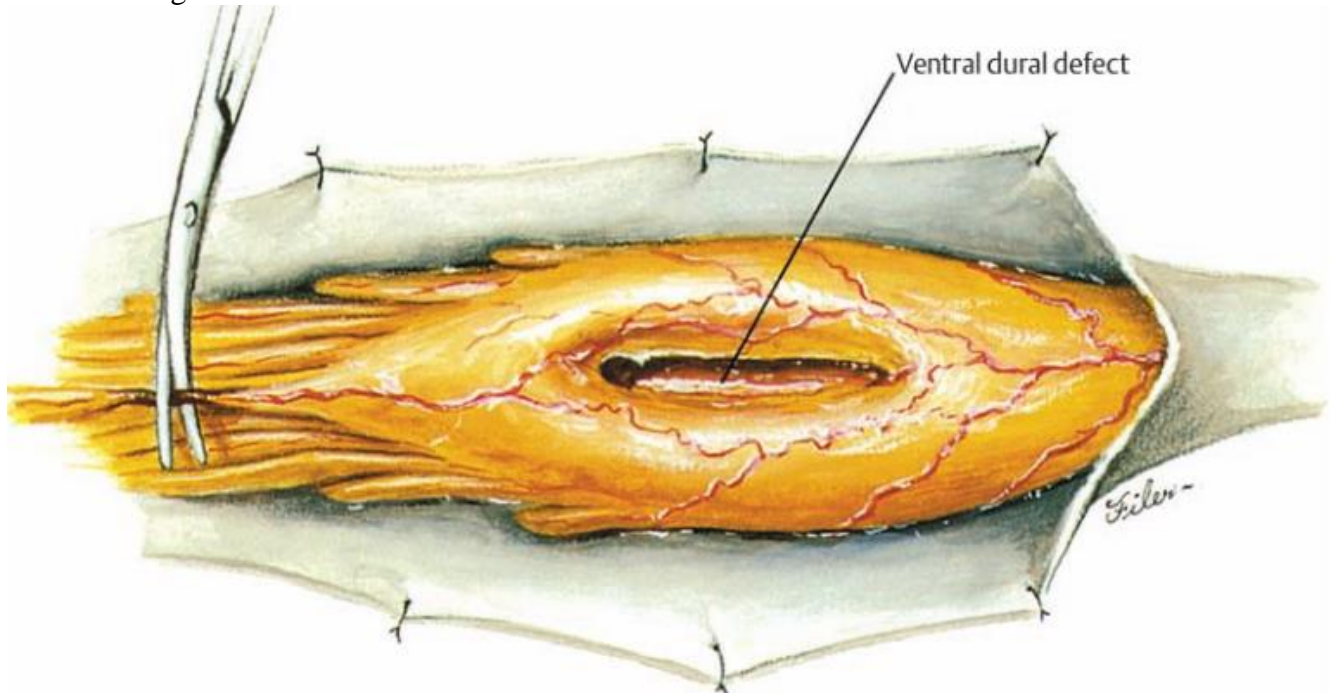
- **paramedian dorsal nerve roots** stretch from dorsomedial aspect of hemicords to end blindly within median dural sleeve; these are nonfunctional and must be cut prior to resection of dural sleeve.
- dural sleeve is always wedged against the caudal reunion site of hemicords, and any “free” part of hemicords not closely apposed to medial mesenchymal structures would be rostral to septum; in widely split cord, this free area is considerable and constitutes a safe area to begin resection of dural sleeve.
- proceeding caudally from rostral margin of sleeve where hemicords are least adherent, surgeon bipolar cauterizes ventral attachment of sleeve to seal central vessels and then cuts it flush with ventral dural wall:

Dural sleeve is resected flush with ventral dural surface, proceeding from rostral “free part” to caudal end. Note thickened filum terminale:



- not having enclosed bone spur greatly simplifies deep resection of sleeve.
- most hazardous part of this undertaking is at caudal end where hemicords reunite and hug tightly against caudal margin of sleeve, where taut pressure on cord is readily felt and where slight upward migration of cord might sometimes be seen right after whole sleeve has been resected.
- complete resection of dural sleeve exposes ventral extradural space in sagittal midline.

Ventral dural defect is left after complete resection of dural sleeve flush with vertebral body. Note sectioning of thickened filum after it has been cauterized:



- if prominent bony stump is left from extradural removal of septum, it can be trimmed down easily with small ophthalmic / Lampard rongeur until it is no longer in contact with ventral surface of hemicords.
- **closure of anterior dural defect is unnecessary** because of abundant adhesions of ventral dura to posterior longitudinal ligament that would naturally prevent CSF leakage.
N.B. anterior dural closure may actually be undesirable because anterior suture line potentially increases likelihood of anterior cord tethering.
- **posterior dural closure** ultimately converts double dural tubes into single sac.

- occasionally, fibroneurovascular stalk containing paramedian dorsal nerve roots, fibrous bands, and large blood vessels tautly tethers hemicords to dorsal dura (**MYELOMENINGOCELE MANQUÉ**); these bands always penetrate dura at level more caudal than their origin from hemicords, and they often form exuberant tuft of vascular fibroadipose tissue clinging tenaciously to outer surface of dura; these bands must be cut flush with hemicords to complete untethering process.
- tuft of extradural fibroadipose tissue, which cannot be swept away with “normal” extradural fat, is clue to presence of myelomeningocele manqué underneath.

In 5-10% of type I SCMs, bony septum is oblique - must be recognized through preoperative imaging as signature of heightened risk, so that surgeon can make every effort to avoid jarring delicate minor hemicord while dealing with blind underside of oblique bone spur.

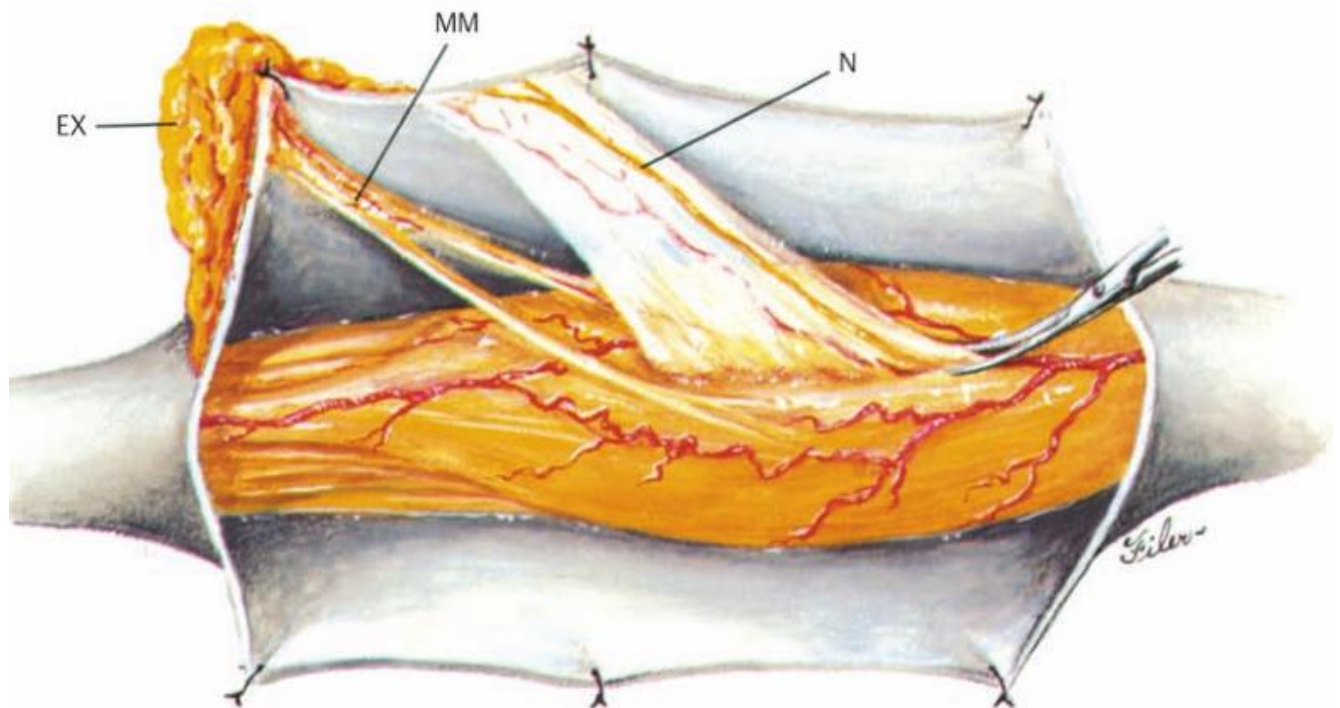
- it arises from midline posterior surface of vertebral body but then immediately reaches diagonally across spinal canal to divide it into two asymmetrical compartments.
- without exception, hemicord contained within larger compartment (*major hemicord*) is much larger than hemicord in smaller compartment (*minor hemicord*), sometimes by a factor of 2 or 3.
- larger hemicord frequently possesses one set of lateral ventral roots but two sets of dorsal roots, whereas smaller hemicord gives off only single set of ventral roots.
- exposure of minor hemicord is hampered because it is partly sheltered by overhanging oblique bone spur as well as being ventrally rotated away from surgeon's view.
- smaller hemicord is extremely delicate - can be injured inadvertently during removal of bone spur.

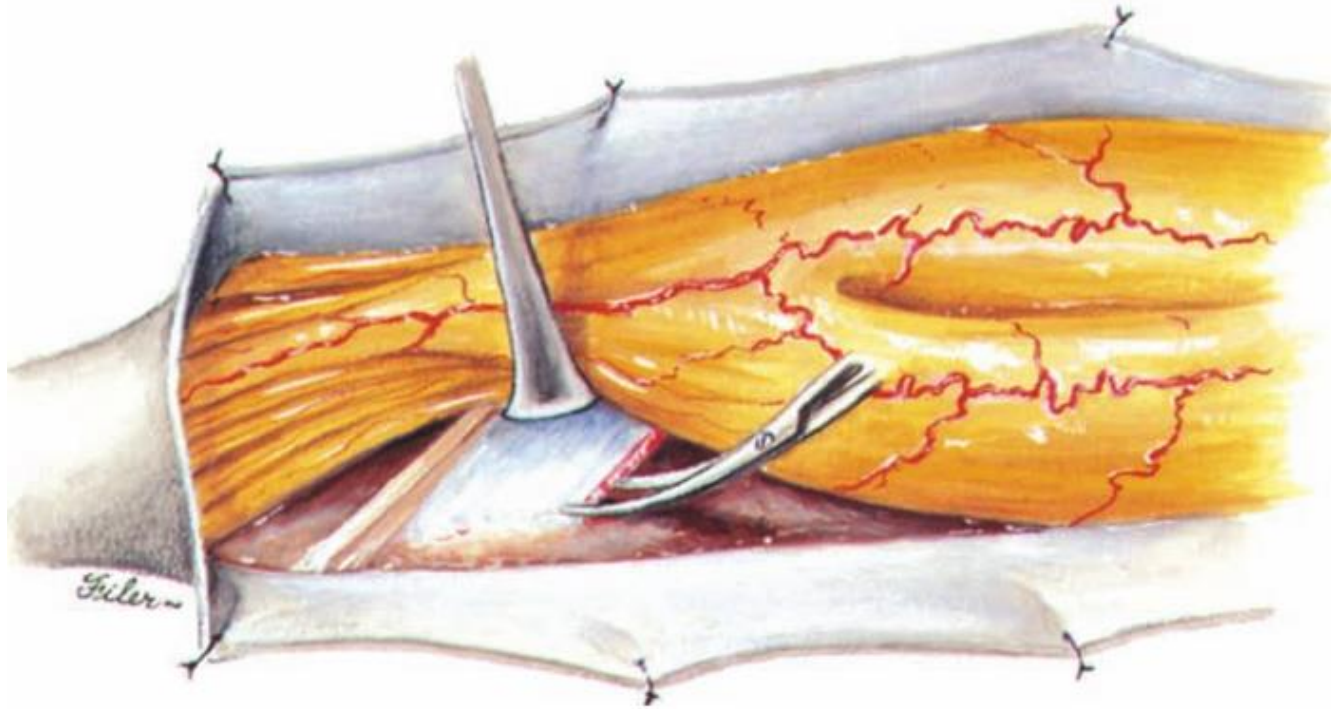
TYPE II SCM

In all cases of type II SCM, some form of fibrous (mesenchymal) septum is found within the midline cleft. The aim of surgery is to remove the tethering effect by resecting the fibrous septum and any associated bands such as those of a myelomeningocele manqué. Three patterns of such nonrigid median septa are found in type II lesions: (1) The least common is a complete fibrous septum stretching between the ventral and dorsal surfaces of the dural sac. The septum is entirely intrathecal. Except for this feature and the fact that it is nonosseous, the complete fibrous septum transfixes the hemicords to the surrounding dura in the same manner as does the type I bony septum. (2) Slightly more common is the purely ventral fibrous septum. Its intimate adherence to the ventromedial aspects of the hemicords in effect anchors the cord ventrally where the incomplete septum fuses with or penetrates the ventral dura. (3) The most prevalent kind is the purely dorsal septum that attaches the dorsomedial aspects of the hemicords to the dorsal dura. A tuft of fibrovascular tissue in the extradural space is sometimes found connected to the septum through a small defect in the dorsal dura. Hypertrophic and fused laminae, common in type I lesions, are seldom found in type II SCMs. In fact, the neural arches of type II lesions are often attenuated or even bifid. Laminectomy for these SCMs is technically easy and safe. However, except where there is a tuft of fibrovascular tissue clinging tenaciously to the dura, marking the site of a dorsal septum, the exact location and extent of the purely intradural type II fibrous septum is usually not apparent after dural exposure. This underscores the importance of pinpointing the precise location of the type II septum before laminectomy by carefully studying the bony anatomy on the CTM. A midline dural opening immediately exposes the purely dorsal septum and the dorsal portion of a complete septum, to one side of the dural incision (Fig. 18-6A). A purely ventral septum and the ventral part of a complete septum have to be sought, either between the hemicords or by gently rotating the hemicords to one side (Fig. 18-6B). Like the type I bony septa, type II fibrous septa are found near the caudal end of the split. However, the length of split in type II lesions is, by comparison, much shorter than that of the type I SCM, and, because fibrous septa are thin, the hemicords in type II SCM are apposed much closer together, with very little “free” part. “Intra-cleft” exploration in some type II lesions, therefore, should not be attempted. Fortunately, the spinal canal at the site of the split is usually wider than usual and thus will allow the

hemicords to be rolled gently to one side for ventral exploration. The shape of the type II septum varies from a broad rectangular or trapezoid sheet to a narrow triangular sail, but one invariant feature is that the point of attachment between hemicords and septum is usually rostral to the point of attachment between dura and septum (Fig. 18–6A). This is true of all three kinds of fibrous septa, giving the appearance that the fibrous septum is dragged upward by rostral movement of the cord occurring after formation of the primordium of the septum. This upward dragging converts the incomplete (ventral or dorsal) septum into a backward-pointing oblique sheet and the complete septum into a V-shaped sheet with the apex pointing rostrally. Centromedian blood vessels are always seen with the type II septa, either as a marginal artery skirting the rostral or caudal edge of the septum (Fig. 18–6B), or as a leash of parasagittal vessels loosely incorporated with the septum on either side. Very rarely, a true arteriovenous malformation is seen, with large vessels weaving in and out of the median cleft. Unless these large vessels are contributing to the tethering of the hemicords, they should be left alone. Paramedian dorsal nerve roots and myelomeningocele manqué are commonly found in type II SCMs (Fig. 18–6A). Such roots invariably course dorsally after emerging from the dorsomedial aspect of the hemicords. The puny nerve roots either end blindly in the septum or penetrate the dorsal dura with the septum. The more robust fibroneurovascular stalks of the myelomeningocele manqué always penetrate the dorsal dura at a level more caudal than their hemicord origin. These bands contribute to the tethering and must be cut flush with the cord surface. Untethering is completed by simply cauterizing the central vessels and excising the median fibrous septum. In some cases of complete septa, the fibrous and vascular elements are seen coming through a small defect in the ventral dura, presumably where the original endomesenchymal tract arose. This small defect never leaks CSF and does not need to be repaired.

Figure 18–6 Treatment of a type II SCM. (A) Shown is a type II SCM with a purely dorsal fibrous septum attached to the medial aspects of the hemicords. Note the direction of the septum, which points caudally toward the dorsal dura. The large fibroneurovascular stalk of a myelomeningocele manqué is just caudal to the midline septum. Ex = an extradural fibroadipose tuft attached to the myelomeningocele manqué; MM = myelomeningocele manqué; N = a paramedian dorsal nerve root within the septum. (B) A type II SCM with a purely ventral fibrous septum. Note the anterior marginal artery at the edge of the septum, and the direction of the septum, pointing caudally toward its ventral dural attachment.





SPECIAL CIRCUMSTANCES

Associated Distal Tethering Lesions

Associated tethering lesions not directly connected with the SCM are common. In my recently reported series of 39 cases, all SCMs located below T-7 were associated with at least one additional lesion tethering the conus, whereas the majority of SCMs above T-7 had no other cord anomaly. The most common conus lesion is a thickened filum, followed in prevalence by terminal and dorsal lipomas, dermal sinus tracts, and limited dorsal myeloschisis. Thus, the entire neuraxis must be screened carefully by preoperative neuroimaging. The untethering is not complete unless these secondary lesions are also treated (Fig. 18-5).

Composite SCMs and Multiple SCMs

A composite SCM consists of two or more SCMs of differing types occurring in tandem, with no normal cord between each individual SCM. The most common composition of a composite SCM is a type I-type II-type I combination (Fig. 18-7). Each individual component is typical of its kind: Each of the type I lesions has an extradural osseocartilaginous spur, median dural sleeve, and hypertrophic neural arches, and the middle type II lesion has a median fibrous septum within a single dural tube. The three septa, although of two different textures, are invariably continuous, suggesting that the entire lesion results from a single (but very large) endomesenchymal tract in which meninx primitiva precursor cells have been included at both ends to cause the type I configuration, but they have not been included in the middle where the median septum remains fibrous. The total length of the septa can be very long, sometimes spanning as many as seven vertebral levels. The split cord is coextensive with the septa so that the rostral and caudal reunion sites of the hemicords hug tightly to the rostral margin of the rostral bone spur and the caudal margin of the caudal bone spur, respectively. Exposure, laminectomy, and extradural resection of the two type I bone spurs are as described above. The dural opening begins rostral to the rostral dural sleeve, skirts around it, returns to the midline over the type II lesion, and finally skirts around the second dural sleeve (Fig. 18-8A). Resection of the middle type II fibrous septum should then be done to gain a “free” area within the midportion of the median cleft. This will provide working room to begin the resection of the type I dural sleeves above and below; for the rostral dural sleeve, resection goes from caudal to rostral, whereas resection goes from rostral to caudal for the caudal dural sleeve. This way, the manipulation of the dural sleeve is always directed toward and never away from the tight reunion site of the hemicords at either end (Fig. 18-8B).

Central vessels and paramedian nerve roots are scattered throughout the extent of the long row of mid-line septa and all have to be divided. Release of the cord is accomplished with total excision of all three septa and reconstruction of a single dural sac for the entire affected length of the cord. If two or more SCMs occur in the same patient but are separated by an interval of normal spinal cord, they are true multiple SCMs. These are rare because they result from multiple endomesenchymal tracts, that is, from multiple embryological errors in the same neural tube. The individual SCMs may be all type I or type II, or of each type. Their surgical treatment is as described.

Figure 18-7 A composite SCM (type I-type II-type I combination). (A) An axial view from a computed tomographic myelogram (CTM) shows a type I SCM at T-12 with an oblique bony septum and double dural tubes. (B) This CTM view shows a type II SCM at L-1 with an oblique fibrous septum within a single dural sac. (C) This CTM view shows a type I SCM at L-4. All three septa are coplanar in obliquity.

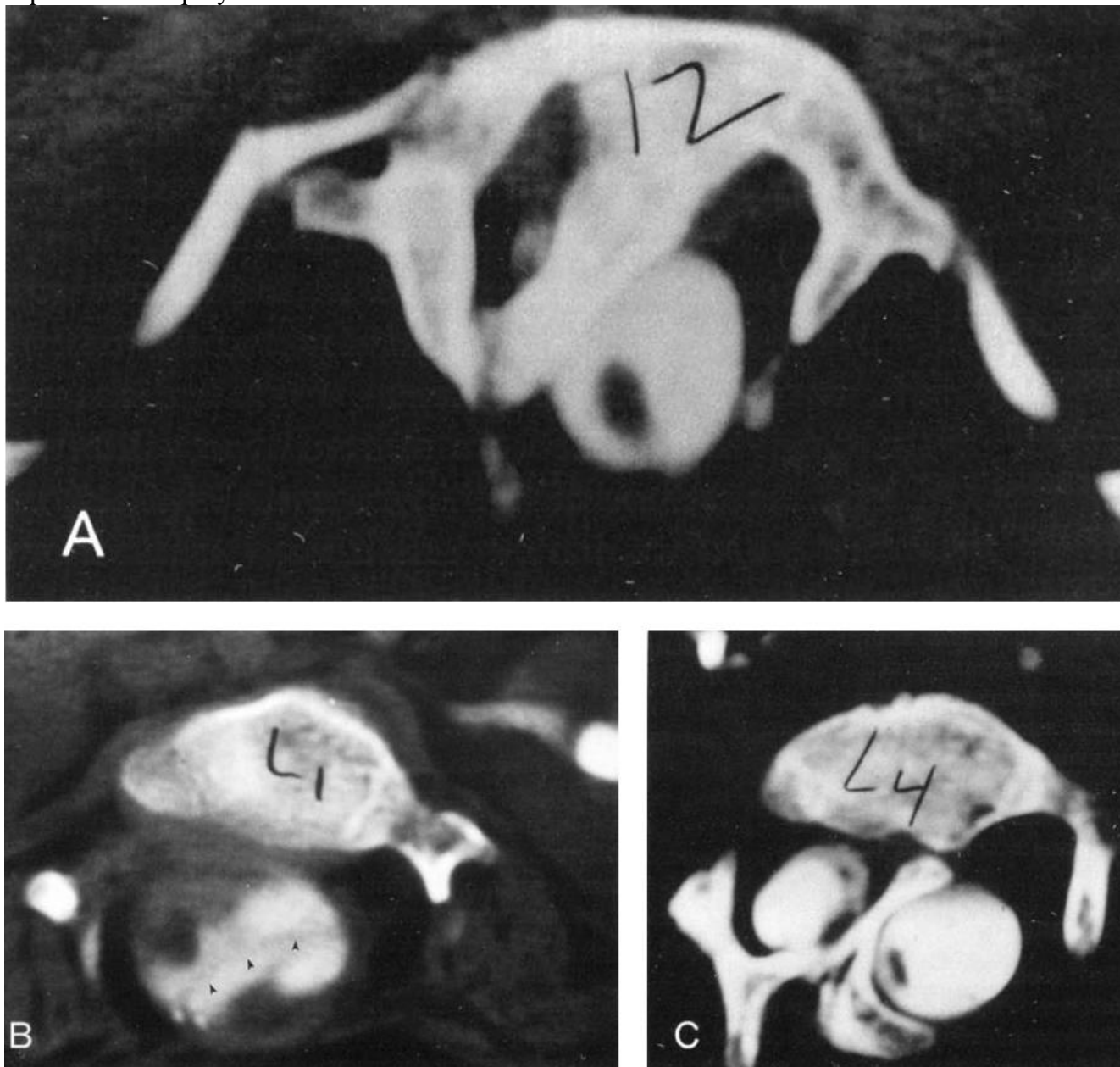
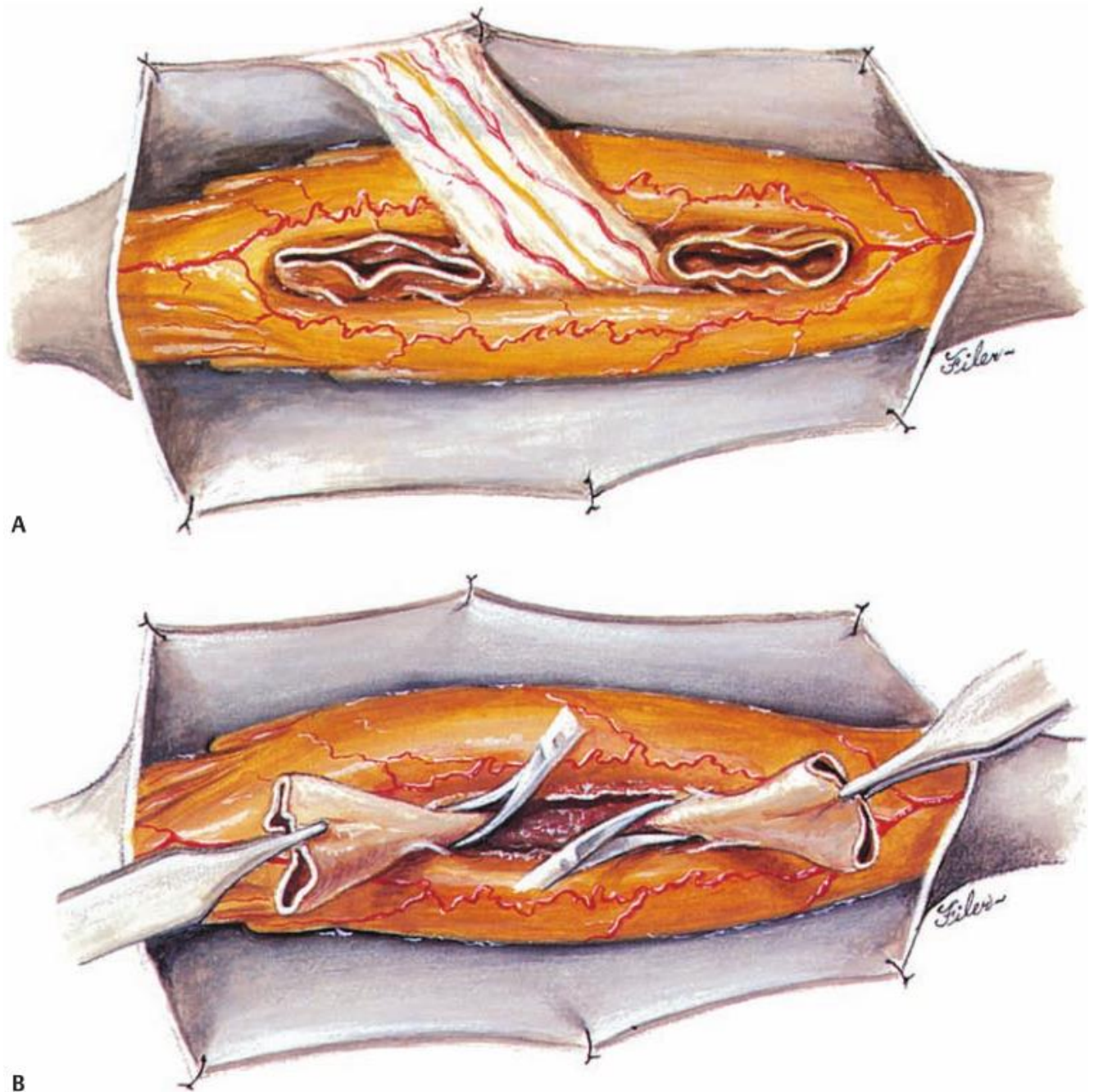


Figure 18-8 Intraoperative exposure of a composite SCM (same lesions). The fibrous septum has been resected, which provides room in the middle; the dural sleeves now can be resected. (A) a midline type II fibrous septum fills the safely from a middle free space toward the respective crotches. interval between the median dural sleeves of the two type I of the split cord.

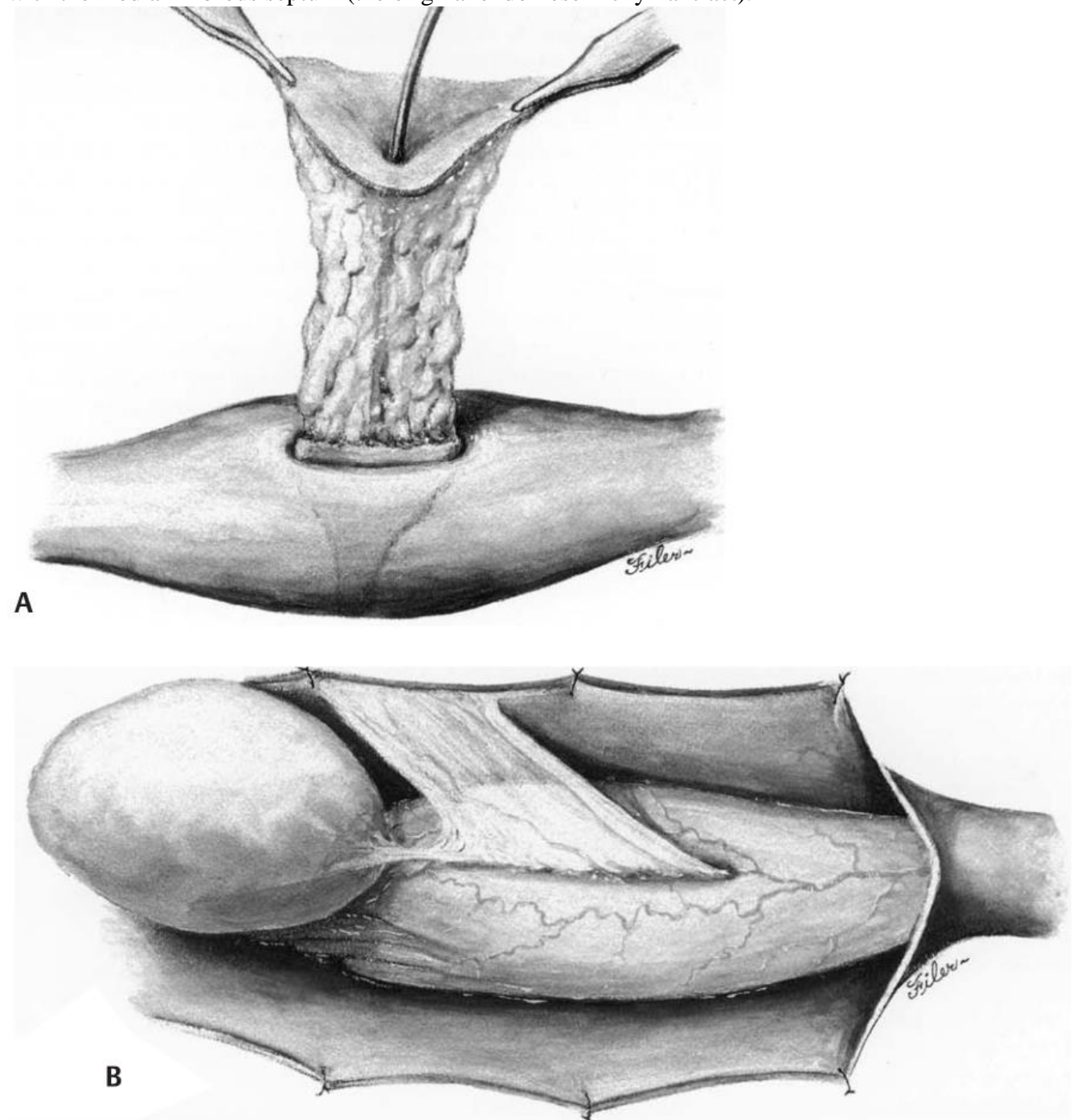


Associated Dermal Sinus Tract and Dermoid Cyst

A dermal sinus tract is formed when the original connection between the endomesenchymal tract and the cutaneous ectoderm is retained. Because of this embryological relationship, the deep end of the sinus tract is always in continuity with the mesenchymal median septum regardless of the type of SCM, but because the median septum is either extra- or intrathecal depending on the lesion type, the clinical significance of the retained dermal sinus tract depends on the type of SCM it is associated with. For a type I lesion, the dermal sinus tract can be traced all the way from the cutaneous opening (the pit) through midline defects in the lumbosacral fascia, muscles, and neural arches to the bone spur (Fig. 18–9A). Thus, the tract is always excluded from the CSF, and except in rare situations where it penetrates one wall of the median dural sleeve to involve the hemicord, it does not contribute to the tethering. It is removed together with the bone spur before the dura is ever opened. Even if the tract may occasionally encyst to form a dermoid cyst, it lies outside the dural sac and seldom becomes large enough to cause compression of the hemicords. In a type II SCM, however, the dermal sinus tract is of necessity intradural where it retains connection with the median fibrous septum. In its intradural course, the sinus tract is often densely adherent to the hemicords or the cord caudal to the caudal reunion site, thereby exerting a separate tethering effect on the cord. In addition, more than 50% of

dermal sinus tracts in a type II SCM will develop a dermoid cyst within the dura, often large enough to cause cord compression (Fig. 18–9B). The entire intradural sinus tract and cyst must be excised to eliminate the tethering effect and prevent recurrence. The cyst is first collapsed by intracapsular evacuation of its “cheesy” content, and the cyst wall is then carefully peeled off the pial surface of the cord. Its deep end is removed with resection of the fibrous median septum.

Figure 18–9 SCM and associated dermal sinus tract. (A) In a type I SCM, the dermal sinus tract is continuous with its bony septum and median dural sleeve but is entirely extradural. (B) In a type II SCM, the dermal sinus tract is intradural. A large dermoid cyst within this tract maintains a connection with the median fibrous septum (the original endomesenchymal tract).



Associated Myelomeningocele and Hemimyelocele

Approximately 25 to 35% of SCMs have an associated, and adjacent, open neural tube defect. Depending on whether one or both hemicords are involved in the dysraphic sac, the lesion may contain a hemimyelocele or a full-blown myelomeningocele, respectively. In most myelomeningoceles, the open neural placode is terminal and thus is caudal to the SCM. Less commonly, the open placode is

segmental and may therefore be either rostral or caudal to the SCM. Because the open dysraphic sac is usually treated at birth, by the time the SCM is diagnosed by later neuroimaging studies and explored via a second surgical procedure, the original neural placode would have already developed dense adhesions to the dorsal dura. Because the placode is always adjacent to the split cord and may well be contributing to the tethering, it is always freed from the dura when the SCM is being treated. The most caudal set of intact laminae above the open spinal defect are removed to expose normal, nonadherent dura. Depending on whether the placode is rostral or caudal to the SCM, it is carefully detached from the dorsal dura by sharp dissection with microscissors either before or after the median septum is excised. Most hemimyeloceles are segmental. The unaffected hemicord is usually hidden from view by the median septum during the original sac closure, when the hemiplacode is mistaken to be the whole lesion. During the definitive procedure for the SCM, the entire dural sac (double or single) must be exposed to give access to both hemicords. This often requires cutting into dense scar tissue. Again, removing the adjacent normal laminae helps to define the full width of the dura rostral to the scar. After identifying and removing the median septum, the hemiplacode is detached from the dorsal dura with sharp dissection.

COMPLICATIONS

Worsening of neurological function - occurs in < 5% of patients; more common with **type I SCM** - as a result of injury to hemicords during removal of bone spur:

- when **bony septum is oblique** and delicate minor hemicord is tucked under overhanging septum within acute angle made by septum and vertebral body.
- risk of hemicord injury is minimized by following precautions:
 - 1) **accurate preoperative depiction** of peculiar angulation of bony septum and relationship of minor hemicord to bony overhang.
 - 2) **wide laminectomy** at site of septum to improve exposure of both dural sacs (without wide exposure, oblique bone spur may be mistaken for lateral wall of spinal canal)
 - 3) extremely careful **piecemeal resection of dorsal end of septum** - as more of this end of septum is bitten away, more of minor dural tube is exposed, which in turn will permit further peeling of median dural sleeve off underside of septum to prepare for more bone removal.

CSF leakage when there is previously treated open neural tube defect adjacent to split cord.

- **watertight dural closure!**
- fully **prone position for 5-7 days** after surgery (heavy sedation may be necessary).

Transient detrusor weakness and urinary retention

- not uncommon after resection of **type I SCM**.
- can last from a few days to several months (permanent in ~3% of patients).
- more common in **adults** than in children.
- catheter is removed on 3rd postoperative day as patient is encouraged to ambulate and use bathroom.
- if large postvoid residual urine volume → **BETHANECHOL** to strengthen detrusor contraction, or **PRAZOSIN** to encourage relaxation of internal urethral sphincter; if PVR remains high on medication → intermittent catheterization is continued on outpatient basis for 4-6 weeks → cystometrogram (to determine whether therapy can be discontinued).

