

Craniotomies

Last updated: January 16, 2021

Table of Contents

GENERAL ASPECTS 2
APPROACHES, CHOICE OF 5
SPECIAL SITUATIONS..... 8
AWAKE CRANIOTOMIES..... 8
TRANSNASAL ENDOSCOPIC ACCESS TO ANTERIOR CRANIAL FLOOR..... 19
FRONTAL (UNILATERAL) CRANIOTOMY..... 19
BIFRONTAL CRANIOTOMY 20
FRONTO-TEMPORO-ZYGOMATIC CRANIOTOMY 21
SUBFRONTAL CRANIOTOMY 21
PARIETAL CRANIOTOMY..... 22
(SUB)TEMPORAL CRANIOTOMY..... 22
PTERIONAL CRANIOTOMY 23
PTERIONAL CRANIOTOMY WITH ORBITOZYGOMATIC EXTENSION (“OZ CRANIOTOMY”) 24
ANTERIOR CLINOIDECTOMY..... 25
TRANSORAL CLIVAL APPROACH 25
TRANSPETROSAL APPROACHES TO POSTERIOR FOSSA 26
RETROLABYRINTHINE (PRESIGMOID) APPROACH 26
TEMPOROPOLAR (HALF-AND-HALF) APPROACH TO THE BASILAR ARTERY AND THE RETROSELLAR SPACE..... 29
POSTERIOR FOSSA CRANIECTOMY / MIDLINE SUBOCCIPITAL CRANIOTOMY 30
LATERAL SUBOCCIPITAL CRANIOTOMY..... 33
RETROSIGMOID (RETROMASTOID) CRANIOTOMY 35
SUPRACEREBELLAR INFRATENTORIAL APPROACH..... 38
FAR-LATERAL SUBOCCIPITAL APPROACH..... 41
TRANSCONDYLAR APPROACH..... 44

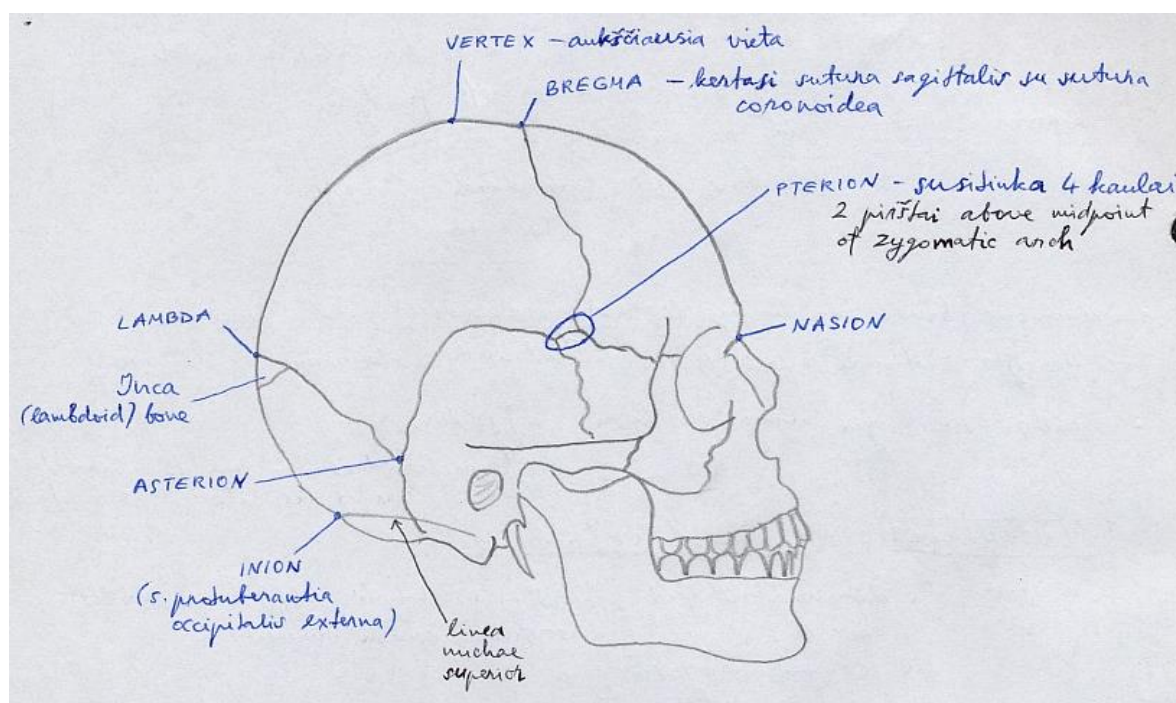
Detailed Table of Contents

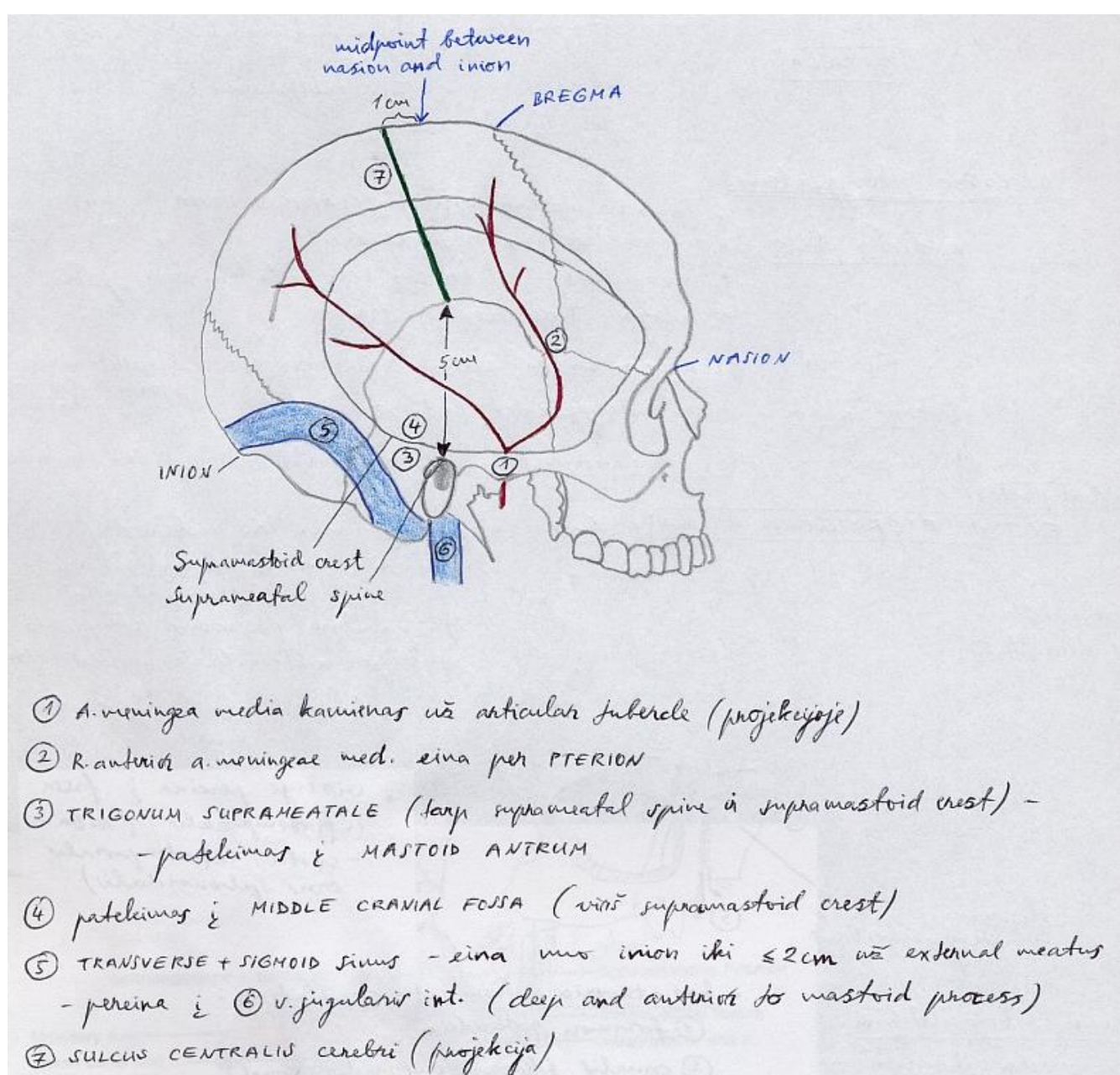
GENERAL ASPECTS 2
 SURGICAL ANATOMY OF CRANIUM..... 2
 Frontalis branches of CN7..... 3
 Asterion 3
 Occipito-mastoid suture 3
 Torcular 3
 Jugular foramen 4
 Central sulcus 4
 PATIENT POSITIONS 4
 PINNING OF THE SKULL 4
 SIZE OF CRANIOTOMY 4
 INCISION FOR CRANIOTOMY 4
 PERICRANIAL FLAP 4
 BONE FLAP 4
 BRAIN HANDLING 5
 Retraction injury..... 5
 CLOSURE OF CRANIOTOMY 5
 Vancomycin..... 5
APPROACHES, CHOICE OF 5
 CONVEXITY..... 5
 SKULL BASE 5
 Anterior Skull Base 7
 Middle Skull Base 7
 Mesial Temporal Region 8
 POSTERIOR FOSSA..... 8
 Internal Auditory Canal ± CP angle 8
 Jugular Foramen 8
SPECIAL SITUATIONS..... 8
 Dural Venous Sinus Injury 8
 Entry into Frontal Sinus 8
 Entry into Mastoid Air Cells 8
 Bone flap hits the floor..... 8
AWAKE CRANIOTOMIES..... 8
 Indications 9
 Contraindications 9
 Alternative 9
 Anesthesia 9
 Scalp regional anesthesia..... 9
 Positioning..... 10
 Craniotomy..... 10
 Mapping Principles 11
 Equipment 11
 After Discharge (AD) Threshold Determination..... 11
 Cortical Stimulation 11
 Subcortical mapping..... 12
 Redo craniotomies 12
 Anatomical Localization on Imaging..... 12
 Testing paradigms 13
 Motor Mapping 14
 Sensory mapping 15
 Somatosensory Evoked Potentials (SSEP) Mapping 15
 Sensory Mapping..... 16
 Language Mapping..... 16
 Resection Technique 17
 Complication Avoidance..... 18
TRANSNASAL ENDOSCOPIC ACCESS TO ANTERIOR CRANIAL FLOOR..... 19
 Indications 19
 Preop..... 19
 Details..... 19
 Postop 19
FRONTAL (UNILATERAL) CRANIOTOMY..... 19
 Positioning, Pinning, Incision 19
 Supra-orbital craniotomy (s. "eyebrow" craniotomy) 20
BIFRONTAL CRANIOTOMY 20
 Indications 20
 Positioning, Pinning, Incision 20
FRONTO-TEMPORO-ZYGOMATIC CRANIOTOMY 21
SUBFRONTAL CRANIOTOMY 21
PARIETAL CRANIOTOMY 22
(SUB)TEMPORAL CRANIOTOMY..... 22
 SUBTEMPORAL CRANIOTOMY FOR ENCEPHALOCELE REPAIR (MIDDLE FOSSA)..... 23
PTERIONAL CRANIOTOMY 23
PTERIONAL CRANIOTOMY WITH ORBITOZYGOMATIC EXTENSION (“OZ CRANIOTOMY”) 24
ANTERIOR CLINOIDECTOMY..... 25
TRANSORAL CLIVAL APPROACH 25
TRANSPETROSAL APPROACHES TO POSTERIOR FOSSA 26

Anterior (medial) transpetrosal approaches (Kawase, s. anterior petrosectomy)..... 26
 Posterior transpetrosal (presigmoid) approaches 26
RETROLABYRINTHINE (PRESIGMOID) APPROACH 26
TEMPOROPOLAR (HALF-AND-HALF) APPROACH TO THE BASILAR ARTERY AND THE RETROSELLAR SPACE 29
 INDICATIONS 29
 CONTRAINDICATIONS..... 29
 PROCEDURE 29
POSTERIOR FOSSA CRANIECTOMY / MIDLINE SUBOCCIPITAL CRANIOTOMY 30
 Indications 30
 Preop..... 30
 Position..... 30
 Technique 31
 Dissection 31
 Craniectomy 31
 C1 laminectomy 31
 Fibrous band..... 32
 Dural Opening, Duraplasty..... 32
 Closure..... 33
 Postoperative, Complications, Follow Up..... 33
LATERAL SUBOCCIPITAL CRANIOTOMY..... 33
 Indications 33
 Anesthesia 33
 Technique 33
 Postoperatively 35
RETROSIGMOID (RETROMASTOID) CRANIOTOMY 35
 INDICATIONS 35
 PROCEDURE 35
 Location of asterion..... 35
 Position..... 35
 Electrophysiological monitoring 35
 Pin placement 36
 Incision 36
 Craniotomy..... 37
 EXTENDED RETROSIGMOID CRANIOTOMY 37
 Preop..... 37
 Technique 37
SUPRACEREBELLAR INFRATENTORIAL APPROACH..... 38
 INDICATIONS 38
 CONTRAINDICATIONS..... 38
 PREOPERATIVE..... 38
 PROCEDURE 39
 Anesthesia 39
 Positioning..... 39
 Dissection..... 39
 COMPLICATIONS 40
 Air embolism..... 40
FAR-LATERAL SUBOCCIPITAL APPROACH..... 41
 INDICATIONS 41
 PROCEDURE 41
TRANSCONDYLAR APPROACH..... 44
TRAUMA PROCEDURES (burr hole washout, decompressive craniectomies, etc) – see p. Op320 >>
SUBDURAL TAP THROUGH FONTANEL – see p. TrH13 >>
PATIENT POSITIONING, PINNING – see p. Op100 >>
MEDICATIONS for craniotomies – see p. Op100 >>

GENERAL ASPECTS

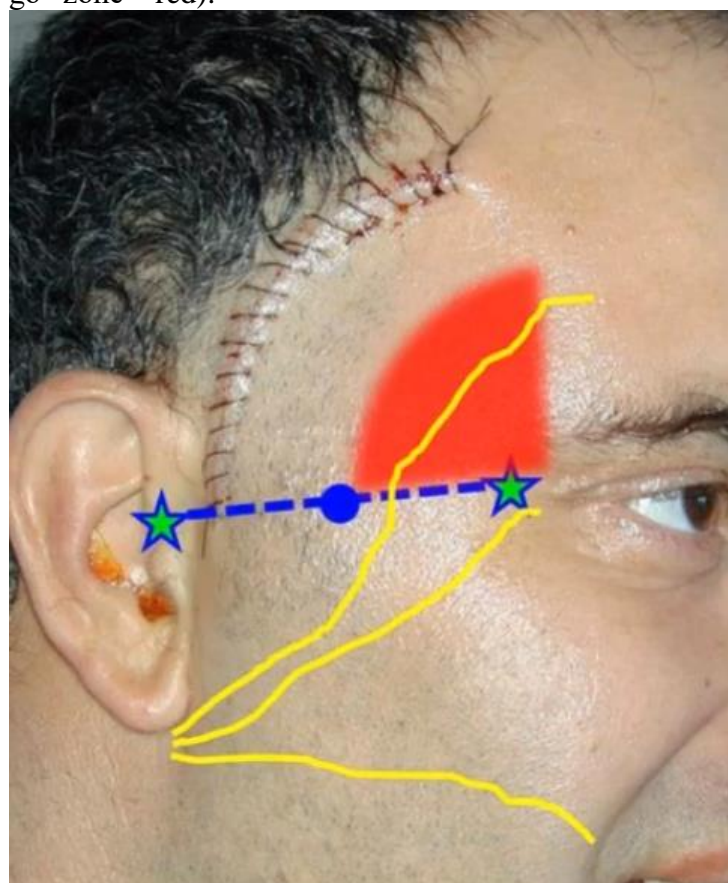
SURGICAL ANATOMY OF CRANIUM





FRONTALIS BRANCHES OF CN7

Line between tragus and lateral canthus; frontalis branches are in front of midpoint of this line ("no go" zone - red):

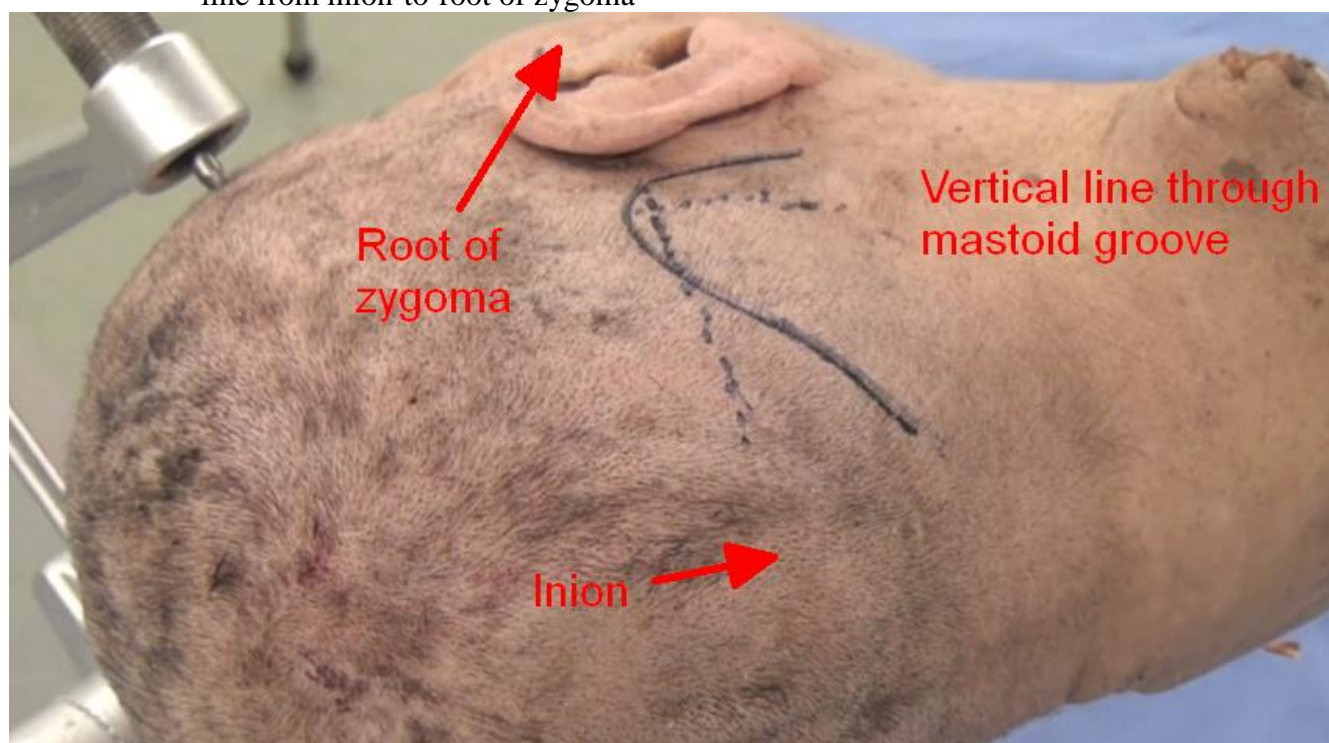


ASTERION

- sigmoid-transverse sinus junction most commonly (but not always) hugs it anteriorly-superiorly (so it is safe to drill here if targeting venous sinus angle) - on the line from root of zygoma to inion where it is intersected with vertical line just behind mastoid process.

N.B. in many cases asterion is above of transverse-sigmoid sinus junction - be careful when drilling bur hole!

- A) 1 cm above and 4 cm posterior to external auditory canal (Dr. Graham)
- B) Intersection of:
 - vertical line through mastoid groove
 - line from inion-to-root of zygoma



OCCIPITO-MASTOID SUTURE

(extends down from asterion) - posterior edge of sigmoid sinus is 1 cm anterior from it.

TORCULAR

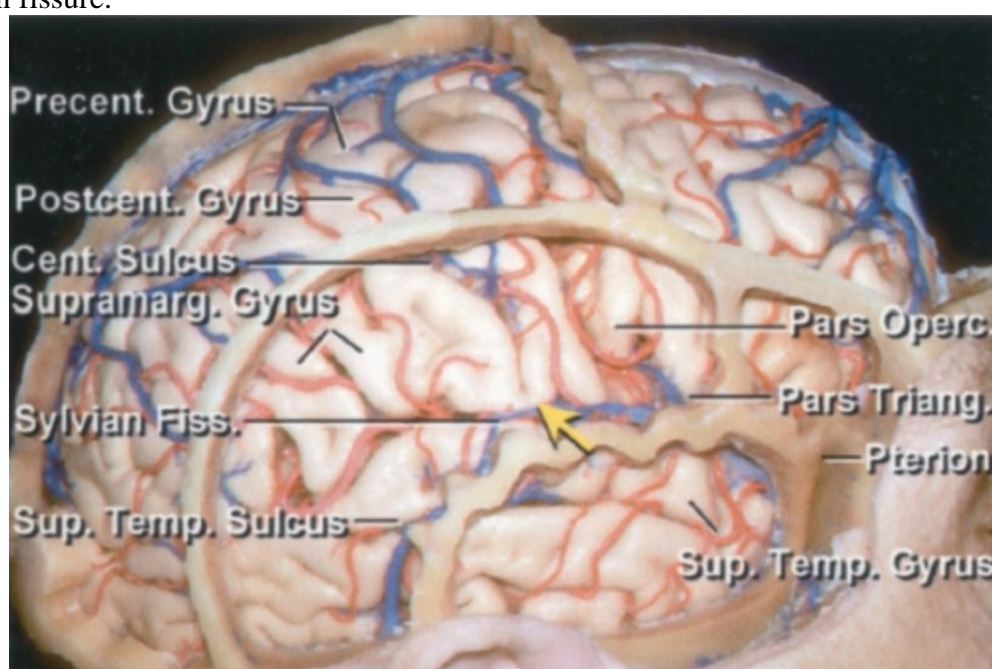
is 1 cm above inion tip.

JUGULAR FORAMEN

– nerves occupy central portion of it; jugular vein is posterior.

CENTRAL SULCUS

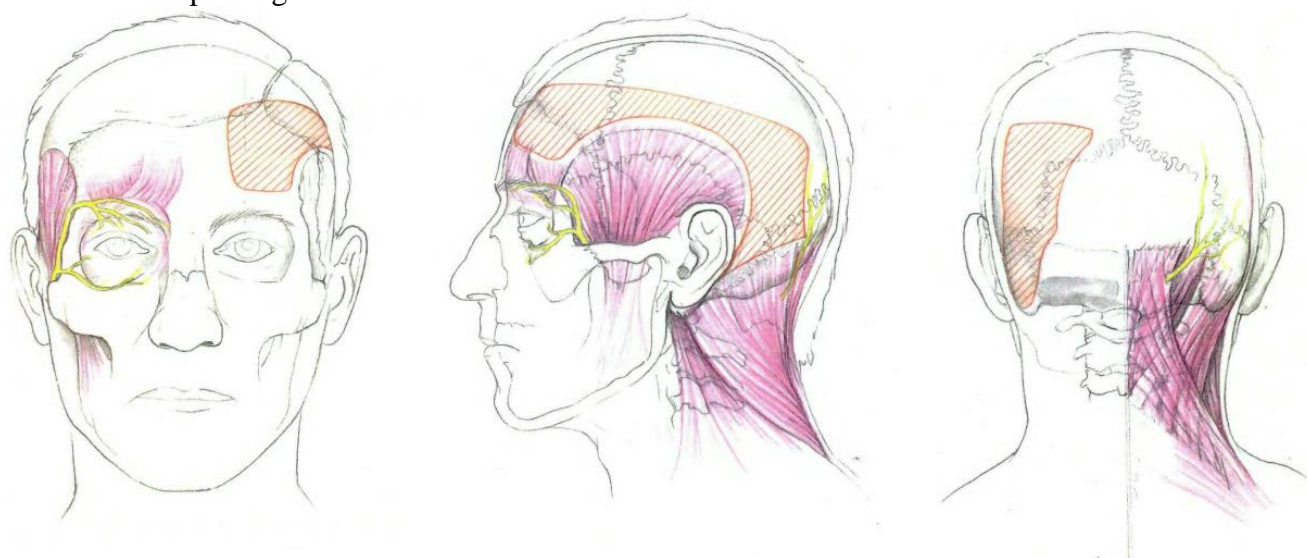
- midline point at the 50% nasion-inion line; location of the central sulcus is approximately 2 cm behind this 50% point
- 3.5-4.5 cm behind the coronal suture. The lower portion of the precentral gyrus is located just posterior to the pars opercularis, and the similar portion of the postcentral gyrus is immediately anterior to the supramarginal gyrus. There is a gyral ridge (yellow arrow, middle image) connecting the precentral and postcentral gyri so that the central sulcus never directly joins the Sylvian fissure:

**PATIENT POSITIONS**

- see p. Op100 >>

PINNING OF THE SKULL

Safe areas for pinning:

**SIZE OF CRANIOTOMY**

- goal of **“keyhole” surgery** - not to perform small incision and craniotomy for sake of small opening but to permit adequate access to skull base while limiting trauma to surrounding structures.
McCarty keyhole
- size of craniotomy:
 - **surface lesions** typically require craniotomies as large as lesion.
 - **deep-seated lesions** can be accessed through much smaller craniotomy since intracranial field widens with increasing distance from skull.

Minimally Invasive Transcranial Operative Corridors: Techniques:

<http://www.neurosurgicalatlas.com/grand-rounds/minimally-invasive-transcranial-operative-corridors-techniques>

INCISION FOR CRANIOTOMY

- instead of straight (slash) incisions, use “S” incisions – will get much more length and thus can retract scalp more for larger craniotomy.
- incise epithelium with knife, then use Bovie for hemostatic cut.
Alternative (**Dr. Broaddus**) – single cut down to bone* then Raney clips.
*except temporalis muscle – better to open with Bovie to prevent bleeding
- avoid Raney clips** – may cause permanent incisional alopecia; if used – remove at stepwise fashion along of scalp closure (minimize blood loss).
- use Metz over temporalis muscle – insert scissor tips between scalp and temporalis fascia and cut over it.
- for lifting up temporalis fascia and leaving cuff – how to find optimal cuff: incise fascia along fibers (vertical cut) – this way will see where fascia inserts into bone and thus will know how big cuff needs to be.

PERICRANIAL FLAP

- helps to seal (inadvertently) entered air sinus.
- make cut through galea, then insert Metz in the subgaleal plane above pericranium – cut on Metz; elevate scalp flap first; then elevate pericranium separately (and keep it wrapped in the wet gauze for the rest of the case).
- Dr. Graham** likes to dissect pericranium from scalp flap at the end of case using Bovie; he sometimes leaves only narrow pedicle for pericranial flap – still enough for vascular supply but lets to advance flap much more posteriorly.

BONE FLAP

- may use *14 mm perforator* at **calvarium** – quick; at **keyhole** and **zygoma** need to use *Acorn drill bit* as bone there is very thin (until perforator reaches disengagement depth, dura is already shredded).
- dura is separated off the edges of bone using Penfield 3, Woodsen probe, or hockey stick probe; may need to enlarge inferior aspects of bur hole to allow the instrument to pass in.
- bur holes are then connected using *footplate*.

BRAIN HANDLING

RETRACTION INJURY

- happens with > 20 mmHg retraction for > 15 minutes
 1Rosenørn J, Diemer NH. The risk of cerebral damage during graded brain retractor pressure in the rat. *J Neurosurg.* 1985;63(4):608-611. doi:10.3171/jns.1985.63.4.0608.
- best seen on postop DWI.

CLOSURE OF CRANIOTOMY

- 2-0 Vicryl for galea only! (common mistake – to include some skin as well – no benefit but increased risk of spit stitch)
- staples for skin (esp. **Dr. Broaddus** – does not like Monocryl!)
- close dura water tight* with 4-0 silk running stitch; may place layer of Duragen above or below dura suture line; may reinforce with dura sealant.
 *esp. for kids < 3 yo – to prevent leptomenigeal cyst (**Dr. Collins** likes to rotate pericranial flap on pedicle to cover dura).

VANCOMYCIN

Topical vancomycin powder 1gram into subgaleal space after final irrigation **decreases infection rate 12-fold** (from 6% to 0.5%) with overall cost reduction 1400 USD per craniotomy (1 gram of vancomycin costs 12 USD, 1 case of postcraniotomy infection costs 24,000 USD)

Mallela et al. Topical Vancomycin Reduces Surgical-Site Infections After Craniotomy: A Prospective, Controlled Study. Neurosurgery 83:761–767, 2018

APPROACHES, CHOICE OF

Minimally invasive ≠ Maximally evasive

CONVEXITY

ENTIRE CONVEXITY:

Twist drill craniostomy >>

Bur hole washout >>

Decompressive hemicraniectomy (“Trauma Flap”) / Frontotemporoparietal craniotomy >>

FRONTAL CONVEXITY:

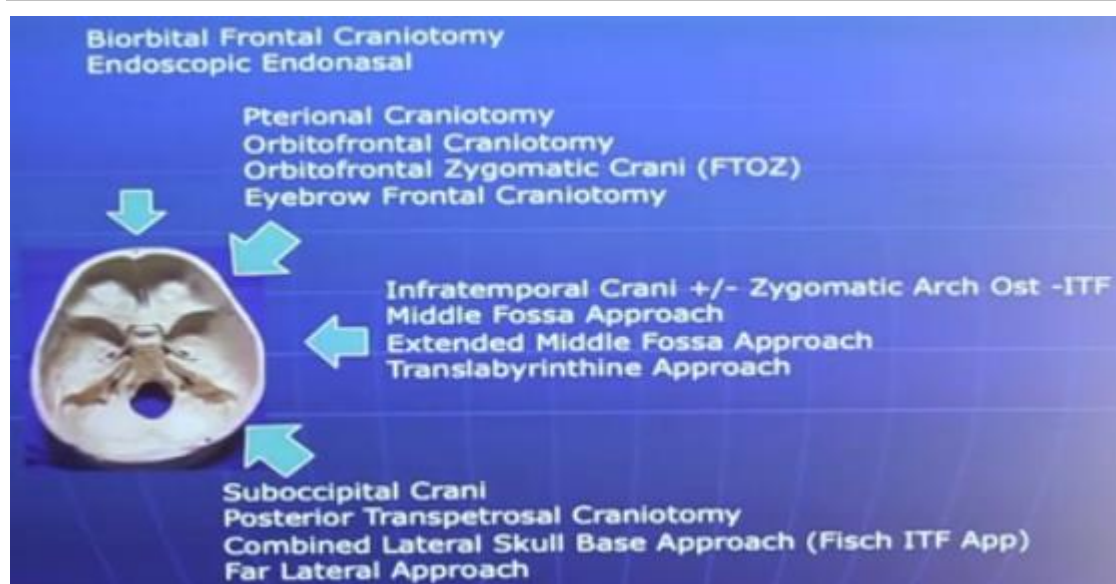Decompressive Bifrontal craniectomy (Kjellberg) >>

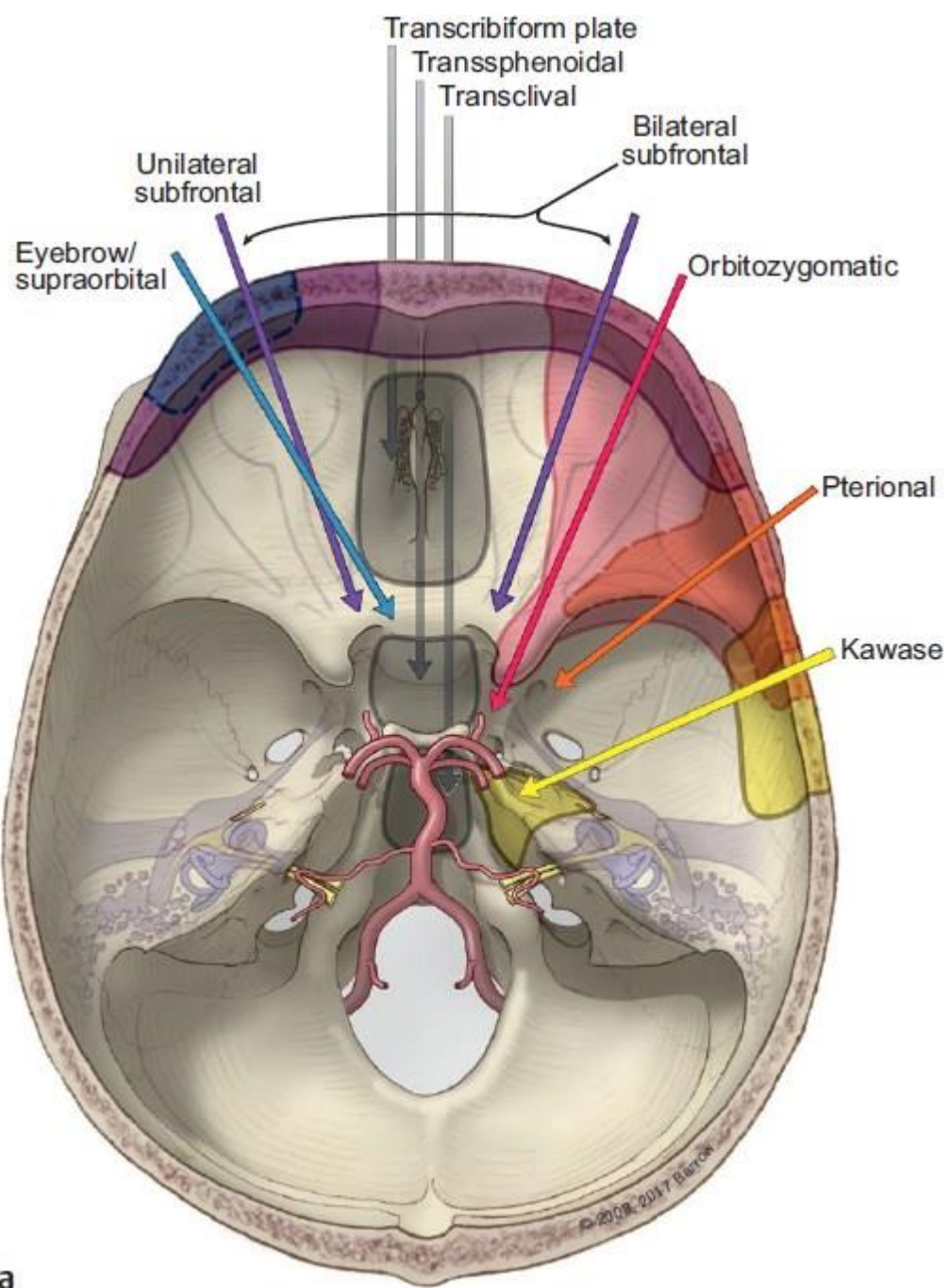
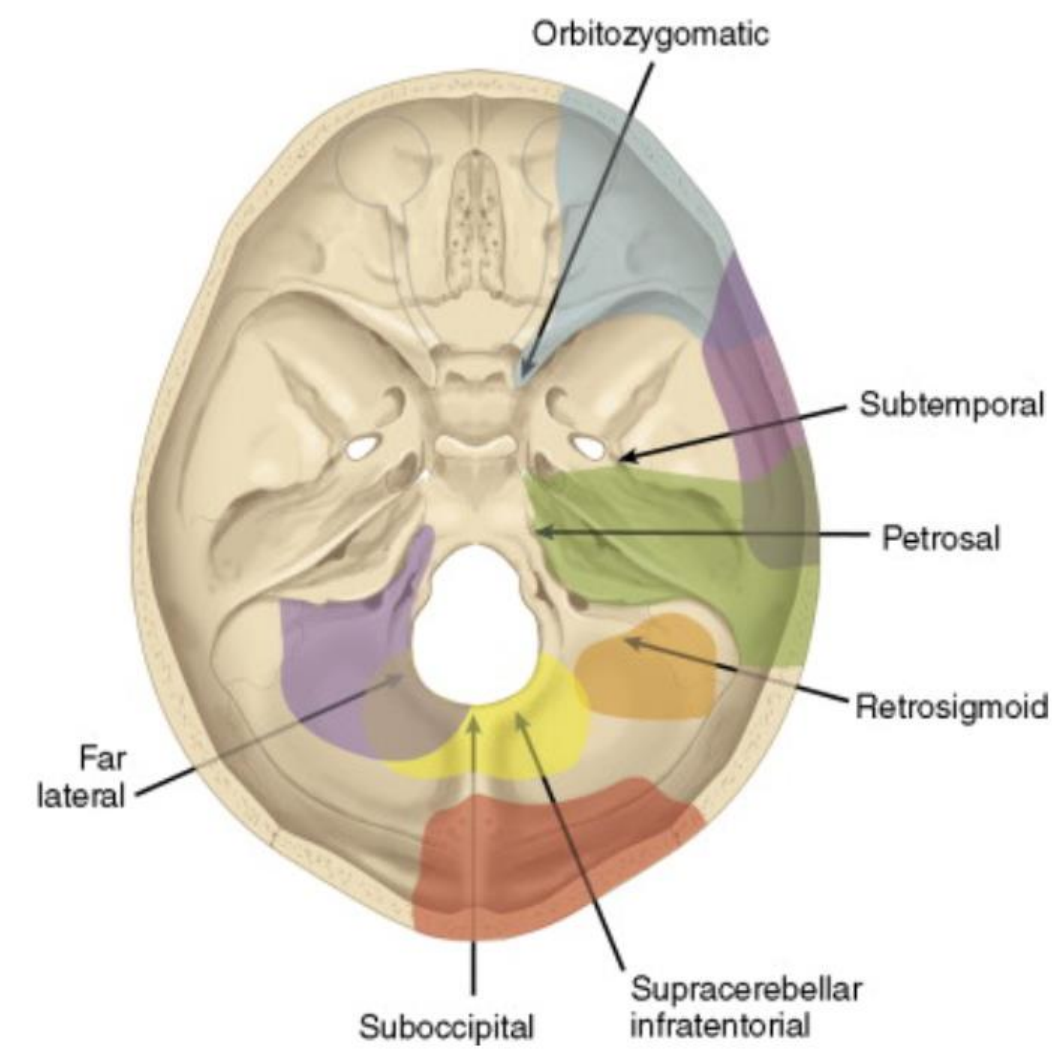
Frontal (Unilateral) craniotomy >>

FRONTOTEMPORAL CONVEXITY:

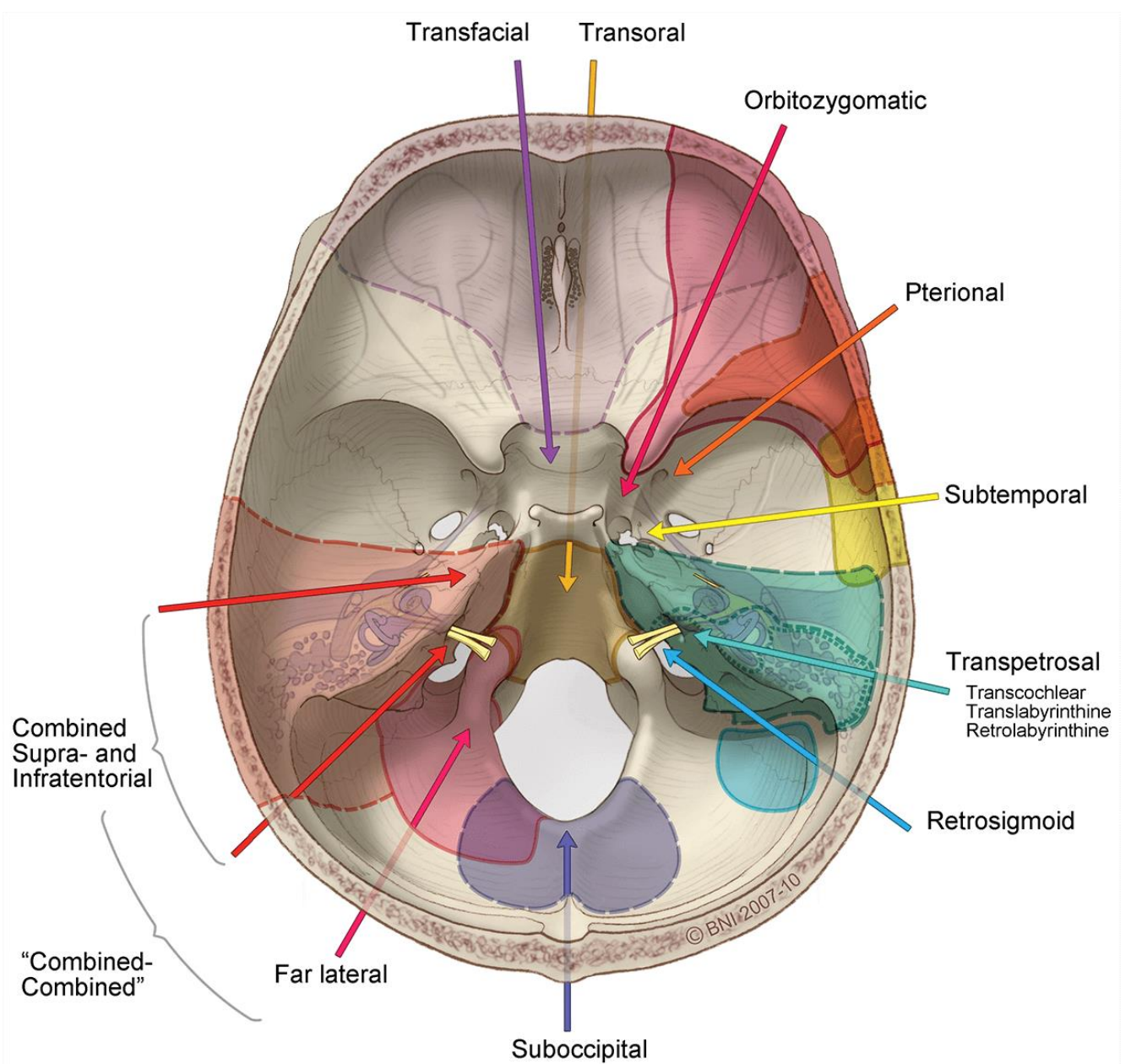
Fronto-temporo-zygomatic craniotomy >>

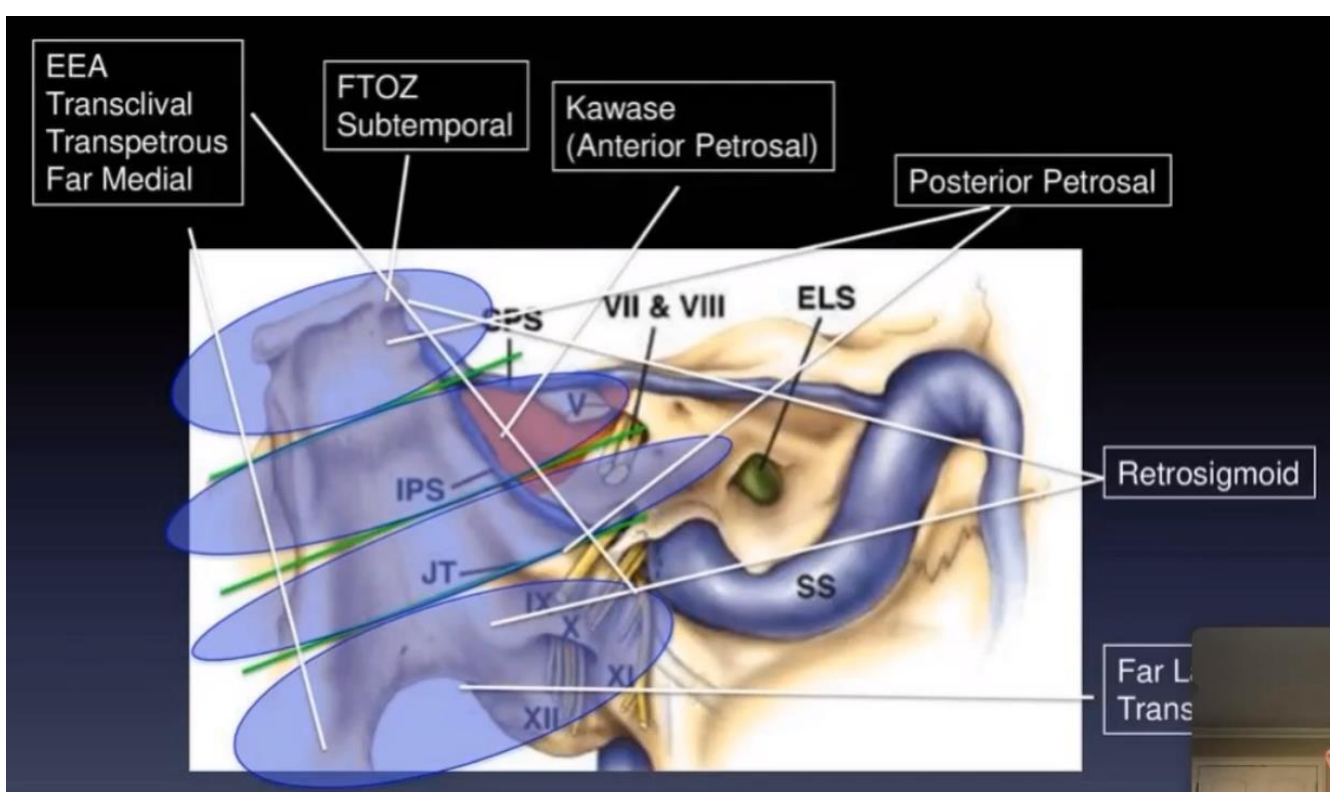
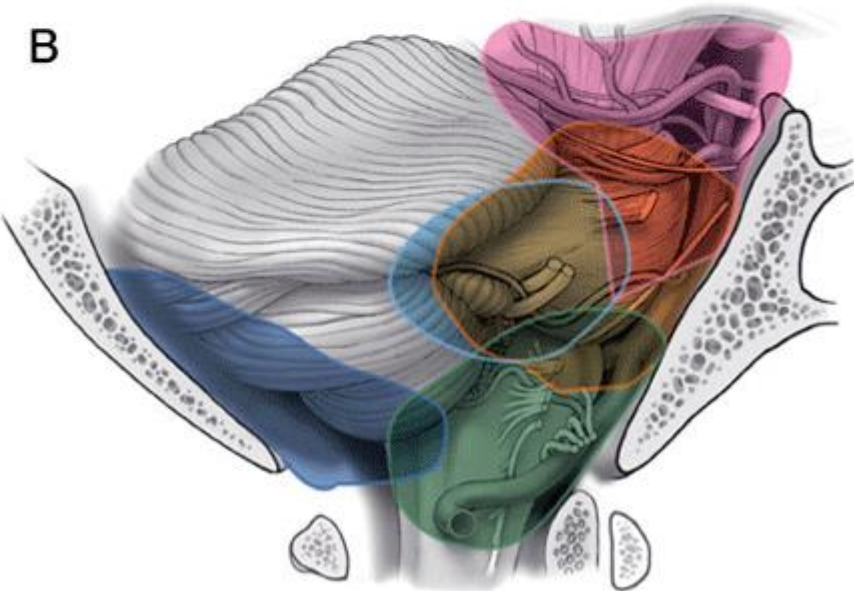
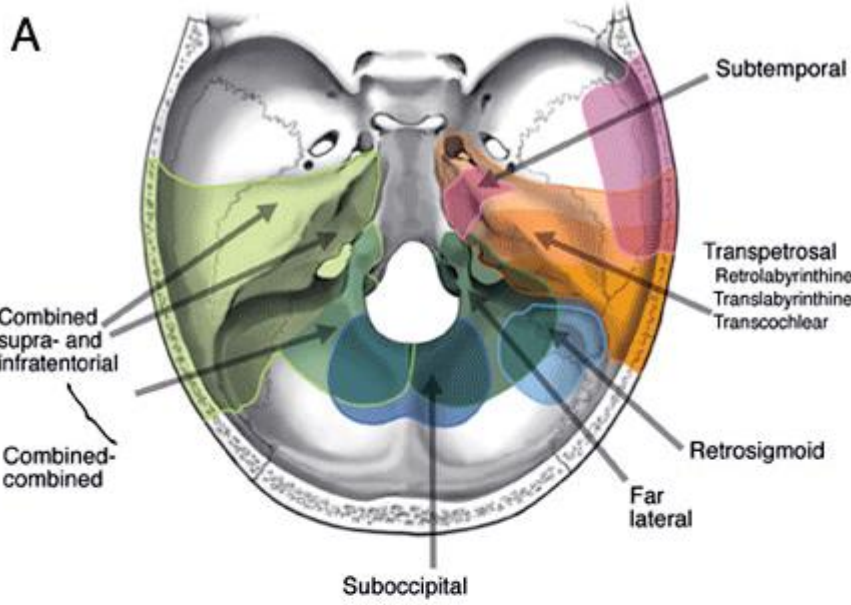
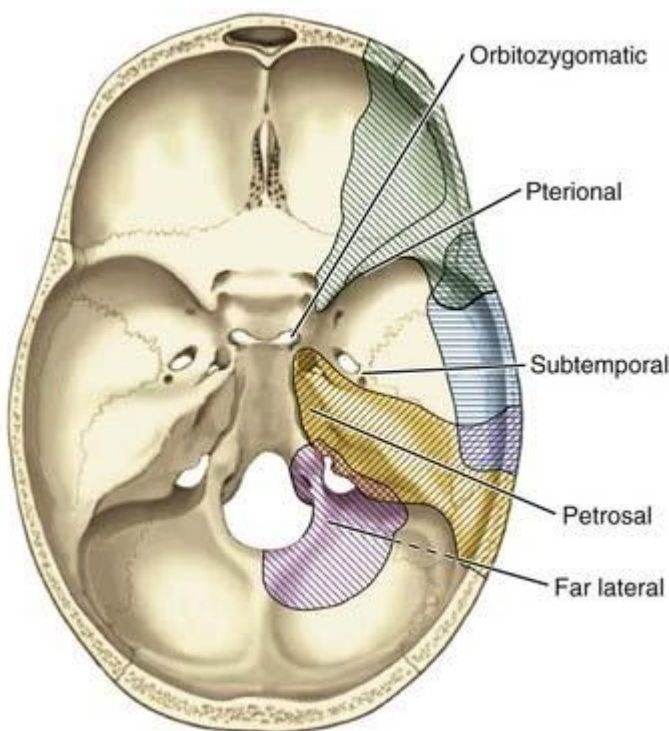
SKULL BASE





a





ANTERIOR SKULL BASE

- Transnasal endoscopic access to anterior cranial floor >>
- Midline Anterior Skull Base approach
 - NREF video >>
- Bifrontal craniotomy
- Subfrontal craniotomy
- Supraorbital keyhole craniotomy - through eyebrow incision
- Interhemispheric approach

Transbasal approach – extending down through cribriform plate into nasal cavity (up to hard palate); now obsolete due to ENT endoscopic capabilities.

- for anterior skull base repair may use titanium mesh, pericranium flap, galea flap, temporalis muscle rotated on vascular pedicle; postop may use “airflow diversion” (tracheostomy, intubation, or at least nasal airway for 3 days – all help to prevent soft tissue used for reconstruction movement when patient is breathing / coughing / sneezing).

MIDDLE SKULL BASE

- Fronto-temporo-zygomatic craniotomy >>
- Frontotemporal craniotomy (e.g. Dandy’s frontotemporal “macrosurgical approach”)
- Pterional craniotomy (e.g. Yasargil’s microsurgical pterional approach) >>
- Orbitozygomatic craniotomy >>
- Infratemporal craniotomy
 - NREF video >>

Designing a Lateral Skull Base Approach – NREF video >>

MESIAL TEMPORAL REGION

- divided into 3 areas:

1. **Anterior** - transsylvian-transinsular approach
2. **Middle** - transtemporal approach
3. **Posterior** - supracerebellar-transtentorial approach

POSTERIOR FOSSA

- A. Suboccipital craniotomy >>
 - Supracerebellar approach >>
- B. Retrosigmoid (retromastoid) >>
 - Far Lateral approach >>
- C. Presigmoid (in order of increasing temporal bone drilling):
 - a) retrolabyrinthine
 - b) translabyrinthine
 - c) transcochlear
- D. Transoral Clival approach >>

Designing a Posterolateral Skull Base Approach: Presigmoid vs. Retrosigmoid Approaches – NREF video >>

Designing a Posterior Fosse Approach – NREF video >>

INTERNAL AUDITORY CANAL ± CP ANGLE

JUGULAR FORAMEN

Approach to jugular foramen – NREF video >>

SPECIAL SITUATIONS

DURAL VENOUS SINUS INJURY

- before elevating fracture over sinus **notify anesthesia** (risk of **bleeding + air embolism**) and have large piece of Gelfoam and **rapid infuser** ready.
 - Air Embolism management: lower head, cover area with soaked RayTeks and flood with saline
- if large circular sinus is encountered while crossing foramen magnum, this should be controlled with **Weck clips**, divided, and oversewn with dural sutures. *see below*
- if bleeding is too brisk and finger pressure blocks view for repair → proximal sinotomy to allow temporary placement of inflatable Fogarty balloon catheter.
- if interposed graft is necessary for permanent repair of large sinus laceration that cannot be repaired any other way, **autogenous saphenous vein graft** may be utilized after temporarily shunting blood through interposed shunt to allow time to sew graft into place.
- bleeding from **CAVERNOUS SINUS** – inject fibrin glue into it!

Small tears can be closed using bipolar cautery and Gelfoam.

Medium tears can be managed by placing Gelfoam, Surgicel, or Avitene Flour over opening followed by wet cottonoid until bleeding stops.

Larger tears (esp. if contralateral flow is not patent or nondominant on preoperative imaging):

- lower head to prevent air embolism
- place gauze over to control bleeding; do not pack sinus – will cause thrombosis (maybe disastrous)
- while bleeding is controlled, drill bone around widely to have a good access for repair (keep sinus covered with patty to contain bleeding; assistant may place fingers on sinus proximal and distal to sinus injury to apply pressure and control bleeding).
- repair sinus wall using:
 - a) **muscle piece** plug
 - b) **dura flap** – cut C-shape adjacent dura flap (based on dural sinus) and reflect it over sinus wall defect – suture in place using interrupted 4-0 silk stitches, cover with Surgicel wrapping Gelfoam; may perform ICG angiography to confirm sinus patency

Videos of operative repair techniques:

<https://www.neurosurgicalatlas.com/volumes/principles-of-cranial-surgery/operating-room-crisis-management/dural-venous-sinus-injury>

<https://www.neurosurgicalatlas.com/cases/repair-of-superior-sagittal-sinus-injury>

ENTRY INTO FRONTAL SINUS

- carefully remove sinus mucosa from **bone flap** pockets (may use diamond drill bit for thermal kill)
- rest of sinus in orbitofrontal bar is cover with wet long patty for the duration of case; at the end check to make sure no bone dust or clots are in frontal sinus; leave mucosa intact; do not place any Gelfoam in it; **M. Couldwell** places muscle plug into sinus; cover with vascularized pericranial flap → Tisseel / DuraSeal.
- add additional antibiotic coverage.
- if sinus **mucosa is inflamed** (sinus is no longer sterile) – need **sinus cranialization**:
 - remove entire mucosa down to ostia
 - remove posterior wall of frontal sinus
 - cover ostia with pericranial flap
- Japanese neurosurgeons **suture-repair** sinus mucosal entry to close sinus intracranial access.

ENTRY INTO MASTOID AIR CELLS

- wax well or fill with HydroSet.

BONE FLAP HITS THE FLOOR

- a) **soak in Betadine** – best choice
- b) **autoclave** – powerful solution but ↑ risk of autoresorption

AWAKE CRANIOTOMIES

Used sources:

Connolly "Fundamentals of Operative Techniques in Neurosurgery" 2nd ed. (2010), ch. 60 (275-278 pages)

Badie 'Neurosurgical operative atlas - Neuro-oncology' 2nd ed. (2007), ch. 14 (pages 115, 117-119)

Jandial "Core Techniques in Operative Neurosurgery" (2011), procedure 39

Greenberg (2016) ch. 93.6.2-3

General anesthesia is preferred for most patients with *minimal to moderate motor and/or sensory deficits* and with lesions outside language regions.

Language function can only be assessed in **awake patients**.

Awake craniotomy should be considered for patients with *more severe motor or sensory deficits*, provided that the patient is cooperative.

- awake craniotomy - currently reserved only for **speech area** testing with bipolar stimulation (while patient is counting or naming objects); for **motor strip** use SSEP mapping (strip electrodes show specific **phase reversal** potentials from sensory to motor strip).

INDICATIONS

Lesions / cortical resections in or near **motor, somatosensory, language** cortex, **thalamus, brainstem**.

- **language mapping** – preop fMRI or Wada test to determine hemisphere of language dominance; object naming, at 4 sec per image, must be better than 75%.
- **motor mapping** requires (near) normal power (at least 4-/5 for mapping under general anesthesia)
- **somatosensory mapping** requires (near) normal sensation.

Dr. Cohen-Gadol uses:

asleep mapping - if the tumor does not directly infiltrate the central lobe and its associated white matter tracts but is anatomically within millimeters of these vital structures.

awake mapping:

- 2) for tumors that directly infiltrate these structures as shown on preoperative anatomical magnetic resonance (MR) or functional MR (fMR) imaging.
- 3) tumors that infiltrate the postcentral gyrus - in awake mapping stimulation of this gyrus leads to subjective paresthesias that are not detectable in an anesthetized patient.

"I use mapping (awake or sleep) primarily for low-grade gliomas affecting the central lobule. The use of this technique for resection of high-grade gliomas (HGGs) directly infiltrating the functional cortices and tracts often leads to neurologic morbidity, despite preservation of these functional areas. Subtotal resection of these HGGs is also associated with postoperative neurological decline and risk of hematoma formation. However, I do use mapping for specific HGGs that do not directly infiltrate the functional areas, but are adjacent to them. This strategy allows mapping for safe resection in nonfunctional peritumoral regions in expectation of radical tumor removal."

CONTRAINDICATIONS

1. Obesity, sleep apnea, airway problems.
2. Psychiatric issues (esp. anxiety).
3. Children < 6-10 years (decreased cortical excitability):
 - 1) awake craniotomies are not as well tolerated
 - 2) cortical stimulation mapping may not elicit motor responses (H: SSEPs are more useful to identify central sulcus).
4. Language baseline < 80% of objects named correctly at 4-second intervals. Because stimulation language mapping relies on the ability to block object naming, language cannot be localized when baseline errors are too high. Although some object slides can be discarded from the specific patient's slide set, the final set should have at least 50 slides. When the patient has normal naming ability (i.e., 100% of slides named correctly), slides are presented at 3-second intervals. This allows quicker mapping with a higher current because of less temporal current summation.

ALTERNATIVE

- subdural grid electrodes and extraoperative functional mapping.

ANESTHESIA

A) patients awake for entire duration of surgical intervention (**awake-awake-awake craniotomy, AAA**)

B) patients initially sedated (**asleep-awake-asleep craniotomy, SAS**) - *may compromise electrophysiological brain mapping* and thus endanger patient's neurological outcome

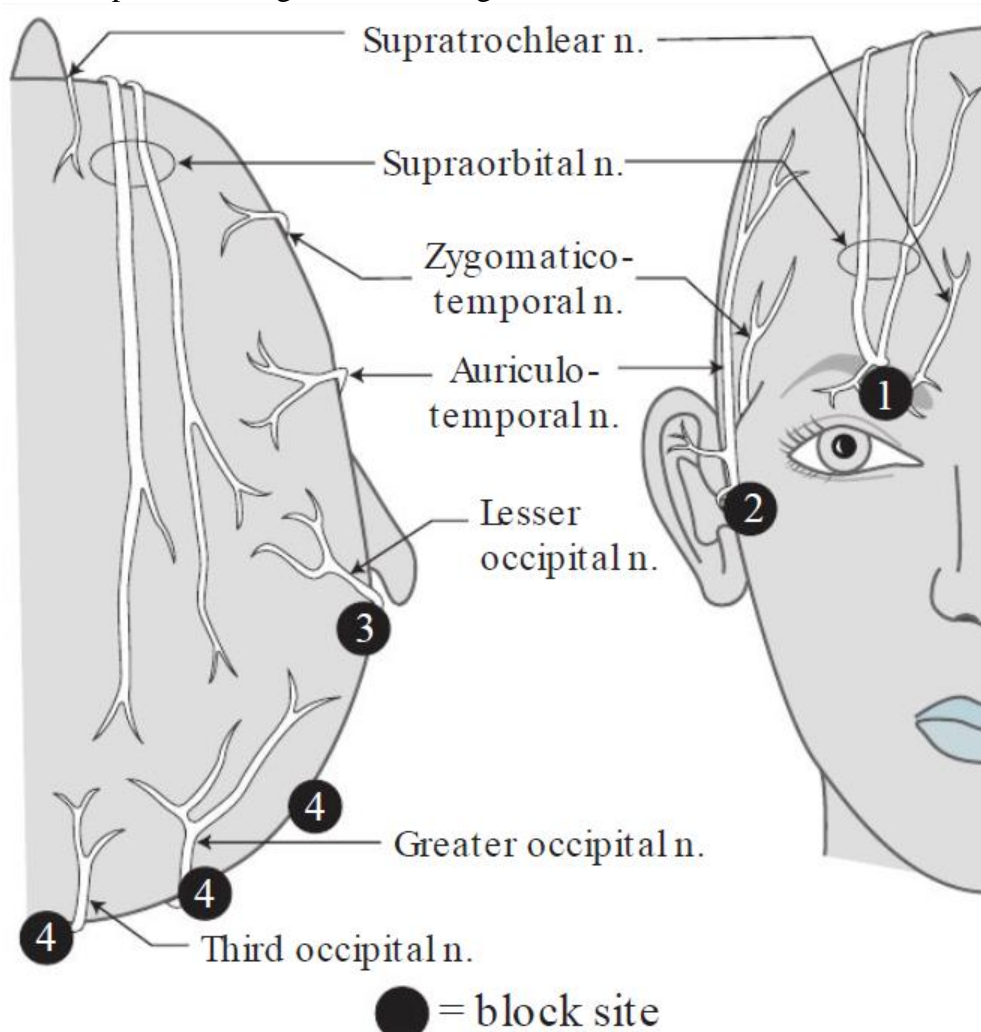
Ott C "The impact of sedation on brain mapping: a prospective, interdisciplinary, clinical trial." Neurosurgery. 2014 Aug;75(2):117-23

- patient should be advised that there may be some pain involved.
- if patient was not on anticonvulsants preoperatively, therapeutic load of AED should be administered.
- 20% **MANNITOL** IV - **maximum 0.5 g/kg**; higher doses will cause nausea and vomiting.
- **paralytics** cannot be used (other than for induction).
- general anesthetic mapping cases - **inhalation anesthetics** must be minimized.
- **language mapping** – only **PROPOFOL** and/or **DEXMEDETOMIDINE** - facilitate mild sedation during opening and closing, and maximum cooperation during mapping and resection phases; no narcotics* or additional anesthetic medications!
 - *thus, good **field block** with 0.25-0.5% bupivacaine + 0.5-1% lidocaine + 1:200,000 epinephrine before draping – along incision, base of scalp flap, ± nerve blocks (e.g. supraorbital, occipital).
- **laryngeal masked airway (LMA)** may be employed depending on patient and preferences of anesthesiologist.
- **dura is pain sensitive!**
- as the dural opening is begun, the desflurane is turned off and remifentanyl infusion of 0.1–0.2 mcg/kg/min IV is started.
- by the time the dural opening is completed, the desflurane has usually worn off and the LMA can be removed
- remifentanyl is then titrated for pain control (neurophysiologic testing can usually be performed at this time).
- the operation may often be carried to completion with the patient awake, although once the intracranial part of the operation is completed, more pain relief may be desired and general anesthesia may be needed for pain control or agitation (LMA may suffice here).

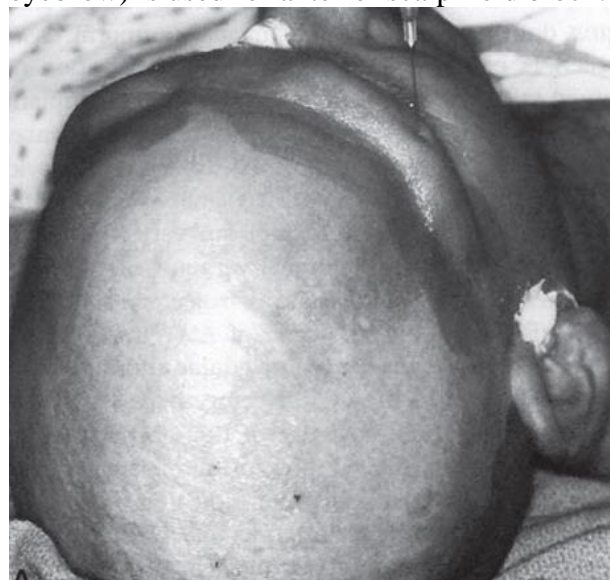SCALP REGIONAL ANESTHESIA

After induction of propofol or midazolam sedation, without intubation, the local anesthetic field block is placed - the **preauricular, postauricular, supraorbital, and occipital** nerves. By starting at these points, placement of the remainder of the block is less painful.

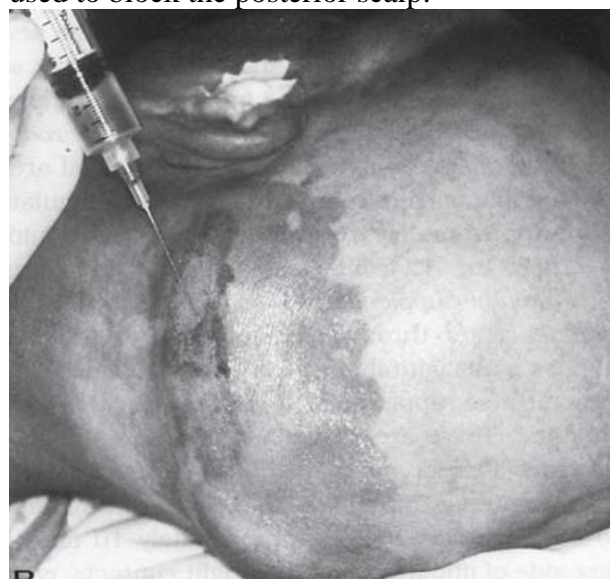- 1) supraorbital & supratrochlear nerves: 2 ml injected 1.5 cm above the supraorbital foramen above the medial third of the orbit. NB: if you are going to use surface matching to register the patient for image guidance (e.g. BrainLab or Stealth), injecting here may deform the skin and affect the registration accuracy. Consider injecting a lower volume of higher concentration agent (e.g. 2% lidocaine)
- 2) auriculotemporal nerve: 5 ml injected 1.5 cm anterior to the tragus. □ Caution: to avoid anesthetizing the facial nerve, inject just deep to the subcutaneous tissue
- 3) postauricular branches of the greater auricular nerve: 2 ml 1.5 cm posterior to the antitragus.
- 4) greater, lesser & third occipital nerves: inject 5 ml with a 22 gauge spinal needle at the mastoid process and proceed along the nuchal ridge until the midline is reached



The entry point of the one-inch, 25 gauge needle (just superior to the lateral aspect of the right eyebrow) is used for anterior scalp field block:



The entry point for the 1 inch, 25 gauge needle (halfway between the root of the mastoid and theinion) used to block the posterior scalp:



POSITIONING

- significantly more time must be spent on patient positioning to ensure that they will be as comfortable as possible without moving.
- extra padding is employed.
- access to the patient's face is necessary for the anesthesiologist and the neurophysiologist.
- patient supine with head on horseshoe headholder; **legs and head of bed elevated.**
- **Mayfield pin head holder** is applied using local anesthesia (*use 80 lbs for awake patients* to avoid pin slip); alternative – use **AxiEM** or **Neuro FrameLock** systems without pinning. see p. Op30 >>
- the patient's **head must always be lateral or angled slightly above the horizon** so that the airway is well protected and the patient can see the computer screen. Attention is directed toward positioning the head to optimize the patient's airway during sedation.

CRANIOTOMY

- standard temporal or frontal craniotomy, but opening must provide access to all areas to be mapped.
- warn **pathologist** not to announce frozen path results over loudspeaker.
- some patients awaken confused or slightly combative - *dura is not opened until the patient is completely awake and calm.*

MAPPING PRINCIPLES

For mapping in EMU – see p. E13 >>

Resources to read:

1. Keles GE, Berger MS. Functional mapping, in Berstein M, Berger MS (eds): *Neuro-oncology: The Essentials*. New York: Thieme Medical Publishers, 2011.
2. Yingling CD, Ojemann S, Dodson B, Harrington MJ, Berger MS: Identification of motor pathways during tumor surgery facilitated by multichannel electromyographic recording. *J Neurosurg* 91:922–927, 1999
3. Keles GE, Lundin DA, Lamborn KR, Chang EF, Ojemann G, Berger MS: Intraoperative subcortical stimulation mapping for hemispherical peritumoral gliomas located within or adjacent to the descending motor pathways: evaluation of morbidity and assessment of functional outcome in 294 patients. *J Neurosurg* 100:369–375, 2004
4. Berger MS, Cohen WA, Ojemann GA: Correlation of motor cortex brain mapping data with magnetic resonance imaging. *J Neurosurg* 72:383–387, 1990
5. Berger MS, Ojemann GA: Intraoperative brain mapping techniques in neuro-oncology. *Stereotact Funct Neurosurg* 58:153–161, 1992
6. Berger MS, Ojemann GA, Lettich E: Neurophysiological monitoring during astrocytoma surgery. *Neurosurg Clin N Am* 1:65–80, 1990
7. "Cortical Mapping" by Dr. Marcio Sotero de Menezes, University of Washington, Seattle, WA. Presented by Seattle Science Foundation.

Click here to view: [Cortical Mapping](#)

EQUIPMENT

- **iced irrigation fluid** and IV **MIDAZOLAM** (to abort seizures during cortical stimulation).
- **brain diagram** for drawing electrode montage on the brain.
- 15-30 small (3 to 5 mm) paper numbered **tickets**; also use **4-0 silk** on pia to outline resection area.
- Ojemann Cortical Stimulator.
- [for language mapping](#):
 - 1) Grass CE-1 electrode holder (Grass Technologies, West Warwick, RI) and cortical electrodes.
 - 2) EEG machine.
 - 3) slide projector (or computer slide show) with 50-100 object drawings, presented at a rate of one object every 3-4 seconds (depending on patient's verbal ability).
- [for somatosensory evoked potentials](#): 8-contact strip electrode (with cable and connector), SSEP machine.
- [bipolar stimulator](#): 1 mm at its tips, separated by 5 mm.

AFTER DISCHARGE (AD) THRESHOLD DETERMINATION

- determining the AD threshold helps to prevent evoking clinical seizure activity and false localization.

"Afterdischarge potentials indicate that the current is too high and needs to be decreased to avoid unreliable mapping and cortical spread of stimulation."
- using bipolar stimulator, beginning at **1.5-2 mA current**, stimulate 3 to 5 areas of brain region to be mapped, calling out **nearest cortical electrode** to EEG team to record; several spots on the cortex are stimulated for the **same duration as the planned** object image presentation epoch (3 or 4 seconds).
- watch EEG for ADs: if none, **increase current by 2 mA increments until ADs are elicited** (this is AD threshold).
- **current 1-2 mA below AD threshold is used for mapping.**
- if either **persistent ADs** or a **frank clinical seizure** occurs, the brain is irrigated with **iced irrigation fluid**;
 - if a seizure persists, **MIDAZOLAM** is administered in 1- to 2-mg increments until clinical seizure activity ceases. It is very rare to evoke seizures that persist or become problematic for continued mapping.
 - if a seizure persists, despite reasonable doses of midazolam and irrigation of the brain with cold fluid, an **airway should be placed** and the seizures stopped with other drugs as needed.

Greenberg

- once cortex is exposed, a recording electrode strip is place on the brain surface
- using a bipolar stimulator, start with a low current (e.g. 2 mA) and begin stimulate an area of cortex for 3–5 seconds, and observe for afterdischarges (akin to a focal seizure) on the recording strip. If no afterdischarges, increase the current in 2 mA increments up to a maximum of ≈ 10 mA. If afterdischarges occur, back off by 1–2 mA and then map that area.

CORTICAL STIMULATION

- **BIPOLAR METHOD** - current passes between two electrodes and stimulates cortex in more precise control.
- if surgeon is willing to operate on awake patients, mapping and resection can take place during same craniotomy - **movable bipolar electrode stimulator** is used on exposed cortex - observing responses (movements, sensory feelings, language arrest).
 - **motor responses** are contractions of muscle groups
 - **sensory responses** are perceived as tingling, vibration, light flashes, buzzing or ringing.
- at the same time stimulated cortex is so completely occupied with electrical intrusion that it is not available for normal function ("**BUSY LINE EFFECT**"):
 - if patient attempts to use extremity involved in motor stimulation sequence, patient will be unable to do so.
 - functional speech areas are inactivated; e.g.:
 - if current blocks language* (positive result) - underlying cortex is eloquent for language and spared at time of resection;
 - if language is not blocked* (negative result) → current strength is progressively increased to, if possible, threshold for afterdischarges.
- stimulation of **association areas** does not produce activated response;
- in **epileptogenic zones**, stimulation may activate circuits habituated by epileptic discharge (responses may be of perceptual illusions, "déjà vu", memory of previous events).

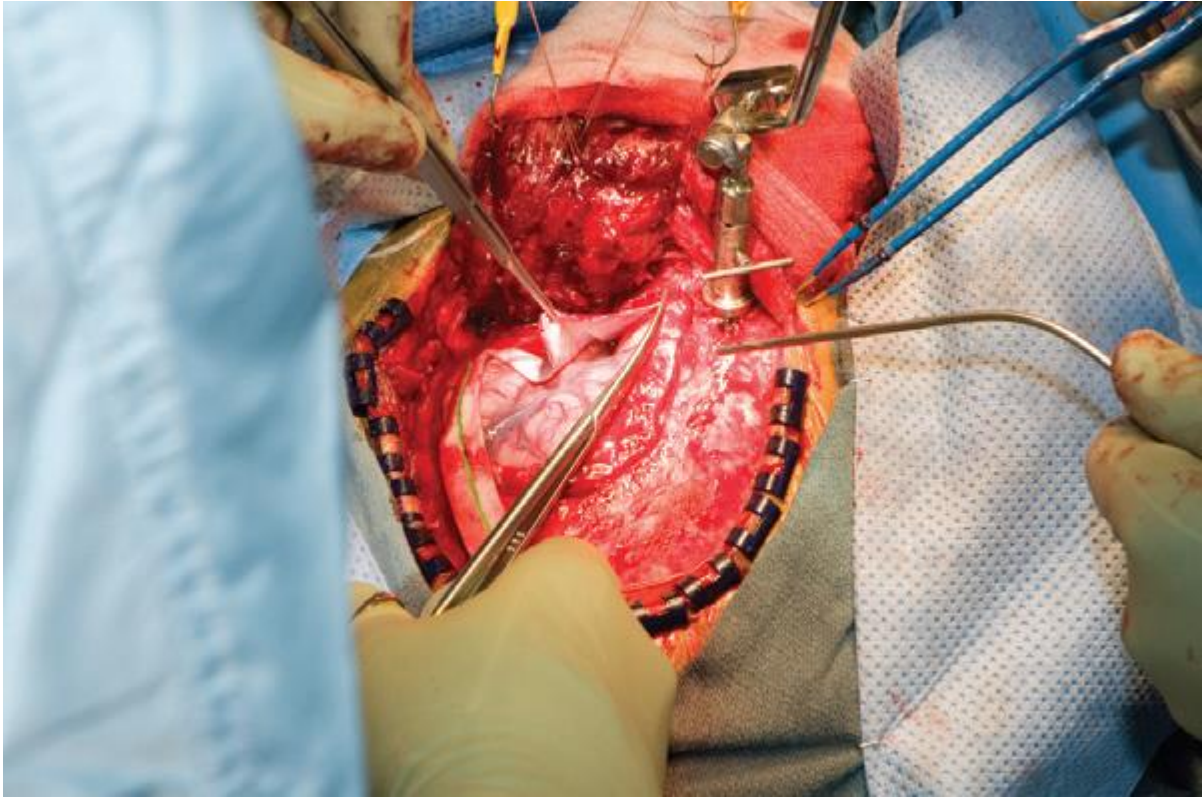
Parameters:

- amplitude of 1-20 mA* (established after AD determination); if a voltage based unit is used, start at 1 volt and increase.
- *for awake mapping, max. 6-10 mA (vs. asleep can go up to 16-20 mA).
- biphasic square wave pulses (1.25 ms per phase)
- deliver in 2-4-second trains
- frequency of 1-60 Hz (60-100 Hz for language mapping)

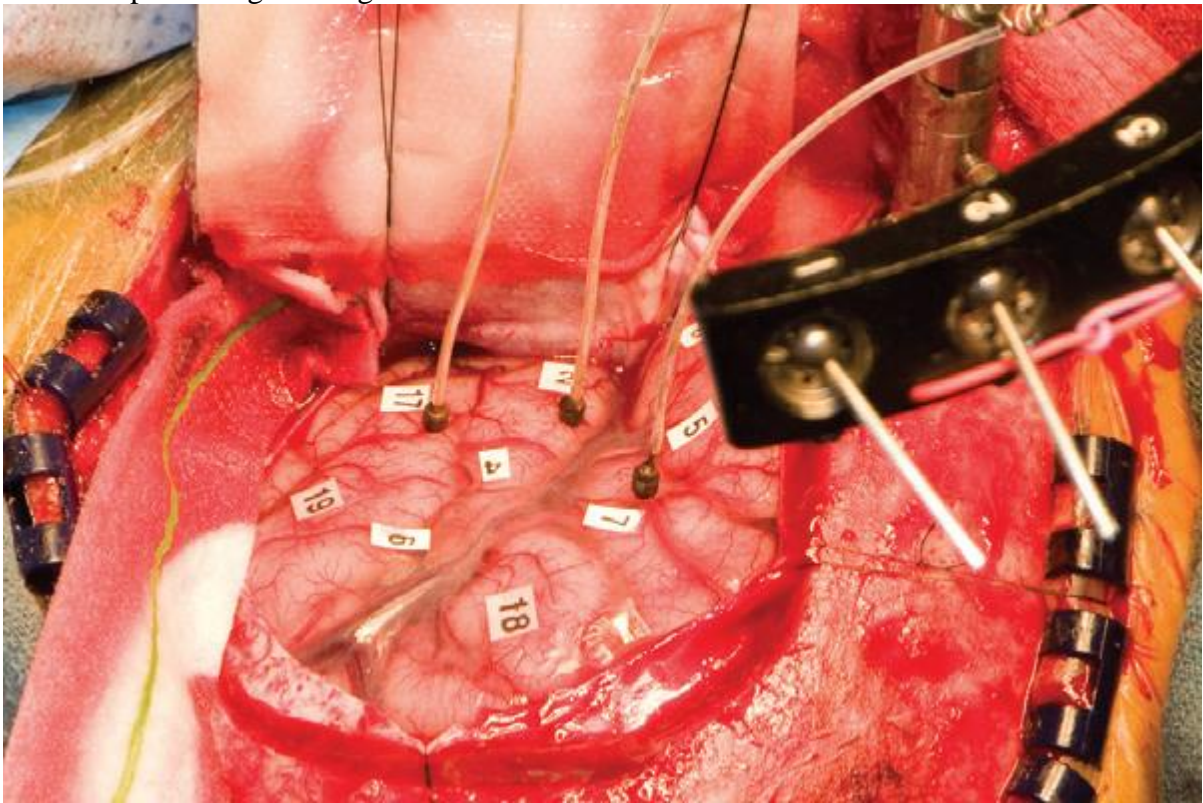
N.B. each cortical site is checked three times to ensure accuracy; avoid **stimulating the same area repeatedly** without a pause to prevent seizures.

- to hold the electrode - an **epidural post**, two options:
 - a) clamps to the skull

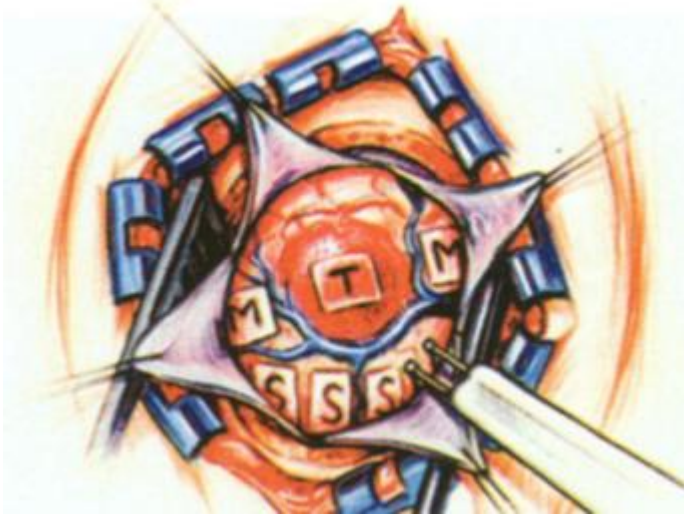- b) screws into the bone (e.g. CE-1 electrode holder) - more stable and avoids potential epidural bleeding:



- after the brain is exposed, cortical electrodes are placed on the brain surface, followed by small numbers that identify which area has been stimulated; there are also many electrode options available, including carbon-tip electrodes (as shown), cotton-tip electrodes, and strip/grid electrodes. We prefer carbon-tip electrodes because they maintain good contact with the cortex while permitting the surgeon excellent access for cortical stimulation:



- stimulation mapping utilizing bipolar electrode to stimulate cortical surface. When motor cortex is stimulated with sufficient current, involved extremity can be observed to contract. As mapping proceeds, small tabs are placed on brain to identify primary motor regions (M), primary sensory cortex (S), and tumor (T):



SUBCORTICAL MAPPING

(e.g. cerebral peduncle mapping)

- use the same (or 1-2 mA higher) current needed for evoking movements with cortical stimulation.

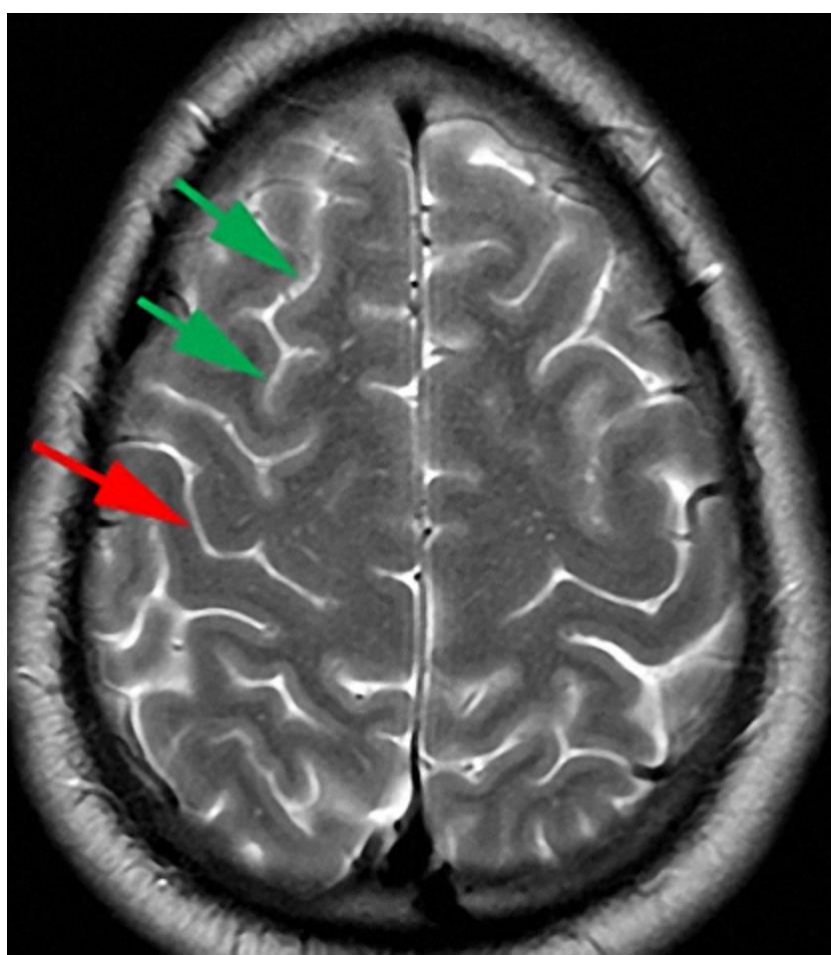
REDO CRANIOTOMIES

- if the dura is adherent to the underlying cortex and cannot be mobilized without a potential risk of pial injury, subcortical mapping is instrumental in mapping and monitoring function. Transdural cortical mapping is an option, but not very reliable.

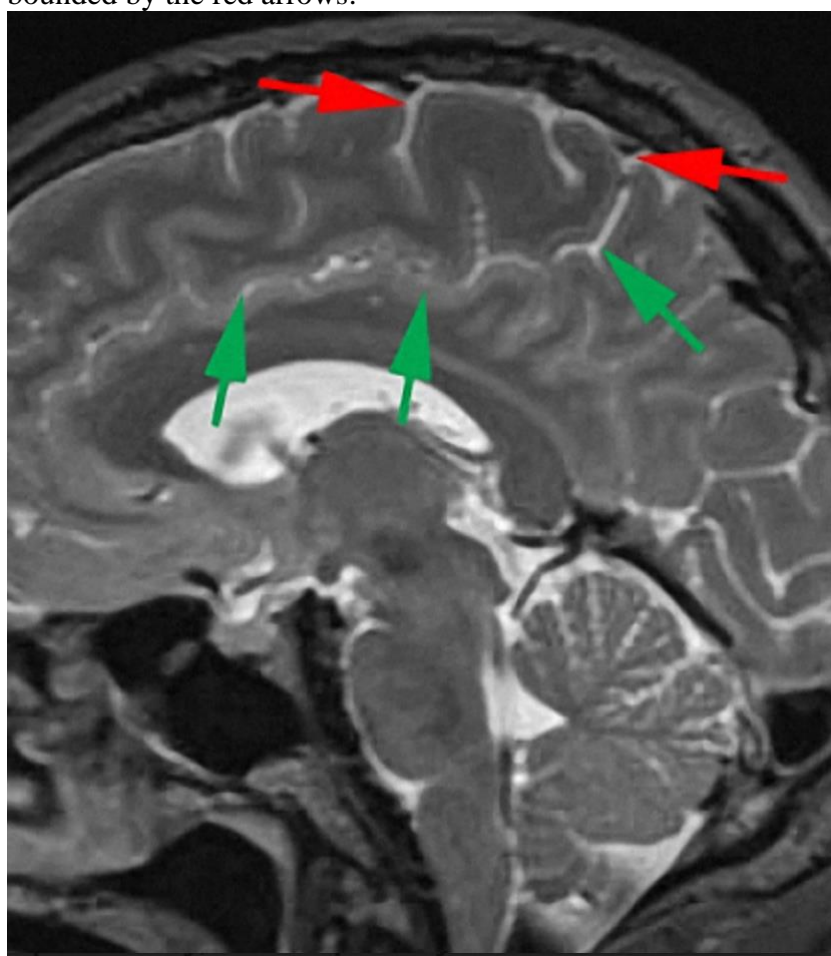
ANATOMICAL LOCALIZATION ON IMAGING

Methods to localize central sulcus (Dr. Aaron-Gadol >>>)

The second, more posterior vertical sulcus, from the end of the horizontal superior frontal sulcus (green arrows) is the central sulcus (red arrow):



Trace **cingulate sulcus** (green arrows) on midsagittal MRI images posteriorly, then superiorly (**marginal sulcus**) to its end. The marginal sulcus is just posterior to the **rolandic cortex** (central lobule) bounded by the red arrows:

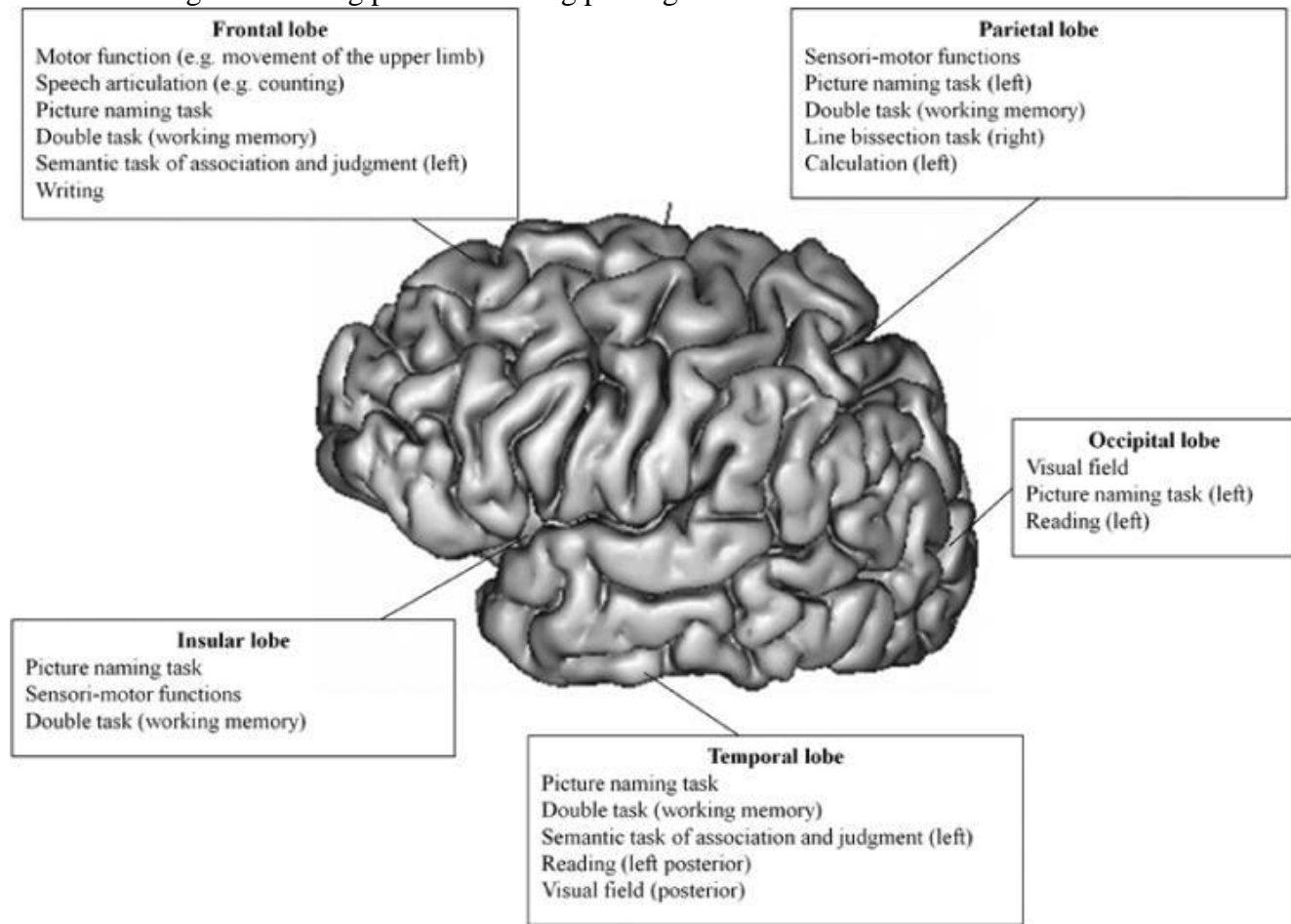


TESTING PARADIGMS

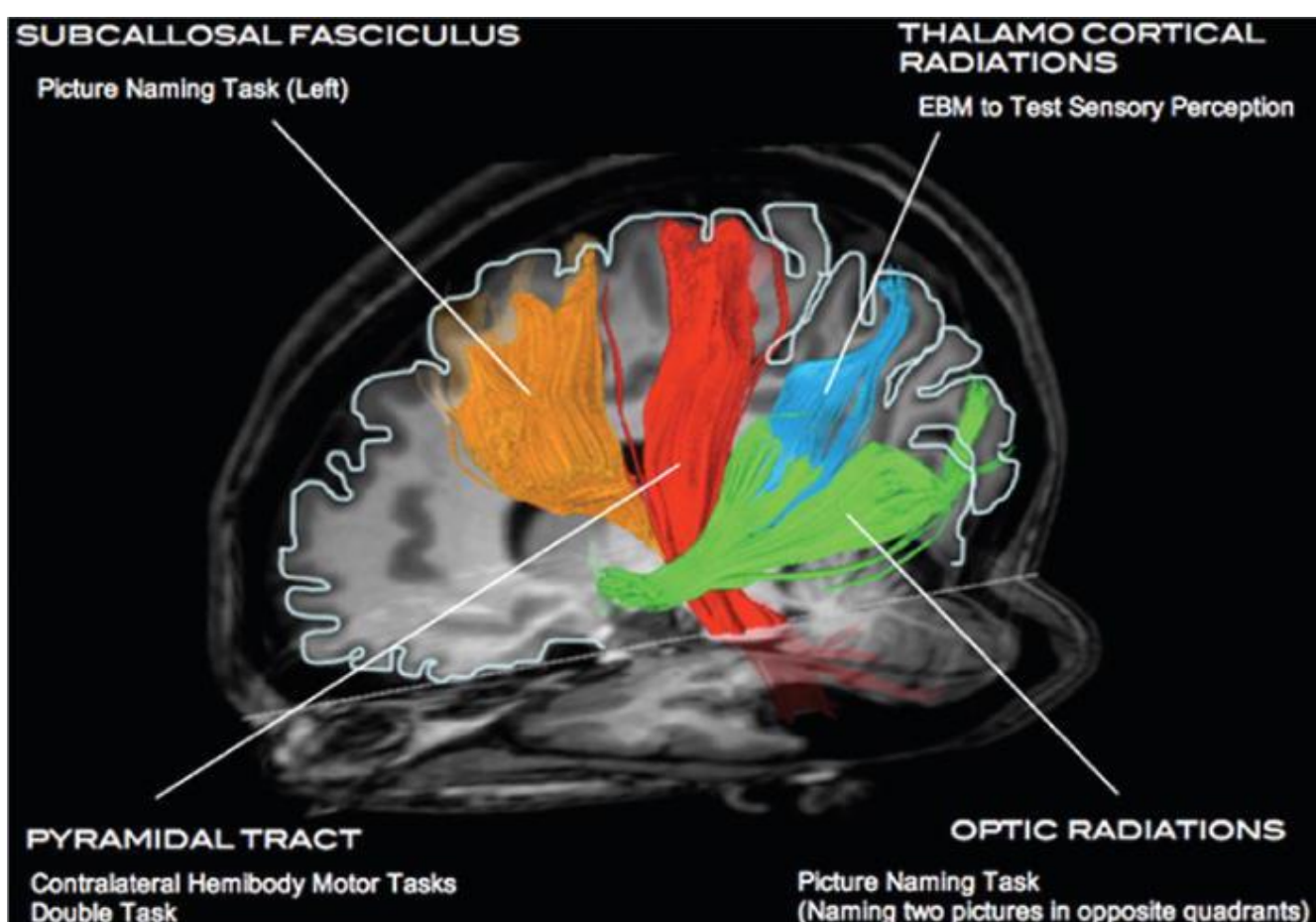
Excellent article:

Coello et al “*Selection of intraoperative tasks for awake mapping based on relationships between tumor location and functional networks*” published online September 20, 2013; DOI: 10.3171/2013.6.JNS122470.

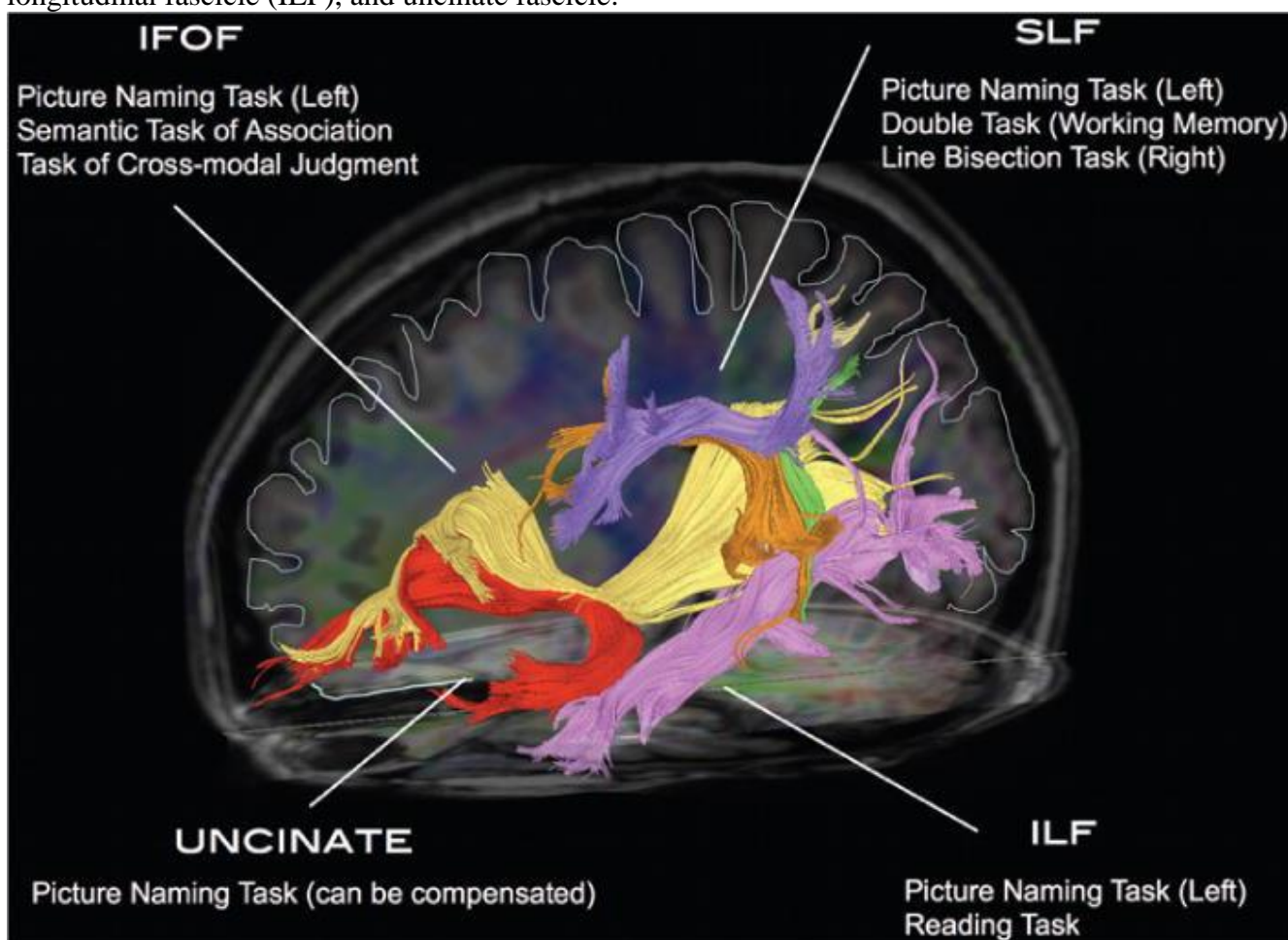
Schematic diagram showing preferred testing paradigms for each site:



Proposal of intraoperative tasks based on relationships between tumor location and white matter connectivity: projection pathways (pyramidal tract, thalamocortical radiations, optic radiations) and subcallosal fasciculus:



Proposal of intraoperative tasks based on relationships between tumor location and association pathways: inferior frontooccipital fascicle (IFOF), superior longitudinal fascicle (SLF), inferior longitudinal fascicle (ILF), and uncinate fascicle:



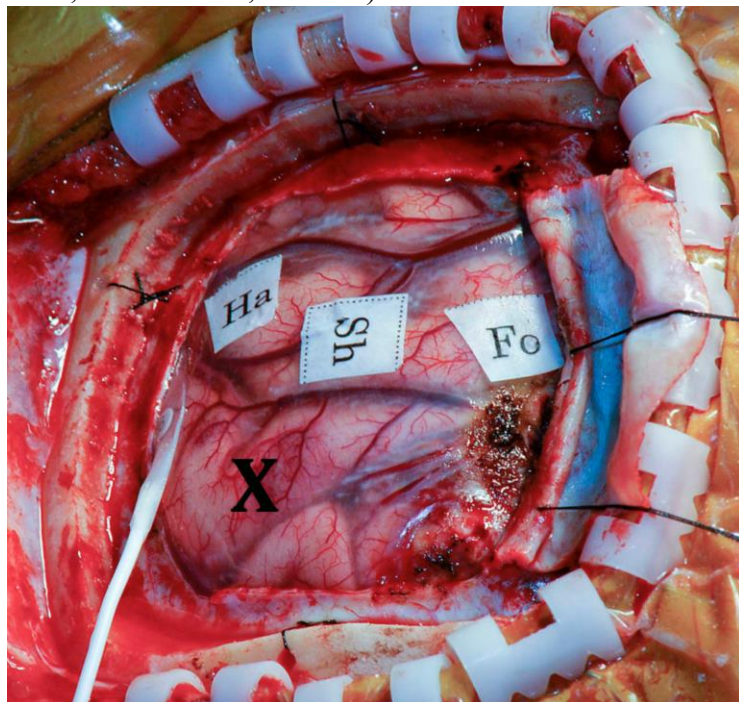
MOTOR MAPPING

- anesthesia - can be performed in **awake** or **asleep** patients.
- if (short-acting) paralytics are used, it is critical to reverse these agents 15–30 minutes prior to applying the electrical stimulation and that a train-of-four muscle twitch can be elicited.
- establish current - can be performed *with or without concomitant electrocorticography (ECoG)*:
 - a) *when using ECoG* (3 electrodes are placed on the neck as reference for EEG), stimulate with increasingly higher currents until **after discharges (ADs)** are noted, use current 1-2 mA below AD threshold for mapping. *see above >>*
 - b) *when not using ECoG*, begin stimulation mapping at 2 mA and increase current by 1-2 mA until **movement** is evoked.
- map - stimulate cortex with bipolar stimulator for 2-3 seconds, observing any movement of contralateral body.

Dr. Cohen-Gadol

<https://www.neurosurgicalatlas.com/volumes/brain-tumors/supratentorial-and-posterior-fossa-tumors/sensorimotor-mapping-for-glioma>

Mapping the motor cortex. A subdural strip electrode is used to detect afterdischarge potentials (Ha: hand; Sh: shoulder; Fo: foot). The location of the tumor is marked by “X.”



- nondominant face motor cortex may be removed, apparently resulting in only temporary facial weakness. I have personally removed gliomas that infiltrated the face area and witnessed complete return of facial function as long as the underlying white matter tracts for the adjacent motor cortices were left intact.
- resection of the cortices just anterior to the motor cortex can lead to transient hemiplegia/hemiparesis or supplementary motor area (SMA) syndrome.

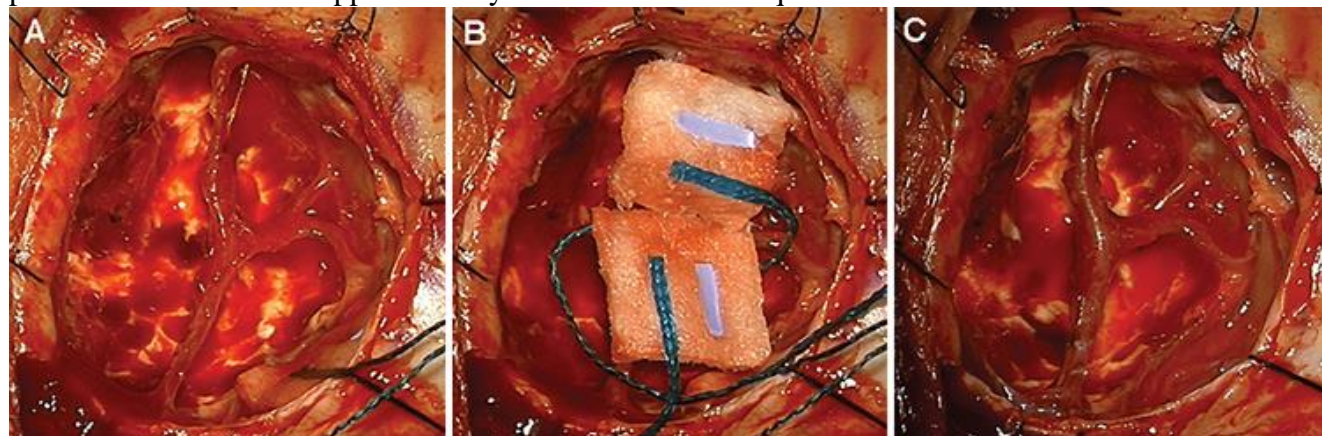
Dr. M. Berger recs:

For cases conducted under general anesthesia, standard neuromonitoring with electromyography was performed and the anesthesia team and surgical assistants watched for motor responses. For awake motor mapping cases, the patients were awake, alert, and following commands and provided verbal feedback at the time of motor mapping on whether they moved, in addition to the visual monitoring by the anesthesia team and surgical assistants.

Both cortical and subcortical stimulation was performed with a 1-msec constant-current square-wave pulse at 60 Hz. Stimulus intensity was typically started at 1 mA and increased up to 6 mA for awake cases until a motor response was identified. For asleep cases, stimulus intensity was increased up to 16 mA, in 2-mA increments, until a motor response was identified. The location was considered a negative site if there was no response at 6 or 16 mA, in awake and asleep conditions, respectively. Resection was carried out with the intent of a maximal resection until positive cortical or subcortical mapping sites were reached. At this point, if the patient was under general anesthesia, the resection was stopped. However, if the patient was awake, he or she was asked to move the body part that was positively stimulated. Subsequently, the resection was continued, a millimeter or so at a time, until the patient's function diminished slightly and then the resection was stopped.

Ischemic events can be caused either directly by coagulating an en passage small arteriole or indirectly when there is vasospasm within or adjacent to the resection cavity. Great care must be taken during the resection, and the **bipolar cautery** is now used sparingly, if at all, to avoid the direct injuries. In cases with vasospasm, the spastic artery or arteriole can be seen directly under the microscope and often occurs when resecting a thin cuff of tumor at the margin. When this is seen, especially for a larger artery or arteriole, we administer **PAPAVERINE** on the vessel using a small patty during the procedure and remove it prior to closing the dura.

Case example of spastic artery in the resection cavity and use of papaverine to prevent distal ischemia. A: Spastic artery in resection cavity. B: Papaverine-soaked pledgets on the vessel. The pledgets were placed on the vessel for approximately 5 minutes. C: Subsequent vasodilation:



While either **asleep** or **awake** motor mapping is acceptable, **awake craniotomies are preferred**, especially in patients with any preoperative motor deficits, in order to try to obtain the most detailed cortical and subcortical map possible. In addition, performing the case with the patient awake allowed additional resection after the positive cortical site was identified until the patient developed a slight deficit. This allowed us to achieve greater extent of resection in each individual case than what would have been achieved if the patient were under general anesthesia.

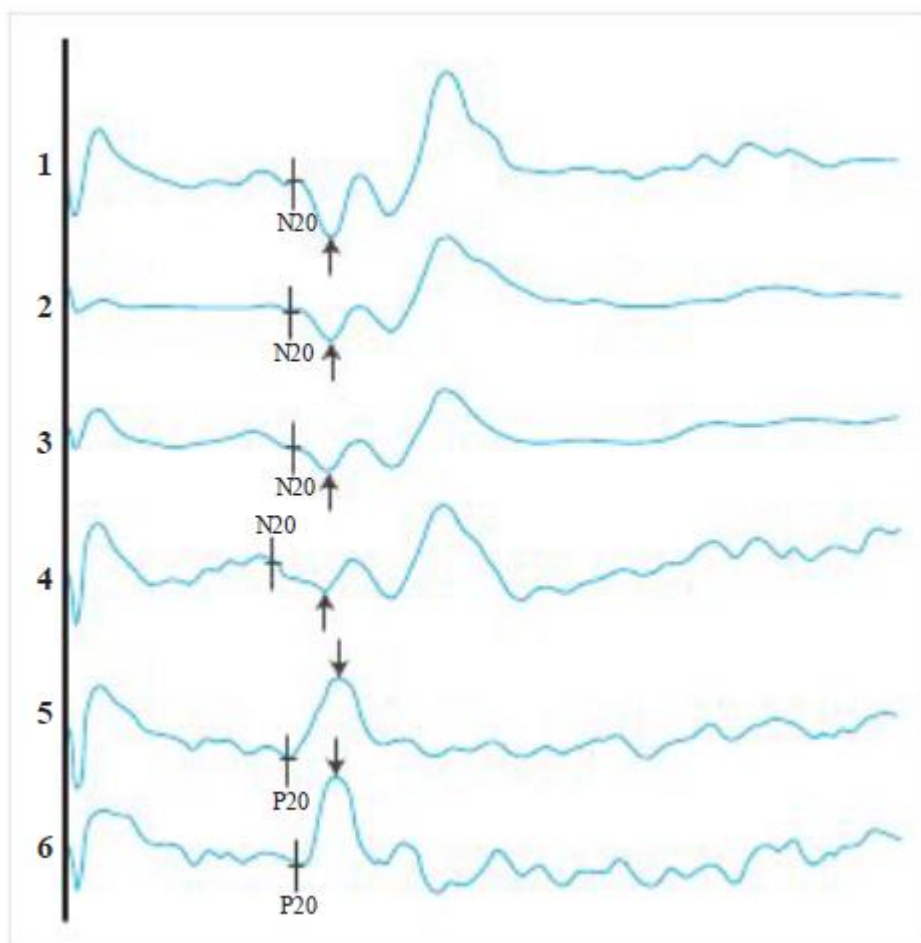
Monopolar stimulation is a valid alternative to the 60-Hz bipolar technique and brings with it a lower risk of intraoperative seizures, although the current spread is likely to be greater than with bipolar stimulation.

Greenberg 93.6.2

Phase reversal method for localizing primary sensory and motor cortex

Utilizes intra-operative SSEPs to localize primary sensory and motor cortex in patients under general anesthesia (as opposed to using brain mapping techniques in awake patients). A strip grid is placed on the surface of the brain perpendicular to the anticipated orientation of the central sulcus. SSEP stimulation is performed while recording through the strip grid. Phase reversal of the N20/P20 peak between a pair of electrodes in the strip grid indicates that those electrodes straddle the central sulcus (□Fig. 93.1) with primary motor cortex located anteriorly, and sensory cortex posteriorly. The grid is then repositioned and the test is run again to verify the findings.

Fig. 93.1 Phase reversal Intra-op 6-electrode recording strip placed on the brain during SSEP recording. Phase reversal of the negative N20 peak (arrows) to a positive P20 peak between electrodes #4 & 5 indicates that electrodes #4 & 5 straddle the central sulcus.



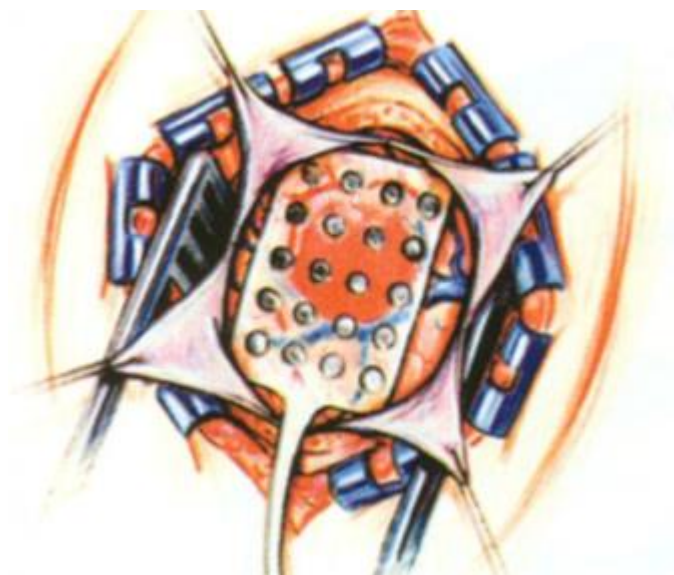
SENSORY MAPPING

- removal of or injury to the postcentral gyrus leads to disabling proprioception deficits. These deficits improve significantly over time, but some functional limitations in fine hand movement and gait will be permanent.

SOMATOSENSORY EVOKED POTENTIALS (SSEP) MAPPING

- **anesthesia** - can be performed in **awake** or **asleep** patients with minimal muscle paralysis.
- median nerve or tibial nerve stimulating electrodes are placed contralateral to hemisphere where SSEP testing is to be performed.
- place 8-contact strip or grid electrode in transverse (axial) orientation, traversing presumed central sulcus (i.e. right angle to the central sulcus).
 - for bipolar montage, note phase reversal to identify somatosensory cortex.
 - for median nerve referential montage, note N20 (somatosensory gyrus) and P22 (motor gyrus)
- move strip electrode and repeat procedure to verify accuracy.
- because the brain is not being directly stimulated, **seizures cannot be evoked** with SSEP mapping.

4 x 5 grid is placed on cortex for somatosensory evoked potentials, each 1 x 5 strip is sequentially activated in effort to identify phase reversal that will localize position of central sulcus and primary motor and sensory cortices:



SENSORY MAPPING

- **anesthesia** - requires **awake** patient (vs. SSEP mapping – can be also done asleep).
- **establish current** - can be performed with or without concomitant electrocorticography (ECoG) – *see above >>*
- **map** - stimulate cortex with bipolar stimulator for 2-3 seconds, having patient report after each stimulation epoch any sensation in the contralateral body.

LANGUAGE MAPPING

Neurosurgical atlas (pending):

<https://www.neurosurgicalatlas.com/volumes/brain-tumors/supratentorial-and-posterior-fossa-tumors/language-mapping-for-glioma>

There are two ways of language mapping:

- fMRI** and/or **passive ECoG** – show **critical** and **participating** cortex
 - ESM** (electrocortical stimulation mapping) – delineates **critical** cortex – thus, used as a gold standard to guide resections.
- **anesthesia** - patient must be **awake** and **cooperative** (only anesthetic agents that may be used are narcotics).
 - employ **neuropsychologist** to assist.
 - cortical electrodes are placed 2-3 cm apart, covering area to be mapped; electrode positions are drawn on the brain diagram, which is passed off to EEG team for EEG montage creation (typically arranged anterior to posterior and superior to inferior).
 - numbered tickets are placed 1 cm apart, covering area to be mapped.
 - numbered ticket closest to area stimulated is called out following stimulation and recorded.
 - **cortical threshold** is determined by responses in lower sensorimotor strip (N.B. speech testing response cannot be considered negative unless stimulation current threshold has been established by reproducibly positive responses elsewhere in same patient).
 - stimulation using **balanced biphasic square wave pulses** (50-60 Hz, 0.5-4 ms peak-to-peak, and 2-16 mA per phase) is administered via **bipolar electrode** with 5-10 mm interelectrode distance.
 - while patient is performing language task, current is applied to cortex prior to display of object, continuing until task is performed correctly or next task appears.
 - patients over age \approx 40 usually need reading glasses to see written material, and they should have their own available in the O.R., although the temples (earpieces) usually can't be accommodated.

Language tasks:

- naming objects** presented for a 3-4-second duration (rehearsed preoperatively with the neurophysiologist)
 - following** simple and complex **commands**
 - comprehension, **repetition**, spontaneous speech.
 - have patient **to count** while intermittently stimulating frontal cortex anterior to motor cortex.
 - **interruption** or **perseveration** of counting is indicative of local cortical involvement in speech → identify sites by numbered tickets.
 - automatic verbalization, such as counting, is robust and may persist!!!
 - language tests for representation in temporal lobe - have patient to perform **recitation of rhyme** (gives more reliable results than counting).
 - **arrest, alteration of cadence, phonemic / semantic / syntactic errors** are indicative of speech representation in stimulated area.
- object naming errors define areas of essential language cortex; this may be evidenced by complete speech arrest, significantly slowed speech, or paraphasic errors.
 - **spread of epileptiform discharges** from nearby regions of brain, however, **can confound** identification of regions of primary language cortex; H: **subdural grids** - used to monitor after discharge potentials to exclude this possibility.
 - many people have **multiple language areas** - finding one language area in either the temporal lobe or the frontal lobe does not mean that mapping is complete - the entire area at risk should be mapped.
 - occasionally, there will be **additional isolated area of speech** in temporal cortex (separate from, and some distance anterior to, remainder of temporal speech area); interference with speech from stimulation of this area may be transmitted (H: place cottonoid pledget soaked with 0.5% **LIDOCAINE** without epinephrine over convolution at that point for 5 min - if there is no interference with spontaneous speech or recitation, area may be safely resected).
 - in **multilingual patients**, **each language** must be mapped.
 - injury to the native tongue would disrupt all language function.
 - injury to secondary languages would not affect the native language.

N.B. mapping is only the first step - during resection, the surgeon must **avoid injuring subcortical connections and vascular structures**. When in doubt, the patient should be kept awake and continue the object-naming task until the risk period is over.

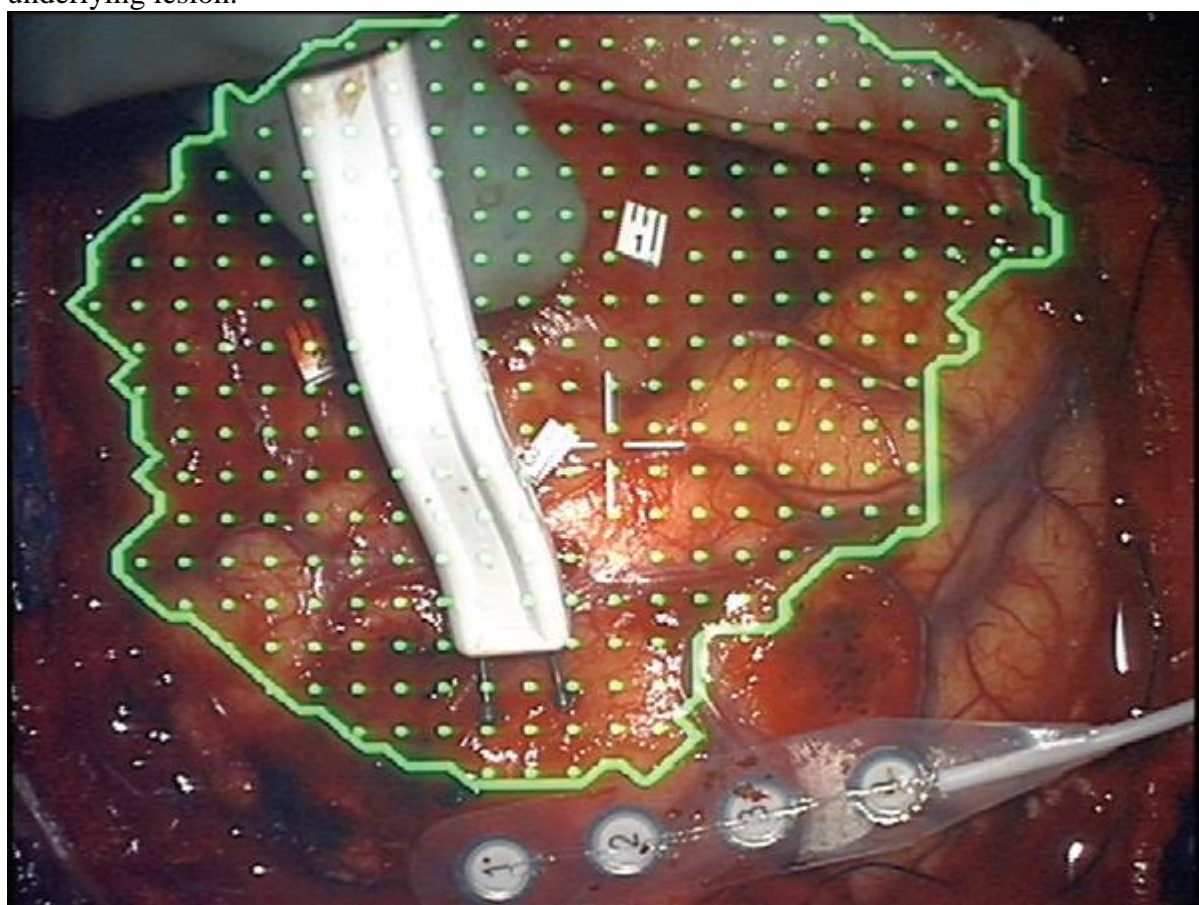
- if the surgeon cannot find the language area, the patient should continue object naming throughout the resection.

Youmans p. 782

Language mapping requires an awake craniotomy, and with an experienced team, this approach can be used routinely in an efficient and safe manner. Numerous descriptions of awake craniotomy techniques have been published.^{13,16} A handheld bipolar stimulator consisting of 1-mm electrodes with a separation of 5 mm is used to apply a 5-second, 60-Hz, biphasic square-wave constant-current or constant-voltage stimulus at sequential sites across the exposed cortex of interest, beginning with low-stimulation parameters and gradually increasing the stimulation intensity until either language is

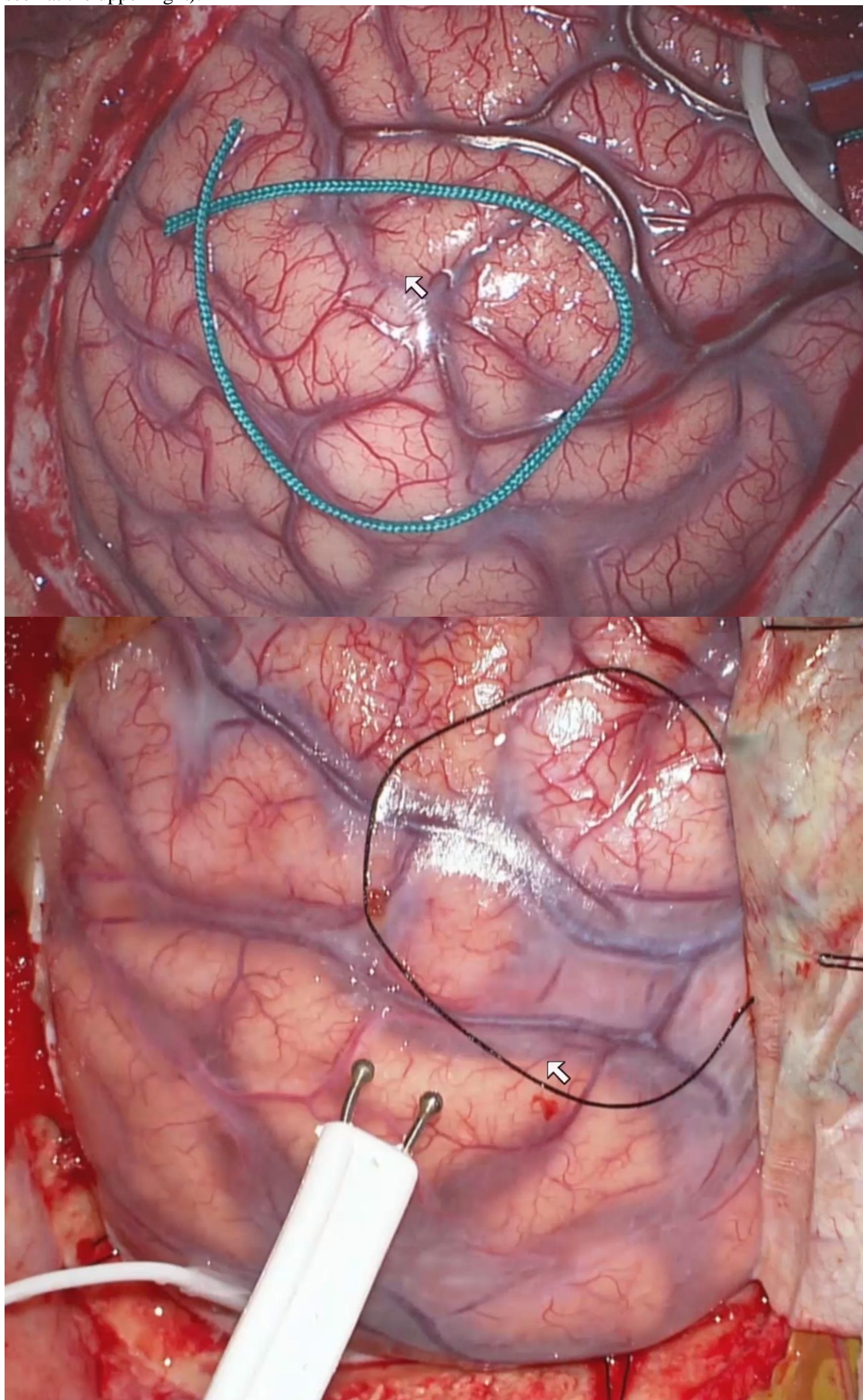
disrupted or the maximal subthreshold for afterdischarges is reached (Fig. 64-2). Adjacent electrodes monitor the cortex for afterdischarges, and cold irrigation or intravenous propofol is available as needed to manage stimulation-induced seizures. Broca's area is most easily identified, with arrest of speech during counting being readily elicited; speech interference by a direct motor response must be excluded. Beyond Broca's area, naming is assessed by using pictures of objects presented on an appropriately positioned computer screen during application of the stimulus. The cortex is investigated in this manner at approximately 1-cm intervals, with each site typically tested three times. Numbered labels are used to identify sites that have been tested, and intraoperative photographs can be used to document the results of the functional mapping procedure. Subsequent resections are generally kept a minimum of 1 cm from positive language sites, although this conventional dictum does not take into account sulcal patterns that may warrant its modification.

FIGURE 64-2 Functional mapping of language in the left temporal lobe with a handheld bipolar stimulator. Numbered tags identify previously tested sites. The green outline, superimposed on the surgical field with the heads-up display of a neuronavigation system, represents the boundary of an underlying lesion.

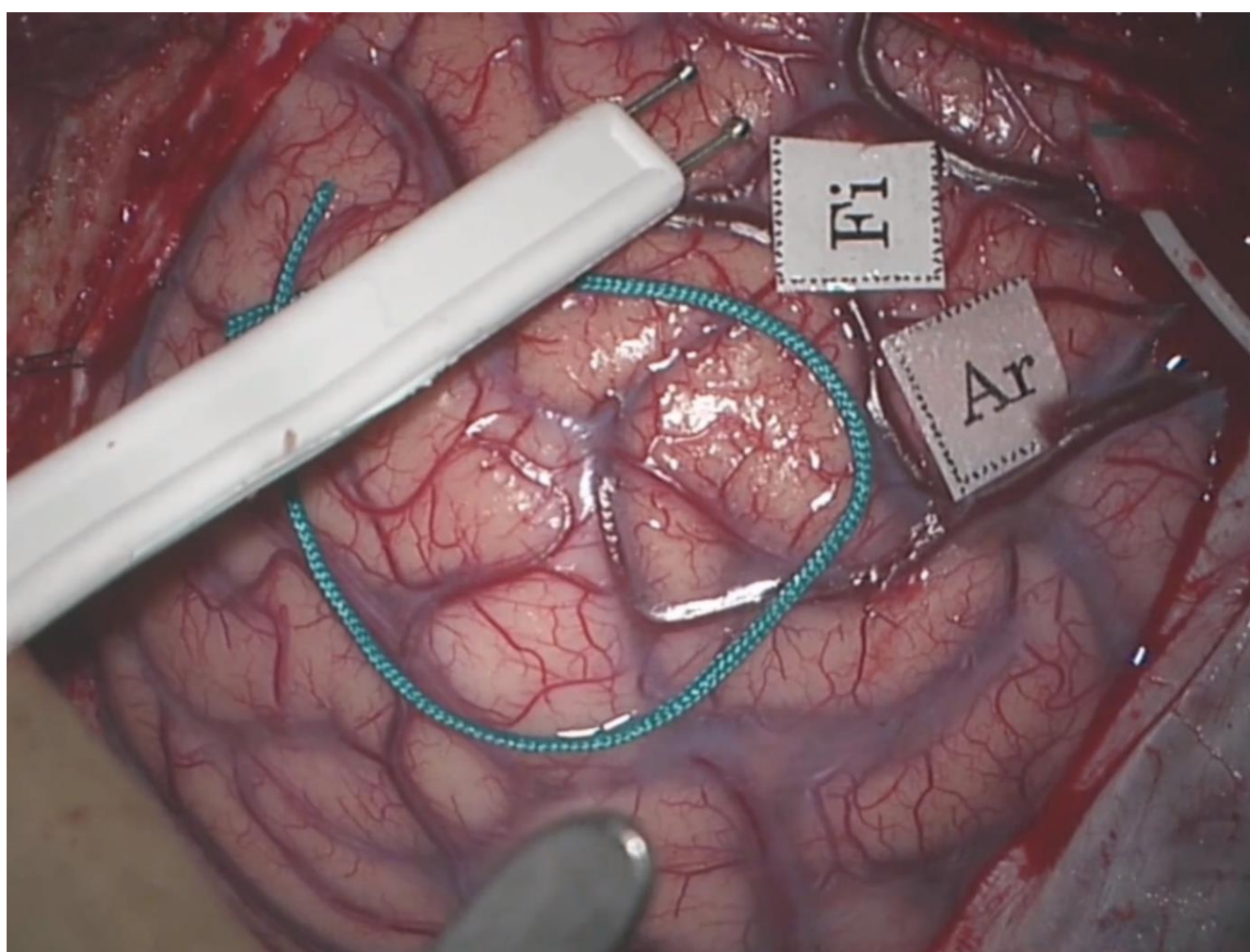


RESECTION TECHNIQUE

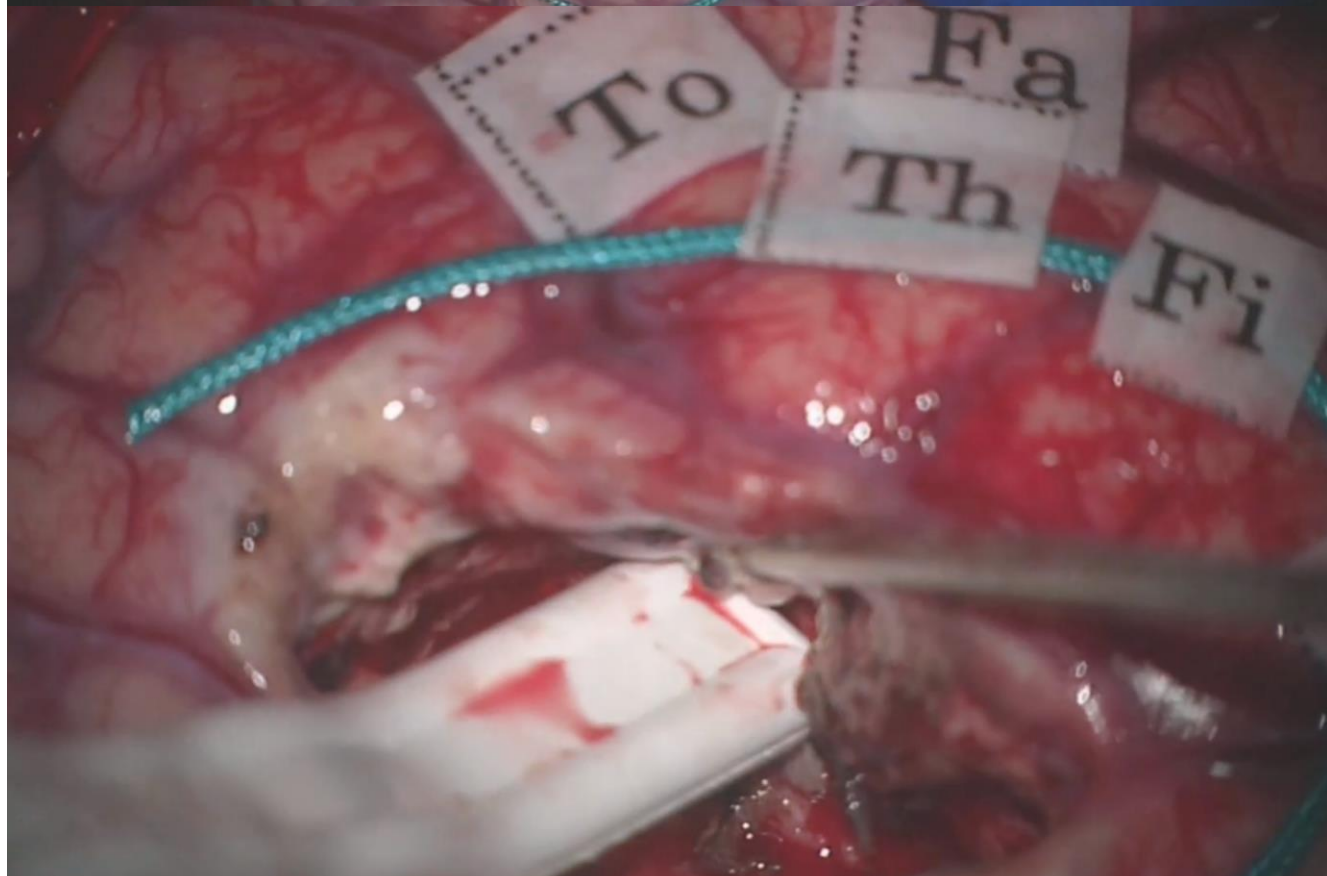
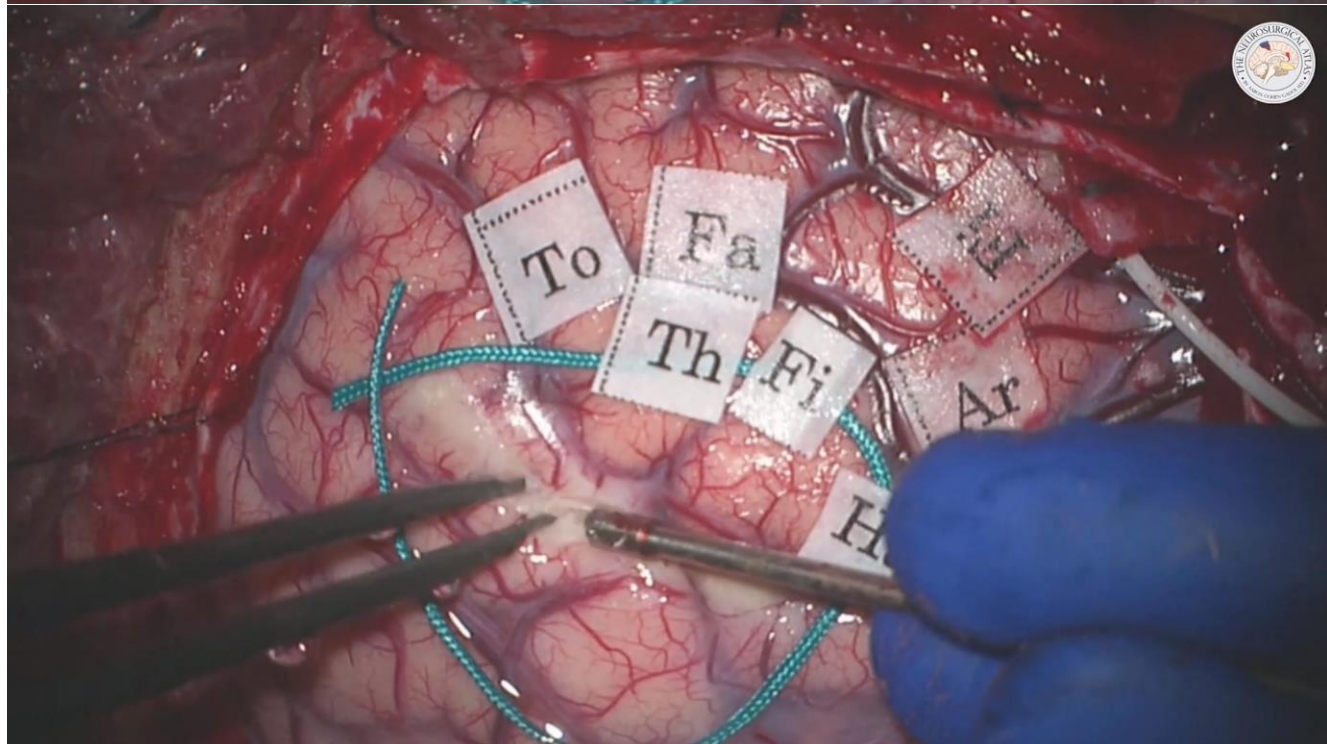
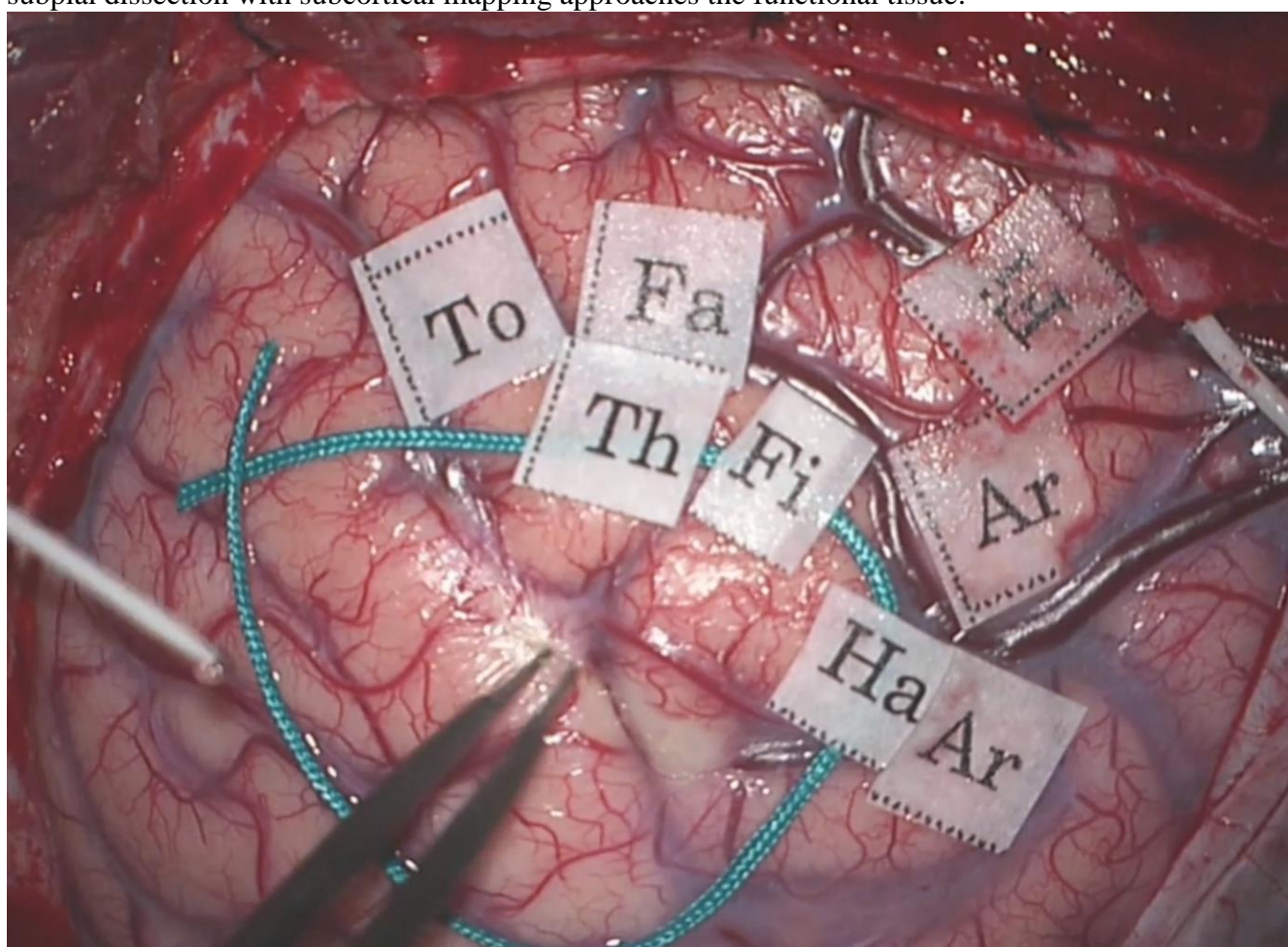
Using navigation and suture strip outline tumor on pila surface (recording subdural strip electrode is seen at the upper right):



Using bipolar stimulator and paper tickets map cortex:



Hand-finger area overlaps tumor; corticotomy is made away from functional cortex margin and later subpial dissection with subcortical mapping approaches the functional tissue:



COMPLICATION AVOIDANCE

- after mapping is complete, borders of the surgical resection are identified based on the operative goal and location of eloquent cortex. The surgical resection border is identified with silk suture. Resection proceeds with the patient again placed under propofol anesthesia for the remainder of the procedure. An exception is when the resection is very close to the language areas. In these

instances, the patient continues naming during the portion of the resection that is closest to the language area and then goes back to sleep.

N.B. **resections within 1 cm of language cortex** carry significant risk of permanent postoperative language deficits.

- when no functional area is found, it is best to assume that there may be technical problems with the mapping and proceed with the resection with patient performing the appropriate task, or design a resection that is safest without mapping data.

N.B. do not assume that absence of evidence (inability to locate a given function) is evidence of absence.

Development of any permanent* neurologic deficit can blunt or eliminate any survival advantage gained by resection.

*some deficits resolve over several weeks postop

- never undercut functional cortex.
- never sacrifice blood vessels subserving functional cortex.
- antibiotics are used for 48 hours after surgery because of the limitations on sterile draping of the surgical field during awake procedures.
- risk of temporary postoperative deficits of sensorimotor function is significant, especially with tumors directly infiltrating the sensorimotor cortices. If function is intact or mildly compromised at the end of the operation, but worsens on the first postoperative day, the opportunity for meaningful recovery is substantial. However, a significant decline at the end of the operation usually signifies an irreversible direct or ischemic injury. The most common reason for neurologic decline on the first postoperative day is subclinical seizures.

TRANSNASAL ENDOSCOPIC ACCESS TO ANTERIOR CRANIAL FLOOR

NREF video >>

INDICATIONS

Olfactory groove meningioma.

PREOP

- lumbar drain, leave clamped; Dr. Broaddus prefers no.
N.B. lumbar drain helps but does not save poor closure

DETAILS

- register for neuronavigation (e.g. Stryker mask)
- bilateral nasal cavities decongested with NeoSynephrine moistened pledgets.

ENT part – operative 0-degree endoscope:

- bilateral superior turbinate removal, partial superior posterior nasal septum removal, bilateral maxillary antrostomies and total ethmoidectomies
- nasoseptal mucosal flap is developed on intact vascular pedicle.
- ethmoidal cribriform plate drilled off with high speed diamond bur to create anterior skull base defect right under the tumor.

Neurosurgery part:

- coagulated dura → durotomy over the tumor with # 11 blade.
- tumor removed in piecemeal fashion using ring curettes and pituitary rongeurs.
- 30 degree endoscope to inspect the tumor cavity for additional tumor tissue.

ENT part - reconstruction:

- pack base of the tumor bed with AlloDerm patch, followed by septal cartilage patch, DuraSeal glue, and overlay of well vascularized nasoseptal mucosal flap again reinforced with DuraSeal glue.
- nasal passages packed with Gelfoam, followed by Merocel packings into both nostrils; packings were lubricated with bacitracin ointment and inflated with some saline.
- orogastric tube to decompress the stomach and suction out the oropharynx.
- deep extubation, no cough.

1980s – **free tissue grafts** (onlay, inlay) – success for CSF leak repair 90% on 1st attempt (96% on redo);

Gasket seal closure: fascia lata or AlloDerm (enfolded into bone defect), then vomer bone or Medpor, then cover gasket edges with Surgicel.

– avoid Medpor if will need radiation (rather use AlloDerm – integrates into tissues)

Button graft closure: grafts on both inside and outside of bone defect, grafts sutured together to keep in place.

Modern – **vascularized nasoseptal flap**; fed by sphenopalatine artery.

- 48 hrs cefazolin IV (for extended flaps – triple antibiotics).
- alternatives – middle turbinate flap, palatal flap.
- **JANUS flap** – bilateral flaps (so each flap can be smaller).
- of course, even vascularized nasoseptal flap needs good multilayer free graft closure

POSTOP

HOB up, early saline irrigations, stool softeners, no straining, sneeze with mouth open

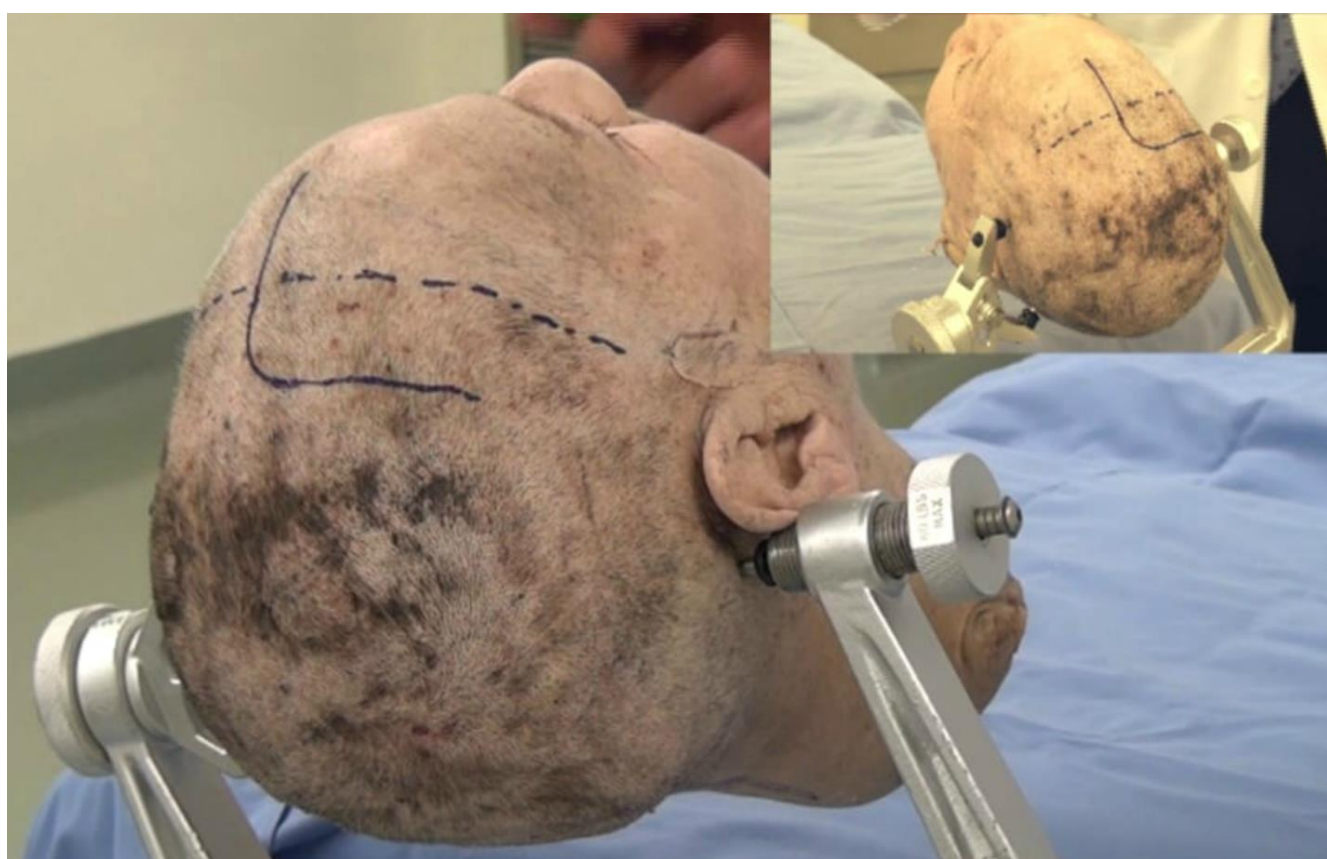FRONTAL (UNILATERAL) CRANIOTOMY

POSITIONING, PINNING, INCISION

Position: supine, head rotated slightly to opposite side.

Pins – single pin on craniotomy side and just behind auricle (too posterior – risk of slippage); two pins along superior temporal line:

N.B. place Mayfield as far posterior as possible – very difficult to close corners! - pull scalp (holding hair) forward during pin placement – will have less trouble closing!

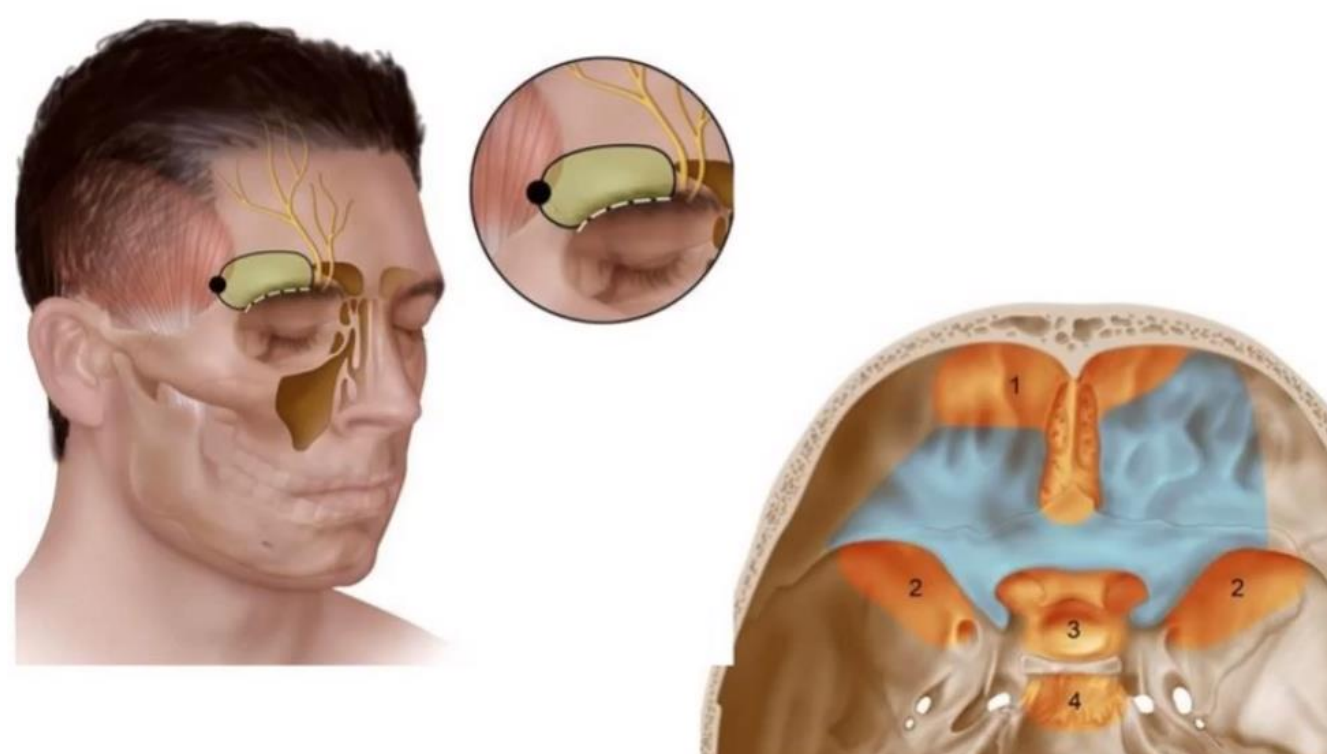


Incision:

- A. L incision – for posterior lesions
 - B. Keyhole supraorbital incision
 - C. Incomplete (3/4) bicoronal incision
- 4 **burr holes** – 2 at or 1 cm posterior to coronal suture (next to midline, just above temporalis insertion); 2 frontal
 - cosmetically best just 1 bur hole at keyhole; consider HydroSet for closure and low profile cranial plates
 - leave temporalis muscle intact; if need to get low towards orbit, need to incise temporalis fascia and reflect it together with scalp flap (to prevent violating fat pad with frontalis branch); **Dr. Broaddus** leaves temporalis fascia intact and just reflects the scalp.

SUPRA-ORBITAL CRANIOTOMY (S. "EYEBROW" CRANIOTOMY)

- incision within the eyebrow (not above eyebrow!) – perfect cosmesis.



- areas in **blue** can be seen during craniotomy; areas in **orange** cannot be seen (H: add endoscope).

BIFRONTAL CRANIOTOMY

INDICATIONS

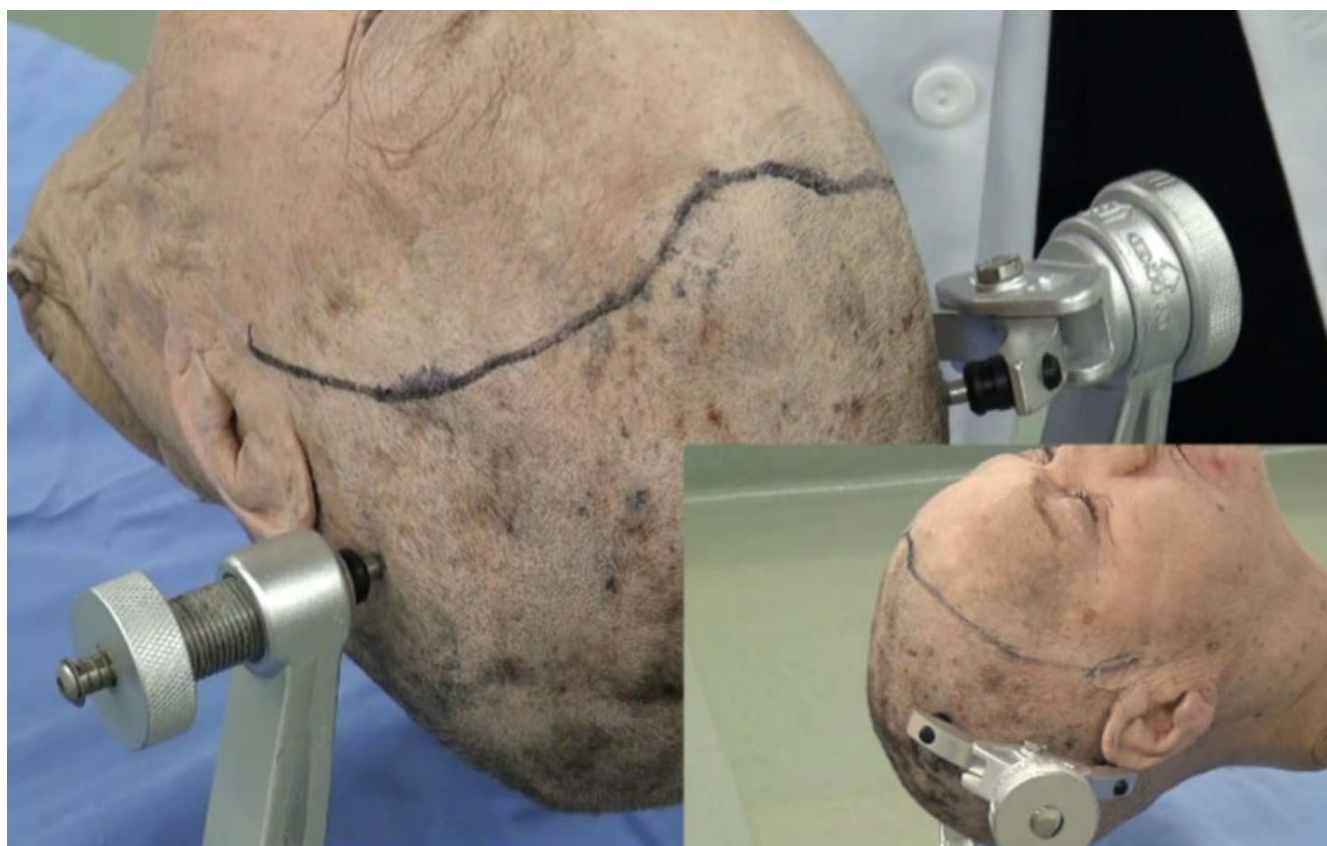Anterior skull base
Frontal bone

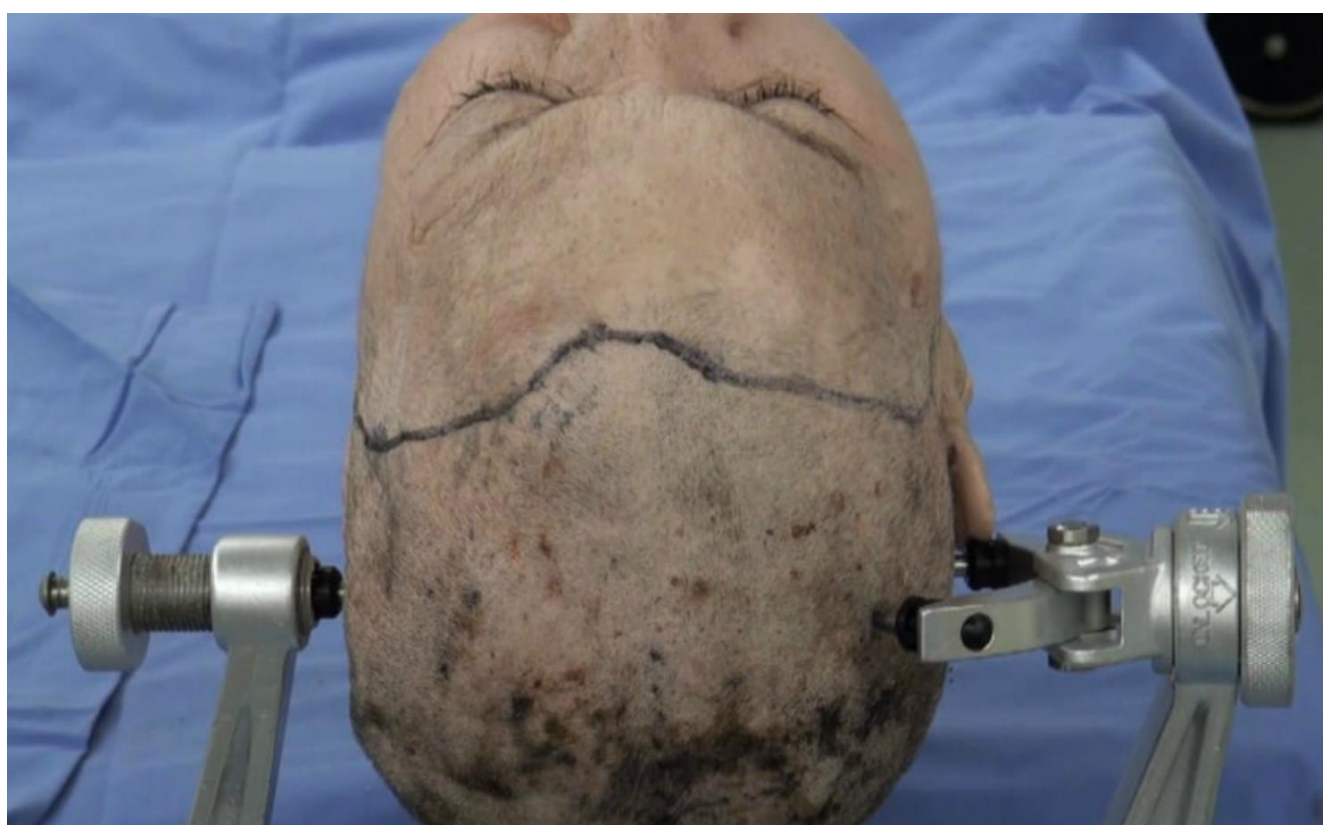
POSITIONING, PINNING, INCISION

Position: supine.

Pin placement – as posterior as possible:

N.B. pull scalp (holding hair) forward during pin placement – will have less trouble closing!





Incision:

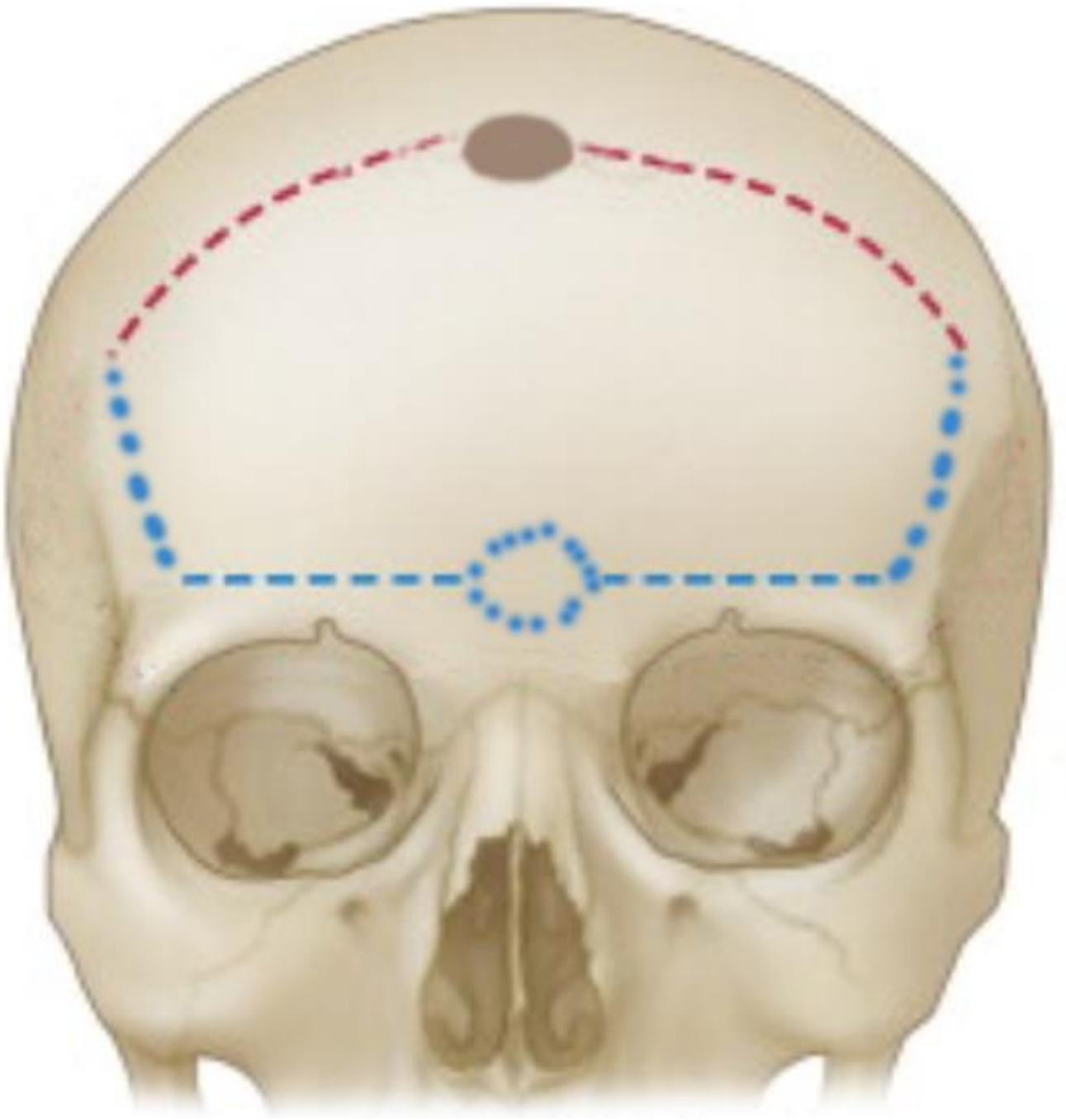
- starts 1 cm anterior to tragus (in skin fold) at level of zygoma (or above)
- extends vertically up, curves anteriorly (always stays behind hair line); lazy omega at midline (Dr. Broaddus does not use it).

FRONTO-TEMPORO-ZYGOMATIC CRANIOTOMY

- indication – sphenoid wing meningioma.
- exposes temporal fossa floor.
- incomplete bicoronal **incision**
- leave temporalis cuff – incise temporalis muscle parallel to superior temporal line, then along posterior scalp incision, then detach temporalis from bone down to zygomatic arch.
- expose both roots of zygomatic arch → use osteotome to cut roots of zygomatic arch → reflect entire temporalis anteroinferiorly together with attached zygomatic arch (during closure reattach zygomatic arch with “dogbone” plates at each end).

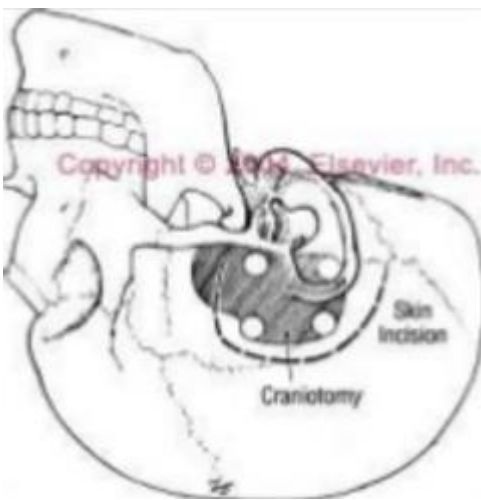
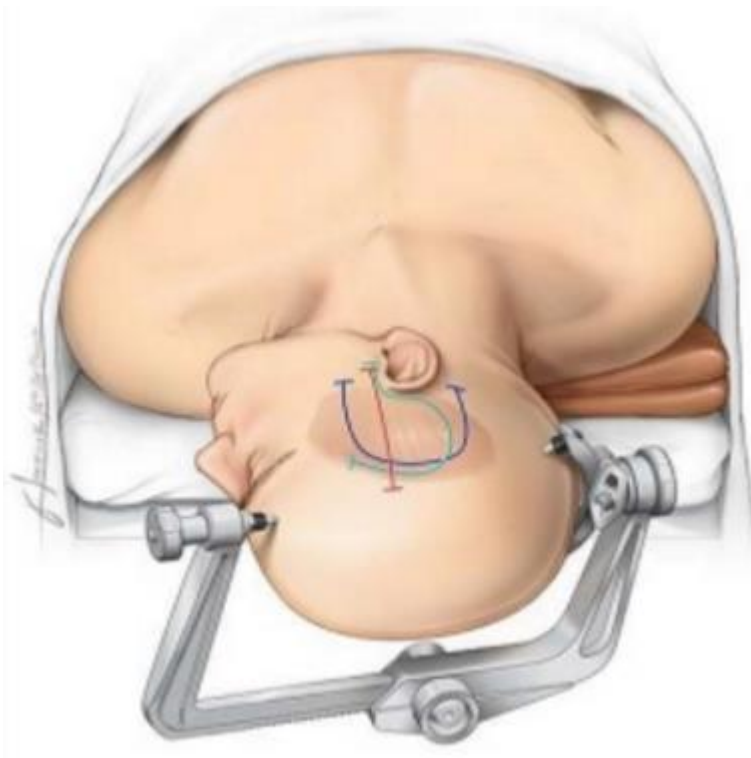
SUBFRONTAL CRANIOTOMY

- ideal for olfactory groove / planum sphenoidale meningiomas – enough unilateral (with $\frac{3}{4}$ bicoronal incision) craniotomy as approach is mainly interhemispheric.
- Dr. Broaddus may not use pinning (uses horseshoe head holder); he likes full bicoronal incision (no midline “lazy sigma” – may become visible due to hair loss).
- make pericranial flap (reflect it anteriorly and wrap in wet gauze).
- need to incise temporalis fascia to lift it up together with scalp flap (in order to preserve frontalis branch); Dr. Broaddus leaves temporalis fascia untouched and only dissects scalp off.
- bur holes:
 - a) *posterior over sagittal sinus*: Dr. Broaddus - one bur hole right over sinus; Dr. JRC - two small bur holes posteriorly on the sides of sagittal sinus (uses matchstick drill bit to connect bur holes)
 - b) *anterior midline burr hole* (just above frontonasal suture); often frontal sinus is thick and impossible to cut with footplate, plus, risk of SSS damage, so Dr. Broaddus uses C drill bit to remove circle of bone in anterior wall of frontal sinus (at the end places bone circle back and fixes with dogbone) → use Acorn, Kerrison to go across posterior wall of frontal sinus.
 - c) some experts place bur holes *at keyholes* – make large bone flap.
- usually frontal sinus is entered – *see above* >>
- sagittal sinus is 2-0 silk suture-ligated and transected (along with falx) at the base.
 - do not use ligating suture for falx retraction
 - no need to reattach falx at the end of surgery
- anterior dura is stripped from remaining frontal bone bar and the bone is flattened.
- at the end of craniotomy lay pericranium on denuded anterior fossa floor.

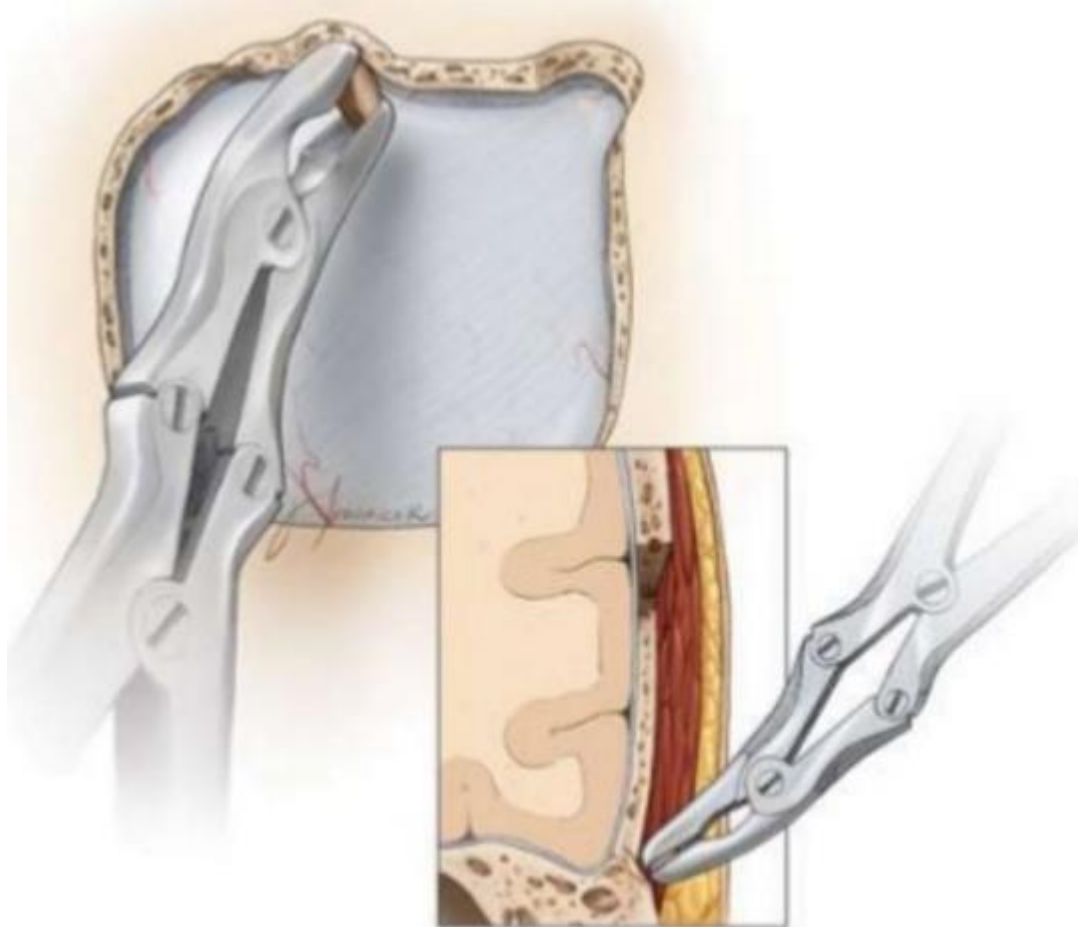


PARIETAL CRANIOTOMY

(SUB)TEMPORAL CRANIOTOMY

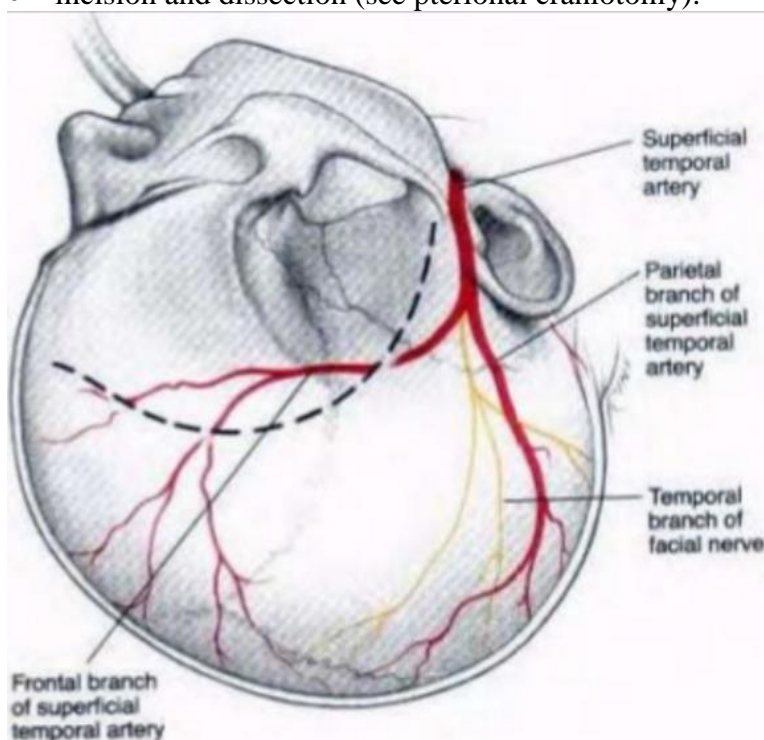


- biting off temporal bone:



SUBTEMPORAL CRANIOTOMY FOR ENCEPHALOCELE REPAIR (MIDDLE FOSSA)

- use navigation with maxillofacial CT – mark location of bone defect and the location of rotundum and ovale.
- incision and dissection (see pterional craniotomy):

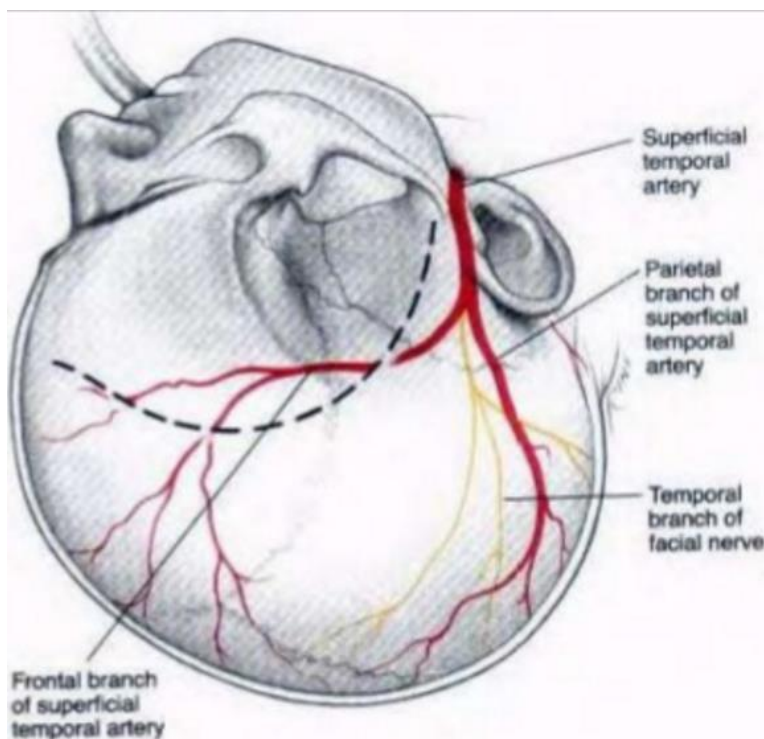


- may use 3 cm craniectomy hole (instead of craniotomy) low on temporal squama.
- stay **extradural** and find bony defect (use navigation).
- amputate herniated brain fragment.
- **repair dural defect**: open slit of dura more proximal to you, slide intradurally dural matrix patch and cover dural defect from inside → suture close dural defect and then your durotomy.
N.B. durotomy does not need to extend to the actual dural defect; it only serves to introduce dural matrix to inlay on dural defect (which is often small).
- **close bone defect**: (dural matrix patch) – bone graft (e.g. from craniotomy) – titanium (either mesh or snowflake) – dural matrix.
- dural sealant, mesh to cover craniectomy defect.

PTERIONAL CRANIOTOMY

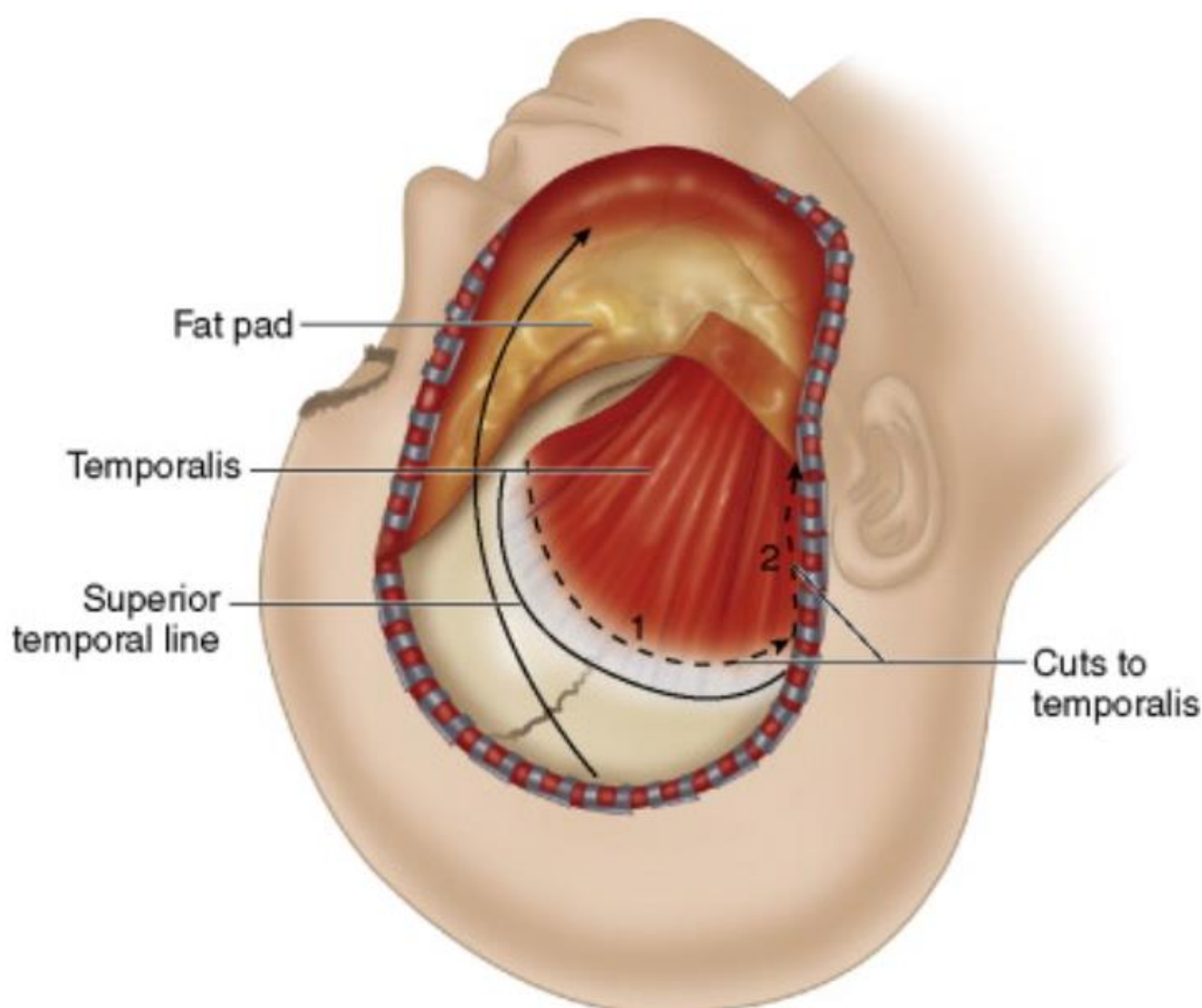
<http://www.neurosurgicalatlas.com/grand-rounds/pterional-craniotomy-details-of-technique>

- lift temporalis muscle from bone in retrograde fashion (Japanese technique) – must see preserved deepest shiny temporalis fascia – preserved innervation and blood supply to temporalis muscle.
N.B. no Bovie in this plane!!!



- dissection is in the plane between galea (temporal artery sits on the galea so reflect artery anteriorly) and superficial temporal fascia.
- once subgaleal fat pad is reached (that is where frontalis branch sits, usually in the anterior 1/3 or 2/3 of zygoma arch), incise superficial temporal fascia (**interfascial dissection** in the interfascial fat pad) or also deep temporal fascia (**subfascial dissection**).
– if need to gain access very anteriorly, - instead of making vertical temporalis cut, - detach temporalis fascia and muscle from anterior ridge of temporal fossa – this way can reflect temporalis muscle-fascia posteriorly.
- some experts lift **myocutaneous flap**.

- when lifting temporalis muscle off the bone, do not use Bovie (although it bleeds) – innervation to muscle comes in the deepest layers; Dr. JRC uses retrograde technique – lifts muscle from inferior to superior (parallel to natural muscle fiber direction).
- temporalis fat pad is mobilized to protect the frontalis branch of the facial nerve. The temporalis muscle is elevated down the root of the zygoma inferiorly and the inferior orbital fissure anteriorly. It is wise to attempt to preserve the superficial temporal artery if possible:



- cosmetically important to close anterior corner where temporalis fascia meets galea; no plates above temporal line anteriorly!
- some experts place Medpor flap to mask anticipated temporalis atrophy.

PTERIONAL CRANIOTOMY WITH ORBITOZYGOMATIC EXTENSION (“OZ CRANIOTOMY”)

NREF video >>
 NREF video (2) >>

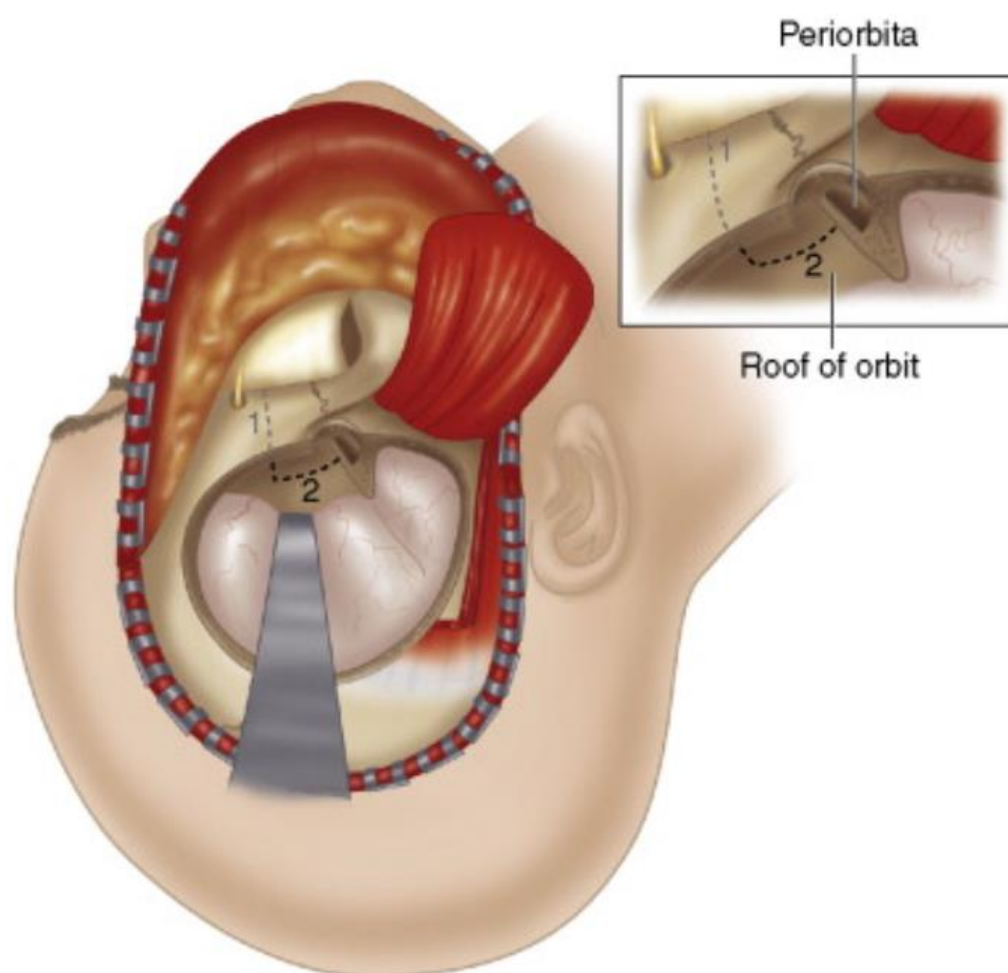
Indications

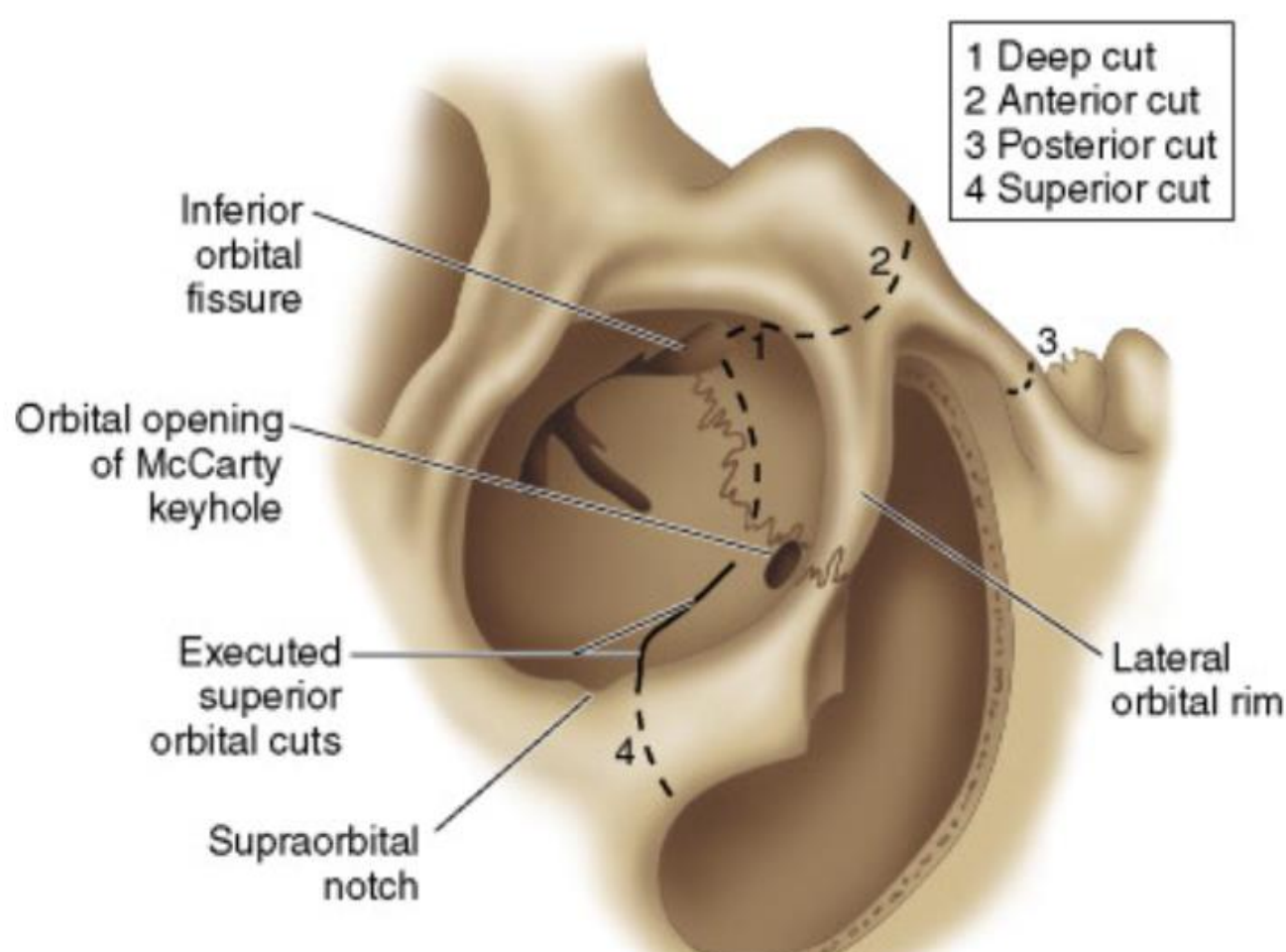
- 1) pathology with intraorbital extension
- 2) pathology with need to look from inferior to superior

Standard (one-piece) OZ – make bur hole in **McCarty key hole**.

Modified (two-pieces) OZ – make **Dandy bur hole** (more superior than McCarty key hole); lift standard pterional bone flap; then it is time for orbitozygomatic part; orbital wall cut connects superior orbital fissure with inferior orbital fissure; there is no need in every case to lift entire OZ bar (depending on operative corridor may be enough to cut only orbital or only zygomatic bar).

- after pterional type scalp flap is made, the attachment of the temporalis fascia to the zygomatic arch should be cut, and the soft tissue should be elevated off the zygoma over the maxillary buttress and frontozygomatic suture. The periorbita should also be freed from the orbital bone.





- place screw holes for plates on facial bones before making bone cuts
- first cut is at zygomatic arch – cut from inferior to superior (to protect frontalis branch).
- second cut is at zygomatic eminence – cut is V shaped; identify inferior orbital fissure by advancing Penfield #4 from orbit side towards infratemporal fossa.
- it is functionally important to preserve masseter attachment to zygomatic arch – my cut arch as a separate bone piece and reflect along with temporalis and still attached masseter; some experts reflect entire OZ piece on the masseter muscle.

VCU patient 5315105

- head secured in pins and turned to the side 45 degrees and extended so that the malar eminence is the superior-most portion of the surgical field.
- Keppra, mannitol.
- incision in coronal fashion - starting from the root of the zygoma and extending superiorly and towards the midline behind the hairline: very superficial cut of skin with #10-blade and then with Bovie – over Metz scissors inserted in subgaleal plane, thus, preserving pericranial flap.
- temporalis fascia was incised and then opened towards the root of zygoma and along the superior temporal line leaving a cuff of temporalis fascia for reconstruction. We opened the temporalis fascia all the way up to the keyhole. Then, the scalp flap together with temporalis fascia was elevated all the way anteriorly to the orbital superior and lateral rim. Temporalis muscle was elevated off temporal bone using periosteal elevator. Then, we disconnected the fascia from the zygoma and orbital rim. The temporalis muscle was reflected anteriorly. Two burr holes were created with an acorn bit at the keyhole and at bottom of temporal surface of greater sphenoid wing. Craniotomy flap was turned with a footplate. The bone was elevated with Penfield #1 and periosteal. Dura was found tightly adherent to the bone and durotomy line extending the part of craniotomy line. Hemostasis was maintained with bone wax and bipolar cautery. Copious amounts of sterile saline irrigation was then used to remove the bone dust. The supraorbital foramen was competent. Kerrison 1 mm punch was used to open it and free up the supraorbital nerve. Remaining sphenoid wing triangle was trimmed with Leksell rongeur. The dura was freed from the roof of the orbit and sphenoid with a Penfield #1. Microplate was secured with micro screw on the zygomatic arch root at the zygomatic bone. Then C1 bit and osteotome were used to create troughs and elevate orbitozygomatic bar in three separate pieces at the roof of the orbit posteriorly and then laterally to the superior orbital fissure and then through the lateral wall of the orbit towards the inferior orbital fissure. The osteotome was used to free up the orbitotomy portion completely. The sphenoid wing was placed flat to the skull base using a M8 drill bit. Bone bleeding was controlled with bone wax. Scalp flap and temporalis muscle were secured reflected anteriorly at the Leyla bar using rubber bands. Dura was opened in curvilinear fashion and reflected anteriorly over the sphenoid. 4-0 silk tuck ups were placed. The operative microscope was brought in to the field and further manipulations were done using microinstruments. The opticocarotid cistern was identified and opened. Blade retractor was placed over the frontal lobe and very gentle retraction was applied securing retractor blade to the Greenberg system rigidly attached to Mayfield clamp. Then, we turned our attention to the dissection of hemorrhagic tumor mass with visible cholesterol crystals. Tumor as well as blood clots were carefully dissected of major blood vessels and optic apparatus with special attention to preserve perforating vessels adherent to the tumor as well as vasa nervorum. Majority of dissection was performed through opticocarotid triangle as well as anterior to the optic chiasm gradually mobilizing and removing in piecemeal fashion all visible tumor tissue. At the end of dissection no visible tumor was remaining and hemostasis was complete. The optic nerves, chiasm, and tract were clearly decompressed. The subdural space was copiously irrigated with warm saline solution. The dura was reflected back and reapproximated with a running 4-0 silk. The orbitozygomatic bars were fixated to the patient's skull with microplates. The craniotomy bone flap was fixated to the patient's skull with cranial plating system. Bony defect around the flap was filled with HydroSet. Temporalis muscle was reattached to the cuff with 2-0 Vicryls. The temporalis fascia was reapproximated with 2-0 Vicryls.

ANTERIOR CLINOIDECTOMY

Extradural approach (Vinko Dolenc) – going blindly – risk of carotid injury.

Intradural approach:

- take lesser and part of greater sphenoid wings extradurally (as an extension of pterional approach)
- then switch intradurally – make dura cut over clinoid and take clinoid.
- clinoid is taken with small Lampard and diamond drill bit (frequent stops and irrigation).
- then optic strut is taken.
- how far anterior clinoidectomy must be – no need to be more anterior than optic strut.
- open arachnoid recess over the optic nerve.

TRANSORAL CLIVAL APPROACH

- can see only 1 cm
- difficult dural closure – CSF leak risk.

TRANSPETROSAL APPROACHES TO POSTERIOR FOSSA

<http://www.medscape.com/viewarticle/511118>

- resection of petrous temporal bone to various degrees provides different levels of access to lesions of posterior fossa (cerebellopontine angle, petroclival region).

Variants of transpetrosal approaches can be classified:

- Anterior transpetrosal approaches
- Posterior transpetrosal approaches

ANTERIOR (MEDIAL) TRANSPETROSAL APPROACHES (KAWASE, S. ANTERIOR PETROSECTOMY)

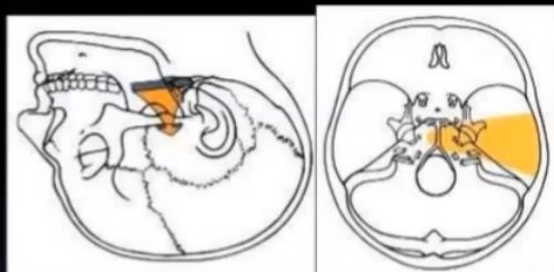
- extensions of basic middle fossa approach.

- designed to **preserve hearing** - spare lateral petrous bone.
- involve resection of medial petrous bone to various degrees.
- involve resection of bone within Kawase rhomboid and division of tentorium to provide exposure of posterior fossa.
- GSPN (easy to identify) is right above and parallel to petrous ICA

http://operativeneurosurgery.com/doku.php?id=kawase_approach

– Most commonly referred as “Kawase” or “Extended middle fossa approach”

- Subtemporal craniotomy
- Anterior petrosectomy (Extradural)
- Transtentorial (middle-to-posterior fossa trajectory)



POSTERIOR TRANSPETROSAL (PRESIGMOID) APPROACHES

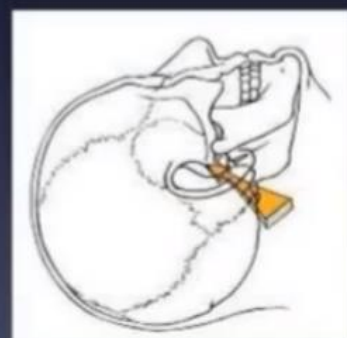
- retrolabyrinthine, translabyrinthine, and transcochlear.

- based on the standard mastoidectomy and involve resection of petrous bone to various degrees - progressively increased exposure anteriorly, but comes at expense of **hearing** in translabyrinthine approach and of **hearing and facial strength** in transcochlear approach.
- subarcuate artery (branch of AICA) – feeds bone of labyrinth – OK to sacrifice.

Posterior petrosal approach

– Most commonly referred as “petrosal approach”

- Mastoidectomy + L-shape subtemporal craniotomy
- Retrolabyrinthine petrosectomy (hearing preservation)
- Presigmoidal transtentorial approach



RETROLABYRINTHINE (PRESIGMOID) APPROACH

Used sources:

R. **Jandial** “Core Techniques in Operative Neurosurgery” (2011), procedure 20

Indications

- The retrolabyrinthine approach is a hearing-preserving presigmoid approach that uses a mastoidectomy and skeletonization of the sigmoid sinus to expose the presigmoid dura behind the semicircular canals.
- The principal appeal of this approach is its ability to expose widely the posterior petrous face and cisternal portions of cranial nerves VII and VIII with a minimal degree of cerebellar retraction.
- The retrolabyrinthine approach additionally is used to identify and expose the superior petrosal sinus, as a first step for division of the tentorium.

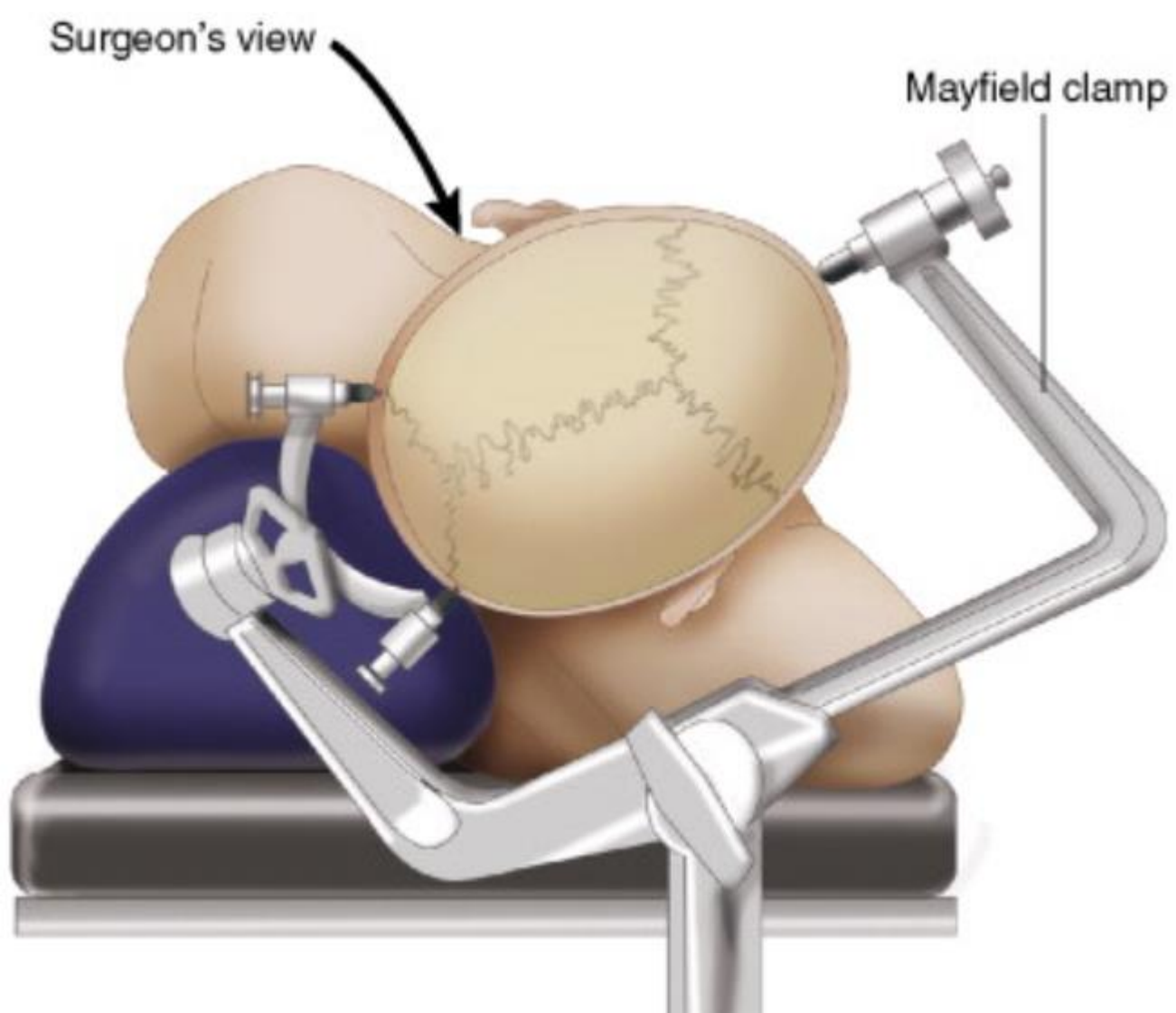
Contraindications

- This approach is unable to access the internal auditory canal or petrous apex directly because of the interposition of the labyrinthine and cochlear structures between the surgeon and these regions.

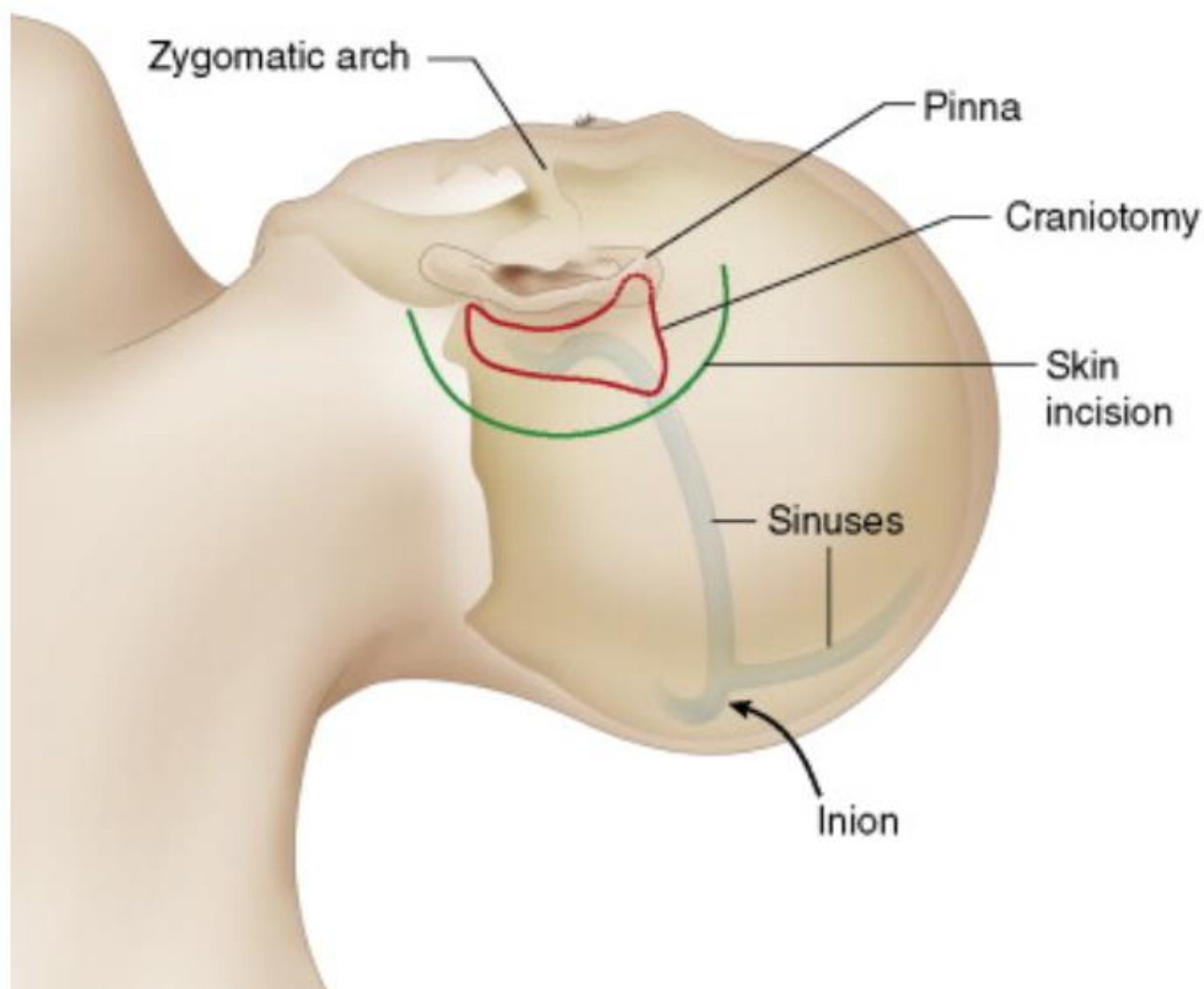
Planning and positioning

- The patient generally is placed in a semilateral position on the operating table, with a bump under the ipsilateral shoulder.
- The head is placed in a Mayfield head holder with two pins placed in the occiput just off midline. The single pin is placed in the ipsilateral forehead, lateral to the mid-pupillary line ideally behind the hairline.
- After pinning, the head is usually positioned such that the region just behind the pinna just superior to the mastoid process is the highest point on the patient's head. With adequate ipsilateral shoulder elevation, this position is achieved by a slight amount of contralateral head rotation, minimal neck flexion, and head elevation.

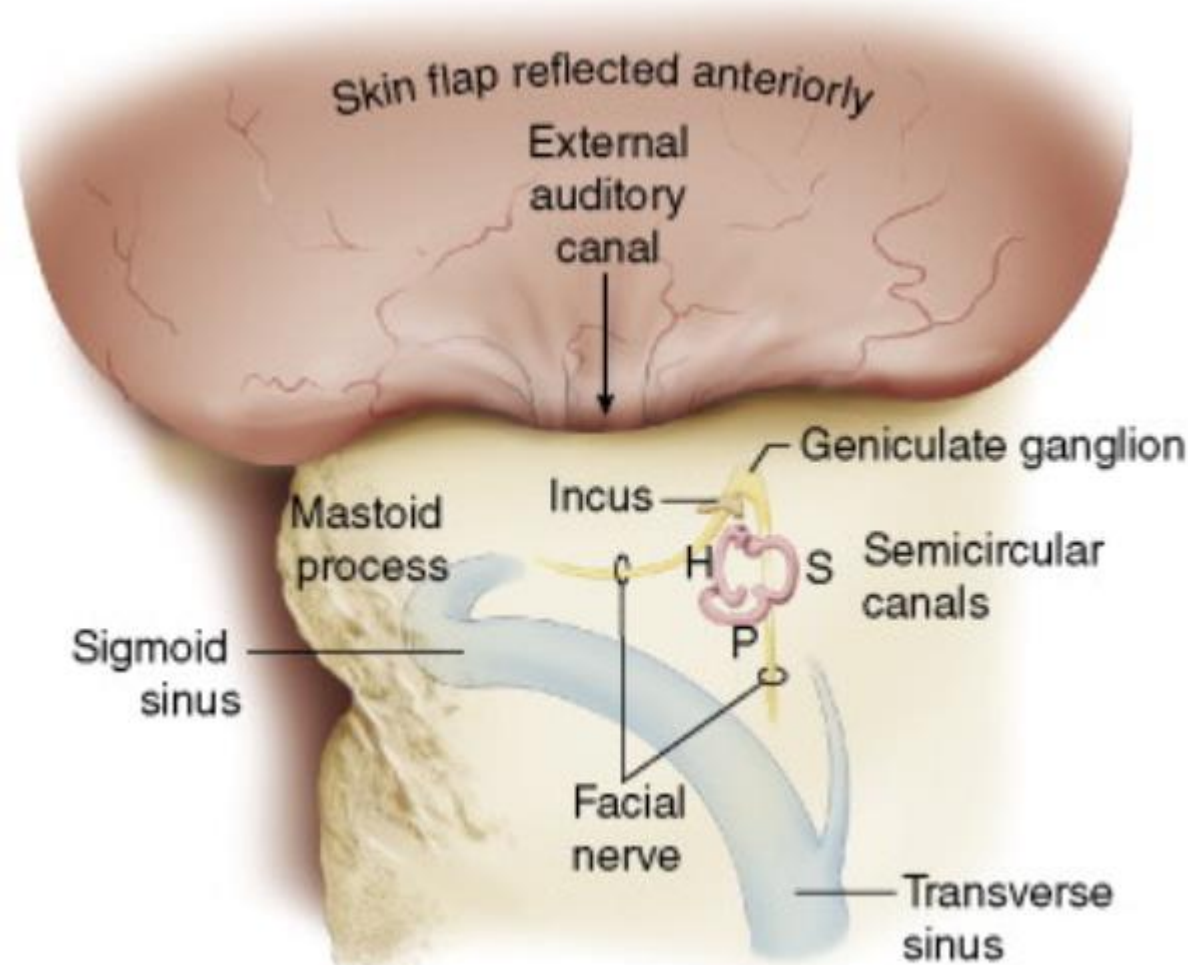
Look for Trawman’s triangle



The skin incision is C-shaped with the convex portion of the "C" pointing posteriorly. The upper limb of the incision begins just superior to the pinna. The height of this superior limb can be estimated by drawing a line from the zygomatic arch to theinion and beginning the upper limb just above the external auditory canal along this line, which should overlie the linea temporalis. The incision terminates just inferior and anterior to the mastoid tip. The apex of the "C" should be far enough back to expose fully the asterion, which is roughly one third of the way from the pinna to theinion:



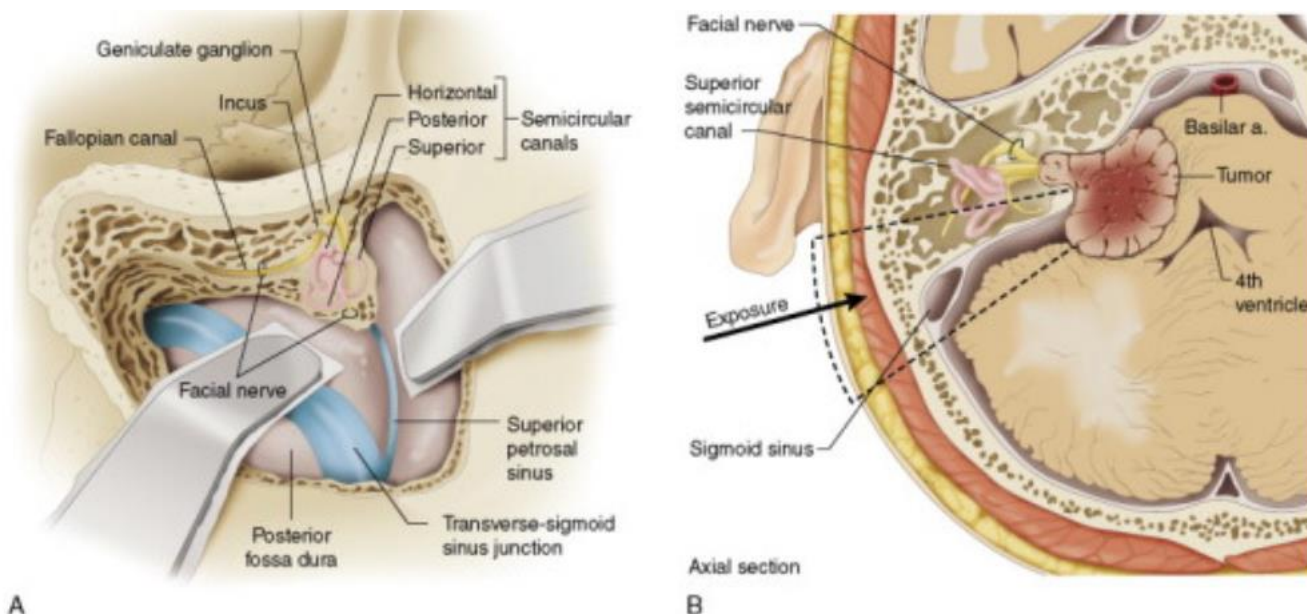
Soft tissue elevation and identification of landmarks. Following incision, the scalp is separated from the underlying pericranium sharply and elevated anteriorly. A pericranial flap is also harvested and reflected anteriorly. The soft tissue dissection should proceed anteriorly until the external auditory canal can be palpated. When the mastoid process has been exposed, the attachments of the sternocleidomastoid and splenius capitus muscles are partially detached from the mastoid tip until the bone begins to curve medially.



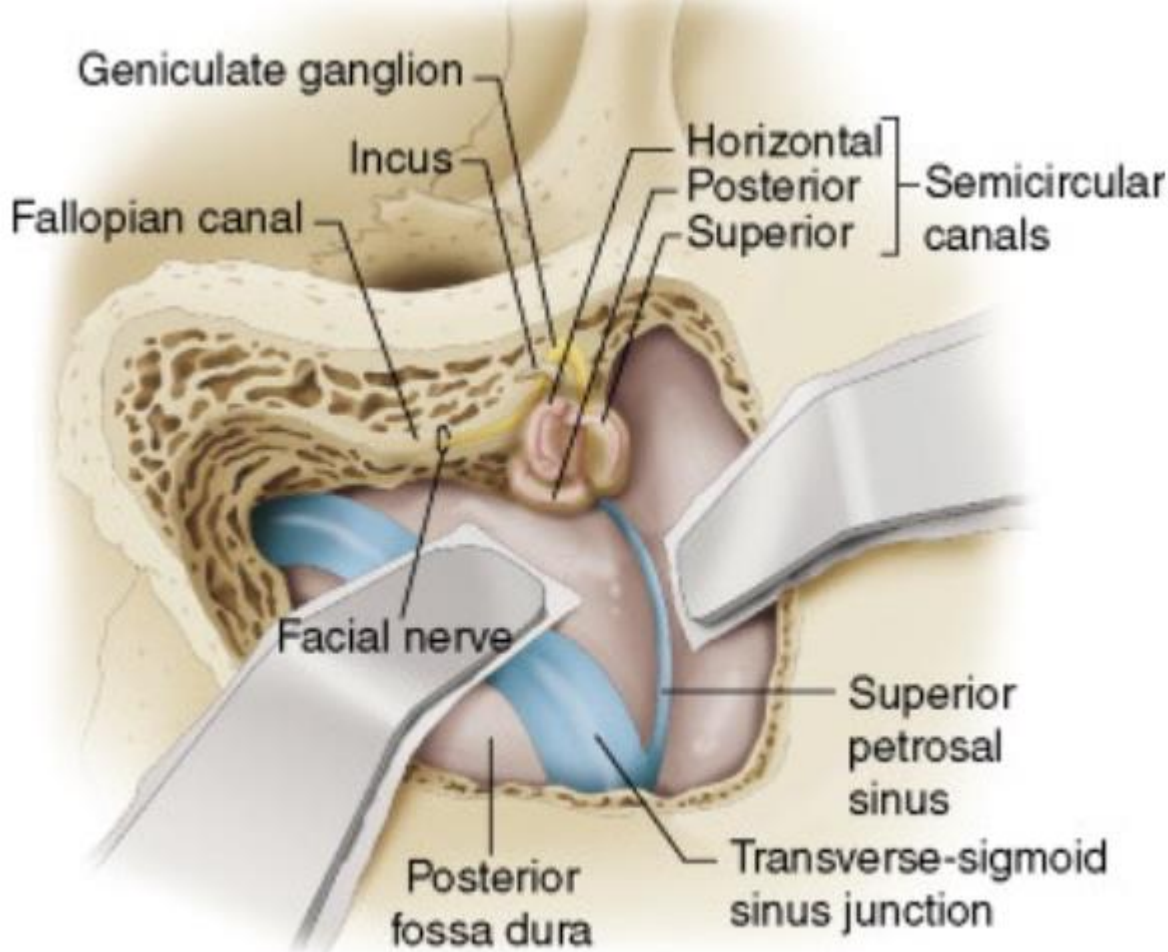
The mastoidectomy is roughly a right triangle with the curvilinear hypotenuse just posterior to the external auditory canal. The superior limb of the triangle runs parallel and inferior to the linea temporalis from just posterior to the zygomatic root to just posterior to the asterion. The anterior limb of the triangle runs in from the anteriormost point of the superior limb inferiorly, following the curve dictated by the external auditory canal, terminating inferiorly at the mastoid tip. The posterior limb

finishes the triangle, running from the asterion to the mastoid tip. An important landmark is the spine of Henle, just posterior and superior to the external meatus. This point roughly overlies the mastoid antrum where the semicircular canals and facial nerve are located.

Digastric groove leads anteriorly into stylomastoid foramen (CN7)!

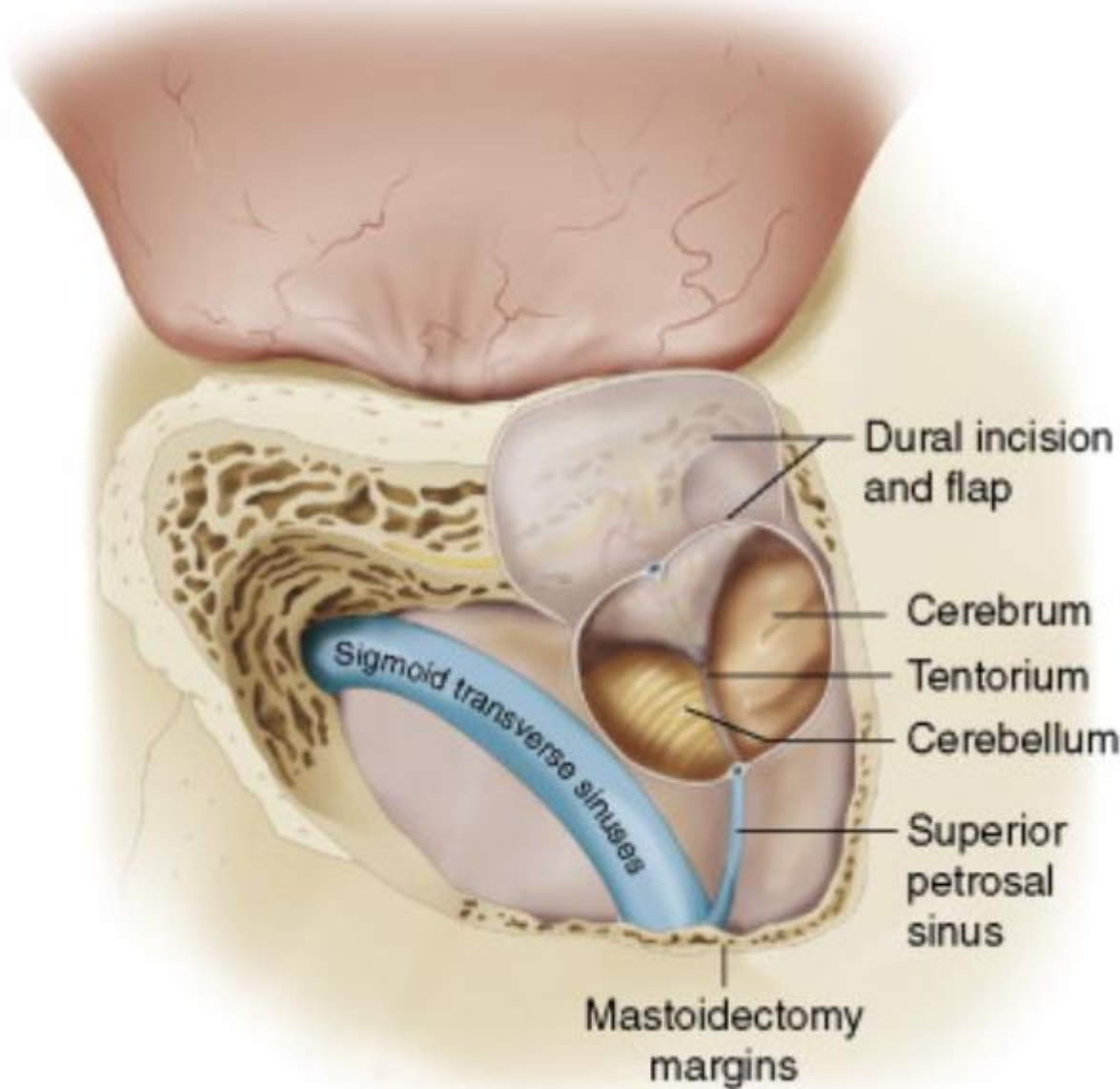


Delineation of the sinodural angle. After exposure of the sinuses and dura, the epitympanum is drilled open with a diamond bit. The bony labyrinth overlying the semicircular canals is skeletonized, with care taken not to violate this protective bone. When the boundaries of the labyrinths are well delineated, retrolabyrinthine bone removal can continue safely until the sinodural angle is defined and the adjacent middle and presigmoid dura are completely exposed up to the sinodural angle:



Delineation of the fallopian canal. Adequate exposure in this approach requires that the presigmoid dura be exposed down to the jugular bulb. The vertical portion of the facial nerve overlies the jugular bulb and dura in this region. The fallopian canal is identified anterior and inferior to the bony labyrinths in the epitympanum. When identified, the canal is skeletonized with a diamond bit, particularly on its deep surface in a rostral-to-caudal direction, until its relationship to the jugular bulb is known. Bony removal can be continued as far anteroinferior as possible underneath the facial nerve.

Dural incision. The dura is opened in a C-shaped fashion around the epitympanum with the base centered around the labyrinths. It is important that the endolymphatic sac is identified and included with the dural flap so that endolymphatic flow is not disrupted. Depending on the goals of surgery, the superior petrosal sinus can be sacrificed as part of a tentorial division, and the middle fossa dura can be opened to provide visualization of the petrous apex, tentorial incisura, or middle fossa floor:



Tips from the masters

- Numerous mastoid emissary veins can be encountered during this dissection, and when bleeding from one of these veins is encountered, it is best to continue dissection until well beyond these veins before attempting to control the bleeding with bone wax.

- The drilling should start with a large cutting bur and proceed to diamond burs as critical structures such as the facial nerve and sigmoid sinus are encountered.
- The largest burs possible for a given drilling task should be used because these are less likely to pierce a small hole in a vessel or nerve than a small bur.

Pitfalls

Care should be taken not to cause kinking of the contralateral jugular vein with the head position.

Care should be taken to avoid entering the external auditory canal during soft tissue dissection.

TEMPOROPOLAR (HALF-AND-HALF) APPROACH TO THE BASILAR ARTERY AND THE RETROSELLAR SPACE

Used sources:

R. Jandial "Core Techniques in Operative Neurosurgery" (2011), procedure 18

INDICATIONS

- **Transylvian approaches** enter the parasellar cisterns on a superior-to-inferior trajectory, forcing the surgeon to work past the carotid artery through the opticocarotid or carotid-oculomotor triangles to access this region, making access of the mid-basilar and interpeduncular cisterns difficult.
- Although the **subtemporal approach** provides a good view of the basilar artery at the level of the tentorium, it is limited in its rostral visualization, which can be necessary for high-riding basilar apex aneurysms or tumors with significant superior extension. Also, the flat trajectory of this approach limits the ability to see the retrosellar space.
- The **temporopolar approach** combines these approaches largely through microsurgical mobilization of the temporal lobe, which is retracted posteriorly and laterally to add the exposure of the tentorial incisura to the visualization obtained with a transylvian approach.

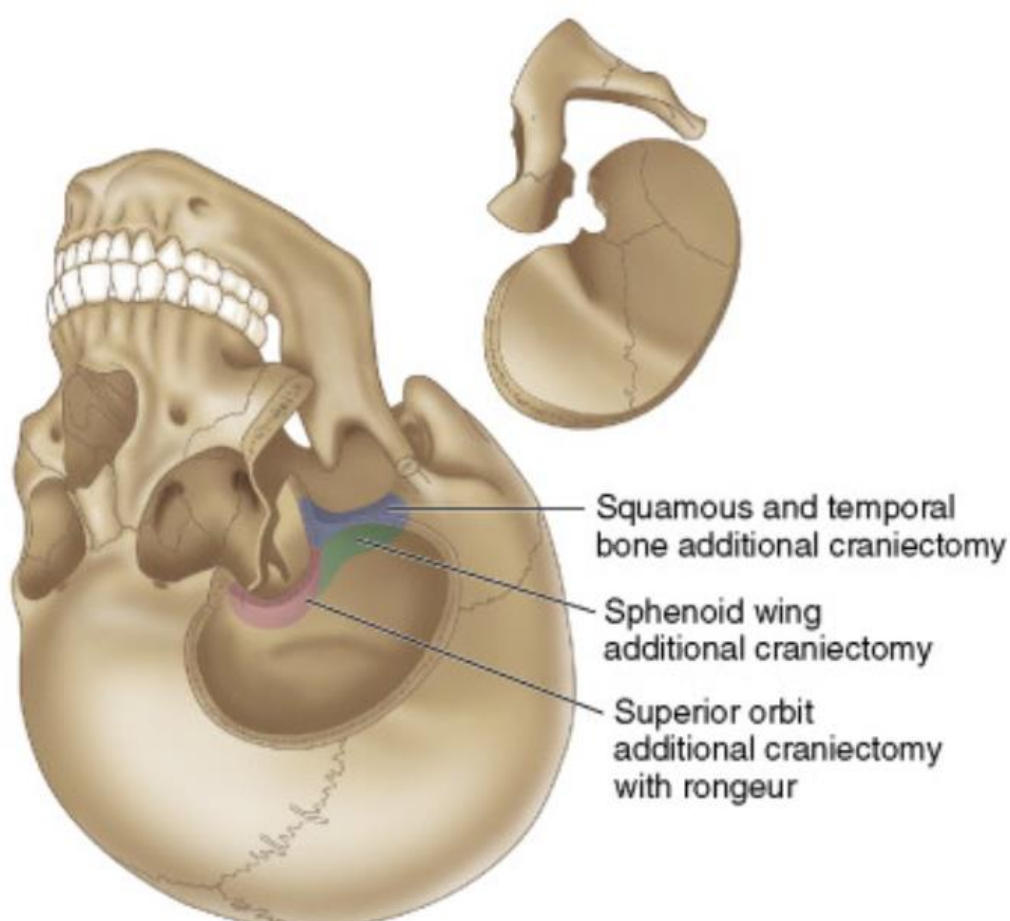
CONTRAINDICATIONS

- Laterally projecting posterior communicating artery or middle cerebral artery aneurysms because these might be attached to the temporal lobe and rupture with retraction.

PROCEDURE

- patient is positioned supine, head is pinned similar to the orbitozygomatic approach (malar eminence the highest point in the field).
- craniotomy is identical to the orbitozygomatic approach.
- Aggressive craniectomy of the squamous temporal bone, from the temporal pole back to the root of the zygoma, until it is flush with the middle fossa floor is particularly important for this approach. This craniectomy is critical for safely mobilizing the temporal lobe posteriorly and working along the middle fossa floor.

Removal of lesser sphenoid wing. Regardless of whether or not an orbitozygomatic osteotomy is performed, it is necessary to drill the lesser sphenoid wing and orbital roof as flat as possible down to the anterior clinoid process. To perform this, the dura is first stripped from the orbit and sphenoid wing using a No. 1 Penfield dissector. The bony elevation of this region is achieved using a side-cutting drill that is held parallel to the orbital bone with the hand resting on the temporalis muscle. The drilling should avoid entering the orbit but should thin the bone in this region as close to this as possible. In deeper portions, thin spicules of bone need to be removed using a fine rongeur. The dural incision is a C-shaped incision that extends over the sylvian fissure and is convex posteriorly. The ends of the "C" should roughly bifurcate the frontal and temporal limbs of the frontotemporal bone flap. Dural sutures should be placed as low as possible and sutured tightly to the scalp



- Sylvian dissection. After dural opening, the arachnoid bridging from frontal to temporal lobe over the anterior sylvian fissure should be meticulously divided using microscissors, No. 6 Rhoton dissector, and bipolar cautery, as necessary. By continuing laterally from the carotid, the middle cerebral artery or a middle cerebral vein can be identified and followed into the sylvian fissure. Arachnoid dissection continues until the frontal and temporal lobes are separated roughly back to the limen insulae. Brain retractors are placed on the frontal and temporal lobes to permit visualization of the basal cisterns.
- After completing the sylvian fissure dissection, the arachnoid surrounding all visible cisternal spaces should be opened sharply with microscissors. This dissection improves visualization and provides further brain relaxation. The posterior communicating artery should be identified exiting from the supraclinoid carotid artery, and the arachnoid of the opticocarotid and carotid-oculomotor triangle should be opened so that its course is clearly visualized and can be followed posteriorly.
- Temporal lobe mobilization. At this point, attention should be turned to the temporal pole and subtemporal region. With gentle posterior temporal retraction, any veins bridging from the temporal pole to the sphenoparietal sinus should be identified and divided. Additionally, the

subtemporal space should be inspected for bridging veins, which should be divided. With the increased relaxation provided by opening the cisterns, the temporal lobe should be retracted slightly posterolaterally so that the arachnoid overlying the uncus can be identified. After mobilizing the temporal lobe, the posterior communicating artery should be followed posteriorly along the tentorial incisura. This can be followed to the membrane of Lilliequist, which can be opened to expose the basilar apex and retrosellar space

Tips from the masters

- The dura needs to be tightly sutured flat against the bone so that it does not obscure visualization.
- Often the frontal and temporal operculum can overlap, making entering an arachnoid plane difficult. It is usually wise in these situations to elevate the frontal lobe gently, identify the opticocarotid cistern, and open this sharply to drain cerebrospinal fluid and identify the supraclinoid carotid artery.
- The cerebrum should be routinely protected at this point because these procedures can take some time. Brain retractors should be padded with Telfa.
- Additionally, it is a good idea to cover any cortical region that would be out of direct view of the microscope during the microdissection. Moistened rubber from powder-free gloves provides good protection and keeps the cortex moist.

Pitfalls

It should never be necessary to take a vein crossing the fissure because these can always be separated to one lobe or another through careful dissection.

Bailout options

- If more posterior exposure of the ambient cistern is needed, the temporal lobe can be retracted upward, converting this approach to a subtemporal approach.

POSTERIOR FOSSA CRANIECTOMY / MIDLINE SUBOCCIPITAL CRANIOTOMY

References:

R. **Jandial** "Core Techniques in Operative Neurosurgery" (2011), procedure 5

Benzel "Spine Surgery" 3rd ed. (2012), ch. 119, p. 1171-1180

Suggested additional resources:

<https://www.neurosurgicalatlas.com/volumes/cranial-approaches/suboccipital-craniotomy>

INDICATIONS

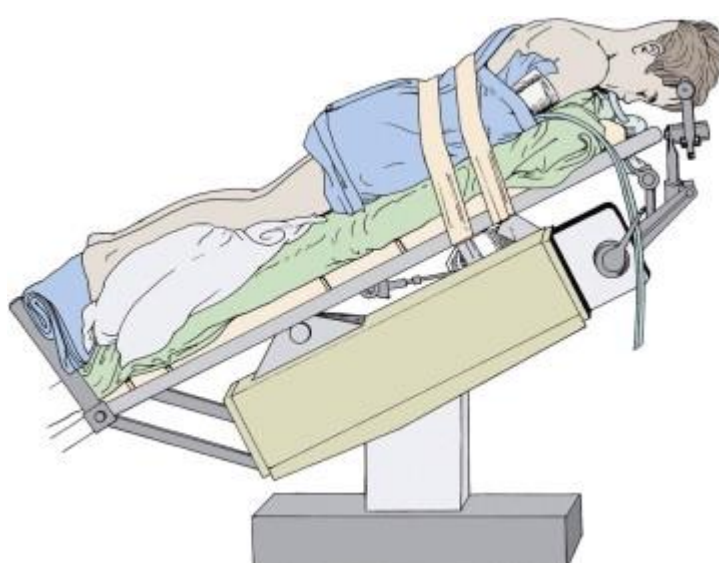
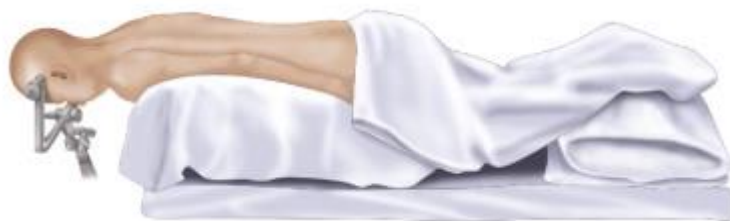1. Cerebellar stroke
 2. Chiari malformations (symptomatic, large syrinx)
 3. Tumors
 4. Vascular lesions (aneurysms, cavernous malformations, AVMs)
 5. Infections
- if lesions extend rostral to tentorium, consider combined supracerebellar and supratentorial approach.
 - if lesion extends from posterior fossa to middle fossa, consider combined middle and posterior fossa approach.

PREOP

- **DEXAMETHASONE, MANNITOL** (not for Chiari, except dex if opening dura and manipulating tonsils)
- avoid *neck hyperextension* during intubation.
- consider *neuromonitoring* (SSEP, MEG, ± BAER) in severe cases.
- consider placing **lumbar drain / EVD** (e.g. occipital)
 - to prevent postoperative hydrocephalus by draining CSF with debris and blood;
 - to protect dural closure.
- some use microscope for intradural portion.

POSITION

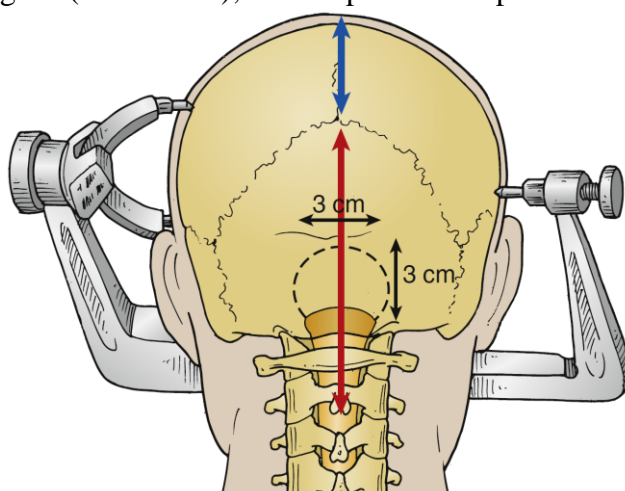
- prone on chest rolls, arms papoose by sides ("Concorde" or "military tucked-in" position):
- operative table as for:
 - a) **PCF** (with head towards anesthesia) – **Dr. Ritter**
 - b) **craniotomy** (with patient rotated 90° away from anesthesia) - **Dr. Broaddus, Dr. Tye**
- head in 3-point Mayfield head frame / horseshoe head rest (**Dr. Tye** for kids < 3 years) - flexed at neck (check chin!)
 - N.B. **translate head posteriorly and flex as much as possible** to facilitate bone work!
- shoulders are retracted inferiorly with adhesive tape.
- hips and knees flexed.



TECHNIQUE

DISSECTION

- incision: midline, frominion to C2 spinous process (*red arrow*) and a separate incision is marked for the pericranial graft (*blue arrow*); suboccipital decompression is approximately 3×3 cm



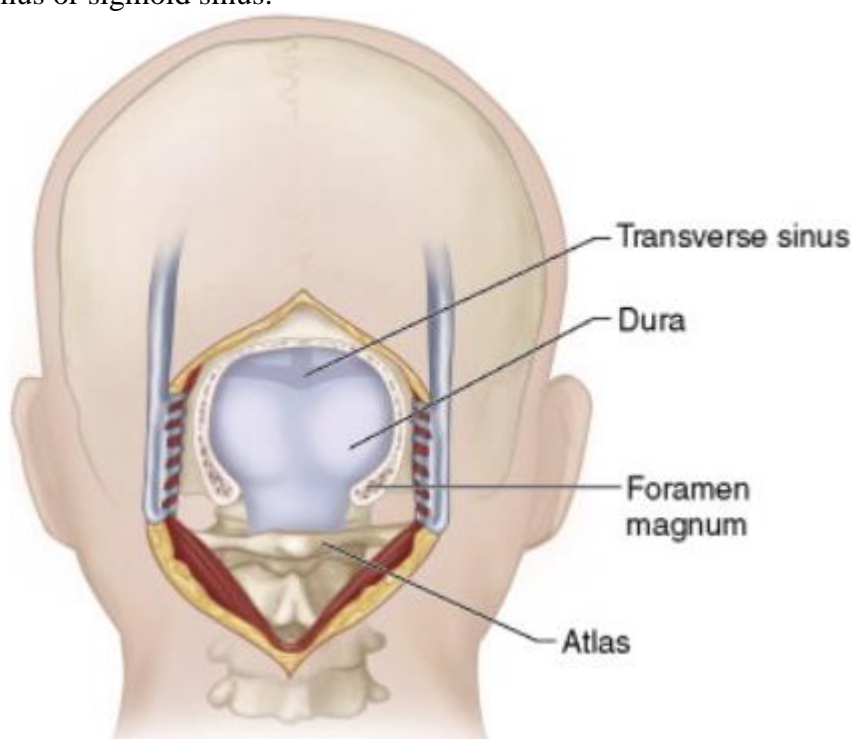
- soft tissues and occipital musculature are separated in midline through relatively avascular plane.
- expose midline keel, lower part ofinion, foramen magnum, C1 lamina.
- lateral exposure of cervical muscles; use Bovie *lower setting* and microinstruments to dissect laterally on C1 lamina see p. A205 >>
- using Penfield 1 dissector / 2-0 curette / Bovie, periosteum is removed laterally (up to occipital condyles).
- using fish hooks for retraction of inferior aspect of incision eliminates need for inferior cerebellar retractor, handles of which can be bulky and unnecessarily raise depth to operative field.
- foramen magnum and posterior arch of C1 are exposed entire width of dura; there is no reason for exposure more lateral than this because exposure of vascular structures on each side of C1 carries risk without benefit.
- by leaving muscle attachments and laminae of C2 intact, postoperative pain and potential spinal instability (\rightarrow cervical kyphosis) are minimized.
- rarely, it may be necessary to remove superior aspect of C2 laminae.

CRANIECTOMY

N.B. in some posterior fossa cases, **Dandy/Frazier burr hole** >> is included in field in case of intraoperative catastrophe or when preoperative hydrocephalus exists!

- Acorn bit to drill lateral and lower portions of posterior fossa \rightarrow table of bone removed using Kerrison rongeur.
 - Dr. Cohen-Gadol**: make burr holes (with Acorn) at lateral superior corners of planned craniectomy \rightarrow extend craniectomy toward foramen magnum with footplate \rightarrow drill across midline over torcular with B1 bit (without footplate) \rightarrow fracture remaining thin bone over torcular using elevation
 - Dr. Ritter**: drill with matchstick (M8) in midline across midline keel (just below torcular) \rightarrow finish craniectomy with footplate (dura is not attached to bone in kids)
 - in young patients, craniotomy begins on one side of foramen magnum, extends up to transverse sinuses, and finishes on other side of foramen magnum, without requiring initial burr hole.
- how far to extend superiorly? – measure preop distance on MRI from foramen magnum to torcular Herophili; generally, **no more than 3.5 cm** (“Chiari I – disease of foramen magnum; compression is not in posterior fossa” – max 1.5-2 cm).
 - how wide? – **width of foramen magnum** (“Chiari I – disease of foramen magnum”); be aware of **vertebral artery** entering skull at sides of foramen magnum – always good to check CTA!!!
 - wax bone edges for hemostasis.
 - Dr. Collins** harvests pericranial flap!

Craniotomy is done with care to preserve underlying dura; burr holes can be placed close to transverse sinus or sigmoid sinus:



C1 LAMINECTOMY

To reduce risk of vertebral artery injury, **electrocautery is not used more than 15 mm lateral to midline** when performing subperiosteal dissection of superior posterior ring of C1.

- necessary for pathology resulting in tonsillar herniation; in addition, C1 laminectomy is done for tumors in fourth ventricle - permits surgeon to angle instruments upward; cisterna magna can be opened at bottom to visualize tonsils fully or to be able to release cerebrospinal fluid for decompression.
- arch of C1 is undermined from dura using Penfield 1 and with craniotome / Kerrison posterior C1 arc is removed.
- lateral **internal vertebral venous plexus** often is encountered (epidural venous plexus located between the dura and the laminae periosteum) - two or more anterior and posterior longitudinal venous channels running along multiple cervical levels – bipolar cautery, liquid Gelfoam control venous plexus bleeding.

Dr. Cohen-Gadol:

- lateral dissection over the posterior arch of C1 should be performed with caution and at lower cautery settings;
- blunt dissection (curette) is advised to prevent injury to the vertebral artery.
- vertebral artery can have a very tortuous route outside its groove over the lateral arch of C1 (sulcus arteriosus) and may travel within the suboccipital muscles.

- brisk bleeding from the venous plexus encasing the artery is a warning sign that the artery is nearby.

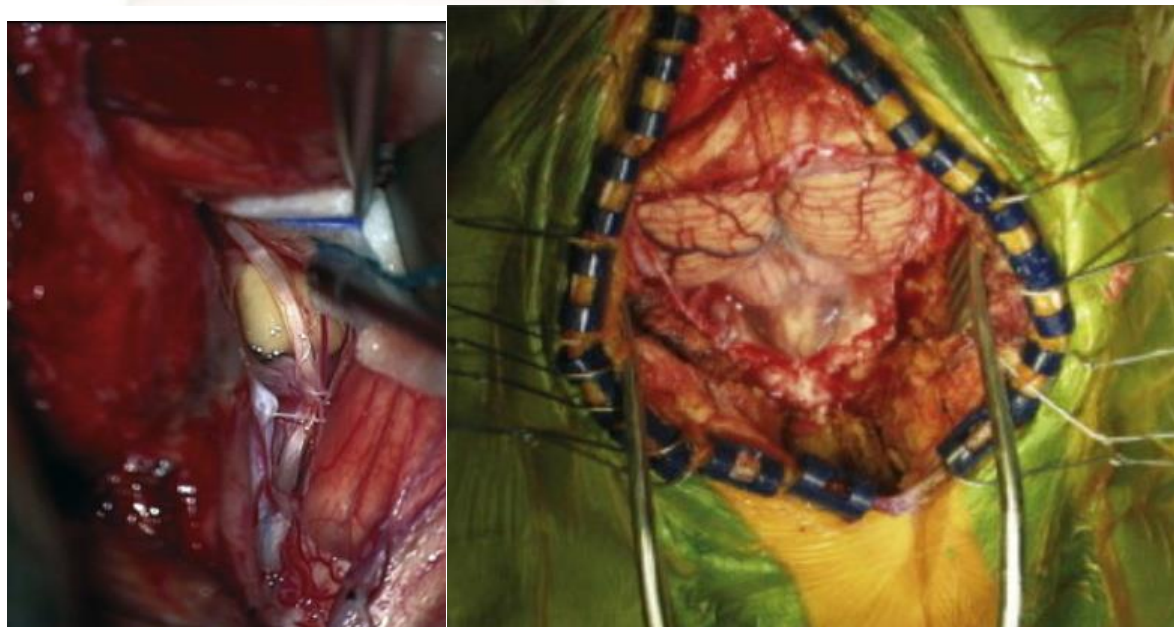
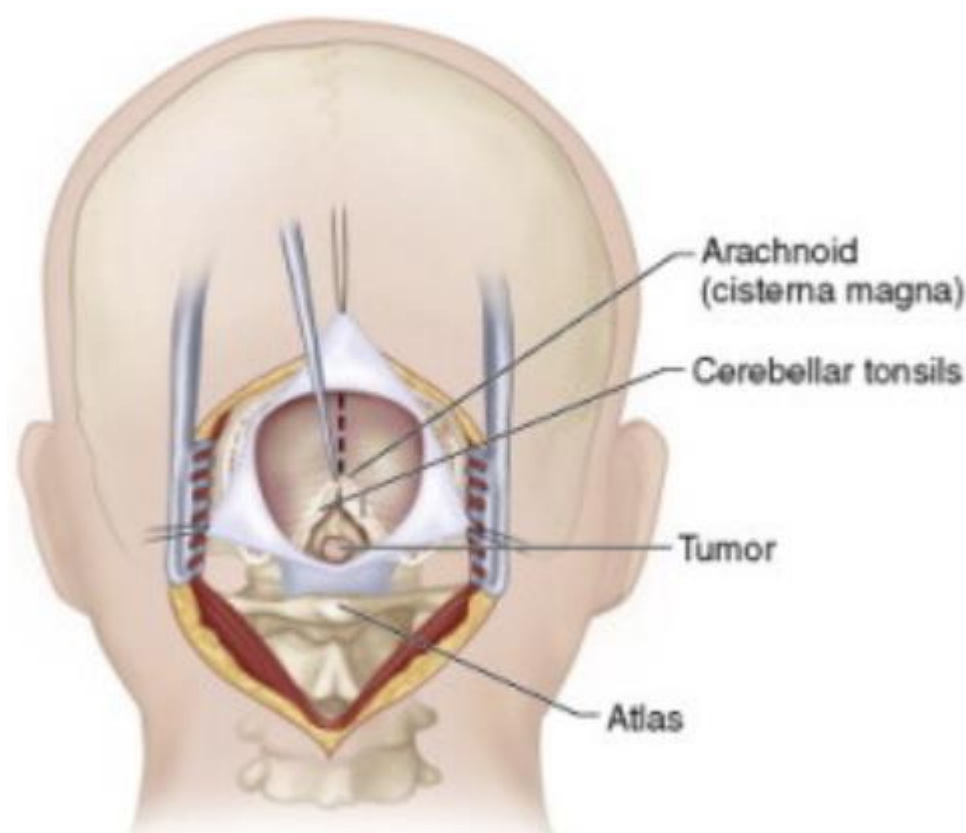
FIBROUS BAND

- after removal of occiput and C1, one should see clear dura but usually there is transverse band of thick constricting fibrous tissue – need to release it: insert hockey stick under it in midline and cut, then lift and dissect away on each side and amputate.

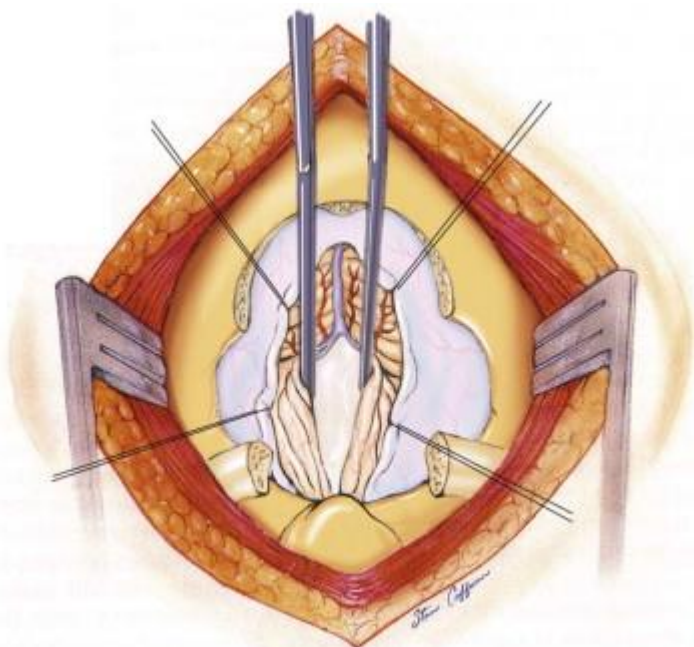
DURAL OPENING, DURAPLASTY

Optional – for pros and cons see p. Dev7 >>

- may skip dura opening for Chiari for kids (dura can be quite vascular in kids!); **Dr. Broaddus** always opens dura for adults; **Dr. Ward** does not open even for adults but stresses importance of resecting fibrous band; dural opening has some morbidity!
 - **Dr. Tye** uses **intraoperative ultrasound** to see if **cerebellar tonsils still pistoning** (despite craniectomy) – i.e. visibly moving up and down in sagittal plane (normally, tonsils remain still or gently pulsate with heart activity) → open dura.
- some surgeons split dura, opening only outer layer.
- dura opened in:
 - a) **Y-shape** with apex at foramen magnum; dura is folded back and retained in place with 4-0 silk suture tack-ups → suture in *triangular* shaped graft.
 - b) **I-shape** (vertical incision) – **Dr. Graham**: pull incision sides apart with silk tuck ups (helps to keep dura elevated away from brain tissue and vascular structures!) → suture in *diamond* shaped graft (may lay graft inside – easier to suture as dural edges clearly visible).
- patent **circular sinus** (esp. in kids) around foramen magnum can be encountered leading to brisk sinus bleeding – control with Gelfoam and bipolar cautery; if sinus is large, use **Weck clips**, divide and oversew sinus with dural sutures. At least some dural cuff should be left around vertebral artery so that dura can be repaired safely in this region.
- may preserve the arachnoid and prevent blood from entering the subdural space.



Tonsils are spread apart so that floor of fourth ventricle is visualized - to inspect for veils covering outlets of fourth ventricle - this re-establishes free flow of CSF from foramen of Magendie.

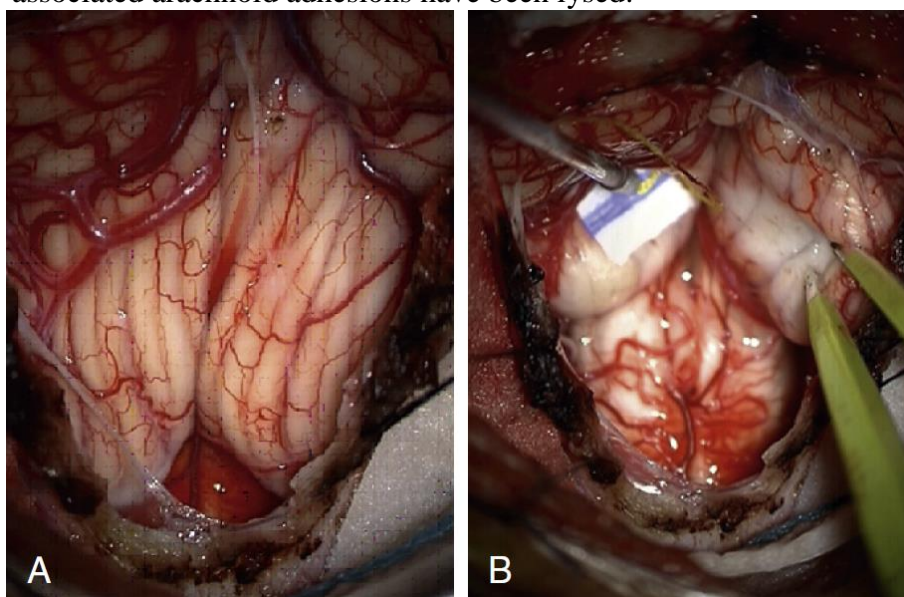


Source of picture: H. Richard Winn “Youmans Neurological Surgery”, 6th ed. (2011); Saunders; ISBN-13: 978-1416053163 >>

- see PICA wrapping around tonsils.
- consider visualization of choroid plexus of fourth ventricle and free flow of CSF into subarachnoid space as evidence of adequate decompression.
- release adhesions around tonsils.
- if CSF egress is limited, tonsils slowly dissected free from surrounding arachnoid tissue and elevated into field → **extrapial coagulation of one or both tonsillar tips** (gently caressing with prongs*) shrinks tonsils sufficiently to restore CSF flow (goal - tonsils should ascend above foramen magnum).

*ideally of ventral surface so it will not form adhesions on dorsal surface, but watch PICA and spinal accessory nerve

After bipolar coagulation, the cerebellar tonsils are above the level of the foramen magnum and any associated arachnoid adhesions have been lysed:



- if free CSF egress from fourth ventricle is not achieved after lysis of subarachnoid adhesions and tonsil coagulation:
 - a) tonsillar subpial resection (to visualize obex and floor of 4th ventricle) with pia coagulated with bipolar cauterization and closed with 6-0 Prolene.
 - b) consider **stent**.
- if dura is tight along cervical cord, cut inferior aspect of the dura laterally as described by Pirouzmand and Tucker to open the dura more widely.
- duraplasty using **DuraGuard** or **suturable DuraMatrix** with interrupted or running 4-0 silk/Prolene sutures → (two layers of Surgicel →).
 - **Drs. Collins, Cohen-Gadol** use harvested **pericranial flap** (may need to extend incision 5 cm superiorly) - avoids any issues with tissue compatibility, allergies, product recalls, sterility, or remote questions of transmission of bovine illness; pericranial graft is harvested before dural opening and is soaked in bacitracin irrigation to remove any blood or debris and keep the patch hydrated.
- check for CSF leakage with Valsalva (30 then 40 cmH₂O) → check with US again.
- cover with **Dura Seal** along suture line.
 - alternative - **blood patch**: 5-10 mL of patient's sterile peripheral blood from anesthesia mixed with a small amount of thrombin; as the mixture starts to coagulate, the blood is put over the suture line → second layer of Surgicel.

CLOSURE

- ± bone may be replaced using 2-0 PDS sutures or cranial plates; if Chiari decompression, bone maybe overlapped with occipital bone (alternative – titanium mesh or special “posterior fossa” plate).
- ± medium-sized Hemovac.
- neck muscles are gently approximated (avoid placing the *deep neck muscles under significant tension - “strangulation” by the deep sutures* - will cause muscle necrosis and uncontrollable postoperative pain).
- water-tight closure of fascia.
- staples or 3-0 Monocryl or nylon running for skin.

POSTOPERATIVE, COMPLICATIONS, FOLLOW UP

- see p. Dev7 >>
CSF leak – see p. S64 >>

LATERAL SUBOCCIPITAL CRANIOTOMY

Used resources

R. Nader “Neurosurgery Tricks of the Trade – CRANIAL“ (2014), ch. 13

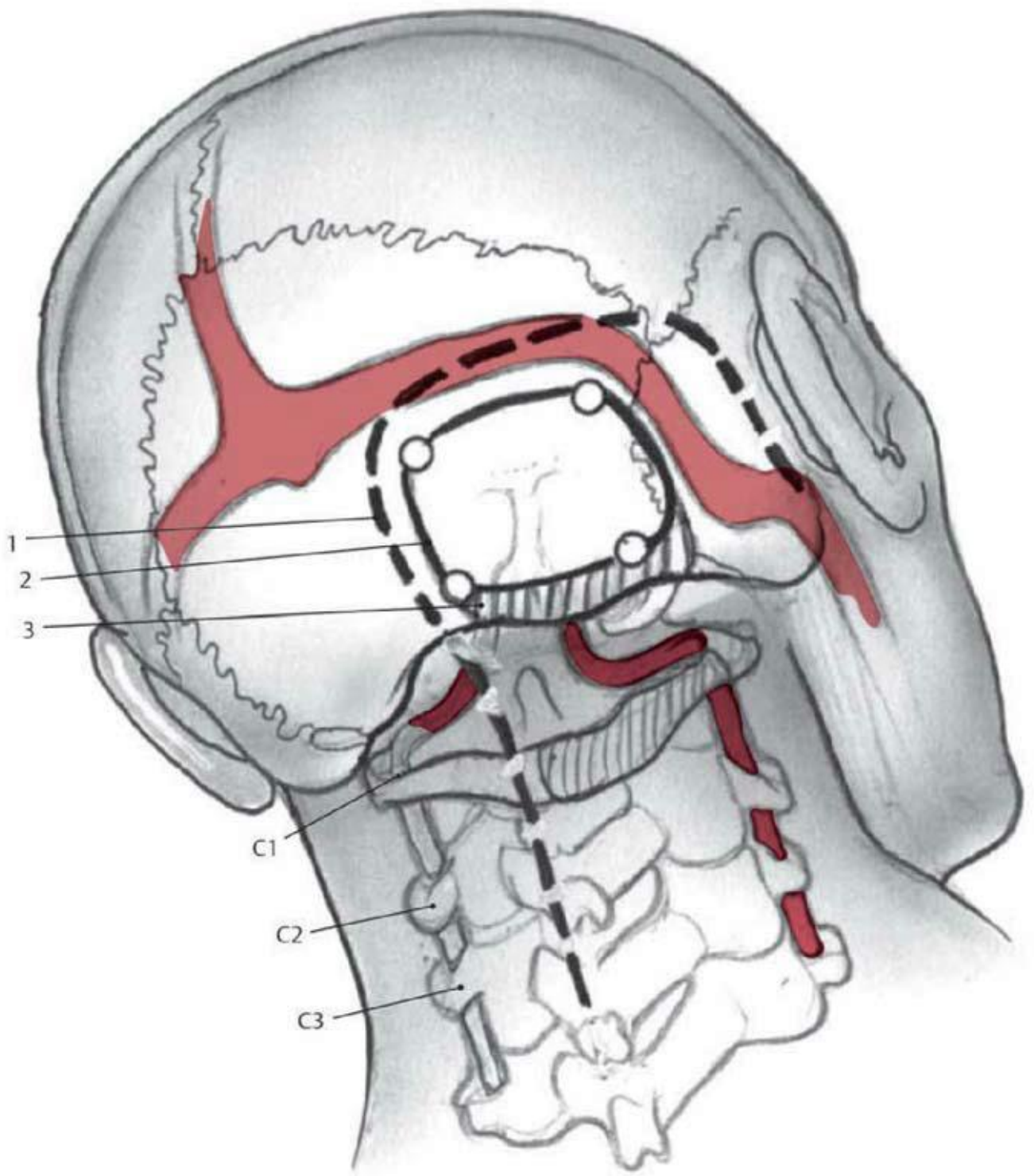
INDICATIONS

1. Exposure of the lateral cerebellar hemisphere, anterolateral brainstem, posterior aspect of petrous bone, craniovertebral junction, and upper cervical cord.
2. Building block for more extensive procedures, such as the transcondylar, far lateral, extreme lateral, and posterior petrosal approach.
3. Provides vertebral artery (VA) control, VA can be mobilized from the vertebral sulcus and foramen transversarium of C1.
4. Compared with the pre sigmoid approaches. it can provide access to lesions below the jugular tubercle.
5. It provides access to the lateral and sometimes ventral brainstem and cerebellum with minimal retraction.

ANESTHESIA

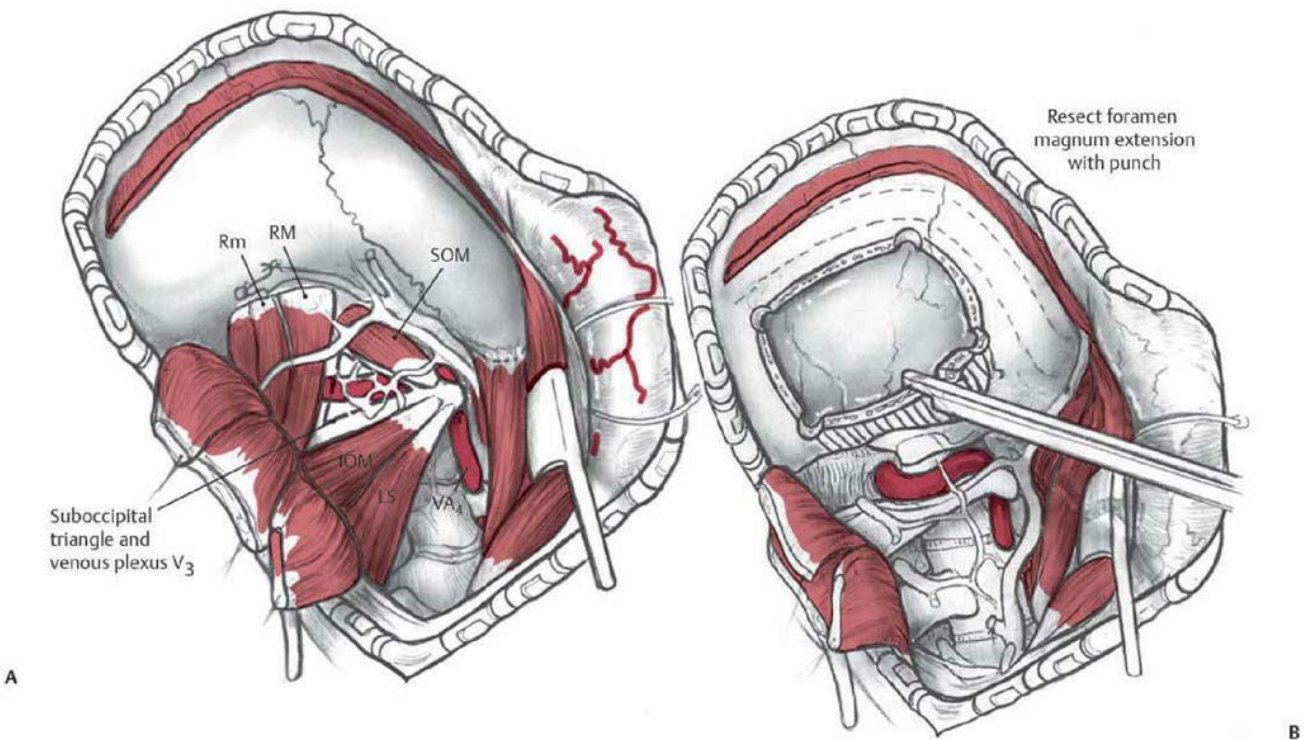
- be ready for **venous air embolism**.
- for lesions in the region of the jugular foramen, consider temporary cardiac pacing.

TECHNIQUE



- lateral oblique positioning, head flexed until nuchal muscles become firm
- J-shaped or "hockey stick" incision; starts at upper mastoid; leave muscle insertion cuff at superior nuchal line for later closure.
- VA lays in the floor of the suboccipital triangle (superior oblique, inferior oblique, and rectus capitis posterior major muscles); transverse process of C1 vertebra can be used as a localizing landmark for the VA.

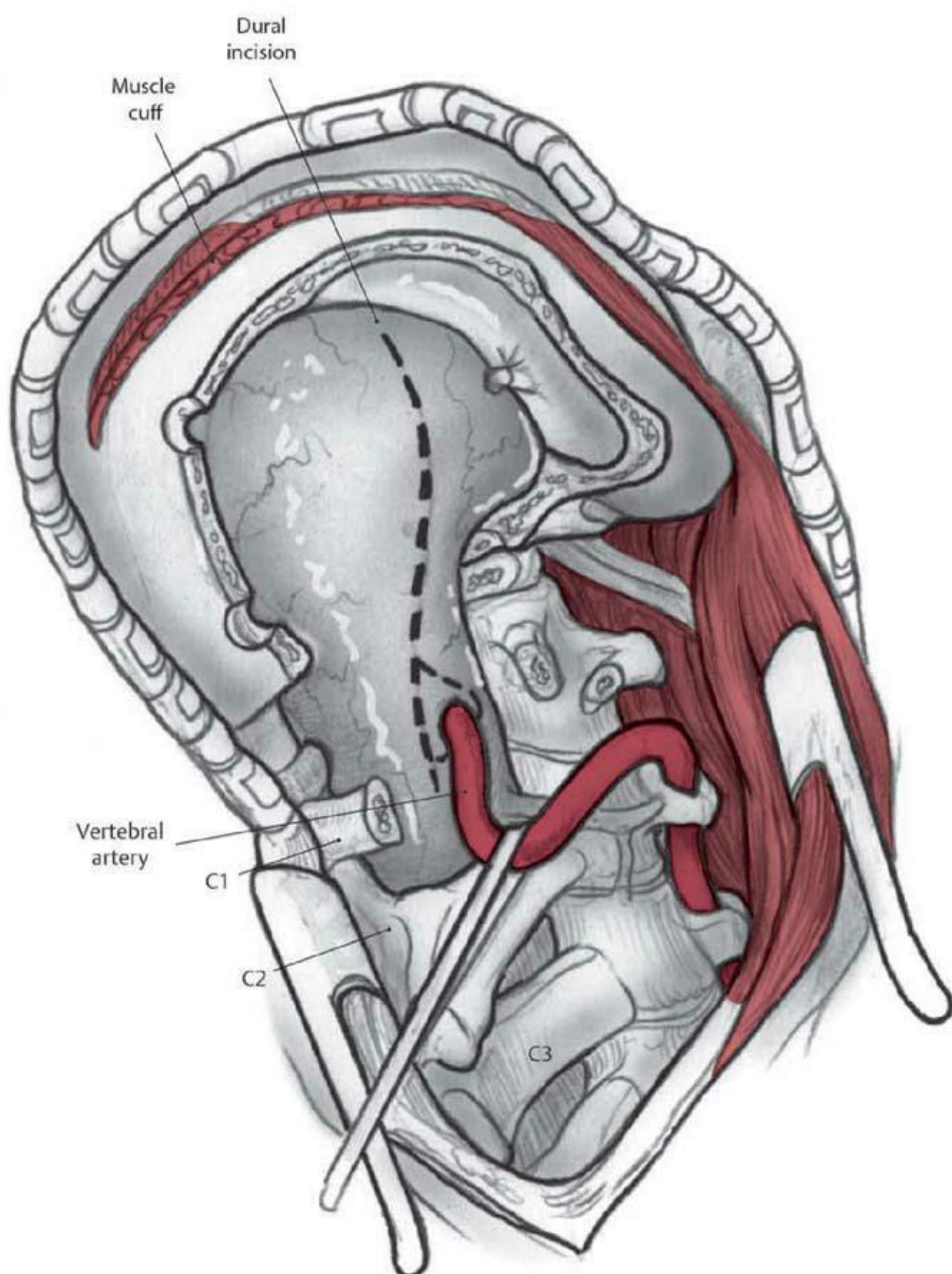
(A) Suboccipital triangle with vertebral artery and C1 transverse process located within the triangle. (B) Once the craniotomy is completed, the foramen magnum is opened with Kerrison rongeurs after the muscles of the suboccipital triangle have been reflected medially and the vertebral artery has been exposed. RM, rectus major muscle; Rm, rectus minor muscle; SOM, superior oblique muscle; IOM, inferior oblique muscle; LS, levator scapula; VA, vertebral artery.



- craniotomy can be done in two parts:
 - i. bone flap next to transverse sigmoid junction
 - ii. bone resected below the level of the craniotomy + C1 laminectomy.
- whenever drilling of the posterior part of the occipital condyle is necessary, subperiosteal dissection with the use of curettes will prevent injury to the VA
- VA injury can be minimized by avoiding rotation of the head once the patient is placed in the park bench position.

Fig. 13.3 Exposure down to the C3 vertebra is shown. A suboccipital craniotomy is being performed and the vertebral artery has been exposed. A curvilinear dural incision is performed with care taken to preserve the entry of the vertebral artery into the intradural space.

Exposure down to the C3 vertebra is shown. A suboccipital craniotomy is being performed and the vertebral artery has been exposed. A curvilinear dural incision is performed with care taken to preserve the entry of the vertebral artery into the intradural space.



When the procedure is combined with a posterior petrosectomy, the sigmoid sinus can be skeletonized and on occasion divided (if the dominant sinus is contralateral or in certain cases of codominance). Prior to permanently occluding the sinus, the pressure of the superior stump should be measured by placing a butterfly needle in the lumen and connecting it to a manometer. The VA can be mobilized if necessary. This can be achieved by continuing the subperiosteal dissection at the posterior arch of C1 up to the foramen transversarium, which can be opened, the VA mobilized and followed toward its entrance to the dural space.

The dura is opened at the level of the cisterna magna to allow cerebrospinal fluid (CSF) egression and subsequent relaxation of the brain surface. The incision extends vertically and posterolaterally parallel to the lateral edge of the craniotomy

POSTOPERATIVELY

NPO until speech therapist evaluates swallowing.

RETROSIGMOID (RETROMASTOID) CRANIOTOMY

term “suboccipital craniotomy” is still used, even though craniotomy now used rarely extends inferior to attachment of cervical muscles at uncus line

Used resources

R. **Jandial** “Core Techniques in Operative Neurosurgery” (2011), procedure 6

Pending resources:

<http://www.neurosurgicalatlas.com/grand-rounds/retromastoid-craniotomy-expanding-the-operative-corridor>

INDICATIONS

CPA angle lesions (acoustic neuroma, MVD for trigeminal neuralgia, etc)

PROCEDURE

LOCATION OF ASTERION

- see above >>

POSITION

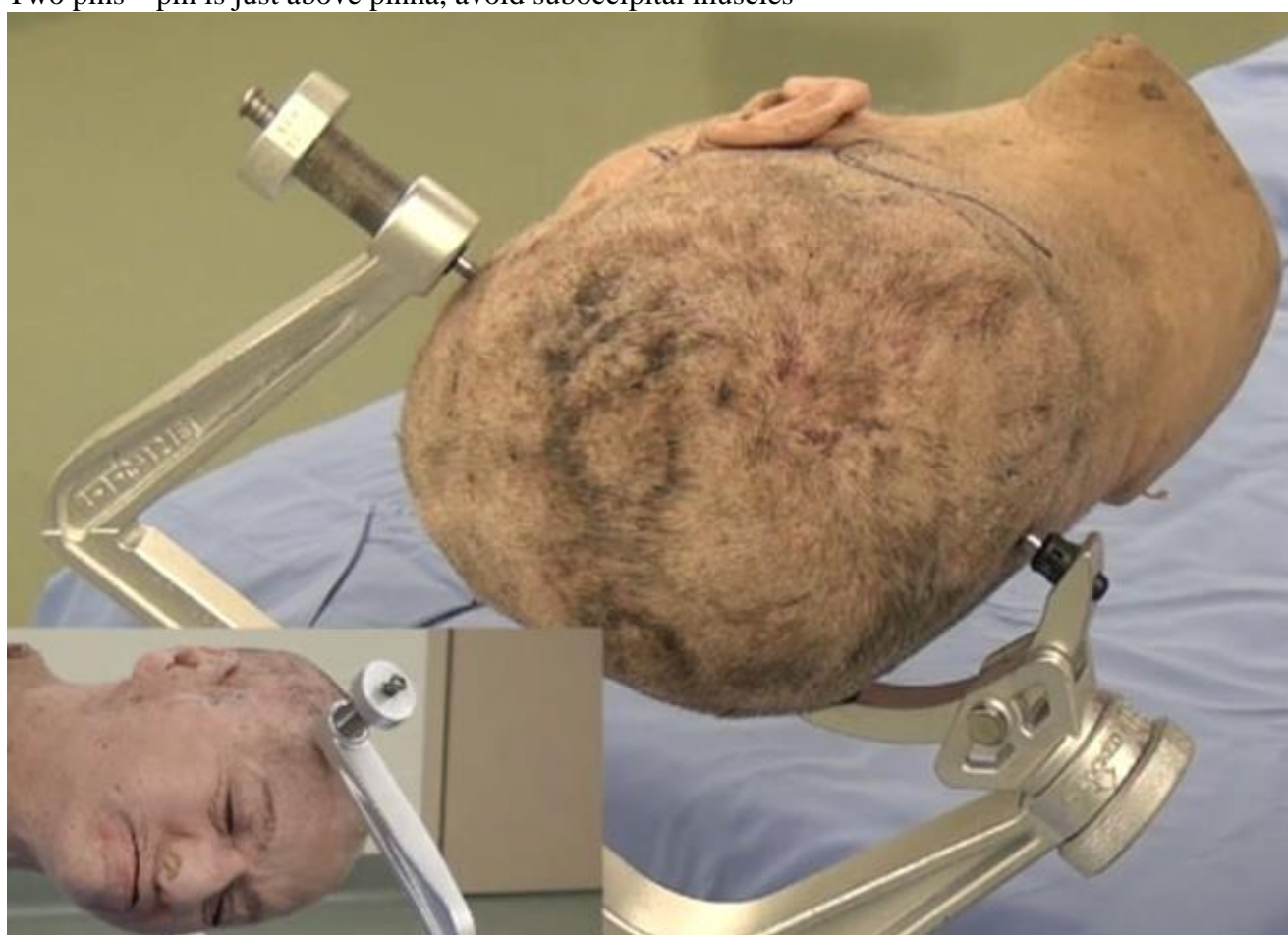- lateral decubitus (“park bench”)**; neck is flexed (chin tuck) and vertex is tilted towards floor
 - roll (towel or gel) under axilla!
 - upper shoulder is also tilted anteriorly (to give more space)
- semisitting position** with neck flexed and face rotated away from side of surgery (ipsilateral tentorium parallel to floor).

ELECTROPHYSIOLOGICAL MONITORING

- 1) bilateral auditory potentials (BAER)
 - 2) EMG of facial muscles.
- cover ear with Tegaderm – keeps equipment in the pinna and prevents prep solution spill into ear canal.

PIN PLACEMENT

Single pin – just above superior temporal line, behind hairline
 Two pins – pin is just above pinna, avoid suboccipital muscles



INCISION

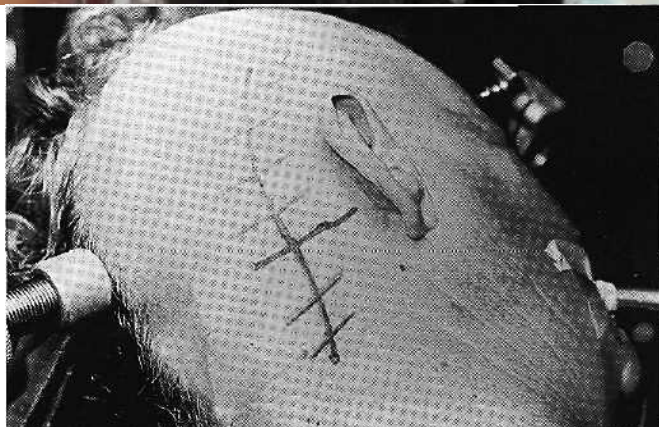
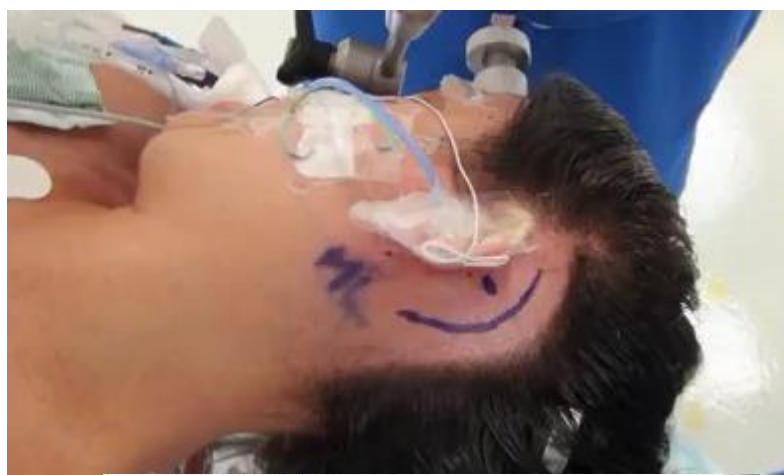Incision #1

Vertical or slightly curvilinear (*lazy-S*) vertically behind auricle, 1-2 fingerbreadths behind hairline central incision third behind ear (1/3 of incision is above **transverse-sigmoid junction** and 2/3 are below)

Alternative: 2 cm superior to the pinna and ending two fingerbreadths below the mastoid tip

Dr. Graham uses vertical incision just beyond digastric groove.

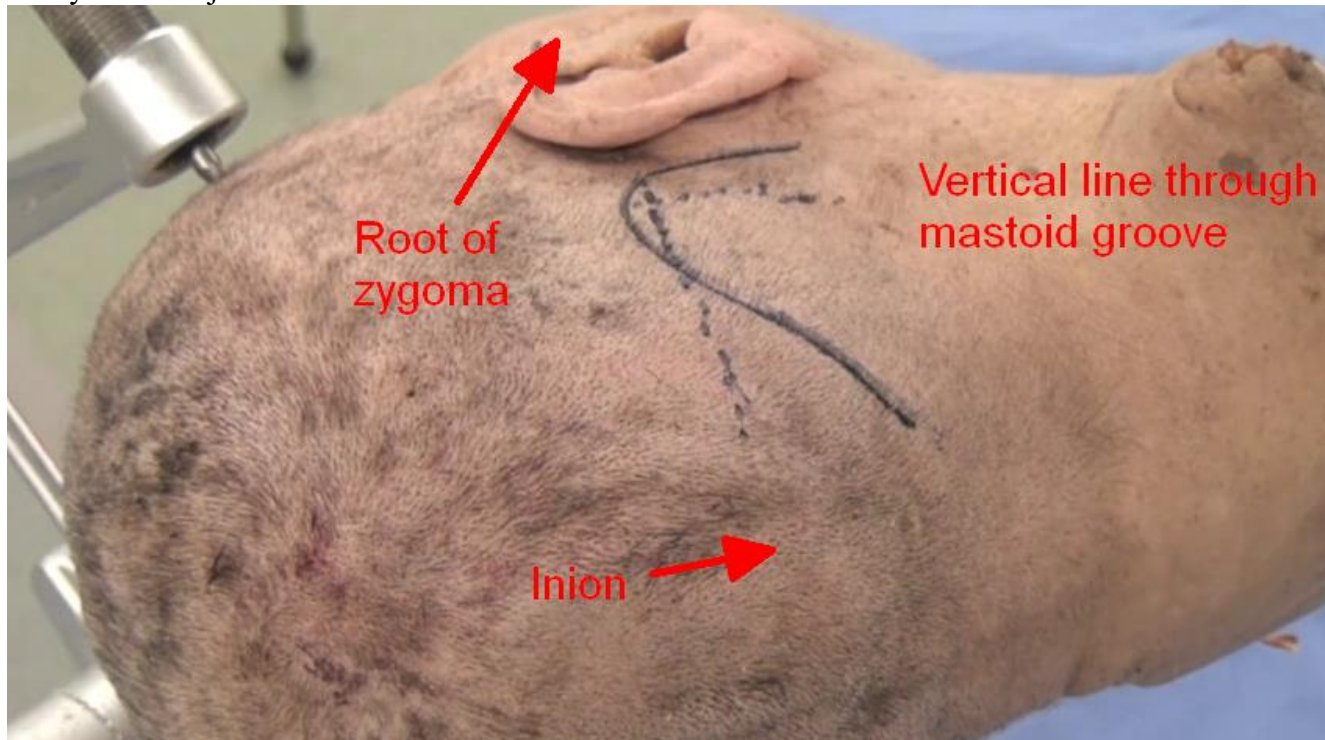
Dr. Broaddus uses lazy-C incision and lower portion goes rather low on neck.

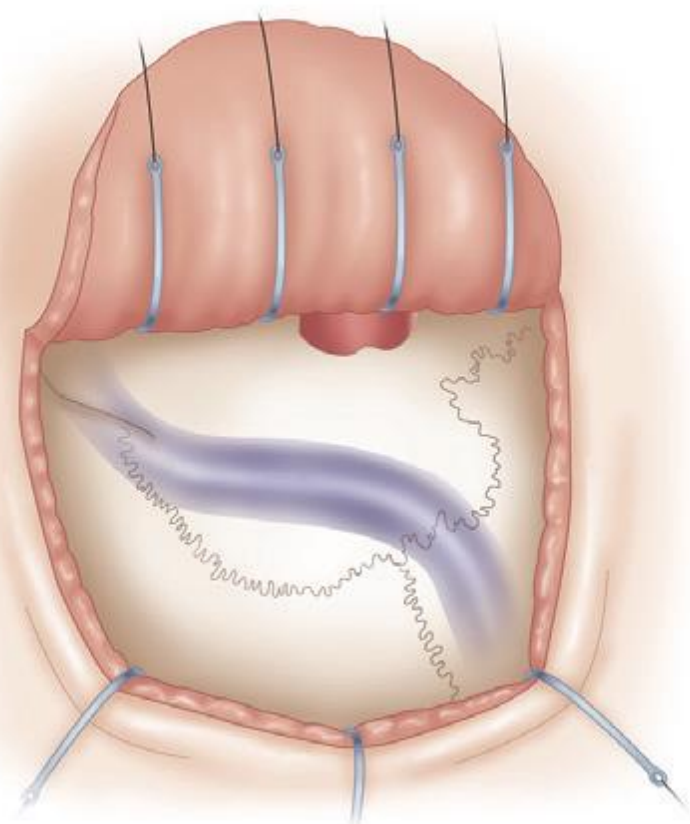


Source of picture: Marshall B. Allen, Ross H. Miller "Essentials of Neurosurgery: a guide to clinical practice", 1995; McGraw-Hill, Inc.; ISBN-13: 978-0070011168 >>

Incision #2

"Lazy lambda" just above asterion:

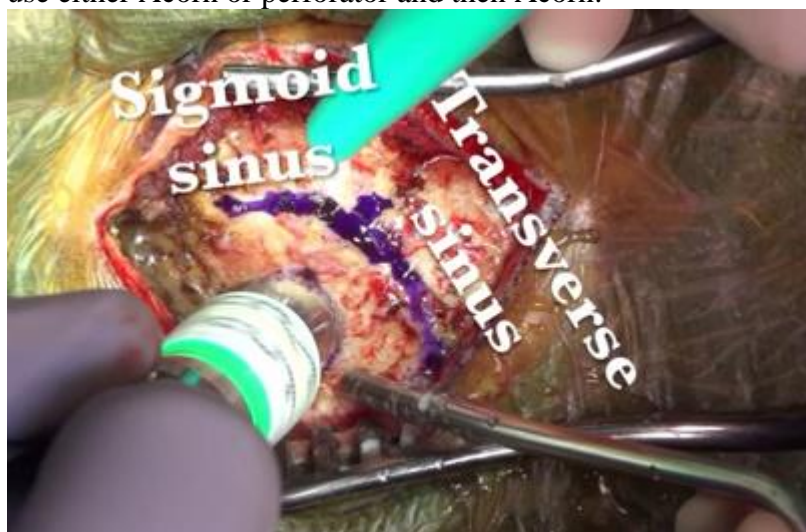



- use fishhooks (less bulky than cerebellar retractor).

CRANIOTOMY

- for MVD - small (3x3 cm) oval retrosigmoid craniectomy with Acorn drill bit and Kerrison rongeur, targeting corner of transverse-sigmoid venous sinus junction (neuronavigation is very helpful here for localizing transverse-sigmoid sinus junction and tailoring craniotomy); exposed mastoid air cells are sealed with bone wax.
- for vestibular schwannoma – larger craniotomy, extend along sigmoid sinus and posteriorly to allow cerebellar retraction.
- use either Acorn or perforator and then Acorn:



- any exposed mastoid air cells are carefully waxed off (to prevent postoperative CSF leak).
- dura is opened in T shape (T “leg” towards transverse-sigmoid sinus junction) - cerebellum is visualized.
- operative microscope
- gentle retraction of cerebellum inferiorly and medially; arachnoid membrane fenestration with CSF cistern decompression to expose cerebellopontine angle.
- petrosal vein is coagulated and cut; however, it is possible to preserve it.
- for MVD – see p. Op400 >>
- dura is closed with running 4-0 silk sutures and reinforced with DuraSeal and Duragen patch (Duragen may sit under dura).

- a) craniotomy – either simple bone flap replacement or use HydroSet (if mastoid air cells were exposed)
- b) craniectomy - cranioplasty with titanium mesh and methyl-methacrylate or with Hydroset.

EXTENDED RETROSIGMOID CRANIOTOMY

- adding bony skeletonization of the sigmoid and transverse sinuses with additional mastoidectomy.
- permits access to areas that are difficult to access with the classic approach—ventral to the brainstem and near the tentorium.
- in older patients with adherent but thin dura, craniectomy as opposed to a craniotomy should be performed over the sinuses (i.e. sinuses are unroofed with a series of cutting and diamond drill bits).

PREOP

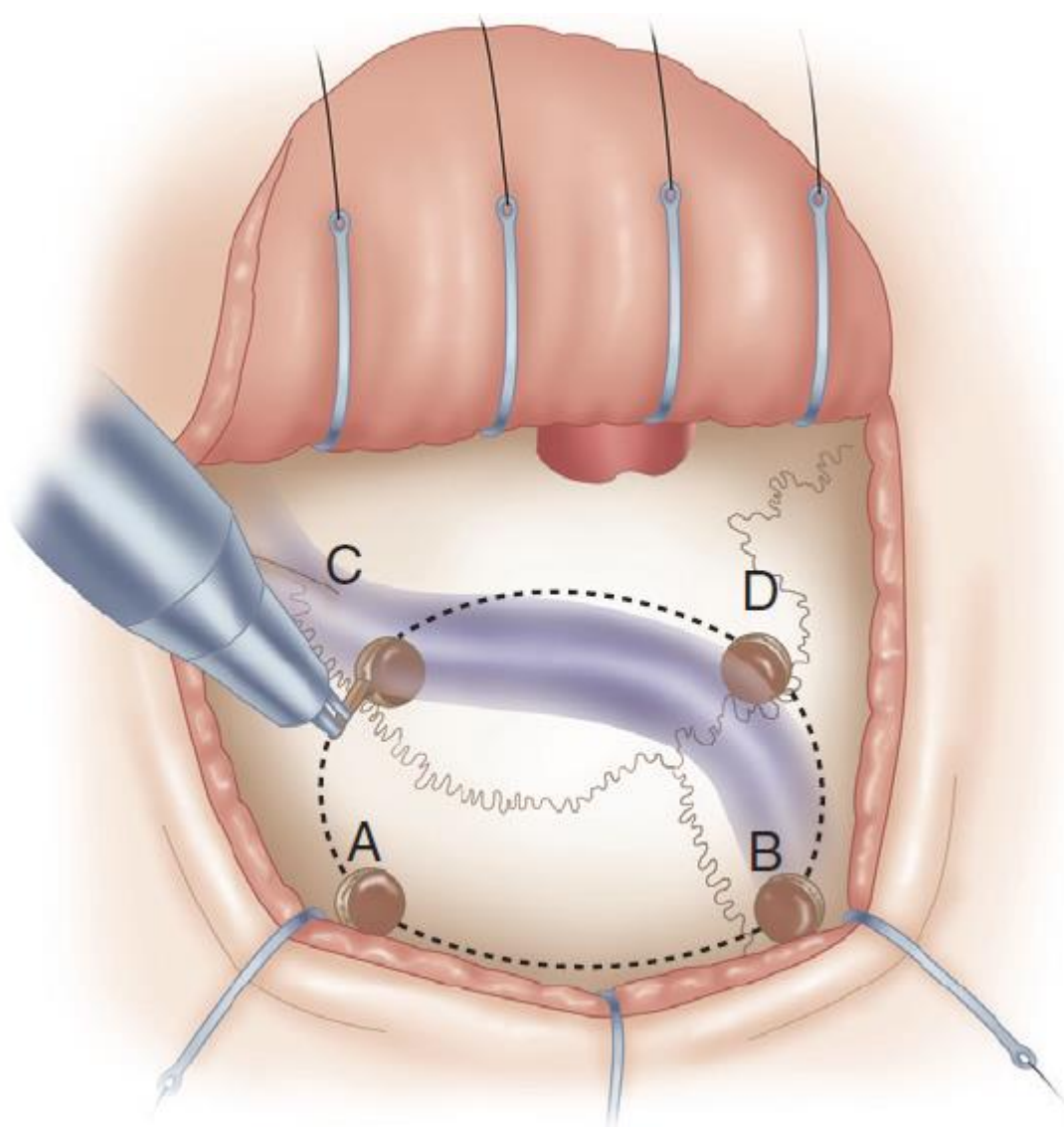
- MRV is obtained to ensure that contralateral venous sinuses are patent before manipulation of the transverse and sigmoid sinuses ipsilaterally.
- after anesthesia induction, multichannel central line and precordial Doppler is placed - early intraoperative detection and management of air embolism.

TECHNIQUE

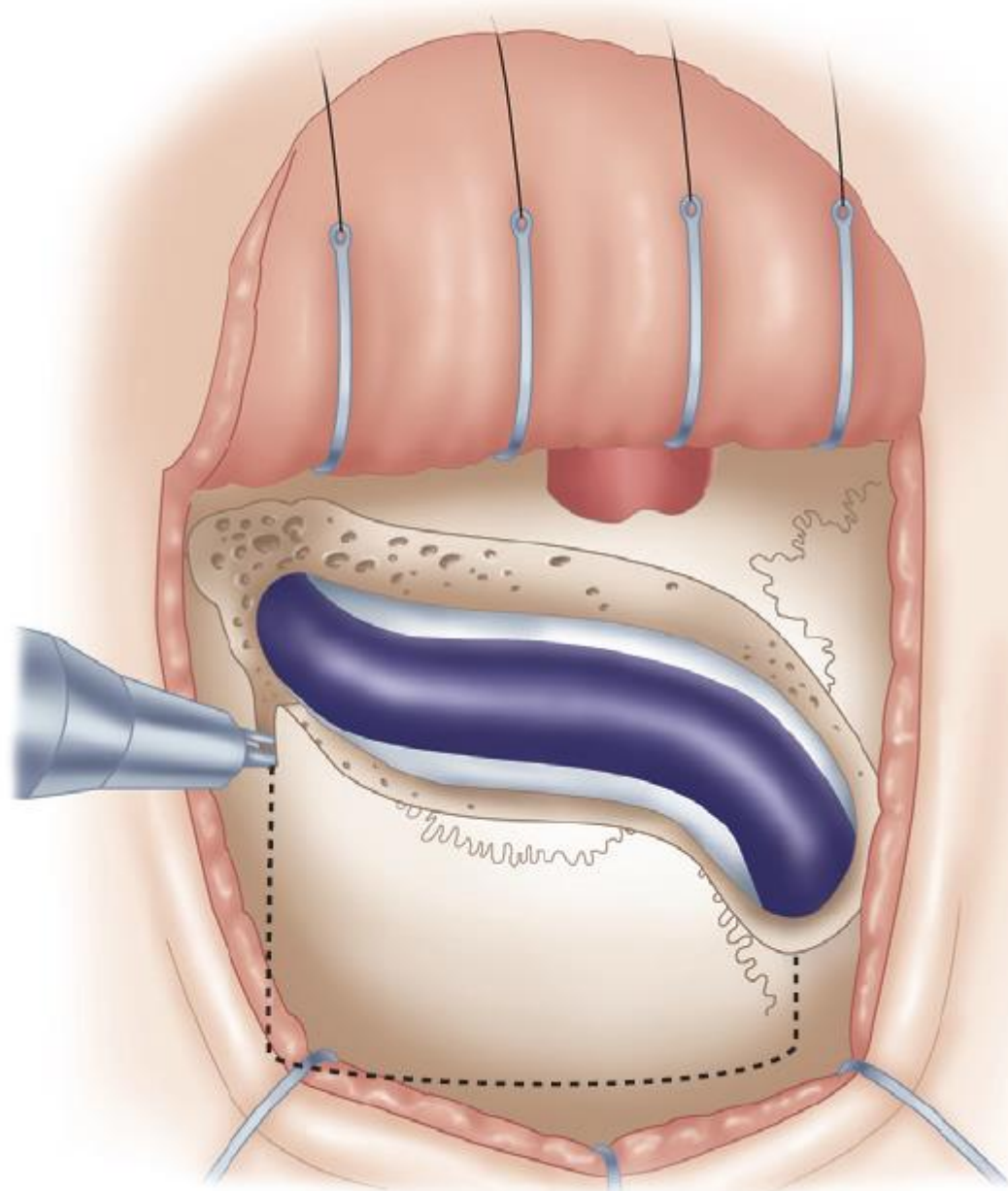
Osteotomies consist of two conceptual components:

1. Retrosigmoid craniotomy with skeletonization of the venous sinuses
2. Limited posterior mastoidectomy (if needed) for exposure of the jugular bulb

Four burr holes are placed in the following order: inferiorly over cerebellar hemisphere (A), over the transverse sinus proximal to the transverse-sigmoid junction (placed slightly supratentorial so that the entire sinus can be exposed) (B), over the sigmoid sinus as it enters the jugular foramen (C), and over transverse-sigmoid junction but slightly supratentorial (D). With a Penfield No. 3, careful epidural dissection is performed to separate the dura and the venous sinuses. A craniotome is used to connect all the burr holes and create a free bone flap.



Process of the limited posterior mastoidectomy begins with a cutting bur but then transitions to a diamond bur as the veil of blue to visualize through a thin eggshell rim of bone. mastoid emissary vein may be encountered;



SUPRACEREBELLAR INFRATENTORIAL APPROACH

<http://www.neurosurgicalatlas.com/grand-rounds/supracerebellar-approach-expanding-the-operative-corridor>

Panaudota literatūra:

R. Jandial "Core Techniques in Operative Neurosurgery" (2011), procedure 10

Skaityk:

Badie: 206-214, 42-54

INDICATIONS

- lesions of:

- 1) pineal region
- 2) posterior third ventricle
- 3) posterior mesencephalon
- 4) amygdala-hippocampus. see p. E15 >>

CONTRAINDICATIONS

- steeply angled tentorium (H: occipital transtentorial approach)

PREOPERATIVE

- preoperative **bubble cardiac Doppler study** - to rule out any possible cardiac shunting or patent foramen ovale (**right-left shunt** ← contraindication for the sitting position).
- **magnetic resonance venography** - relationship of deep venous structures (vein of Galen, basal vein of Rosenthal, internal cerebral veins, and straight sinus) in relation to trajectory and tumor.
- **MRI** - degree of tumor infiltration into surrounding critical neural structures (e.g., midbrain, thalamus); surgical navigation is recommended.

PROCEDURE

- for patients with hydrocephalus, **occipital EVD** >> is placed before soft tissue dissection; also facilitates brain relaxation and decompression of posterior fossa.

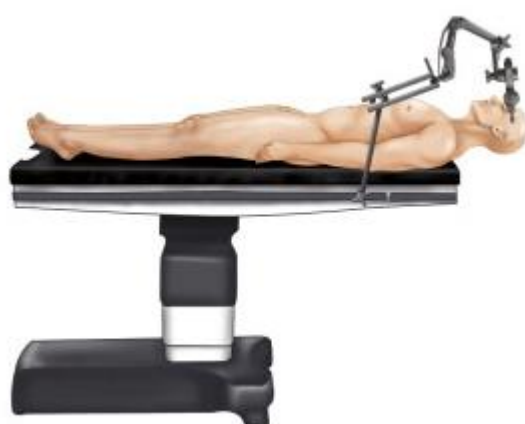ANESTHESIA

Air embolism measures

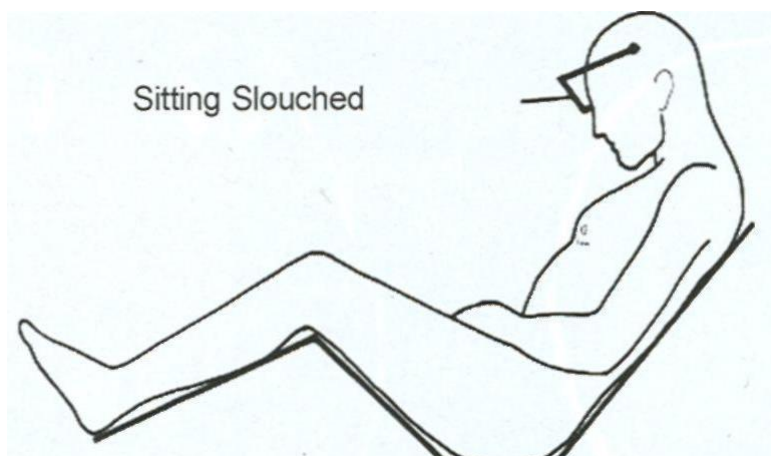
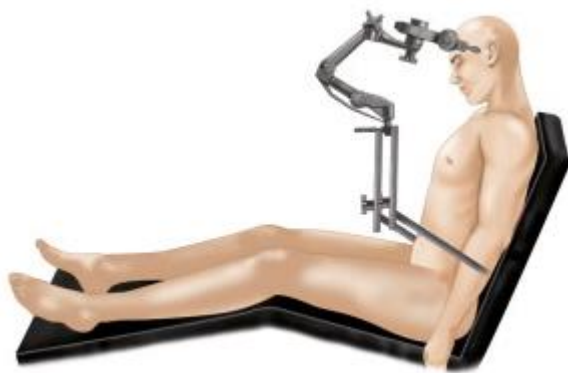- **precordial Doppler ultrasonography** - most sensitive of detecting intracardiac air.
 - **end-tidal CO₂** monitoring
 - place **central venous catheter with multiple orifices** - for aspirating air from circulation should venous air embolism occur.
- patient should be extubated with a reasonable degree of head gatch to avoid shifting of the decompressed brain within the cranial vault.

POSITIONING

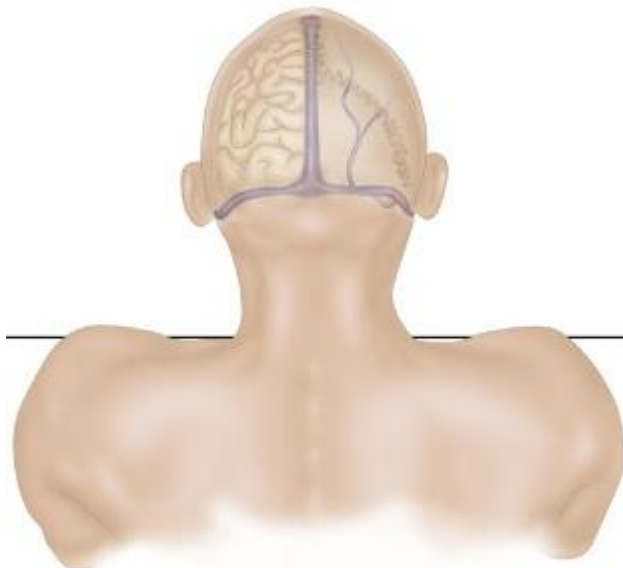
- A. Prone position – only if patient has **patent foramen ovale**, given risk of air embolism with sitting position.
 - B. Sitting position – **preferred** – permits cerebellum to fall with gravity away from tentorium, prevents pooling of venous blood in operative field.
- first place supine on operative table (with reverse orientation):



- after application of Mayfield holder, bed is maneuvered to raise patient's back and flex legs (elevate legs to promote venous return):



- head is flexed to place **tentorium parallel to floor**:



- at least two fingerbreadths of space is needed between patient's chin and sternum - to avoid airway compromise and obstruction of venous return from head.

DISSECTION

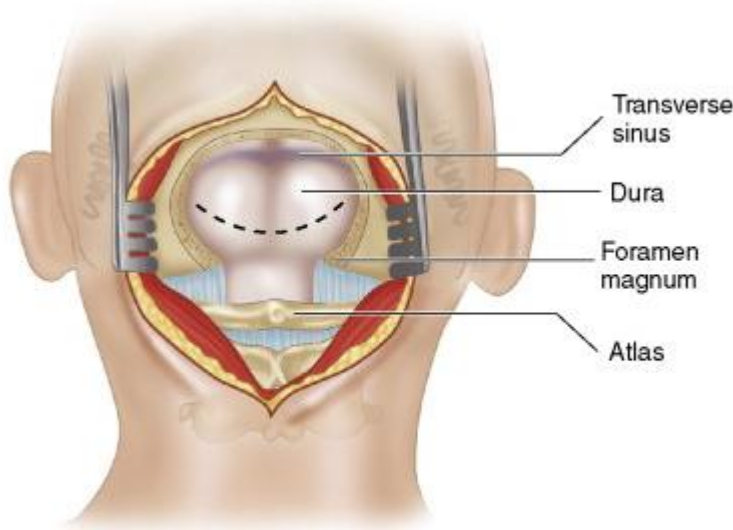
- skin incision from above inion down to approximately C2-4.
- suboccipital craniotomy (musculature is not detached from spinous processes of C1-2)
- burr holes are placed on each side of superior sagittal sinus (right above torcular Herophili) + superior and inferior to each transverse sinus, few centimeters distal to torcular Herophili.

From Badie:

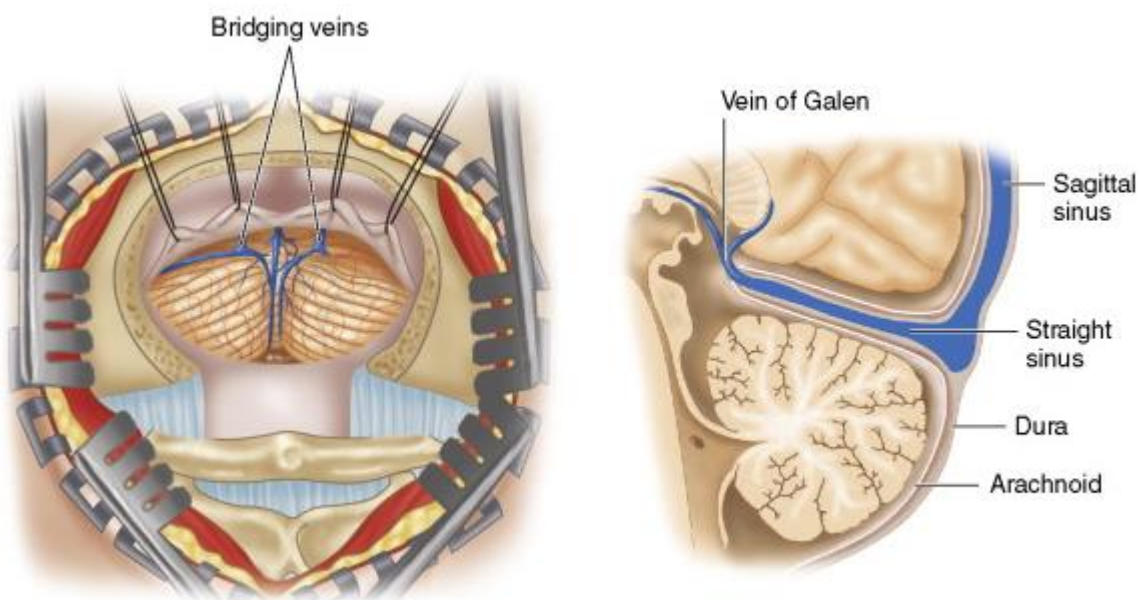
Four bone slots are drilled, one over the sagittal sinus just above torcular, one over each transverse sinus, and a final slot in the midline 1 to 2 cm above the foramen magnum. A craniotome is used to connect the slots, allowing the bone flap to be elevated. There should be sufficient bone removed

above the transverse sinus to ensure an unperturbed view down the tentorium. Bone edges should be carefully waxed, and venous bleeding controlled to avoid air emboli.

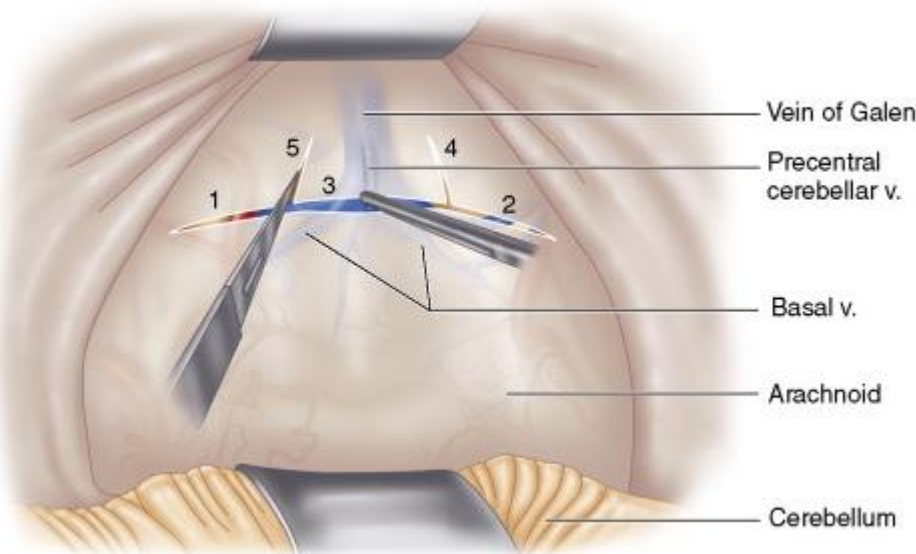
- craniotome is used to connect burr holes to create bone flap.
 - craniectomy is possible option, but craniotomy is preferred to reduce postoperative pain, fluid collections, and aseptic meningitis
- if there is evidence of preoperative tonsillar descent, foramen magnum can be removed in addition to C1 laminectomy.
- dural incision - semilunar or cruciate - based on transverse sinuses and torcular Herophili and reflected superiorly with tenting sutures (be cognizant of retraction placed on venous sinus when reflecting dural flap!):



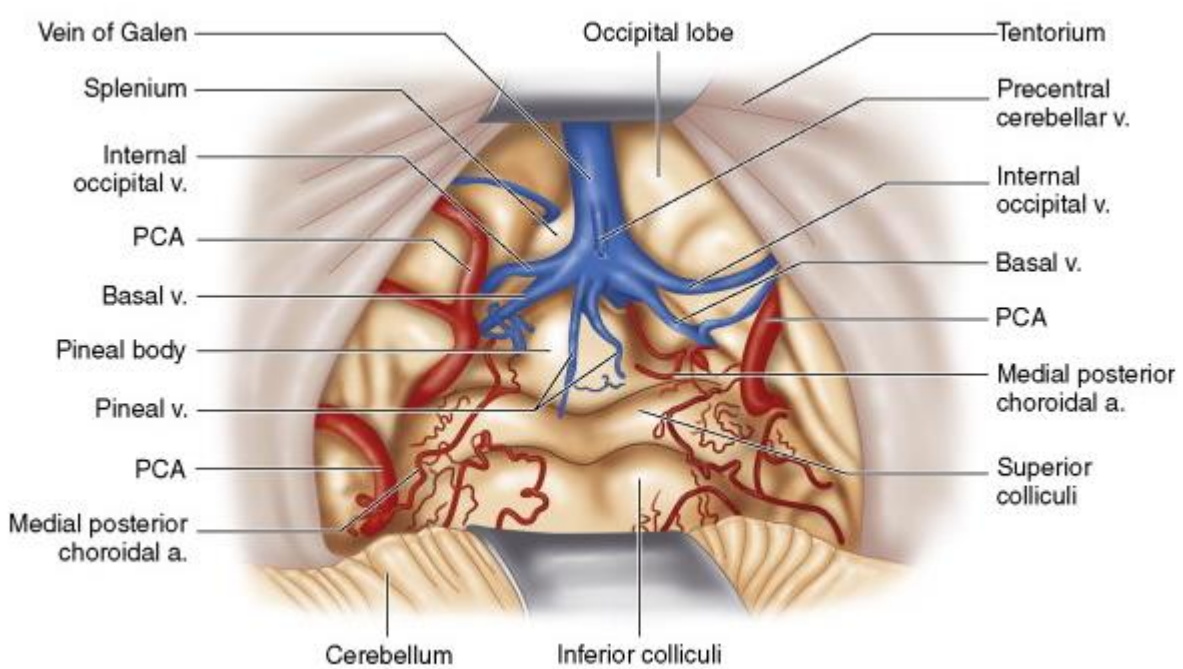
- *if angle of tentorium is too steep*, craniotomy can be extended for occipital transtentorial approach, or tentorium can be cut and retracted via supracerebellar approach.
- **arachnoid adhesions and bridging veins** between cerebellum and tentorium are divided to open supracerebellar infratentorial corridor.
 - *bridging veins should be divided close to cerebellum* to prevent retraction of inaccessible bleeding sources back into tentorium.
 - as this process of dissection proceeds, cerebellum falls with gravity, and **Greenberg retractor** can be placed on tentorium if necessary.



- thickened arachnoid overlying pineal gland and quadrigeminal cistern is exposed and sharply dissected open.
 - **precentral cerebellar vein** is visualized (draining into vein of Galen) – it is the only deep venous structure that should be cauterized and divided:



- normal anatomy when exposure is achieved and cerebellar retraction occurs (N.B. vascular structures and neural structures may be shifted to nonanatomic positions by tumor)



COMPLICATIONS

AIR EMBOLISM

- preop *transthoracic echocardiography* to detect any **right-left shunt** ← contraindication for the sitting position.
- cover torcular Herophili sinus area with wet laparotomy pads
- flood field with saline
- lower patient's head.
- use central venous catheter to retrieve any large emboli

FAR-LATERAL SUBOCCIPITAL APPROACH

NREF video >>

Rhoton video: <http://rhoton.ineurodb.org/?page=23441>

Used sources:

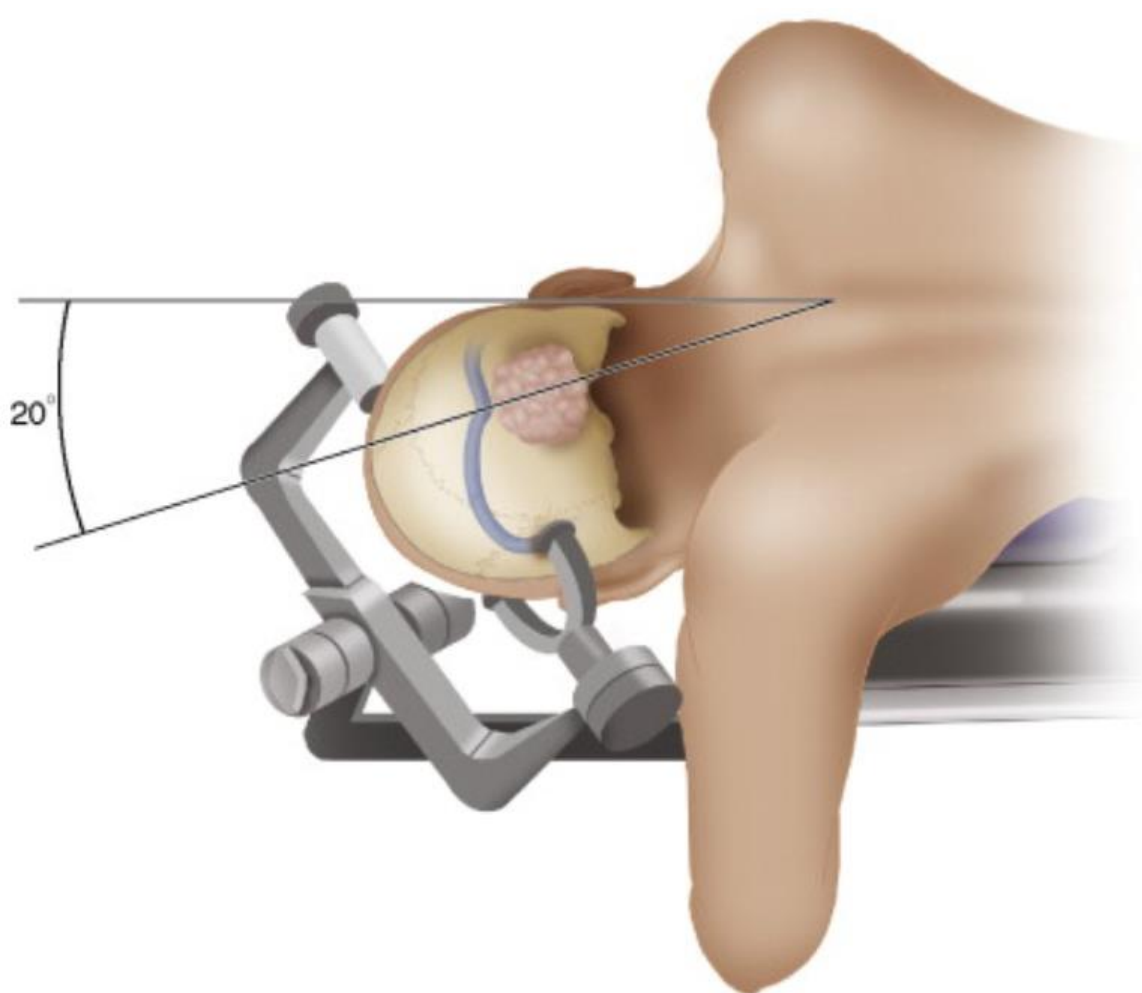
R. **Jandial** "Core Techniques in Operative Neurosurgery" (2011), procedure 17

INDICATIONS

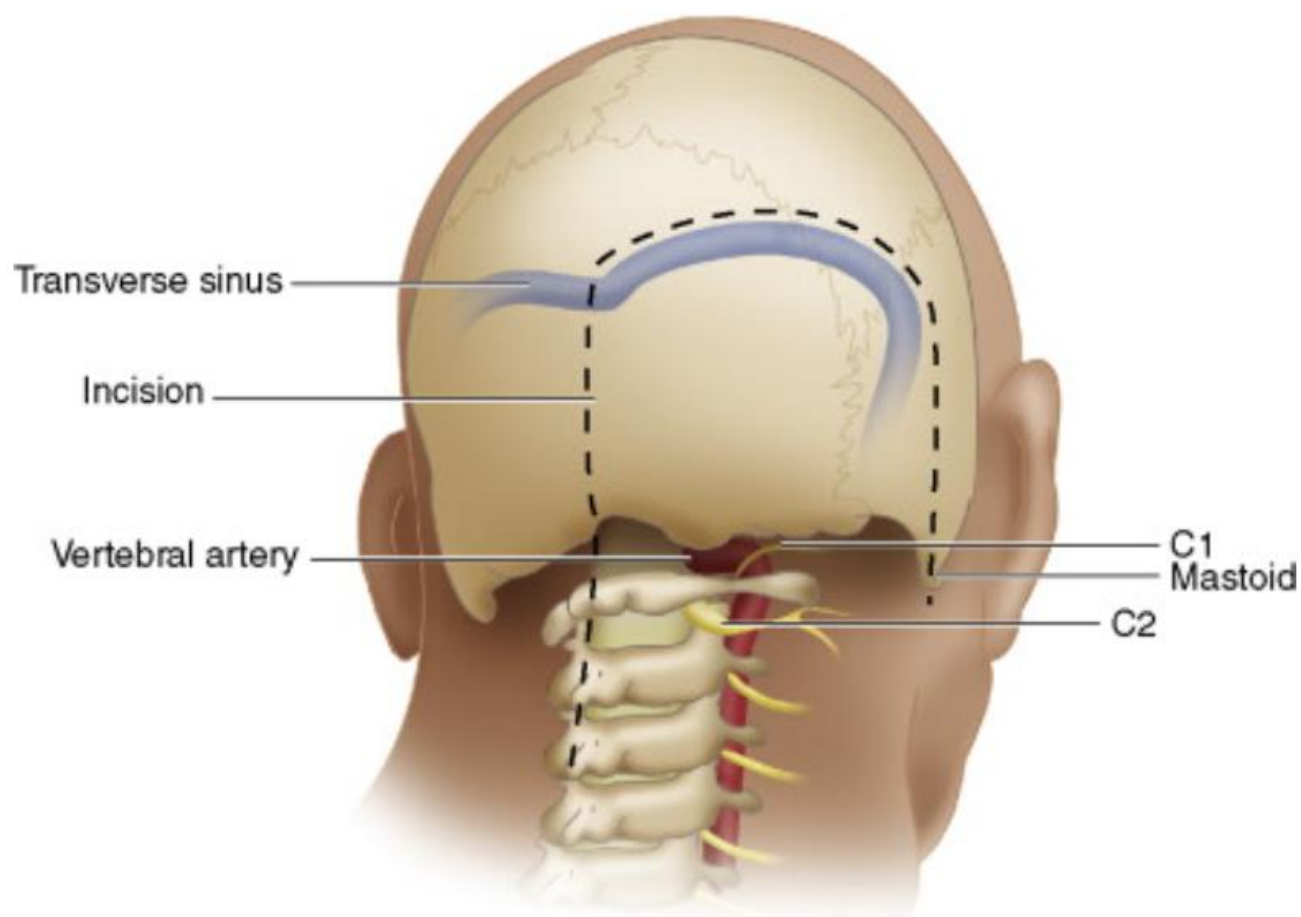
- suboccipital approach with C1 laminectomy provides adequate visualization of approximately 270 degrees of the circumference around the medulla; it does not provide **access to the 90 degrees anterior to the medulla**, however, because the visual angle needed to see this region is obscured by the occipital condyle, which must be drilled to allow access along this visual trajectory.
- allows good proximal vascular control (on vertebral arteries); good approach for PICA aneurysms.
- muscular bulk in the midline approach performed in a conventional suboccipital craniectomy effectively limits the surgeon's ability to dissect safely laterally enough to visualize the extracranial vertebral artery and to drill away the posterior occipital condyle.
- limits of this approach are the **ventral clivus** and **brainstem above the pontomedullary junction**.
- it is like retrosigmoid approach just more inferior.

PROCEDURE

- positioning is the most complex of any common neurosurgical procedure.
- table at least 120 degrees away from the anesthesia team
- **three-quarter prone position** with the contralateral shoulder down
- superior (ipsilateral) shoulder is in mild flexion on an arm rest in mild flexion. The contralateral arm is draped off the edge of the bed and placed in a shoulder sling, which is secured to the edge of the bed with towel clamps
- two Mayfield pins placed just behind the contralateral occiput. The single pin is placed in the ipsilateral frontal bone, above the superior temporal line. After pinning, the head is slightly flexed, rotated toward the contralateral shoulder, and elevated slightly.
- theoretical goal of head positioning is to place the posteromedial portion of the ipsilateral occipital condyle at the highest point in the room. By doing so, the corridor of attack just medial to the condyle is placed basically vertical, maximizing the retraction obtained by gravity.
- it is important to check motor and sensory evoked potentials before and after positioning and to adjust the positioning if there are adverse changes from baseline. We have done these cases with the patient awake in some instances when positioning without neuromonitoring changes was impossible while the patient was asleep

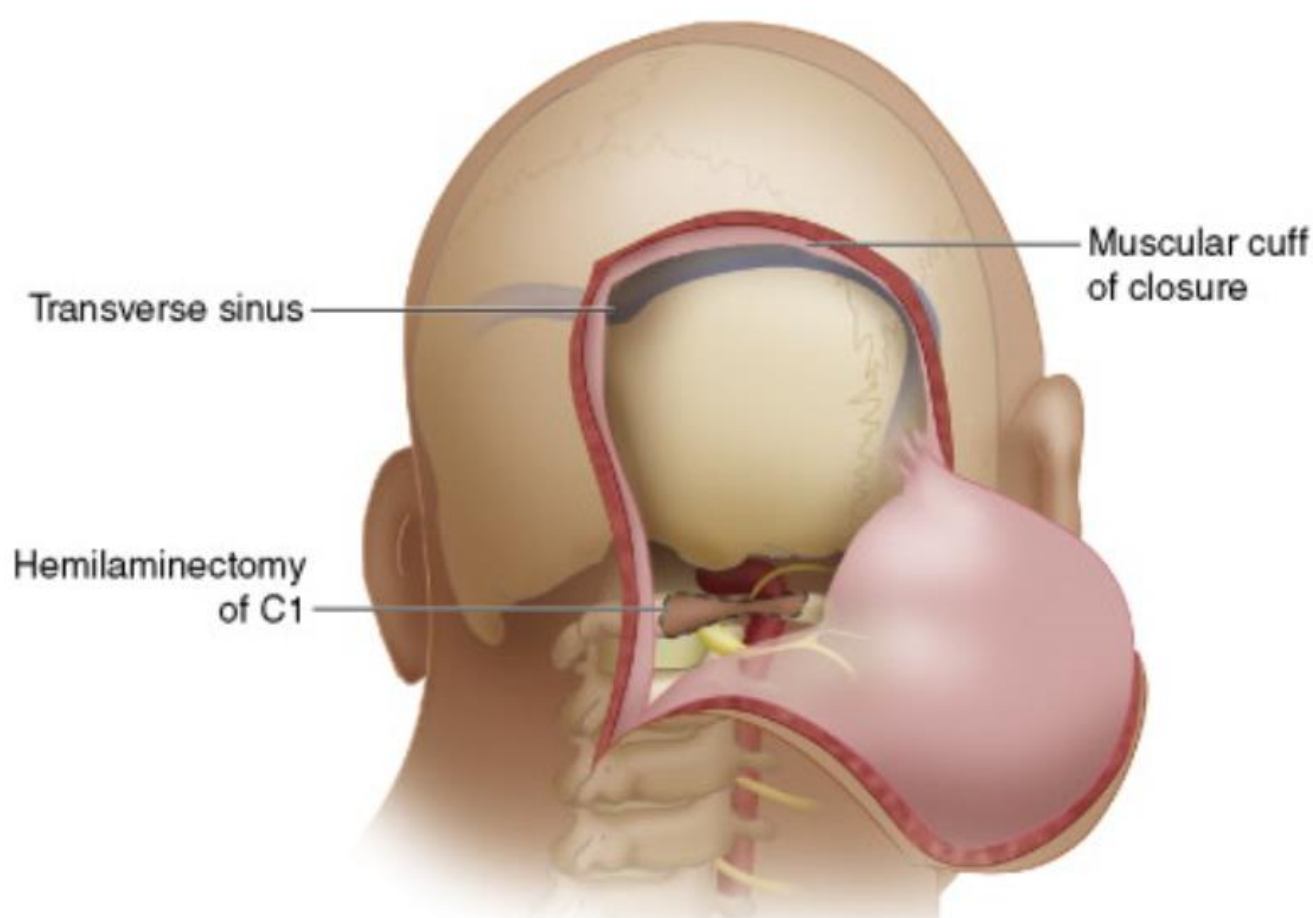


Incision

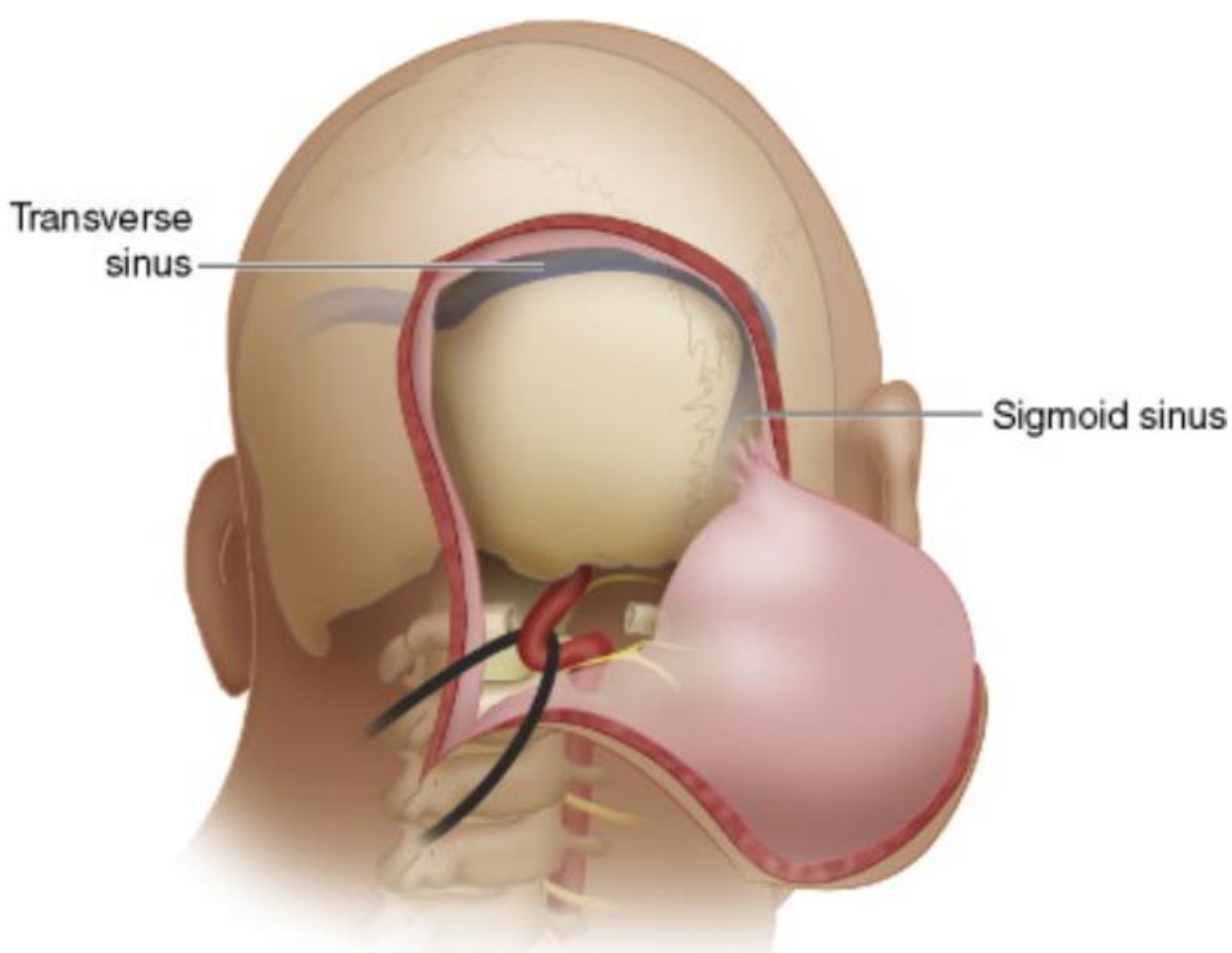


- hockey stick-shaped, consisting of three unequal-length limbs that are roughly perpendicular to each other. The long limb of the incision is midline and begins just below the spinous process of C3 and extends to just above theinion. The horizontal incision extends laterally from just above theinion to just above the mastoid tip. The short limb of the incision begins just below the mastoid tip and extends upward to meet the horizontal limb. This incision parallels the transverse and sigmoid sinuses and provides the ability to fold the myocutaneous flap laterally enough to expose the entire hemiocciput and the arch of C1 out to the tip of the transverse process.
- big mastoid emissary vein is likely – will bleed a lot.

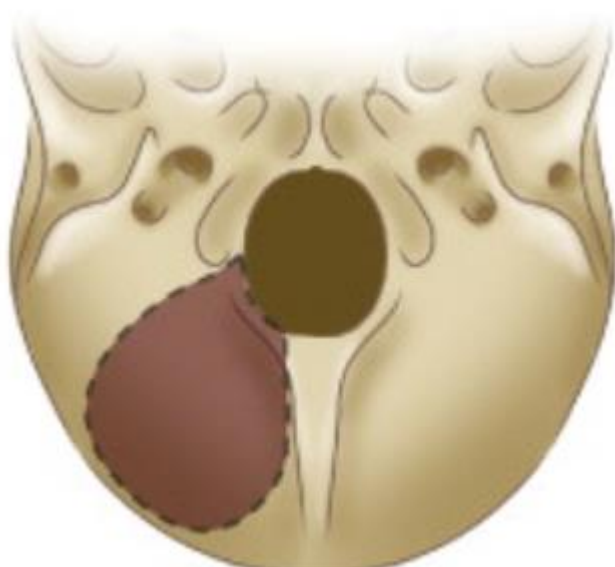
- if needed now can dissect occipital artery from inside of flap (alternative strategy to find occipital artery in the more superficial layer is more difficult); find the origin of artery first – medial to digastric groove.



- soft tissue dissection is performed with a combination of periosteal dissectors and monopolar cautery to expose three key landmarks in their entirety. The hemiocciput should be cleared of soft tissue down to the foramen magnum; once muscle attachments are taken, switch Bovie to periosteal to finalize towards foramen magnum. Also, the mastoid process should be exposed down to the point where the mastoid tip begins to curve medially and anteriorly until the mastoid curves anteriorly.
- Finally, the lamina of C1 should be exposed laterally until the tip of the C1 transverse process can be palpated under the superior and inferior oblique muscles of the suboccipital triangle.
Sulcus arteriosus – where vertebral artery along with C1 root are travelling
- It is important to remain oriented to the spinal midline; this can be confusing because of the degree of head rotation in this position, which is much greater than the typical suboccipital approach. A loss of one's sense of midline not only can increase blood loss owing to muscle dissection, but also can lead to inappropriate trajectories toward critical structures such as the vertebral artery. For this reason, we begin this approach by finding the intramuscular septum early and cautiously identifying the spinal midline and exposing the C1-3 hemilamina from medial to lateral until the C1 transverse process can be palpated.
- During muscle dissection, it is possible to encounter large muscular branches of the vertebral artery.



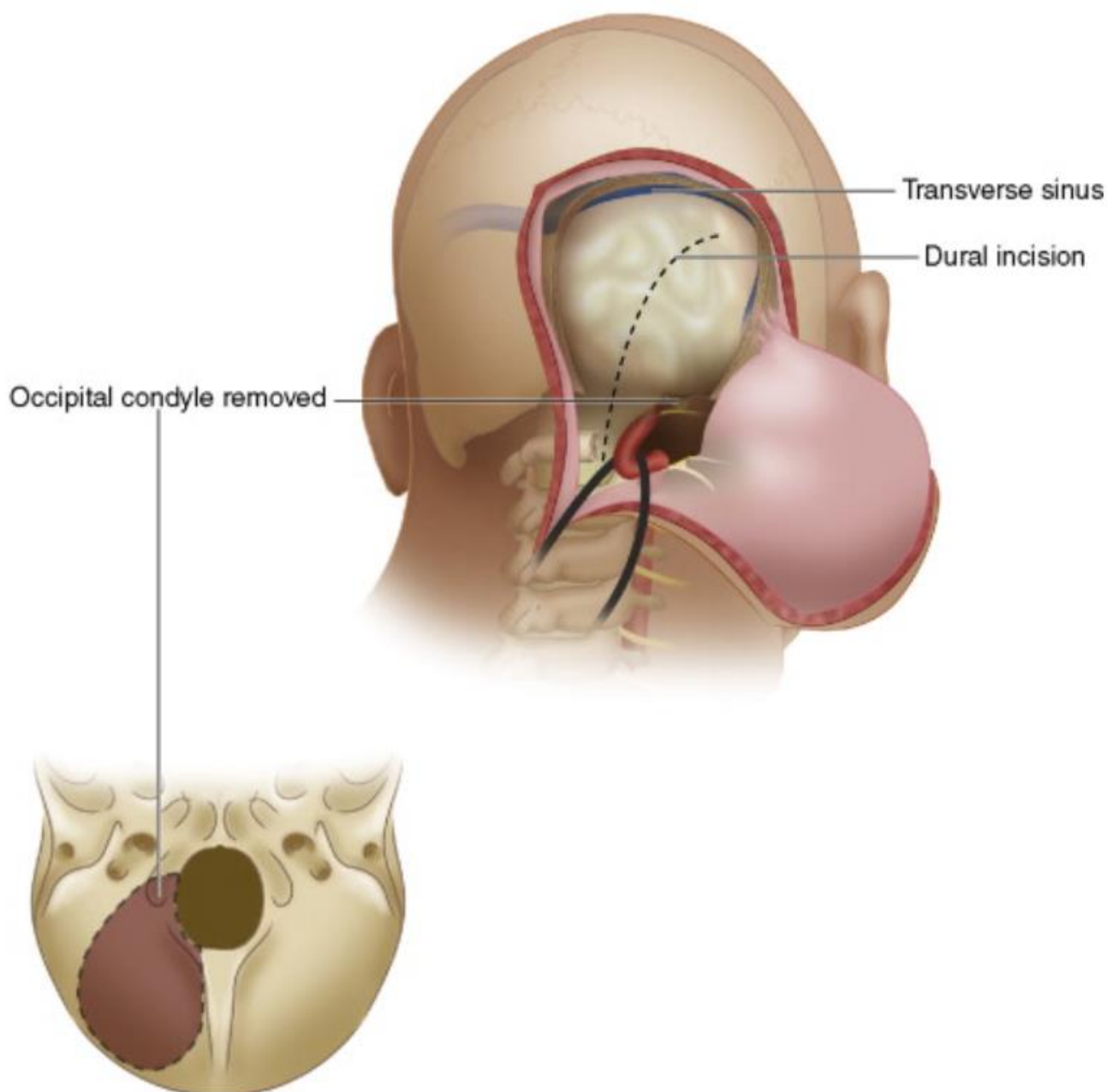
- Identification and mobilization of the vertebral artery. After reflecting the scalp flap with the inferior and superior oblique muscles laterally and posteriorly, the interlaminar and perivascular venous plexus is slowly controlled with bipolar cautery and direct pressure and divided with microscissors. Through this process, the course of the vertebral artery is delineated and prepared for mobilization. The posterior bony portion of the foramen transversarium is removed with a diamond bit drill to free the vertebral artery posteriorly. Multiple periosteal attachments that tether the vertebral artery into the foramen superiorly and inferiorly may be present; these should be sharply divided. The vertebral artery is mobilized away from the occipital condyle with a vessel loop and protected.
- extradural origin of PICA – such PICA always enters dura next to VA.



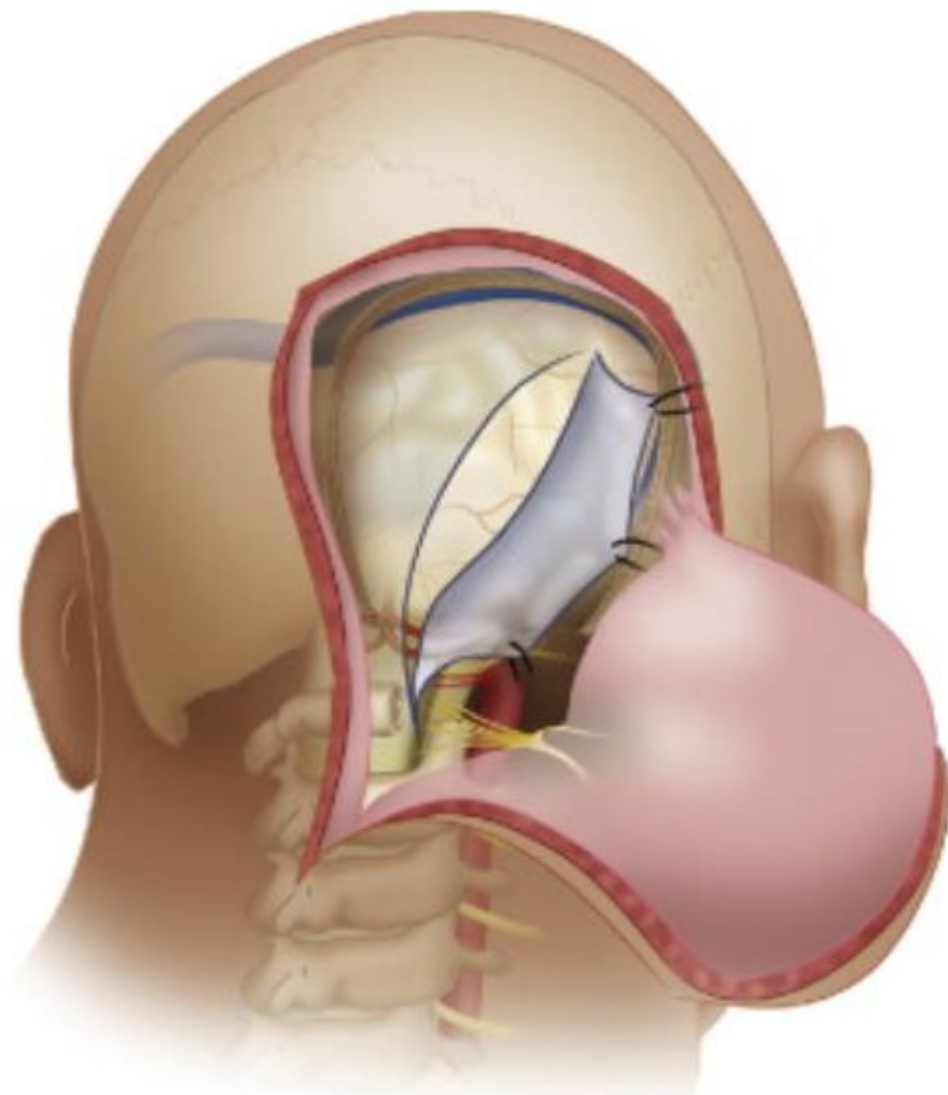
- bone flap involves three bone cuts that viewed from above remove a J-shaped plate of hemioccipital bone. The medial vertical limb of the bone flap extends upward from the foramen

magnum to just shy of the transverse sinus, which is just lateral to midline. The lateral vertical limb begins just inferomedial to the asterion and extends inferiorly and medially in a curvilinear fashion to reach the foramen magnum as lateral as possible. The horizontal limb connects the upper portions of each vertical limb at right angles and roughly parallels the transverse sinus.

- Although it is possible to use the foramen magnum as the sole entry point for the side-cutting bur, we prefer to add two burr holes. One burr hole is placed inferolateral to the inion and torcular Herophili and one is placed inferomedial to the asterion to help dissect a clear epidural plane to turn the bone flap in, preventing injury to the venous sinuses.
- thick dural attachments at the foramen magnum are bluntly separated from the bony rim of the foramen magnum because dural tears in this region risk injuring the circular sinus.
- C1 hemilaminectomy is necessary to lengthen the dural incision to achieve the desired exposure in this approach. The hemilaminectomy is performed either piecemeal or using a side-cutting bur with a footplate.
- hemilaminectomy of C2 and C3 can further improve visualization.
- It is wise to have a set of permanent and temporary aneurysm clips on the field throughout the case if needed to address vertebral injury.



- Retrosigmoid mastoidectomy. In contrast to the transpetrosal approaches, the goal of mastoidectomy in the far-lateral approach is to expose the transverse and sigmoid sinuses from the torcular Herophili to the beginning of the jugular bulb, defining the superior and lateral extent of the dural incision. This is performed with a sequence of dural dissection away from the bone, bony thinning with the drill, and removal with a Kerrison punch.
- Drilling of occipital condyle – core out cancellous bone, then remove cortical shell (less venous bleeding). Removal of the occipital condyle and associated lip of foramen magnum allows the additional anterior visualization that this approach provides. Although the posterior half of the condyle can be removed with relatively minimal adverse effects, additional condylar removal provides increased visualization at the cost of decreased stability of the atlantooccipital joint. **Roughly 50% (8 mm) of condyle can be safely removed posteriorly** before *occipitocervical fusion* should be considered. Following this rule, hypoglossal canal is rarely seen. Before drilling, the rerouted vertebral artery should be protected well away from the site of drilling
- don't drill too much of condyle → instability.
- After the sigmoid sinus is exposed, it is essential that the remaining mastoid air cells are aggressively obliterated with bone wax to prevent cerebrospinal fluid egress through the middle ear.
- Ideally, as much of the bone removal as possible should be performed as part of a bone flap because replacement of bony surface is cosmetically superior and possibly prevents muscular adhesion to the dura and suboccipital pain



- dura is opened in a lazy J-shaped fashion from the transverse sigmoid junction curving medial and inferiorly so that it crosses the foramen magnum just posteriorly to the intradural entry point of the vertebral artery. The cervical dura should be opened in a linear and paramedian fashion down to at

least the upper edge of the C2 lamina. If a large circular sinus is encountered while crossing the foramen magnum, this should be controlled with Weck clips, divided, and oversewn with dural sutures. At least some dural cuff should be left around the vertebral artery so that the dura can be repaired safely in this region. The dura should be reflected anteriorly with sutures placed as deeply as possible to keep the dura flat against the bony surface of the drilled condyle

Supracondylar extension – through jugular tubercle (seen on medial wall of condylar part of occipital bone); remember – CN11 is draped over jugular tubercle).

TRANSCONDYLAR APPROACH

Rhoton video: <http://rhoton.ineurodb.org/?page=23441>