

# *Peripheral Nerves*

Last updated: December 19, 2020

<b>PERIPHERAL NERVE STIMULATORS .....</b>	<b>2</b>
INDICATIONS .....	2
METHODS.....	2
REQUIREMENTS.....	3
TRIAL.....	3
COMPANIES.....	3
St. Jude .....	3
Biostim .....	3
PR Therapeutics .....	3
<b>SURGERY FOR PERIPHERAL NERVE TRAUMA .....</b>	<b>3</b>
TIMING OF SURGICAL INTERVENTION .....	4
STRATEGY.....	5
NEURORRHAPHY .....	7
Various modifications .....	10
Cable Grafts.....	11
Conduits (Tubes).....	14
UNRESTORABLE / UNSUCCESSFUL NERVE REPAIR .....	14
POSTOPERATIVE.....	15
<b>CARPAL TUNNEL RELEASE .....</b>	<b>15</b>
Bilateral CTS.....	15
ANATOMY.....	15
Arterial arcs in palm .....	17
TECHNIQUE.....	19
position .....	20
anesthesia.....	20
skin incision.....	20
retinaculum cut .....	21
closure .....	23
RESULTS .....	24
COMPLICATIONS .....	24
POSTOPERATIVE.....	24
<b>CARPAL TUNNEL RELEASE (ENDOSCOPIC TECHNIQUE) .....</b>	<b>25</b>
<b>ULNAR NERVE NEUROLYSIS AT ELBOW .....</b>	<b>26</b>
ANATOMY.....	26
PROCEDURE .....	26
Position.....	26
Neurolysis (In situ decompression).....	26
Postop .....	27
Failures .....	28
In situ decompression vs. Nerve translocation .....	28
Endoscopic decompression .....	29
In situ decompression with Medial epicondylectomy .....	29
Subcutaneous transposition .....	30
Intramuscular transposition .....	30
Submuscular transposition .....	31
<b>ULNAR NERVE NEUROLYSIS AT WRIST .....</b>	<b>31</b>
<b>PERONEAL NERVE NEUROLYSIS AT FIBULAR HEAD .....</b>	<b>31</b>
<b>NERVE BIOPSY .....</b>	<b>34</b>
NERVE SELECTION .....	34
TISSUE TECHNIQUES, PATHOLOGIC FINDINGS.....	34

**SURAL NERVE BIOPSY ..... 34**  
 ANATOMY ..... 34  
 INDICATION..... 34  
 CONTRAINDICATION ..... 35  
 ANESTHESIA ..... 35  
 POSITION..... 35  
 INCISION ..... 35  
 DETAILS..... 35  
 CLOSURE..... 36  
 POSTOPERATIVE..... 36  
 COMPLICATIONS ..... 36  
**SUPERFICIAL RADIAL NERVE BIOPSY ..... 36**  
**ALLOGRAFT NERVE REPAIR ..... 38**

## **PERIPHERAL NERVE STIMULATORS**

### **INDICATIONS**

Examples of peripheral stimulation indications with evidence of efficacy that may be covered are:

- PNS of occipital nerves for occipital neuralgia, post-surgical neuropathic pain, cervicogenic headaches and treatment resistant migraines.
- PNS of trigeminal nerves (and branches) for post-traumatic and post-surgical neuropathic pain in the face related to the trigeminal nerves.
- PNS / PNFS of nerves in upper and lower extremities of complex regional pain syndromes (type 1 and 2), pain due to peripheral nerve injury, post-surgical scar formation, nerve entrapment, painful mononeuropathy, and painful amputation neuromas.
- PNS / PNFS of intercostal and ilio-inguinal nerves for post-surgical and post-traumatic neuropathic pain involving these nerve distributions.
- PNFS of trunk / lower back for cases of severe post-surgical neuropathic pain (continuous, burning, and unresponsive to less invasive procedures).

Current peer-reviewed data DOES NOT SUPPORT PSN / PNFS for fibromyalgia, phantom limb pain, diffuse polyneuropathy, nociceptive pain in trunk or lower back, or angina pectoris. Claims for these indications will be denied as not reasonable and necessary.

### **METHODS**

PNS has been tried for over 50 years and has been used in a wide variety of chronic pain syndromes, but the scientific literature is limited for many of the indications tried. The most accepted uses of PNS or PNFS involves one of three methods:

- Open exposure of a peripheral nerve and direct implantation of a PNS electrode (as in treatment of a radial nerve, sciatic nerve, median nerve, etc.).
- Percutaneous insertion of a PNS electrode in direct vicinity of the stimulated nerve (e.g., occipital nerve for severe headaches).
- Implantation of subcutaneous PNFS electrodes in the area of pain the peripheral nerve fields for severe axial or chest wall pain.

As with a Spinal Cord Stimulator (SCS), PNS and PNFS performance of an effective trial is a pre-requisite of final implantation. Many experts recommend that the temporary neurostimulator be placed in an ASC or outpatient hospital setting. However, the temporary neurostimulator trial can be done in an office setting if all the sterility, equipment, professional training and support personnel for the proper surgery and follow up of the patient are available. Permanent neurostimulators must be placed in an ASC or hospital. Physicians performing PNS or PNFS trials in place of service office must have like privileges at an ASC or hospital, or the physician must be board certified or board eligible in Pain Medicine, Orthopedic Surgery, or Neurosurgery by an ABMS Board or the equivalent as determined by the state of practice. Other ABMS Specialty Boards or the equivalent in the state of practice may be included if such practice is included in the training program curriculum.

It is preferable that the physicians performing the PNS or PNFS trials will also perform the permanent implant. If the physician implanting the trial PNS / PNFS does not or cannot implant the permanent neurostimulator(s), the patient should be informed of this in writing and given the name of the referral surgeon who will implant the permanent neurostimulator(s).

## REQUIREMENTS

Coverage of PNF / PNFS trials requires that patients have all of the following:

- Documented chronic and severe pain for at least 3 months,
- Documented failure of less invasive treatment modalities and medications,
- Lack of surgical contraindications including infections and medical risks,
- Appropriate proper patient education, discussion and disclosure of risks and benefits,
- No active substance abuse issues,
- Formal psychological screening by a mental health professional, and
- Successful stimulation trial with greater than or equal to 50% reduction in pain intensity before permanent implantation.

## TRIAL

The only reliable predictor of PNS / PNFS effectiveness is a trial of stimulation with implanted PNS / PNFS electrodes. If a trial fails, a repeat trial is usually not appropriate unless there are extenuating circumstances that led to the trial failure (equipment malfunction, early lead migration, etc.), technological advances, or an alternative neuromodulatory technique that may lead to a more successful second trial. Documentation must explain these unusual situations. It is expected that accurate patient selection will lead to most patients going on to receive permanent implants. All trials which proceed to permanent implant must have adequate documentation in the chart to support that decision. A successful trial should be associated with at least a 50% reduction of target pain, or 50% reduction of analgesic medications, and show some element of functional improvement.

Physicians with a low trial to permanent implant ratio less than 50% will be subject to post payment review and may be asked to submit documentation as to the patient selection criteria, the imaging demonstrating proper lead placement, and the medical necessity of the trials. Failure to provide this documentation will be cause for post-payment denial and recoupment of reimbursement. It is understood that all patients may not have a favorable result of the trial implant; but careful selection should find the most appropriate patients.

## COMPANIES

**ST. JUDE**

**BIOSTIM**

**PR THERAPEUTICS**

**SPRINT endura** (single lead) and **SPRINT extensa** (dual lead) peripheral nerve stimulation systems - percutaneous peripheral nerve stimulation (PNS) system cleared by the FDA and indicated for up to 60 days in the back and/or extremities for both chronic and acute pain.

## SURGERY FOR PERIPHERAL NERVE TRAUMA

See also p. PN7 >>

## TIMING OF SURGICAL INTERVENTION

Allow sufficient time for spontaneous recovery without jeopardizing results of late repair

e.g. for injuries consistent with nerve rupture (e.g. glenohumeral dislocation), 3-6 month period without clinical or electrophysiological recovery warrants surgery; this time frame is sufficient for neurapraxic and axonotmetic injuries to resolve but is not long enough to jeopardize results of subsequent axillary nerve surgical repair.

Earlier repair → better results

N.B. in vast majority of gunshot wounds, nerve is not divided (only contused) – very important for management strategy!

Timing of Nerve Exploration (Repair) - <b>RULE OF 3'S</b>	
<b>Sharp clean lacerations</b>	- (within) <b>3</b> days
<b>Blunt lacerations</b>	- <b>3</b> weeks
<b>Injuries in continuity</b>	- <b>3</b> months

**Lacerations:** Surgery is indicated for **NEUROTOMESIS!**

- sharp lacerations** → **primary repair** within **first 48-72 h** (esp. **clean** lacerations made by sharp objects, obvious motor and sensory deficits); usually **end-to-end**.
- blunt / contaminated lacerations** → **delayed repair** after **2-3 weeks**; repair often needs **graft** due to stumps shrinkage.
  - if injury is **several days** old, wait ≈ 2 weeks for edema to subside.
    - e.g. if swollen and discolored peroneal nerve is encountered during acute knee repair, it should not be resected; rather, waiting several months is better.
  - autologous interposition graft (cable grafting) may be needed if repair is delayed.
  - arguments against primary nerve repair:
    - damage to nerve may be more extensive than is apparent initially.
    - epineurium and perineurium are delicate at this stage and difficult to suture.
    - infection may occur from initial wound contamination.
    - emergency conditions may be suboptimal for careful and tedious operation.
    - lag time for wallerian degeneration (vs. in **delayed repair** - involved neurons are capable of immediately regenerating new distal segments - regenerating axons can penetrate repair site before significant amount of scar forms).
  - if delayed repair is chosen, initial wound should be at least **explored** - débride, tag divided nerve ends (easier found at later re-exploration) or to loosely approximate nerve ends with inert sutures (to prevent retraction) and suture to surrounding fascial tissue

**Blunt trauma** – observe for **at least 6 weeks (up to 6 months)** for recovery from possible

**NEURAPRAXIC-AXONOTMETIC** injury (Sunderland's 1-2°).

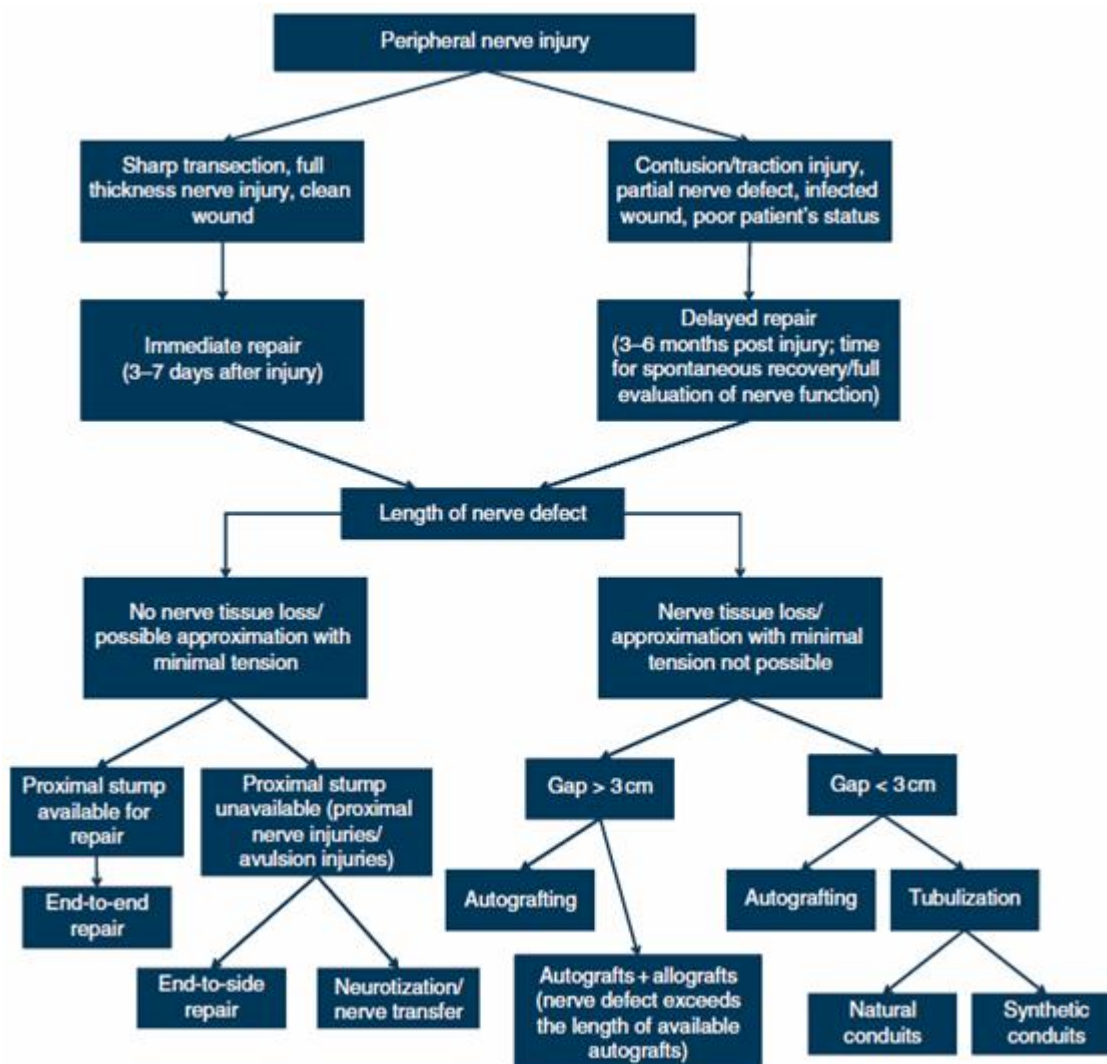
- if no clinical recovery evident, repeat EMG – if some potential recruitment is seen → observe another month (clinical recovery may follow).
- if nerve function is progressively deteriorating (as per electrodiagnostic findings), surgery may be indicated because status of connective tissue cannot be assessed without direct exploration.
- for nerve injury within 2-3 inches of recoverable muscle, 2 months is required for growing axons to begin process of muscle reinnervation.
- brachial plexus** stretches / contusions are observed for 4 months.

- time frame for *radial nerve* exploration ranges from 8 weeks ÷ 5 months. Surgical delays in **excess of 5 months** dramatically decrease rate of functional return!!! For *brachial plexus* injuries, operate < 6 months from injury!

Surgery must be planned according to facts that:

- peripheral nerve regenerates **≥ 2,5 cm per month**;
- if it takes > 12 months for axons to reach target end-organ:
  - a) **motor aspect:** significant degree of muscular atrophy has occurred (motor end plates are reinnervated with difficulty > 1 year after denervation; in general, muscles can be reinnervated up to 2 years);
    - e.g. not worthwhile to suture ulnar nerve near axilla or peroneal nerve above mid thigh.
    - e.g. with blunt injury to sciatic nerve, surgical intervention should occur as soon as possible if no clinical recovery within 3-8 weeks; on other hand, one can observe patient with distal median nerve injury for 3-4 months and still obtain good surgical result.
  - b) **sensory aspect:** restitution may still be possible – crude sense of touch returns ± temperature (other senses do not return)
    - e.g. worthwhile to suture median nerve near axilla or tibial nerve above mid thigh to effect return of at least protective sensation.
- adults > 40 years rarely achieve functional result from ulnar nerve repairs proximal to elbow.

## STRATEGY

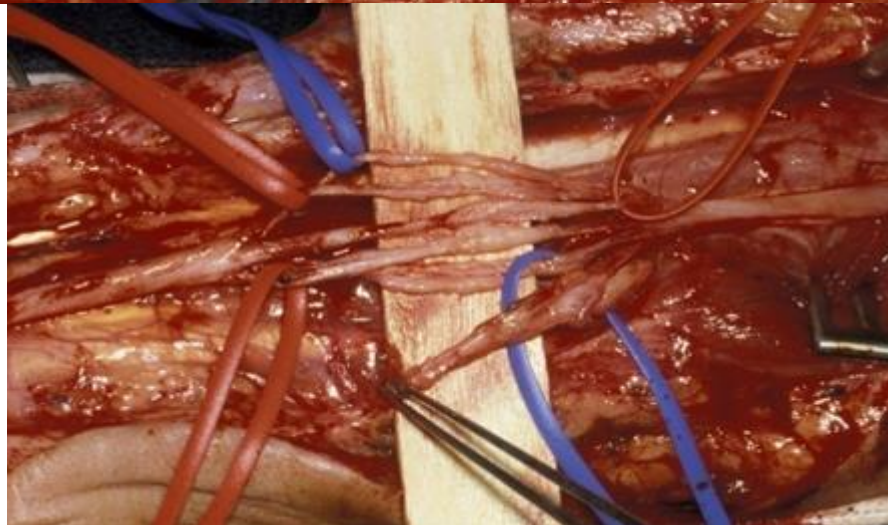
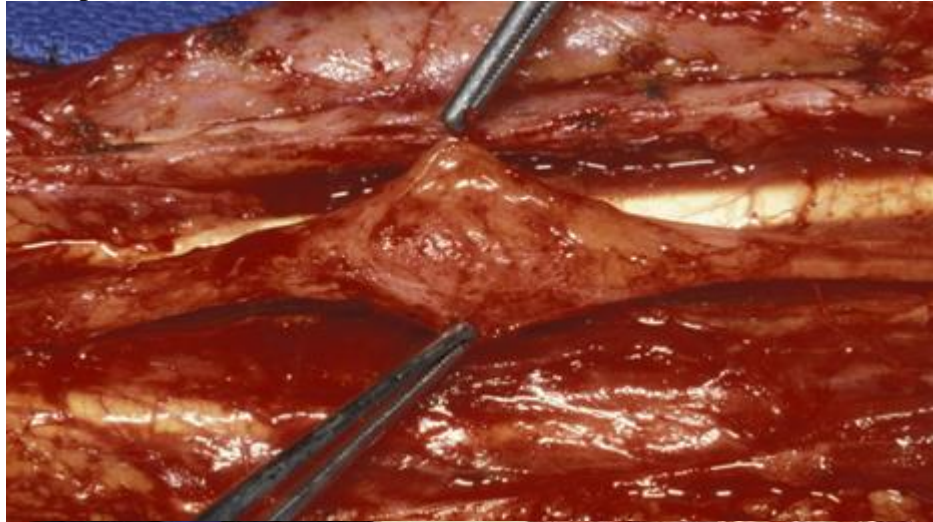




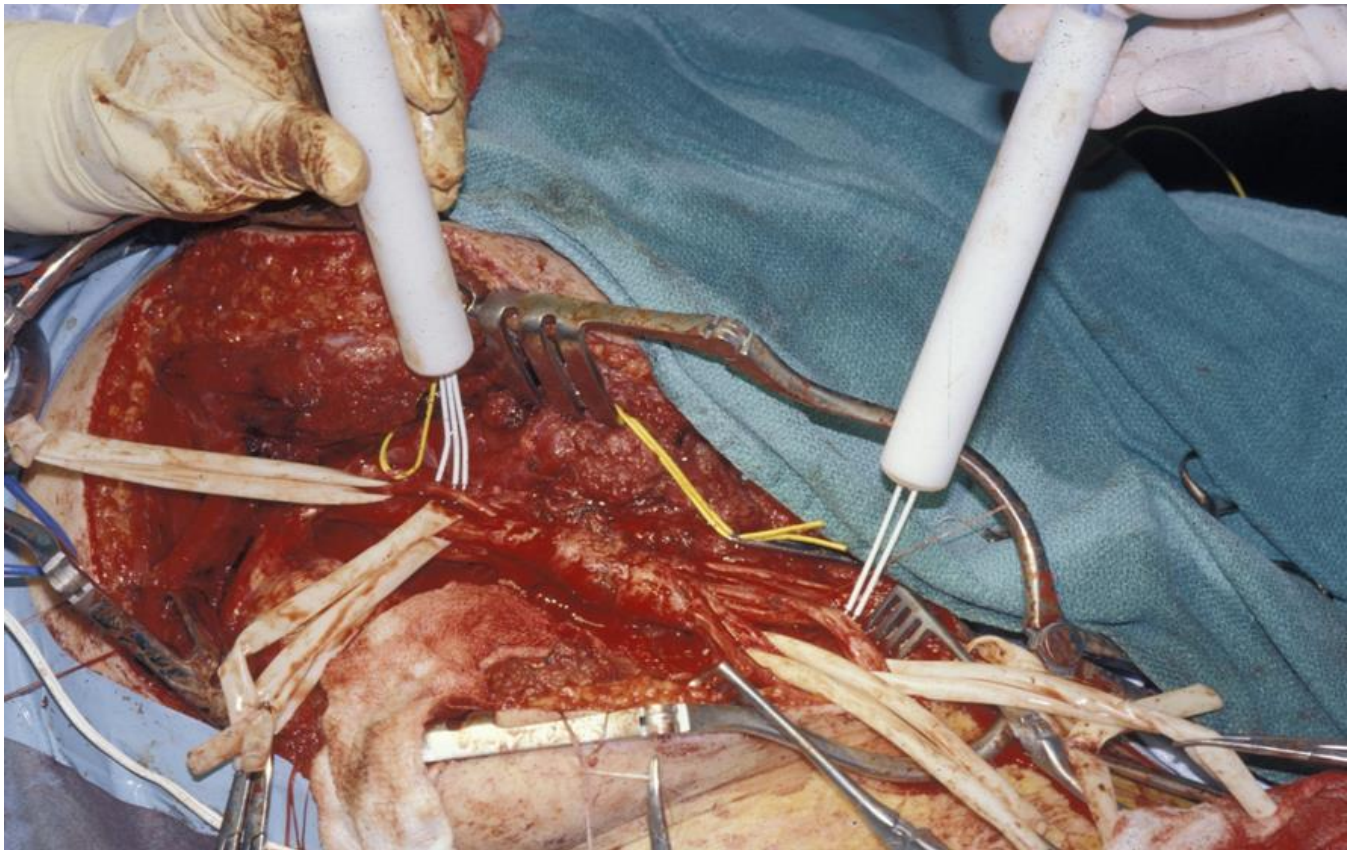
**Excise** damaged segment or release regenerating nerve fibers (**neurolysis**) ± place **cable graft** (between proximal and distal nerve ends) → anastomose cleanly cut ends (**neurorrhaphy**).

Clinically nonfunctioning nerve in continuity ( $\leq 4^\circ$  lesion, s. *neuroma in continuity*):

- A. Bad scar → **excise** → cable **graft**
- B. Modest scar → electrically stimulate nerve proximal to injury and look distally for evidence of muscle contraction or transmission of nerve action potentials (**intraoperative action potentials**):
  - a) **no transmission across area of injury** → **excise** injured portion → cable **graft**
  - b) **transmission across area of injury** → **external neurolysis**; sometimes **internal neurolysis** is performed to test more selectively for nonfunctional fascicles that need excision repair:



Intraoperative stimulation and action potential recording:

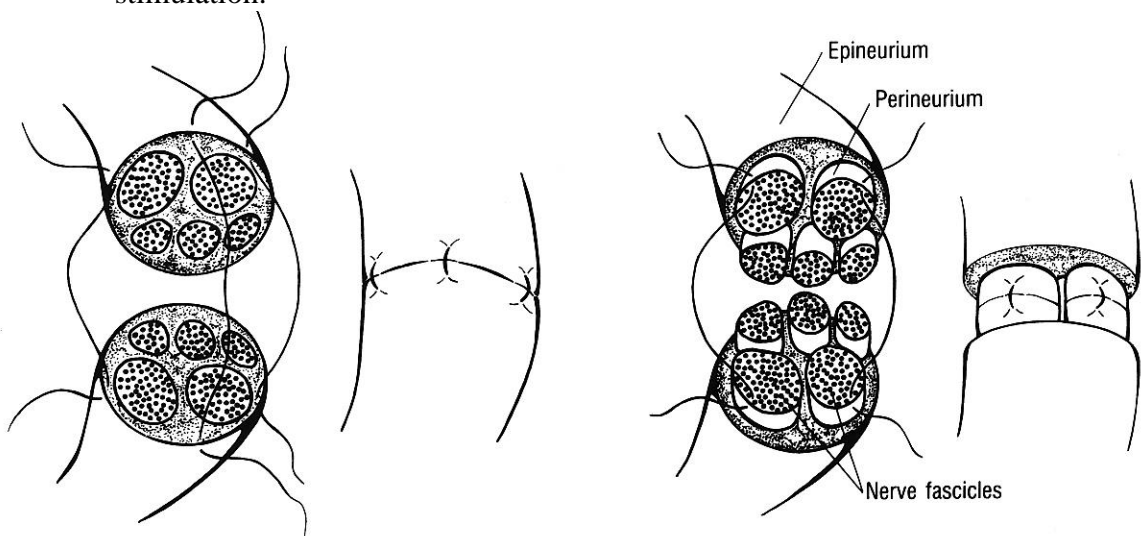


- do not use local anesthetic if planning to use nerve stimulation intraop.

## NEURORRHAPHY

**EPINEURAL vs. FASCICULAR repair** - neither technique is superior!

- **EPINEURAL** repair appears appropriate for most cases!!!
- **FASCICULAR** repair is **technically** more challenging and more **traumatic** to nerve (extra sutures add to scar tissue production); conditions for fascicular repair:
  - 1) done in **first 48-72 h**.
  - 2) nerve is **cut distally** (clear distinction can be made between sensory and motor divisions of nerve); use local anesthesia - motor and sensory fascicles can be identified by direct stimulation.



**Figure 21-11** Epineurial and intrafascicular repair.

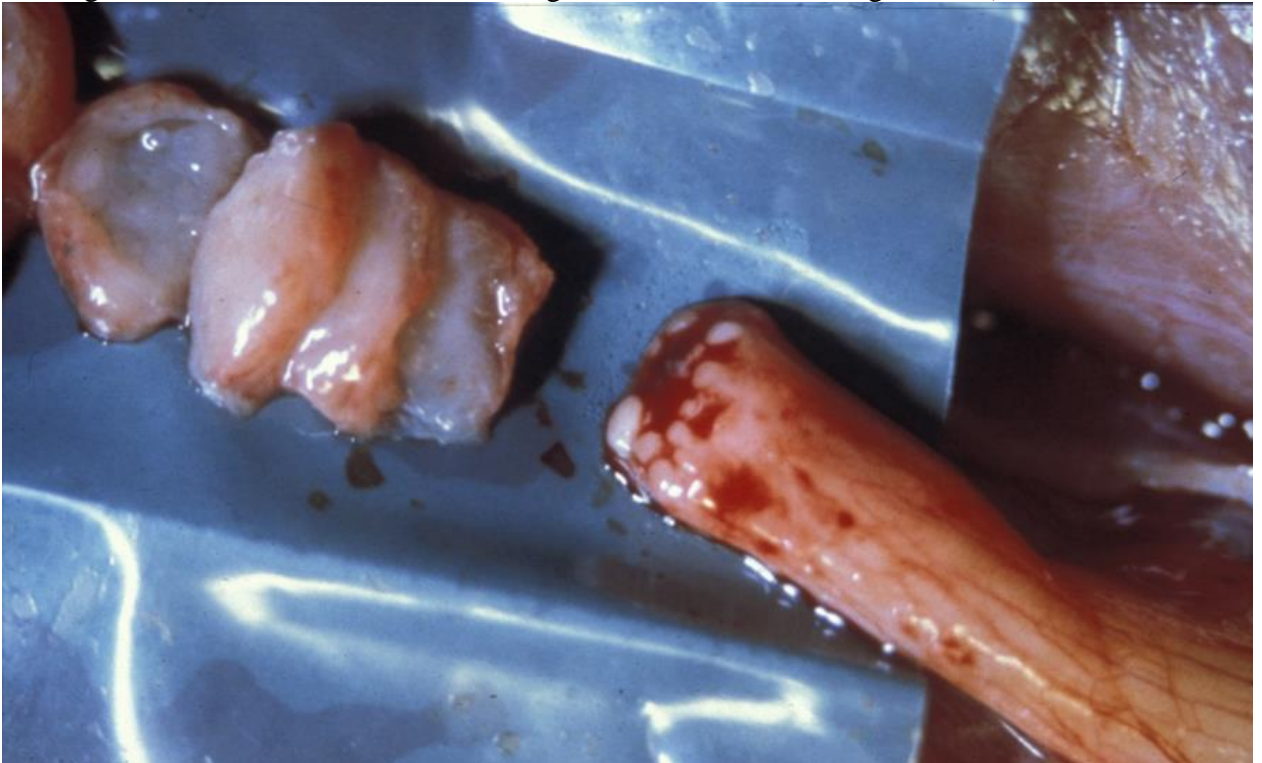


How to improve proper fascicular alignment: epineurial vessel alignment, serial cross-section topography, gross fascicular matching, histochemical stains (not done in OR)

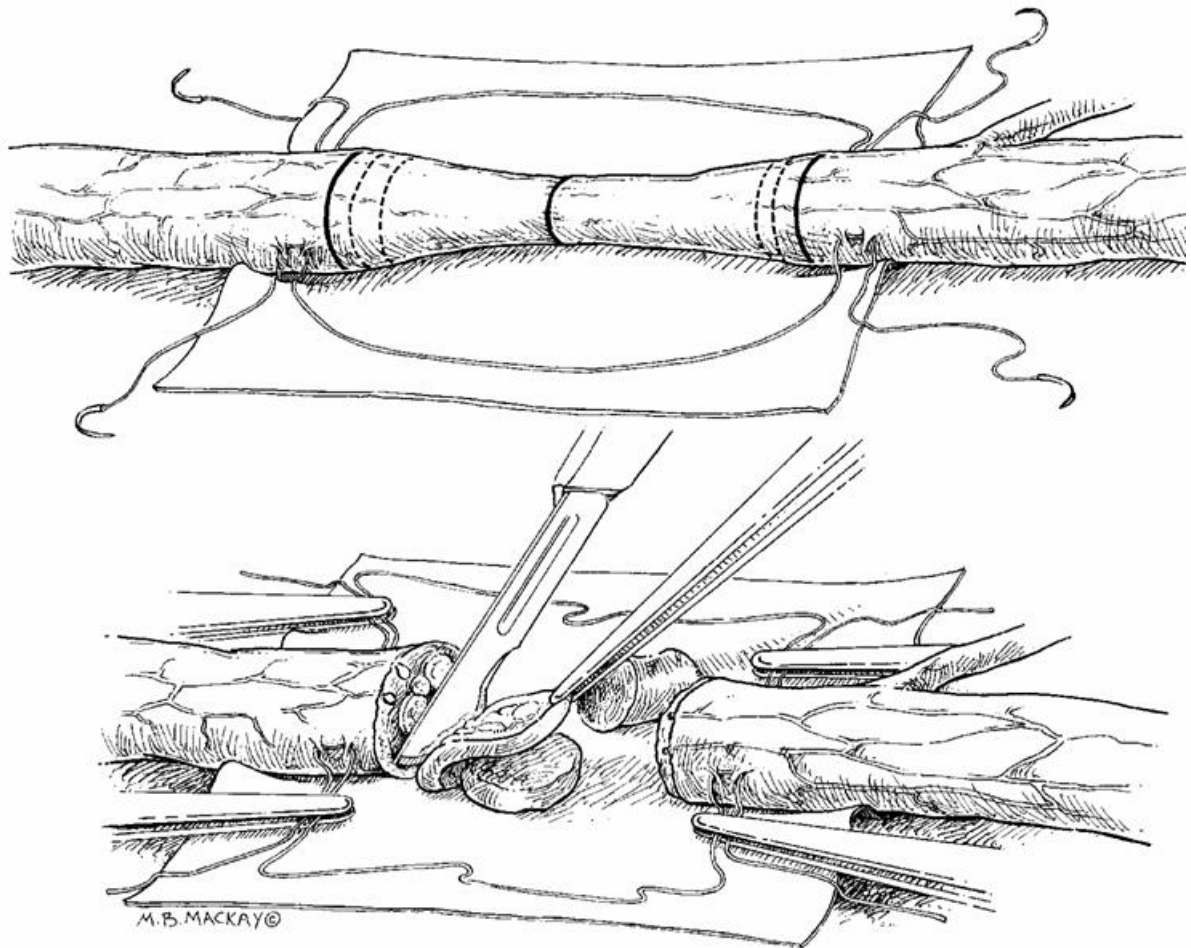


### Technique

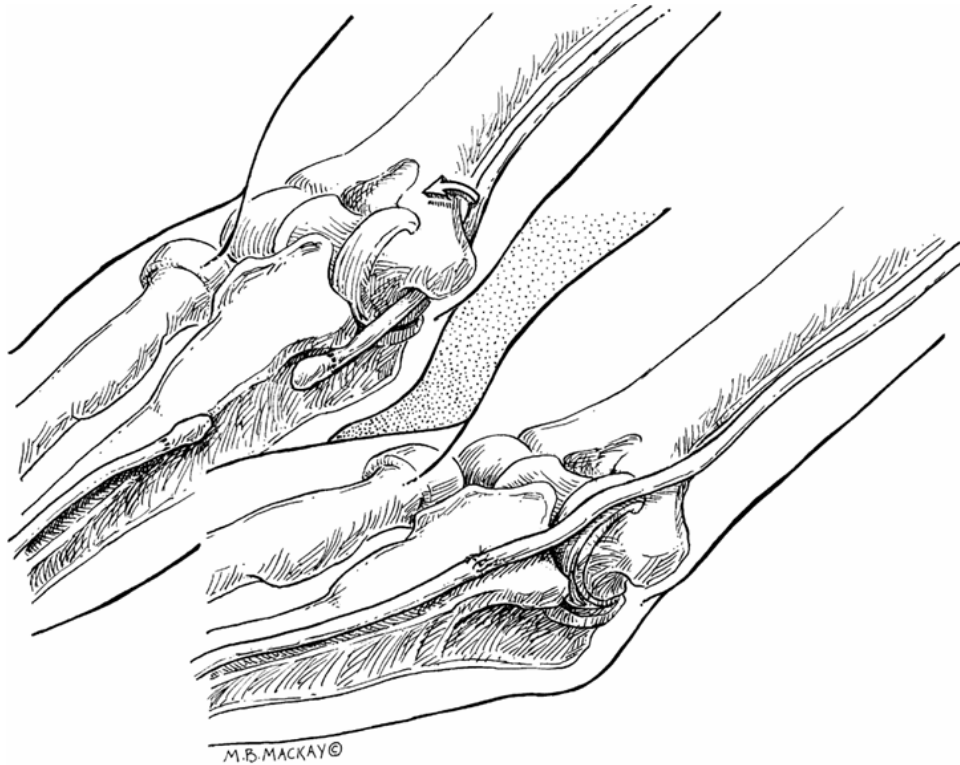
- clean adventitial connective tissue.
- place nerve ends on blue background.
- *ends are trimmed* to healthy nondamaged axons (use blade breaker or razor blade chip against cutting surface that will stabilize nerve, e.g. moistened wooden tongue blade):



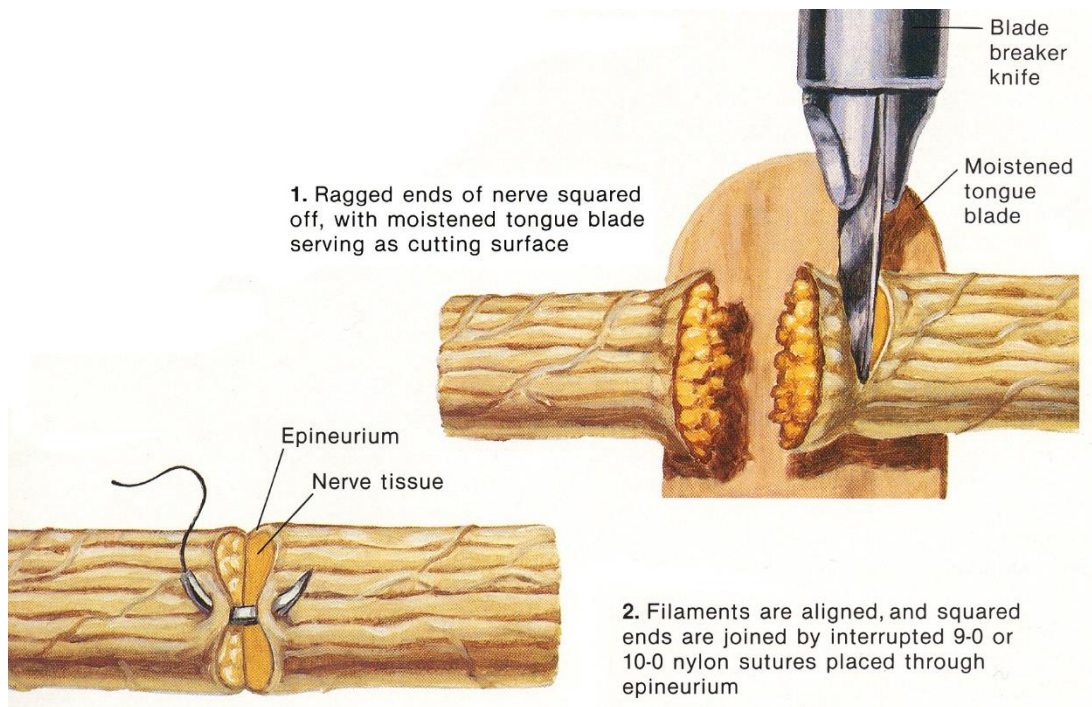




- keep nerve ends moist.
- precise suturing - use *magnification* (up to operating microscope).
- suture:
  - **size** (suture gauge & needle fineness must be consistent with nerve size):
    - 8-0 for epineurium
    - 10-0 for perineurium
  - **material** NYLON, POLYESTER, POLYPROPYLENE.
  - suture **strength** is less of consideration than degree of **inflammatory & fibroplastic reaction**.
  - Use minimum number of microsutures!!! (consider use of **fibrin glue** - itself or to reinforce)
- **END-TO-END connection** through epineurium alone is adequate in most cases (approximate s. coaptate nerve ends).
- follow **fascicle topography** - motor and sensory fibers are properly realigned.
- *deep side of anastomosis* is performed first (after two sutures are placed at each side of line bisecting horizontal axis for orientation; this also aids in nerve rotation), *superficial repair* is accomplished last.
- suture has to **closely approximate epineurium** (to prevent regenerating axons from escaping, to prevent separation), but avoid constriction.
- recovery is better if anastomosis is **tension-free + without damage to blood supply**; within 3 weeks after injury, nerve may lose 8% of its length; measures to reduce tension:
  - a) nerve mobilization
  - b) interposition graft
  - c) bone shortening
  - d) rerouting nerve across flexed joint:



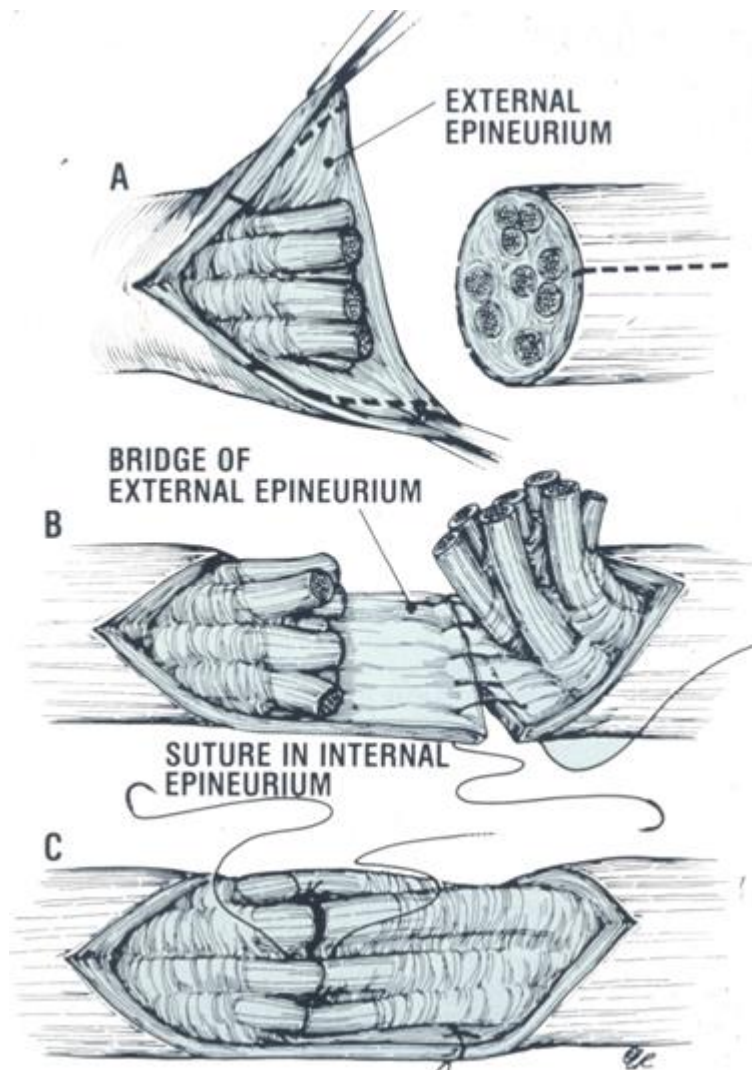
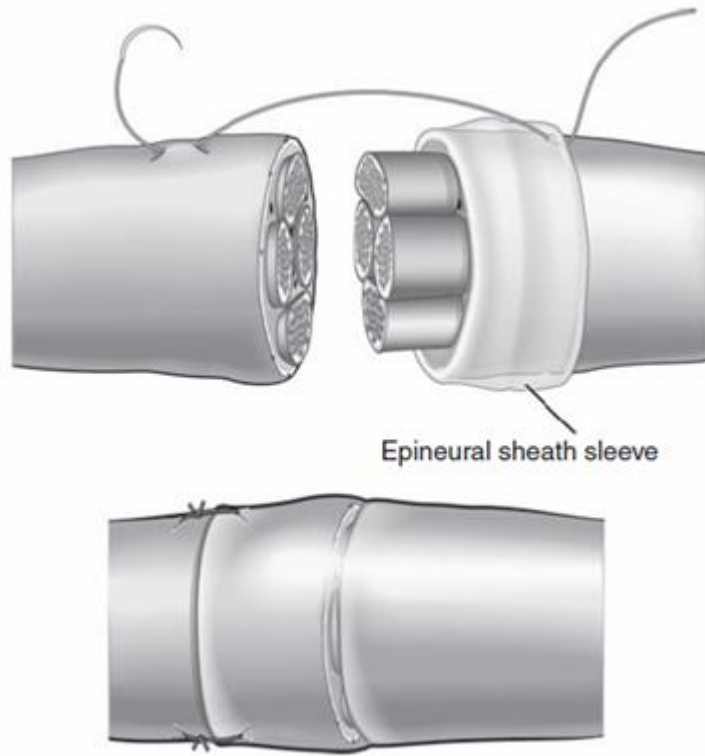
- *small drain* may be placed in repair.



**VARIOUS MODIFICATIONS**

**Epineural sleeve repair**

- compression and tension is transferred from repair site
- biological chamber for axoplasmic fluid leakage



**CABLE GRAFTS**



Graft undergoes Wallerian degeneration and provides mechanical guidance for ingrowing axons!

**Disadvantages: two connections, temporary graft ischemia.**

- at each anastomosis  $\approx 10\%$  axons will not cross (primary neurorrhaphy is better than cable grafting).

**Advantages: no tension.**

**Indications:**

- extremely scarred bed (poor vascularity) – use vascularized nerve grafts.
- destroyed length of nerve with total **gap > 2-3 cm** (tension under primary anastomosis).

**Sources for grafts:**

- Autografts** – golden standard!
  - sural* nerve
  - antebrachial cutaneous* nerve
  - lateral femoral cutaneous* nerve
  - any **amputated extremity**.

EXAMPLES OF DONOR NERVES AVAILABLE FOR AUTOGRAFTING

Donor nerve		Available length (cm)	Hypesthesia
Medial antebrachial cutaneous nerve	MACN	10–12 (above elbow) 8–10 (below elbow)	Medial forearm
Lateral antebrachial cutaneous nerve	LACN	10–12	Lateral forearm
Superficial sensory branch of the radial nerve	SSR	20–30	Radial dorsal hand
Dorsal cutaneous branch of the ulnar nerve	DCBUN	4–6	Ulnar dorsal hand
Sural nerve		30–50	Lateral foot

- Allograft** (tissue from unrelated donor) - limited success; requires immunosuppression for  $\approx 1$  year (can be discontinued when graft has been incorporated with ingrowth of Schwann cells from host nerve ends).
  - advantages: unlimited supply, less time consuming in surgery, absence of morbidities in donor site (sensory paresthesia, neuroma, or scar formation), better nerve samples (in terms of quantity and caliber), requires no surgical adaptation of the diameter stump between donor and recipient nerves

N.B. **cryopreserved allografts** obviate need for any immunosuppressive treatment (cryopreservation and controlled freezing leave perineurial and endoneurial connective tissues intact, effectively preventing infiltration by host lymphocytes as has been observed in fresh allografts → decreased immune response and graft rejection); same results achieved with **acellular allografts**

**Harvesting of sural nerve for cable graft** (produces only well-tolerated sensory loss on lateral foot)

- lateral aspect of leg is exposed.
- **incision** - 1 cm lateral and parallel to Achilles tendon; begun 1 cm proximal to lateral malleolus and extended proximally.
- sural nerve is found just superficial to deep fascia and deep to lesser saphenous vein.
- nerve is freed by sharp dissection.
- proximal and distal ends are divided with **razor blade** over wooden spatula.
- *if patient is awake*, perform **conduction block** with Xylocaine proximally before transecting nerve (to prevent pain).

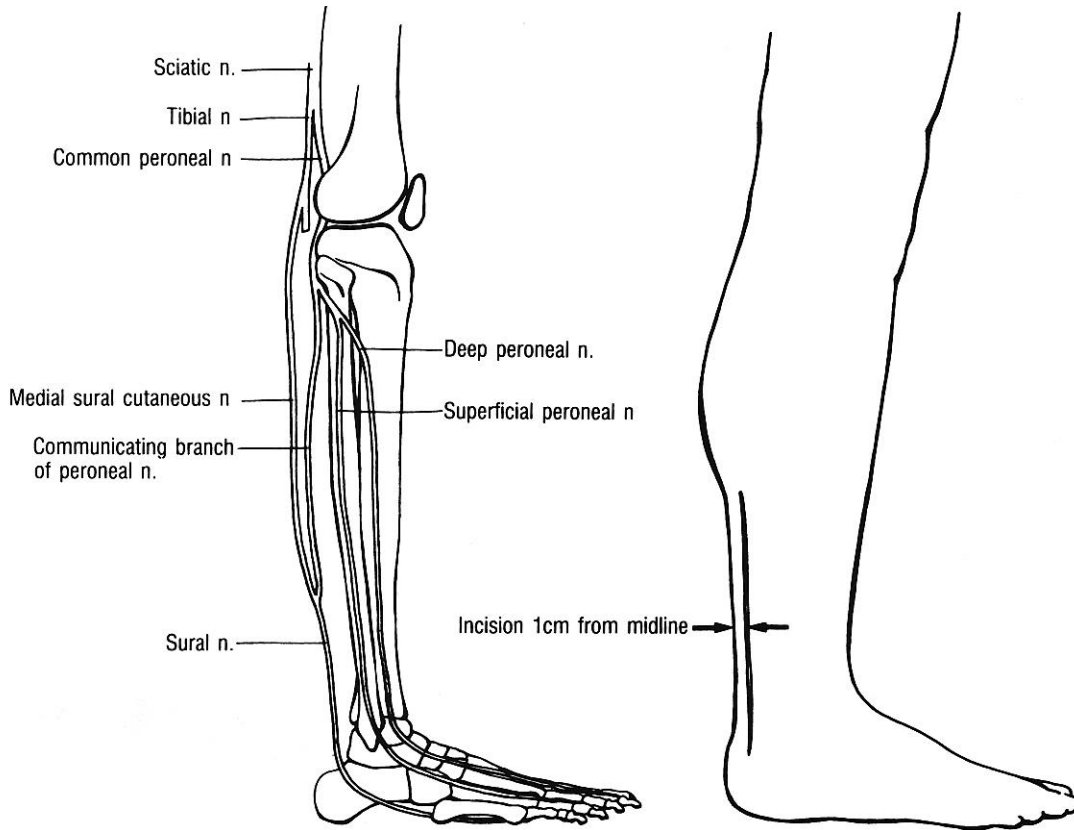
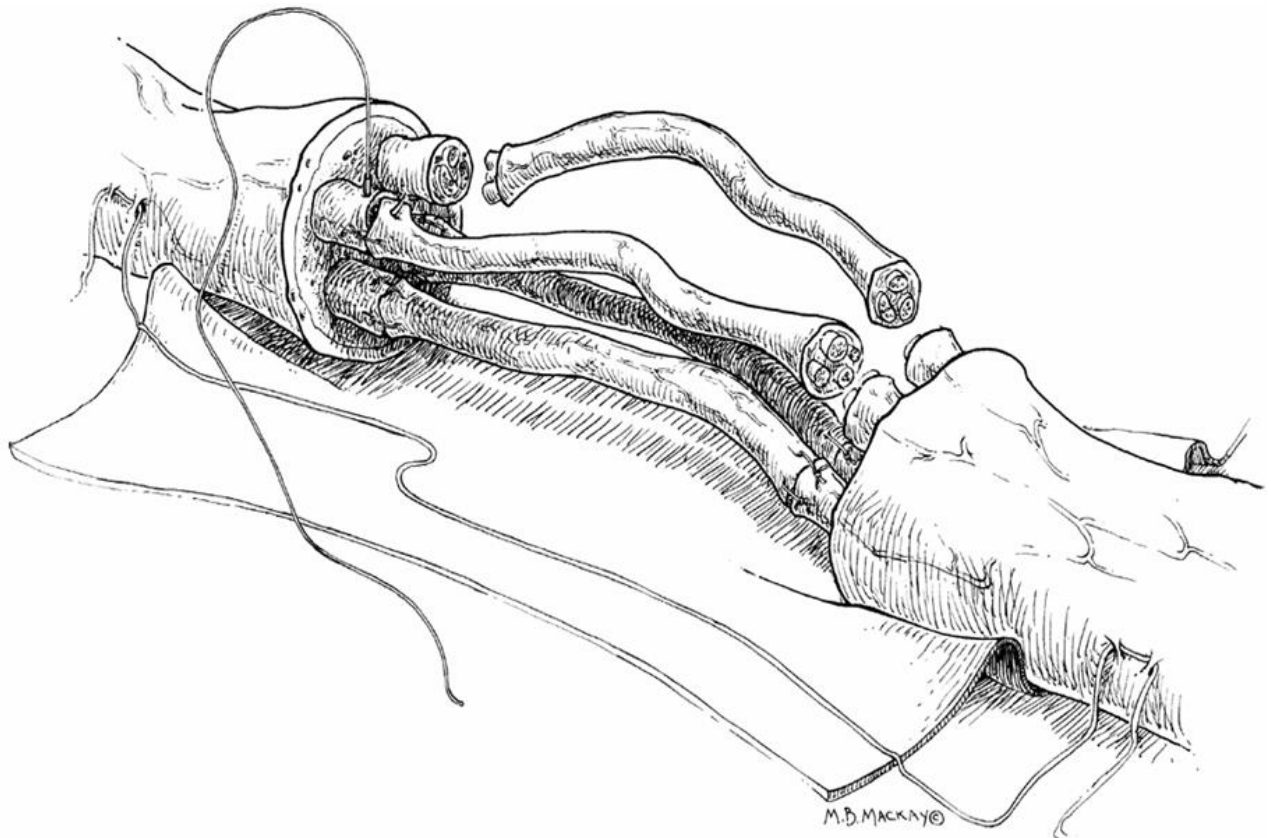
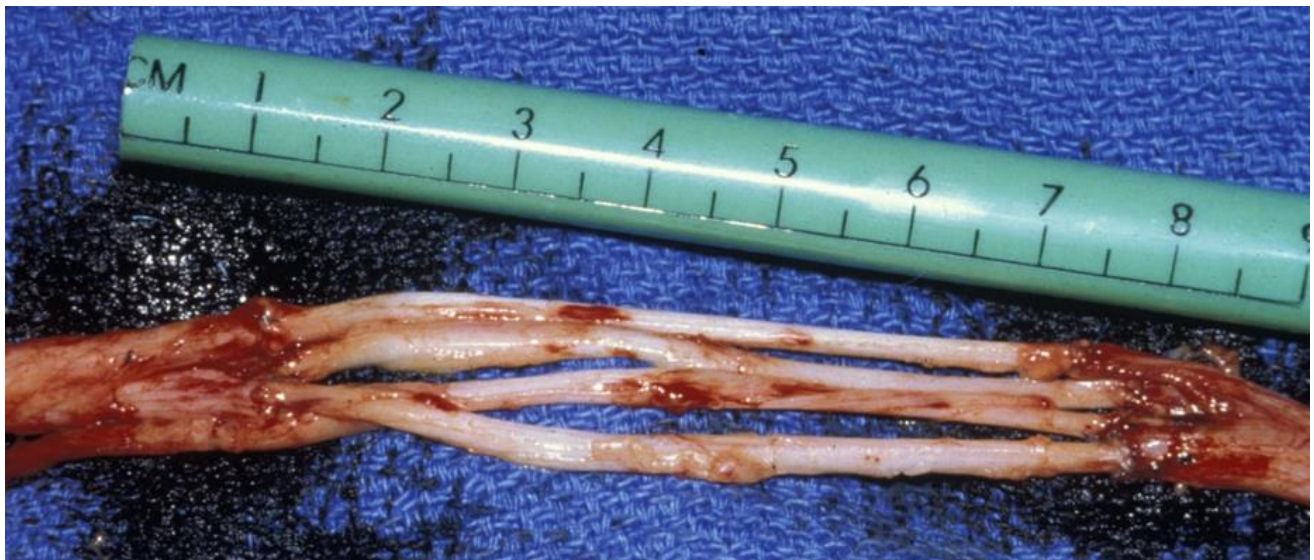


Figure 21-15 Harvesting sural nerve.





**CONDUITS (TUBES)**

1. **Biological conduits** (e.g. with brain-derived neurotrophic factor (BDNF) support):
  - 1) *predegenerated or fresh skeletal muscle*; e.g. *basal laminal grafts of muscle* (for sensory nerve repair) - pectoralis muscle fibers are harvested, frozen in liquid nitrogen, thawed, and used to repair injured digital nerve.
  - 2) *arteries, veins*
  - 3) *mesothelial chambers*
  - 4) *epineural sheath*
2. **Artificial conduits** (e.g. type I collagen, silicone, expanded polytetrafluoroethylene, porcine intestinal submucosa, etc) – for maximum 3 cm lengths.

FDA APPROVED RESORBABLE SYNTHETIC GUIDES

Product name	Neurotube	Neurolac	NeuraGen	NeuroMatrix NeuroFlex
Material	Polyglycolic acid	Poly-DL-lactide-ε-caprolactone	Type I Collagen	Type I Collagen
Company	Synovis	Polyganics BV	Integra NeuroSciences	Collagen Matrix Inc
Maximum length (cm)	4	3	3	2.5
Diameter (mm)	2.3-8	1.5-10	1.5-7	2-6
Degradation time	3 months	16 months	4 years	7 months
Clinical data	Yes	Yes	Yes	No

- slide tube over larger nerve → neurorrhaphy → slide tube over anastomosis → apply Tisseel and fold blue background over (to mold sausage of Tisseel over anastomosis)

**UNRESTORABLE / UNSUCCESSFUL NERVE REPAIR**

1. **Nerve transfers (neurotization)**  
e.g. spinal accessory or long thoracic nerve can be grafted onto distal arm nerve trunks → improvement in elbow flexion.
2. **Tendon transfers** - to increase extremity function.  
e.g. posterior tibialis tendon passing through interosseous membrane → added power to foot with peroneal deficiency.



## POSTOPERATIVE

- protect repairs by **relaxed joint posturing** for  $\approx$  3 weeks.
- begin **physiotherapy** 2-3 weeks after operation to *maintain range of movement and keep muscles ready for reinnervation* (stimulation prevents atrophy, which would compromise final result of nerve repair).
- *clinical & electrodiagnostic examinations* - q 3 months for first 2 years (in most cases, maximal recovery requires as long as 24 months).

## CARPAL TUNNEL RELEASE

Treat other causes for neurologic symptoms (e.g. cervical radiculopathy, C7 or middle trunk compression in thoracic outlet, proximal median nerve compression) first!

### BILATERAL CTS

- a) **simultaneous treatment** - reduction in total disability time and reduced surgical cost (incl. fewer follow-up visits); but compromised ability of patient to perform self-care
- b) **staged treatment** - treat more affected hand first, followed 2-6 weeks later by treatment of other hand.

## ANATOMY

full anatomy of median nerve → see p. A20 (12) >>

anatomy of carpal tunnel: p. 31 (Topke 1) >> p. 1009 >>

- carpal tunnel is fibro-osseous passageway in the anterior aspect of the wrist.
- carpal tunnel is formed by carpal bones and flexor retinaculum.
- carpal tunnel is 4-6 cm in length.
- carpal tunnel contains:
  - 1) four tendons of flexor digitorum superficialis (FDS)
  - 2) four tendons of flexor digitorum profundus (FDP)
  - 3) tendon of flexor pollicis longus
  - 4) median nerve - travels between transverse carpal ligament and second and third FDS tendons
  - 5)  $\pm$  persistent median artery, anomalous muscles and tendons
- carpal tunnel may be thought of as inverted table - carpal bones forming tabletop; hook of hamate, pisiform, tubercle of trapezium, and distal scaphoid forming table legs.

Floor of carpal tunnel - **VOLAR RADIOCARPAL LIGAMENT** and other bridging ligaments interconnecting pisiform and hook of hamate medially and tubercles of scaphoid and trapezium laterally.

Roof of carpal tunnel - **FLEXOR RETINACULUM**

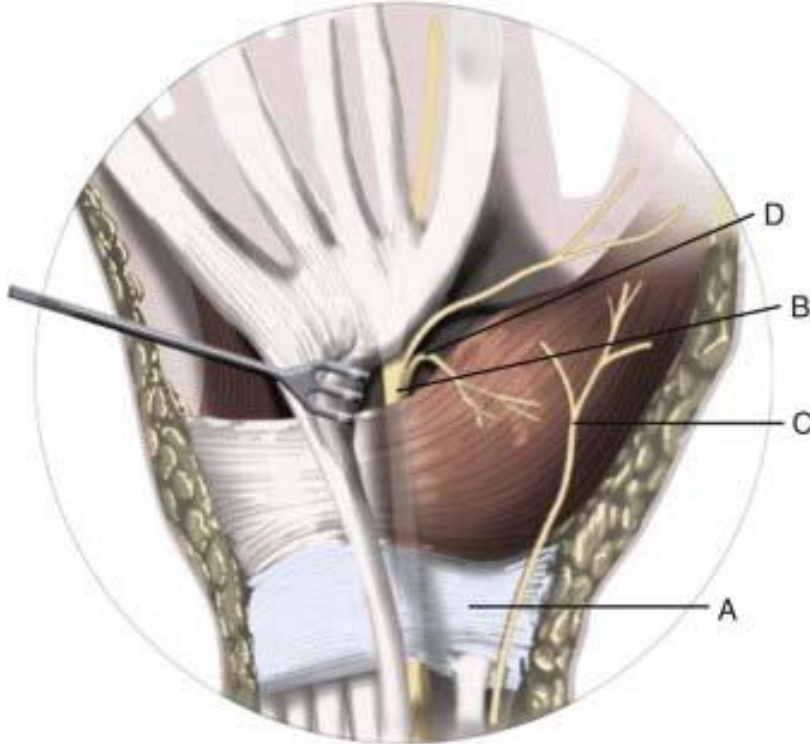
- **transverse carpal ligament (TCL)** arches between **pisiform** and **hook of hamate** *ulnarly*, and **scaphoid tuberosity** and **crest of trapezium** *radially*
- TCL is 3-4 cm in width and 2.5-3.5 mm in thickness
- **palmar fascia** is fused to **TCL** proximally and then fans out to soft tissue of palmar skin as *palmar aponeurosis*

FLEXOR RETINACULUM = TCL + proximal palmar fascia

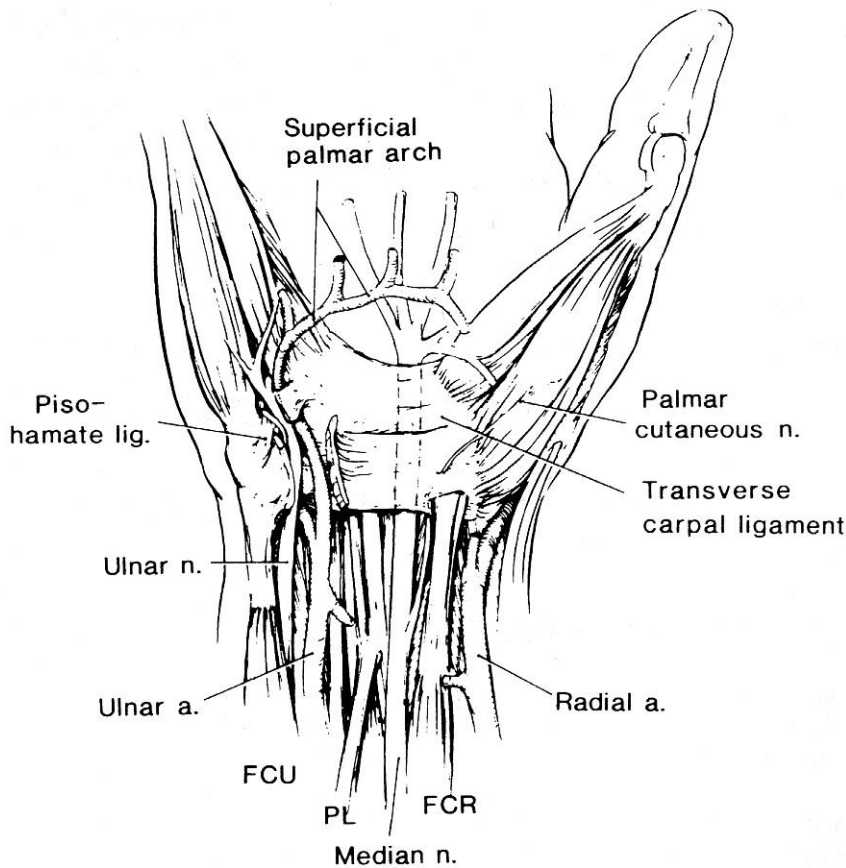
- ulnar nerve and ulnar artery run superficially on ulnar side of the TCL

- tendon of flexor carpi radialis is enveloped by two layers of TCL on radial side of wrist.

A, flexor retinaculum; B, median nerve; C, palmar cutaneous branch; D, recurrent motor branch:



Source of picture: Huang JH, Zager EL. Mini-open carpal tunnel decompression. Neurosurgery.2004;54:397.



Source of picture: David C. Sabiston "Sabiston Textbook of Surgery: the Biological Basis of Modern Surgical Practice", 15<sup>th</sup> ed. (1997); W.B. Saunders Company; ISBN-13: 978-0721658872 >>

Median nerve is vulnerable to compression at two particular sites in carpal tunnel:

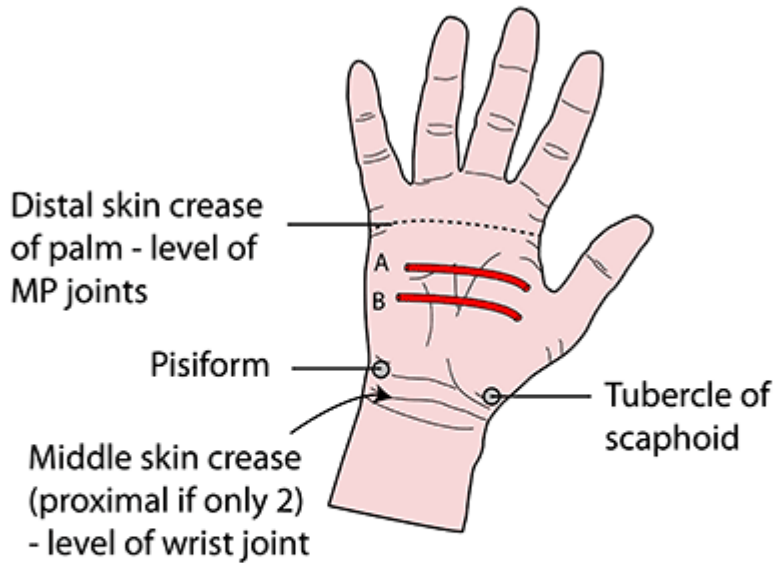
- 1) proximal edge of TCL

- 2) adjacent to hook of hamate

**ARTERIAL ARCS IN PALM**

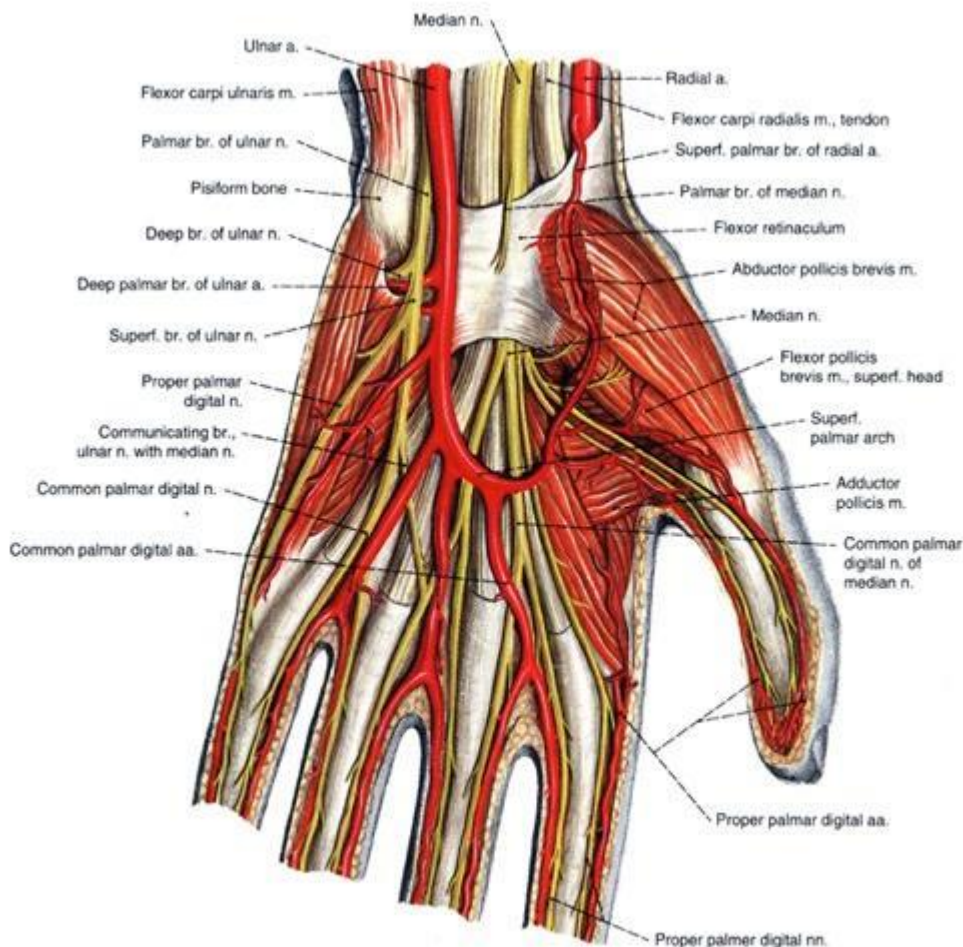


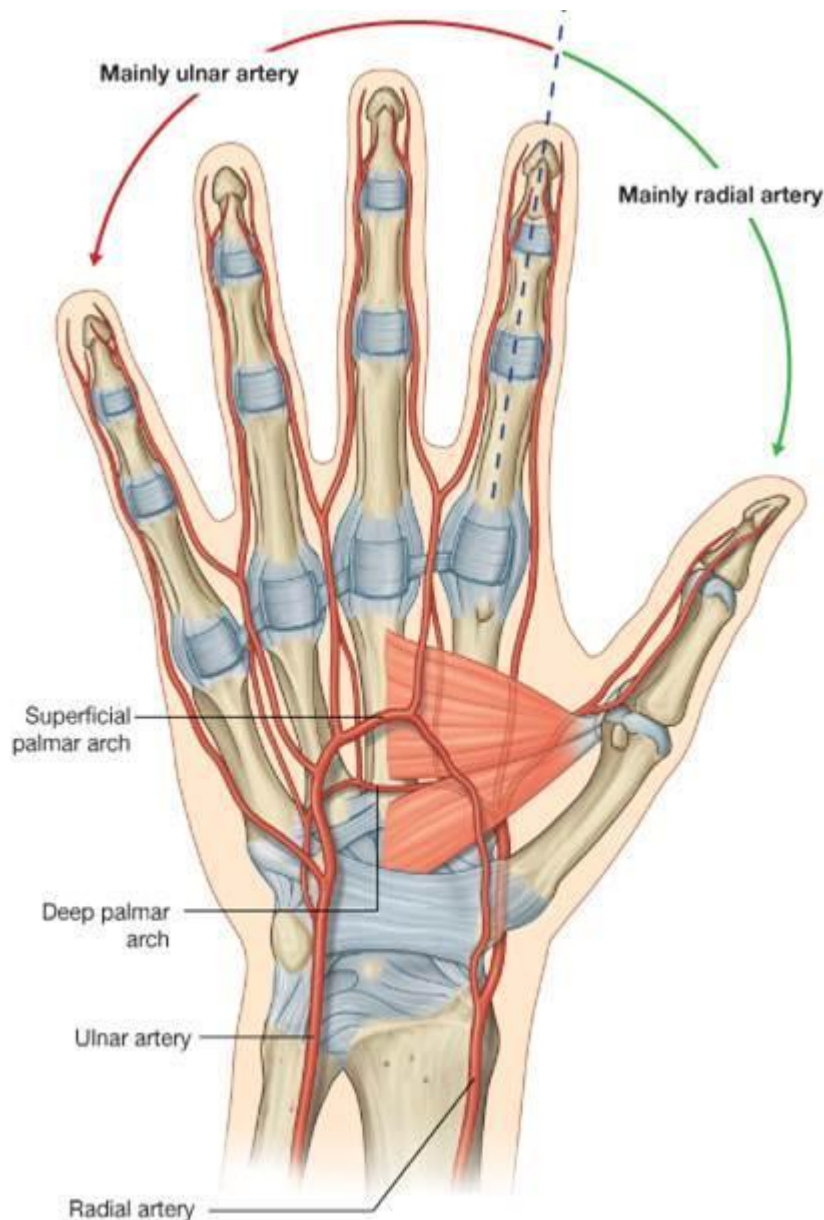
## SURFACE ANATOMY



**A Superficial palmar arch**  
 Level with outstretched thumb.  
 From ulnar artery.  
 1/2 way between distal palmar crease and distal wrist crease

**B Deep palmar arch**  
 From radial artery.  
 1 cm proximal to superficial arch





## TECHNIQUE

R. Jandial "Core Techniques in Operative Neurosurgery" (2011)

E. Sander Connolly "Fundamentals of operative techniques" (2002)

Mark S. Greenberg "Handbook of Neurosurgery" 7<sup>th</sup> ed. (2010)

H. Richard Winn MD "Youmans Neurological Surgery" (2011)

Fischer "Atlas Of Approaches In Neurosurgery"

Roberto C. Heros "Kempe's operative neurosurgery" (2003)

Setti S. Rengachary "Neurosurgical operative atlas" (1991-1993)

Henry H. Shmidek "Operative Neurosurgical Techniques" 5<sup>th</sup> ed. (2006)

**Surgical release** of transverse carpal ligament (TCL) – successful in 70-90% cases.

- endoscopic procedures are also successful (2-portal or single-portal technique). *see below*
- RA patients – also add *tenosynovectomy*.
- most reliable guide to nerve at operation - **m. palmaris longus tendon** - inserts in palmar aponeurosis and lies directly over median nerve just proximal to **TCL**.

*m. palmaris longus* is absent in 25% individuals - median nerve is beneath fascial membrane midway between **m. flexor carpi radialis** and **m. flexor digitorum superficialis** tendons.

- 10% ulnar nerves and 4% ulnar arteries lie radial to hook of hamate outside of Guyon canal - risk for injury during carpal tunnel surgery.

### POSITION

supine with arm abducted 60 degrees and forearm supinated on arm board.

- tourniquet is optional.
- wrist is often placed on a roll to provide wrist extension.

### ANESTHESIA

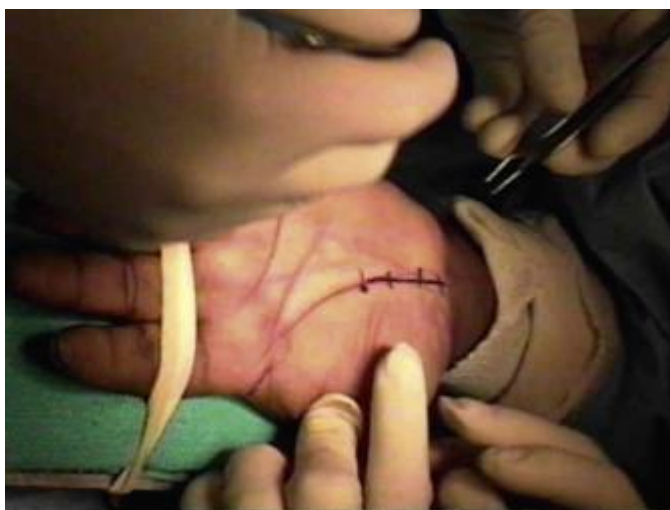- local nerve block (0.25% bupivacaine containing 1:200,000 epinephrine) – infiltrate along incision
- axillary block
- Bier block.

### SKIN INCISION

- straight or slightly curvilinear, 3-4 cm (1.5-3 cm in “mini-open” approach)

Incision cannot be too short but *postoperative pain is proportional to length of incision*, therefore, **Dr. Holloway** prefers endoscopic approach.

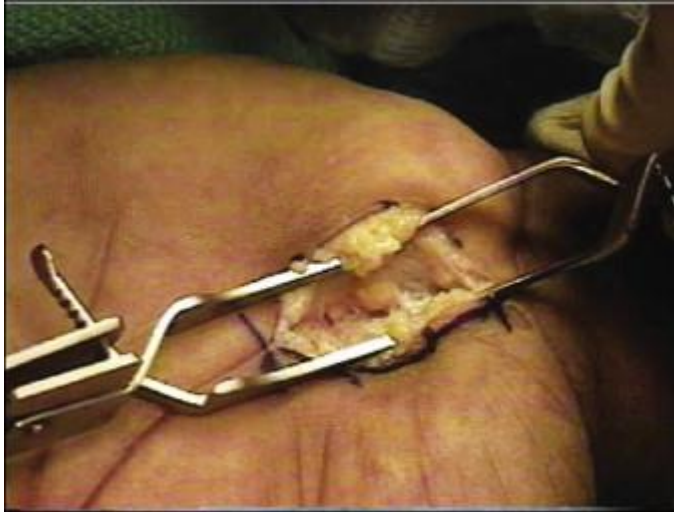- just ulnar or directly over **m. palmaris longus tendon** ( $\approx$  longitudinal midpalmar crease or 6 mm to ulnar side of thenar crease)
  - proximal end - at *proximal wrist crease* (exposes median nerve just before it dips under flexor retinaculum);
  - *zigzag* across wrist (to avoid scar which restricts motion).
  - distal end stops  $\approx$  1.5 cm beyond *distal wrist crease*; may have to be extended distally for better exposure in large hands
  - length of incision  $<$  3 cm (postoperative pain is proportional to length of incision);
  - retracting palmaris longus reliably locates median nerve.
- along **thenar crease / middle palmar crease** (**Dr. Cameron**)
  - proximal end - at *distal wrist crease*
  - *curvilinear* (along thenar crease) or straight (along middle palmar crease)
  - length of incision 3-4 cm
  - distal end stops at point intercepting imaginary line (Kaplan's) drawn from distal border of extended thumb to pisiform prominence, in line with long axis of radial side of ring finger.



- Dr. JRC** bends 4<sup>th</sup> finger – finger tip points to correct crease.



- deep to skin, subcutaneous fat and palmar fascia are encountered (take care to protect palmar cutaneous branch of median nerve, which is not consistently visualized)
- Senn, Alm, cricket, or small bur-hole retractor
- bipolar electrocautery



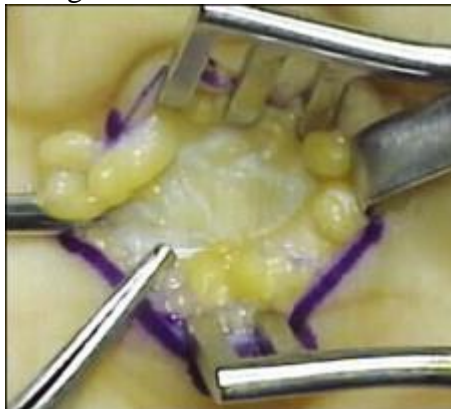- deep to palmar fascia will encounter shining retinaculum fibers (occasionally, thenar and hypothenar muscles may obscure ligament).

#### RETINACULUM CUT

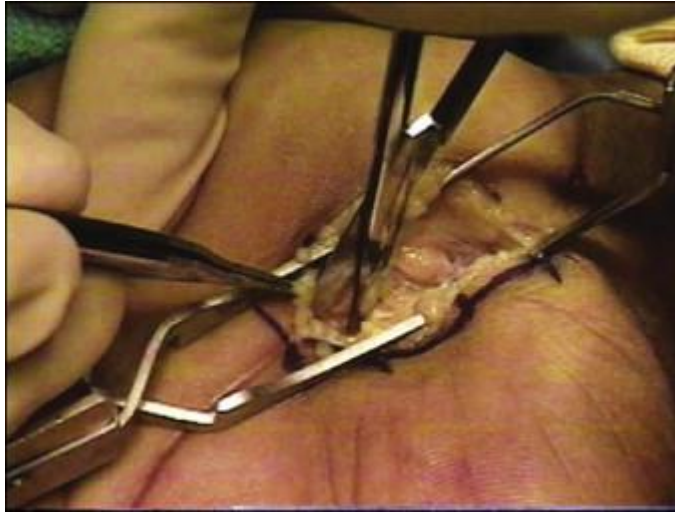
- accurately over midpoint of nerve surface (so as to avoid sliding down dangerous radial side of nerve - motor branch to thenar)

Do not injure **ulnar neurovascular bundle** by retractor blade!

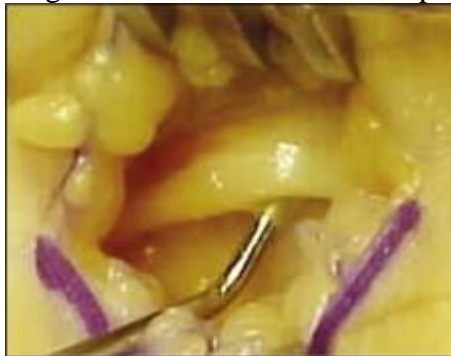Also **recurrent motor branch of median nerve** may be transligamentous or subligamentous!



- TCL is divided at its midpoint
- use scissors or scalpel and direct visualization of median nerve



- incision follows course of nerve as it is exposed gradually by advancing cut.
- proceed distally until deep palmar fat around superficial palmar arch is encountered.
- fine-tip Crile instrument is passed proximally and distally along median nerve – check median nerve for changes in color or thickness and presence of adjacent tumors or masses



- completeness of **distal** cut is confirmed by checking for remaining cross bands while dragging curve-tipped clamp\* backward toward opening.
- check completeness of **proximal** cut: skin is elevated to permit visualization 2-3 cm into forearm; drag curve-tipped clamp\* (with tip against skin) backward toward opening; proximal TCL and distal antebrachial fascia are incised.

\*or Penfield No. 4 dissector

- *neurolysis* of median nerve is not generally recommended.

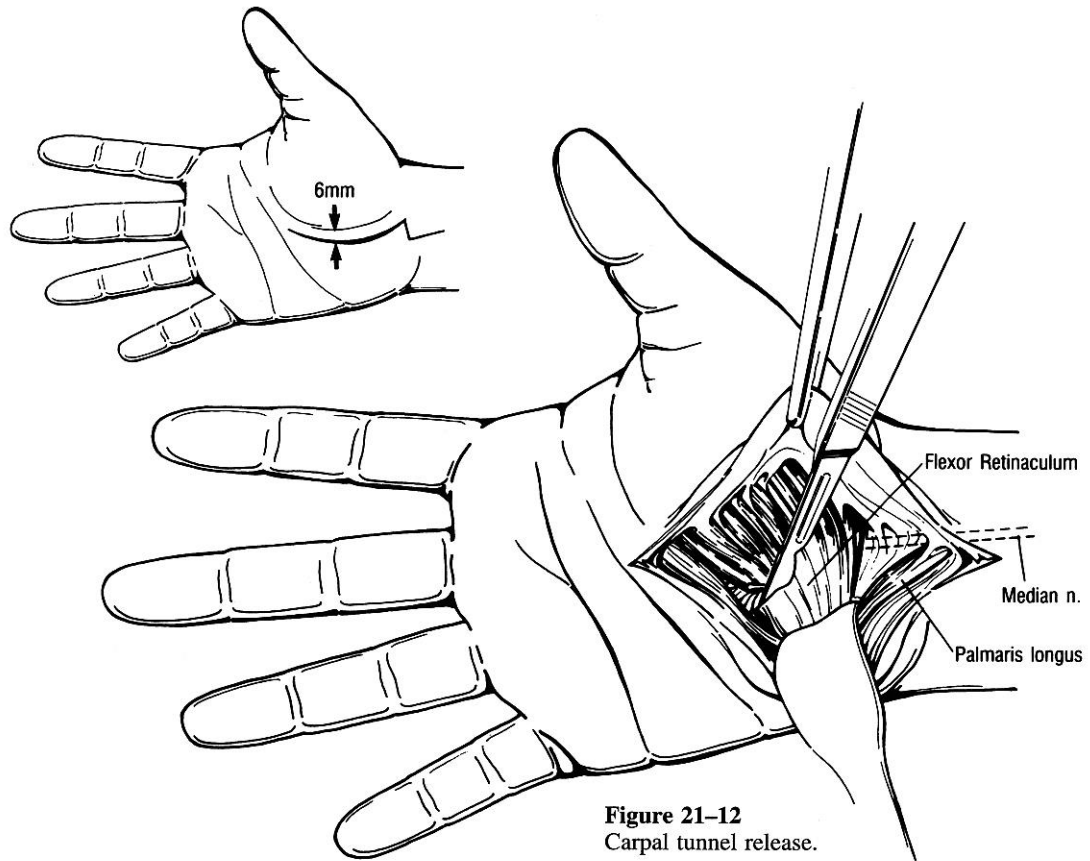
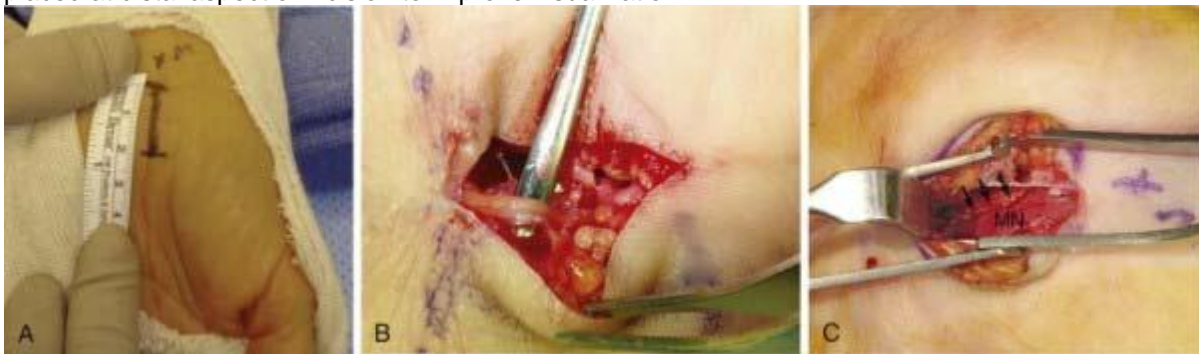

Figure 21-12  
Carpal tunnel release.

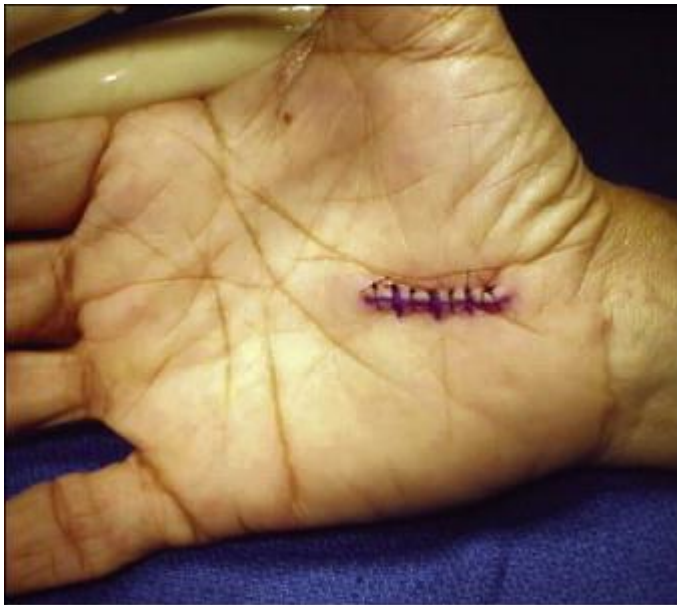Mini-open carpal tunnel release:

- A, Incision measuring 2 cm starting at distal wrist crease and extending distally in line with third interspace.
- B, Intraoperative identification of median palmar cutaneous nerve (identified with a No. 4 Penfield dissector).
- C, After division of transverse carpal ligament (*arrows*), the median nerve (MN) is visualized. Senn retractor is placed at distal aspect of incision to improve visualization:



**CLOSURE**

- meticulous hemostasis (if used, tourniquet should be released at this point).
- optional: 3-0 Vicryl for palmar aponeurosis and loose connective tissue (do not reapproximate TCL!)
- 2-0 or 4-0 nylon (vertical mattress) on skin
- bulky fluff gauze dressing is applied to volar surface, along with elastic wrap.



## RESULTS

89% of patients were satisfied with results:

Improvement in pain was seen in 87% of patients, improvement in paresthesias in 92%, improvement in numbness in 56%, and improvement in weakness in 42% of patients.

Major symptoms persisted in 6% of patients.

## COMPLICATIONS

- (1) **median nerve transection** → repair with epineurial sutures
- (2) **hematoma** → emergency evacuation
- (3) **incomplete TCL** sectioning;
- (4) cutting *ulnar-median anastomotic branch* (runs parallel to and  $\approx$  1 cm beyond distal **TCL** edge);
- (5) palmar **pain**;
- (6) pillar **pain** along thenar & hypothenar eminences (related to adjustment of carpal bone alignments);
- (7) temporary **loss of grip** strength (secondary to relocation of origin of hypothenar and thenar muscles and bowing of flexor tendons through **TCL** incision).

## POSTOPERATIVE

- remove elastic wrap after 6 hours; keep dressing for 2 days.
- keep hand elevated.
- encouraged to perform gentle finger ROM exercises ASAP – *move fingers frequently*; do not remove dressing until 1<sup>st</sup> postoperative visit (10-12 days after surgery, when sutures are taken out).
  - return to work 3-4 weeks after surgery.
  - postoperative visits q 3 months for 1 year.
- **postoperative splinting** is not usually recommended - has not been shown to improve wound healing, reduce postoperative pain, or diminish scar tenderness\*. However, Dr. Holloway recommends it to protect incision.

\*patient is advised to gently stimulate surgery area to avoid habitual overprotection of the area



## CARPAL TUNNEL RELEASE (ENDOSCOPIC TECHNIQUE)

From Youmans:

Endoscopic carpal tunnel release (ECTR) has been performed since the late 1980s, and several different endoscopic techniques involving either a uniportal or biportal approach have been developed since. The Agee[66] and Okutsu[67,68] methods use the uniportal approach, whereas the Chow[69] and Brown[70] techniques use the biportal method. For both types of approaches, a tourniquet and either local anesthesia or a Bier block are used. A small incision is made at or just proximal to the distal wrist crease on the ulnar side of the palmaris longus tendon. The antebrachial fascia is exposed and divided bluntly. An elevator is placed deep to the antebrachial fascia and superficial to the flexor tendons. An obturator and slotted cannula are then inserted into the carpal tunnel while staying superficial to the median nerve and flexor tendons. In the two-portal technique, the obturator and cannula are brought through the skin approximately 4 cm distal to the distal wrist crease, the obturator is removed, and an endoscope is placed through the distal opening. The cannula is slotted to allow passage of a blade.

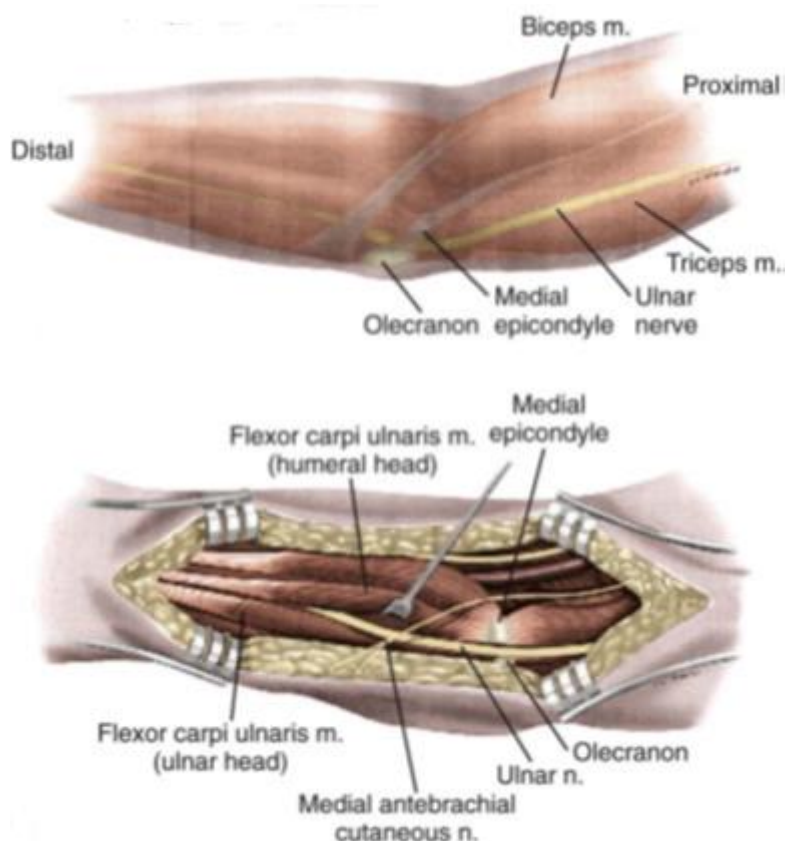
The TCL is divided in either a proximal-to-distal or a distal-to-proximal manner. In the uniportal technique, the endoscope camera follows the blade. With these endoscopic techniques no attempt is usually made to visualize the median nerve. Once the TCL has been completely divided, the cannula is removed, the tourniquet is deflated, and after hemostasis is obtained, the skin incision or incisions are closed with simple skin stitches.

Potential advantages include a shorter recovery time, less postoperative pain, and reduced wound complications.

Drawbacks include a **steep learning curve**; less visibility, which may result in **incomplete sectioning** of the TCL and **increased neurovascular injury**; and **increased cost** associated with endoscopic instruments. Hankins and coauthors reported a large case series of patients who underwent ECTR with the Brown biportal technique. Of the 14,722 patients included in this series, 82.6% had complete resolution of symptoms, 14.7% had some resolution, and 2.6% had no improvement and required open revision.[73] Although ECTR has a growing number of proponents, open carpal tunnel release (OCTR) is still the approach used by most peripheral nerve surgeons.[9] During the past 2 decades there has been quite a bit of controversy over the question whether OCTR or ECTR is superior. The Cochrane Collaboration recently published a systematic review of carpal tunnel surgery in which they looked at 33 studies involving CTS. Fourteen studies reported results pertaining to return to work or normal daily activity and found a mean difference of 0 to 25 days in favor of the endoscopic approach. In terms of reported complications, ETCR was associated with more transient nerve dysfunction such as neurapraxia, numbness, and paresthesias, whereas OCTR was found to have more wound complications. From 6 published studies that included revision rates, the relative risk of needing revision surgery was determined to be higher in the endoscopic group. Revision surgery was performed in 12 of 513 ECTR procedures versus 5 of 370 OCTR procedures (relative risk, 1.2; confidence interval, 0.5 to 3.1). The authors concluded that there is no strong evidence supporting replacement of the standard OCTR and that application of ECTR should be guided by patient and surgeon preference. Four of the studies included compared ECTR and OCTR with a modified incision.[74-77] Pain score, symptom severity, and functional status initially favored ECTR but equilibrated by 8 to 12 weeks postoperatively.[76,77] Use of a modified incision appeared to increase the need for revision surgery in comparison to ECTR.[74] This review also found no evidence supporting internal neurolysis, epineurotomy, tenosynovectomy, or flexor retinaculum lengthening.[78]

# ULNAR NERVE NEUROLYSIS AT ELBOW

## ANATOMY



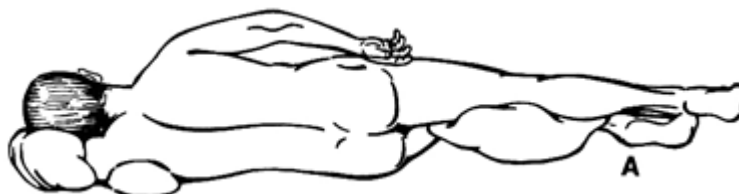Source of picture: Huang JH, Samadani U, Zager EL. Ulnar nerve entrapment neuropathy at the elbow: Simple decompression. Neurosurgery. 2004;55:1150

## PROCEDURE

- anesthesia: monitored IV sedation + local.

### POSITION

- SUPINE** with arm abducted on armrest table (surgeon and assistant are on either side of extremity); shoulder is abducted 90 degrees, the arm is extended, and the forearm is supinated (small roll under the shoulder may help in maintaining this position).
- LATERAL DECUBITUS** - more comfortable for awake patient + more accessible entire segment of ulnar nerve to be dissected.



### NEUROLYSIS (IN SITU DECOMPRESSION)

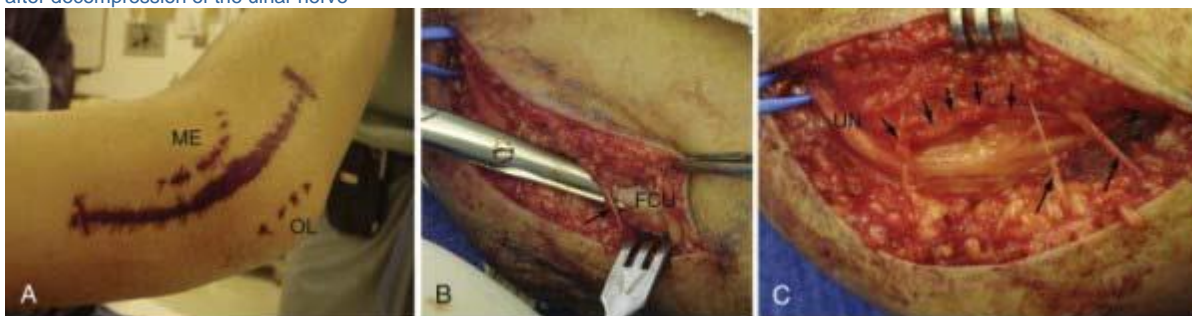- simple **cubital tunnel release** (sectioning taut aponeurosis) – indicated in milder and less chronic forms.

- “lazy omega” incision over medial epicondyle of humerus:
  - a) *convex portion of incision faces anteriorly* – thus, away from tension when elbow is flexed, plus, not overlying nerve).
  - b) if planning transposition - *convex portion of incision faces posteriorly* – this way transposed nerve will be protected under flap.
- dissection with tenotomy scissors through subcutaneous tissue until myofascial layer is reached (i.e. develop full thickness skin-subcutis flap)
 

N.B. *sensory nerve (medial antebrachial) runs across incision* in subcutaneous layer – try to preserve it (or annoying anesthesia will result)!
- then dissect toward cubital canal.
- ulnar nerve is identified in cubital tunnel (usually need to dissect multiple epineurial layers until nerve itself is seen).
- carefully dissect almost\* circumferentially with care taken to preserve branches of feeding vessels.
 

\*ideally, nerve is not circumferentially dissected out! (devascularization, damage to slender branches to flexor carpi ulnaris).
- neurolysis is extended **distally** to point of nerve entry between heads of flexor carpi ulnaris (widely split open aponeurosis between 2 heads of flexor carpi ulnaris, then split FCU along fibers – rather far distally!).
- neurolysis is extended **proximally** to arcade of Struthers, fascia between medial head of triceps and medial intermuscular septum is divided; nerve is released completely from where it pierces intermuscular septum to well beyond Osborne bands – i.e. cutting intermuscular septum, Struthers arcade, arcuate cubital ligament.

Simple decompression of the left ulnar nerve at the elbow. **A**, A 6- to 8-cm incision overlying the course of the ulnar nerve placed between the medial epicondyle (ME) and the olecranon (OL). **B**, Intraoperative demonstration of a branch of the medial antebrachial cutaneous nerve (arrow) and the tendinous edge of the flexor carpi ulnaris muscle (FCU). **C**, Preservation of several branches of the medial antebrachial cutaneous nerve (long arrows) and complete decompression of the ulnar nerve (UN). Note the divided fascial edge (short arrows) after decompression of the ulnar nerve



- **external neurolysis (i.e., circumferential dissection) of the UN is not performed.**
- **once decompression is completed, the elbow is flexed and extended to look for nerve subluxation - if significant subluxation is present, some surgeons believe that a transposition procedure is warranted;** some experts never perform a transposition at the same time because it rarely proves to be needed.
- subcutaneous tissues are closed with 3-0 Vicryl in interrupted fashion with inverted knots.
- skin is approximated with simple running subcuticular 4-0 Monocryl suture
- sterile dressing followed by Ace wrap.
- place arm flexed at elbow into sling for comfort only.

### POSTOP

- remove Ace wrap tonight, leave white dressings on for 5 days
- keep arm in sling for 1-2 weeks (up to 3 weeks if transposition was used)
- early mobilization of the arm is encouraged - gentle full range of motion exercises x3/day starting on POD#2

## FAILURES

Surgical failure usually is due to inadequate release:

- a) at intermuscular septum
- b) between heads of flexor carpi ulnaris.
- failure of *in situ decompression & epicondylectomy* → *subcutaneous transposition*.
- failure of *subcutaneous transposition* → *remove kinking* of nerve at both ends of transposition.
- exquisite nerve tenderness in palpable subcutaneous course → *submuscular transposition*.

From Youmans

A 6- to 8-cm curvilinear incision is planned over the course of the UN as it traverses the elbow adjacent to the medial epicondyle, with 3 to 4 cm of the incision projecting proximal and 3 to 4 cm distal to the elbow. During subcutaneous dissection, care must be taken to preserve branches of the medial brachial and antebrachial cutaneous nerves because injury may result in neuroma formation.[99] The deep fascia overlying the UN is incised with either scissors or a No. 15 scalpel blade. The UN is identified and exposed proximal to the postcondylar groove. Dissection is carried distally through the postcondylar groove, and the fibrofascial cubital retinaculum overlying the nerve is divided. As mentioned before, this is most often the site of maximal compression. The UN is followed distally by dividing Osborne's fascia, the proximal edge of the FCU muscle, and at this point care must be taken to protect the muscle branches of the nerve. The distal skin edge can be elevated for distal visualization of the nerve. Exposure of the UN is also carried proximal to the postcondylar groove to inspect for possible compression at the arcade of Struthers and the medial intermuscular septum. The proximal skin edge should also be elevated for better visualization. The proximal and distal extent of the exposure is probed for any constrictive bands.

## IN SITU DECOMPRESSION VS. NERVE TRANSLOCATION

Currently, there is no consensus whether in situ decompression or nerve translocation is the optimal surgical procedure.

Pros of in situ decompression: simple procedure - shorter operative time, local anesthesia, shorter recovery time, does not require sacrifice of any vessels or nerve branches, and preserves the anatomic course of the nerve.

Pros of transposition: removes the dynamic compression seen during elbow flexion and places the nerve in a more protected position.

**Cochrane systematic review** (430 patients) **failed to find a significant difference** in outcomes between the 2 procedures.

*Caliandro P, La Torre G, Padua R, Giannini F, Padua L. Treatment for ulnar neuropathy at the elbow. Cochrane Database Syst Rev. 2012;11(7):CD006839.*

**Zlowodzki et al (2007)** published a meta-analysis of four randomized, controlled trials that compared in situ decompression and anterior transposition.

- two of these studies used the submuscular transposition method, and two used the subcutaneous technique.
- total of 261 patients with an average follow-up of 21 months
- **no significant difference** in **clinical outcome** or **postoperative nerve conduction velocity** between **in situ decompression**, **subcutaneous transposition**, and **submuscular transposition**.
- significantly fewer complications occurred in patients who underwent **in situ decompression** than in those who underwent subcutaneous transposition.

**Bartels et al.** reported a complication rate of 9% in the in situ group and 30% in the anterior subcutaneous transposition group. They also compared the costs associated with simple decompression



and anterior subcutaneous transposition by using data accumulated from a randomized, controlled trial - anterior subcutaneous transposition procedure has a total median cost 2.5 times that of simple decompression. Costs related to sick leave had the most impact on this difference. Submuscular UN transposition was shown to result in longer recovery times and higher wound complication rates than in situ decompression was.

**Gervasio et al.** demonstrated that patients who underwent in situ decompression returned to work, on average, 9 days earlier than those who underwent submuscular transposition (21 versus 30 days).

**Biggs and Curtis:** 4 of 21 patients who underwent submuscular transposition and 2 of 23 who underwent in situ decompression experienced superficial wound infections; 3 of 21 patients who underwent submuscular transposition and 0 of 23 who underwent in situ decompression experienced deep wound infections. Furthermore, in situ decompression is routinely performed with local anesthesia, thereby avoiding potential complications associated with general anesthesia.

Proponents of submuscular transposition argue that devascularization of the UN after transposition is rarely clinically evident. Davis and Bulluss retrospectively demonstrated no deterioration in symptoms or UN function after submuscular transposition. Furthermore, 82.5% of these patients (33/40) undergoing initial surgery improved at least one grade based on the LSUMC grading system.

### ENDOSCOPIC DECOMPRESSION

Recently, the endoscope has been used to decompress the UN at the elbow. In 1999, Tsai and coauthors published a series of 85 cubital tunnel releases with endoscopic assistance. Through a 2- to 3-cm incision over the course of the UN at the elbow, the authors were able to decompress up to 10 cm proximal and 10 cm distal to the medial epicondyle. In 36 patients with abnormal two-point discrimination preoperatively, 23 (64%) showed improvement after surgery. No significant difference was found between preoperative and postoperative motor function at a mean follow-up period of 32 months. Two patients subsequently required transposition procedures for recurrent symptoms.[110] Ahcan and Zorman published a series of patients who underwent endoscopic release of a 20-cm segment of UN via a 3.5-cm incision overlying the cubital tunnel, with good or excellent results achieved in 91% of patients.[111] In 2006, Krishnan and coauthors published a series of 11 patients who underwent endoscopically assisted anterior transposition of the UN with a unique endoscope-retractor system. Through a 1.5- to 2-cm incision over the ulnar sulcus, the UN was freed circumferentially proximally through the medial intermuscular septum and distally through Osborne's ligament. The nerve was transposed subcutaneously and a fascial flap was created to maintain this position. Using the Bishop scoring system, 7 patients (63.7%) had excellent results, 3 (27.3%) had good results, and 1 patient (9.1%) had fair results with a mean follow-up time of 15.5 months. There were no complications, nor did any case have to be converted to an open procedure.

### IN SITU DECOMPRESSION WITH MEDIAL EPICONDYLECTOMY

- **removal of medial epicondyle** (medial wall of ulnar groove)
  - nerve first is decompressed in situ.
  - medial epicondyle is subperiosteally exposed and removed without disturbing origin of pronator teres.
  - soft tissues over osteotomy bed are carefully approximated.

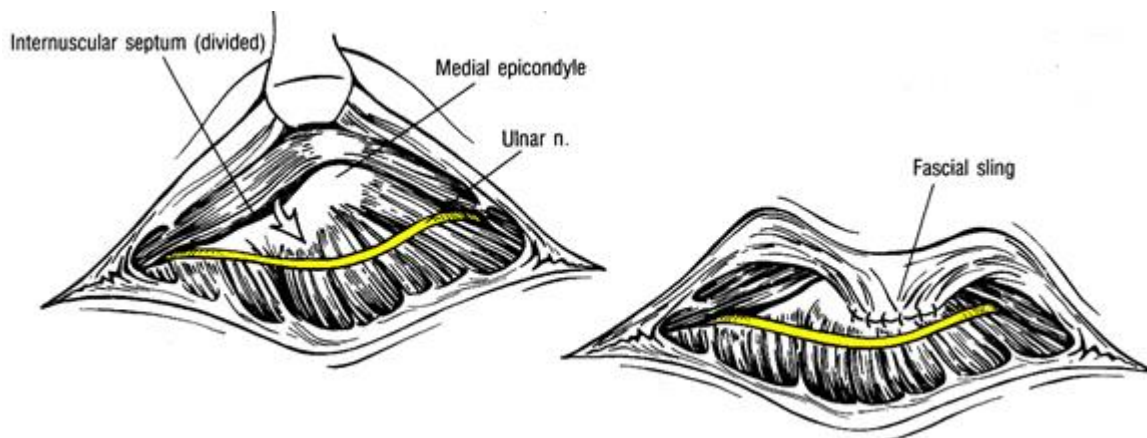
#### From Youmans

In situ decompression is sometimes supplemented with medial epicondylectomy. First introduced by King and Morgan in 1959,[101] this technique involves performing total or subtotal medial epicondyle osteotomy, thereby allowing the UN to move anterior to the axis of rotation of the elbow. Proponents also cite the medial epicondyle as a source of UN irritation.

We suspect that the effectiveness of epicondylectomy may be related to the in situ nerve decompression that is performed at the same time. Complications of this procedure can include **medial elbow stiffness or instability**, or both, particularly if too much of the epicondyle is resected.[22,102] We do not favor intramuscular transposition of the UN because this technique tends to result in the most scar formation.

## SUBCUTANEOUS TRANSPOSITION

- **nerve mobilization and moving anterior** to epicondyle (beneath flexor muscles) - definitive decompression!
- nerve is circumferentially dissected (neurolysis) and lifted out of its cubital tunnel bed.
  - to elevate nerve from postcondylar groove, articular branches and small vessels tethering UN often need to be divided; fortunately, nerve tolerates such dissection in vast majority of cases
  - *sensory fibers to elbow joints* are severed.
  - *twigs to upper flexor carpi ulnaris* may come off quite proximally and should be dissected carefully away from epineurium to gain length to allow nerve to be moved onto anterior surface of elbow flexor muscles in front of medial epicondyle.
- **avoid kinking nerve** at both ends of transposition:
  - aponeurosis and fibers of *m. flexor carpi ulnaris* are split longitudinally between 2 heads.
  - in proximal end, distal segment of the medial intermuscular septum must be excised to prevent tethering or compression of the transposed UN
- nerve is brought anterior to the medial epicondyle and placed in subcutaneous bed under preformed flap
- fascial sling is created to hold the nerve from slipping backward by row of absorbable sutures (between flap and surface of *m. pronator teres* just in front of medial epicondyle).



## INTRAMUSCULAR TRANSPOSITION

- **less vulnerability** than nerve in subcutaneous location - after transposition, nerve is placed in shallow muscular trough created in *m. pronator teres* and *m. flexor carpi ulnaris*; but recurrent symptoms are more common! (postoperative scarring within intramuscular bed).

From Youmans

In the case of submuscular transposition, the origin of the flexor-pronator mass is isolated and divided in a step-cut or Z-plasty configuration, with a proximal cuff of muscle and fascia left intact. Laterally, care must be taken to avoid the brachial artery and median nerve. The proximal attachment of the volar FCU to the ulna needs to be detached to prevent distal kinking of the UN. The UN is brought anteriorly and placed deep to the flexor-pronator mass. The

nerve must not be kinked or compressed over its new course. The flexor-pronator mass is then reapproximated by using the step cut to provide lengthening. Reattachment is performed with multiple 0-grade sutures.

## SUBMUSCULAR TRANSPOSITION

Dr. Graham's preferred transposition!

- placing nerve in submuscular plane lined by muscle fascia - *nerve can glide with joint motions* without being "stuck down" (as in intramuscular or subcutaneous locations).

- anterior surface of *m. pronator teres* is dissected free over length of 4 cm beyond its origin, often necessitating severance of LACERTUS FIBROSIS (fibrous extension of medial free edge of biceps aponeurosis across antecubital fossa).
- divide with Bovie muscle (*m. pronator teres, m. flexor carpi ulnaris*) origin from medial epicondylus – must leave ulnar bone exposed!
- anteriorly transposed ulnar nerve is placed under divided muscles on bone-fascial bed over *m. flexor digitorum superficialis* and *m. brachialis*.
- cut ends of divided tendons are reapproximated in Z-plasty format (horizontal mattress silk sutures) - muscle origin is moved posteriorly - so that they are lengthened, in effect, to lessen tightness over underlying nerve bed.
- elbow is cast at 45° flexion for 3-4 weeks (avoid pronation exercises) → gentle physical therapy (to return joint to full extension over 3 weeks).

## ULNAR NERVE NEUROLYSIS AT WRIST

Anatomy – see p. PN5 >>

- longitudinal incision across wrist crease, along course of ulnar nerve → curves slightly toward hook of hamate.
- fibrotendinous bands over deep branch are cut.
- nerve is traced straight through, past hamate, and extraneurally decompressed all along.
- particularly sharp and downward pinching hook may need to be resected by Kerrison punch.

## PERONEAL NERVE NEUROLYSIS AT FIBULAR HEAD

Anatomy, clinical findings, conservative treatment, tendon transfer – see p. PN5 >>

Indication - for patients who show little or no improvement after 3-4 months.

Technique

- supine position.
- entire leg is prepped.
- lazy C incision just below the left fibular head, over the peroneal canal and over the peroneal nerve course (peroneal nerve is found proximal and posterior to head of fibula).
- dissection through subcutaneous tissue until myofascial layer is reached.

- sharp edge of peroneus longus tendinous aponeurosis and muscular fibers are partially split over the nerve course, thus, entering peroneal tunnel.
- nerve is followed to entrapment point (usually where nerve runs through tunnel roofed by **peroneus longus muscle**).
- peroneal nerve is identified and dissected almost circumferentially with care taken to preserve branches of feeding vessels whenever possible.
- neurolysis is extended both distally and proximally – looking for areas of entrapment or neuroma.
- deep peroneal nerve is followed to extensor digitorum muscle to ensure that it is free.
- optional stimulation to test the nerve – look for distal muscle action.
- may leave peroneal aponeurosis unrepaired to eliminate any source of even slightest compression.
- subcutaneous tissues closed with 2-0 Vicryl → Steri-strips.

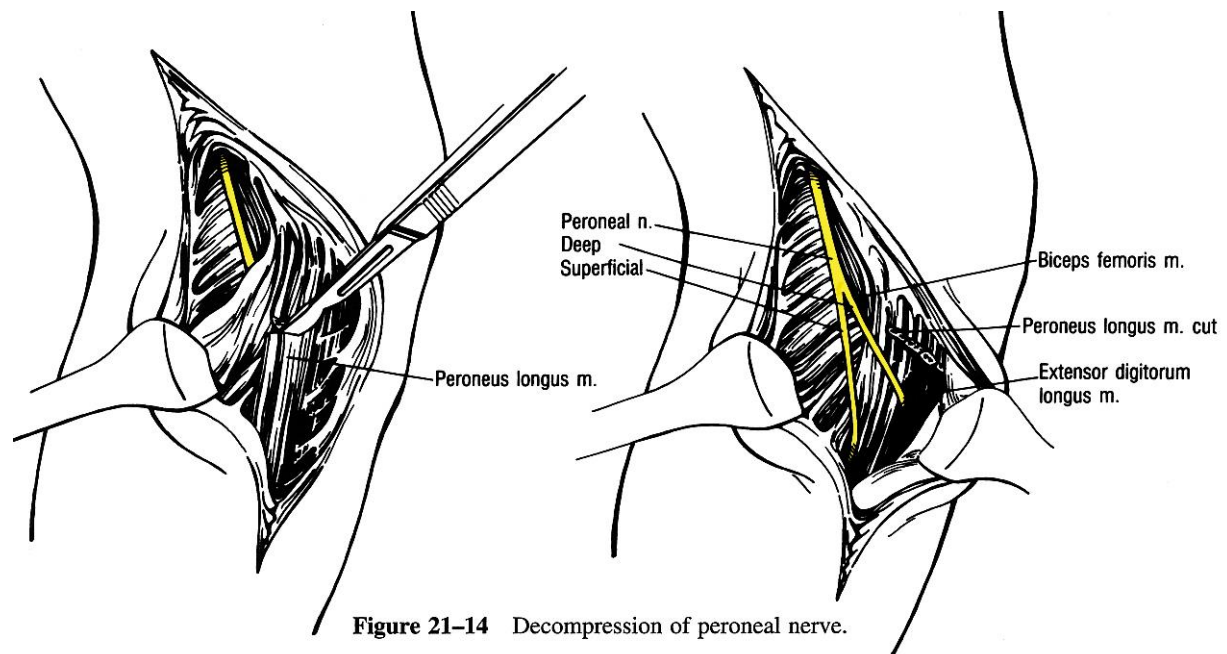


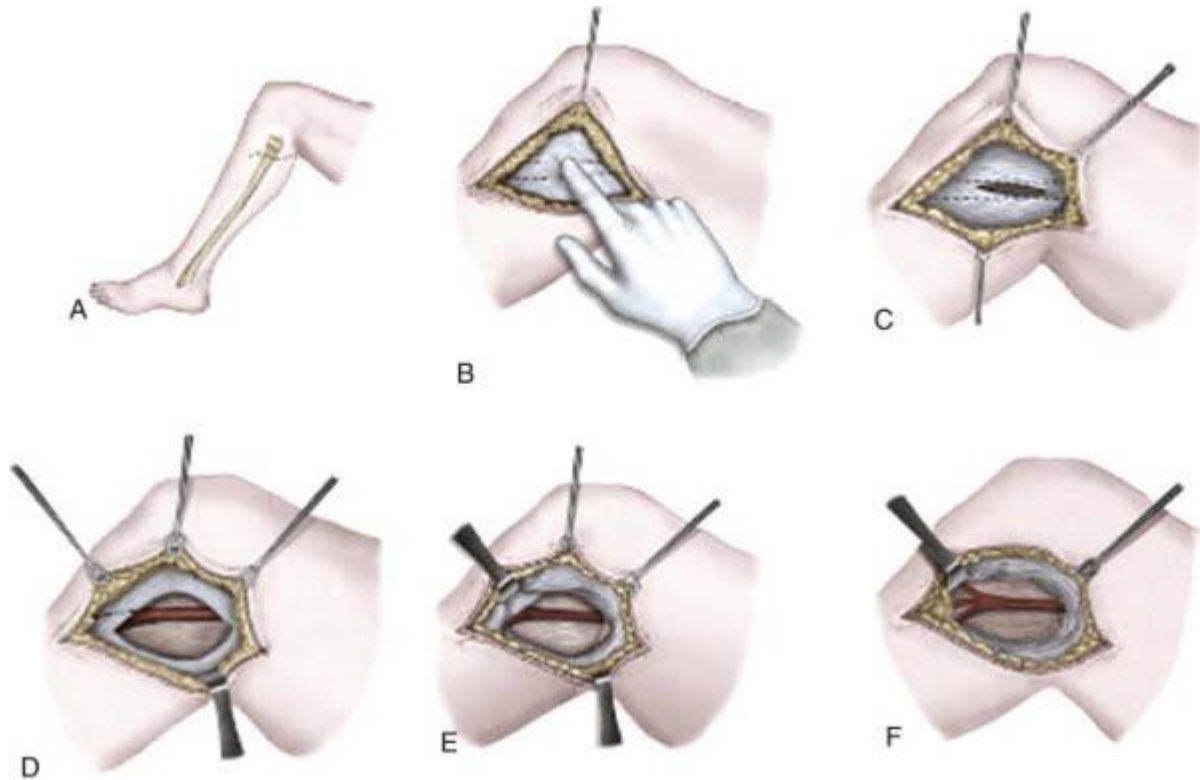
Figure 21-14 Decompression of peroneal nerve.

### From Youmans

Operative decompression of the CPN is relatively straightforward and well tolerated. General anesthesia is used most often (we prefer local anesthesia with mild sedation), and a tourniquet is optional. The patient is positioned laterally with the affected leg uppermost and flexed at the knee. A curvilinear incision is marked in an oblique orientation over the fibular neck above the anticipated course of the CPN:

Schematic illustration of decompression of the common peroneal nerve. **A**, The incision is oriented obliquely along the course of the peroneal nerve just below the fibular head. **B**, After the soft tissue is opened, the surgeon can palpate the peroneal nerve and roll it with a finger just below the fibular head. **C**, The fascia overlying the peroneal nerve is opened. **D**, The peroneal nerve is dissected and the fascia above the peroneus musculature is opened. **E**, The muscle is retracted to identify the fascial band directly below the muscle, which is the main compression point on the peroneal nerve. **F**, The peroneal nerve and branches are completely decompressed:





Picture source: Humphreys DB, Novak CB, Mackinnon SE. Patient outcome after common peroneal nerve decompression. *J Neurosurg.* 2007;107:314

After infiltration with local anesthetic, an incision is made with a No. 15 scalpel blade. Care is taken to preserve any significant cutaneous nerve branches, such as the lateral sural cutaneous and posterior femoral cutaneous nerves. The deep fascia is incised over the usually palpable CPN. The CPN is often surrounded by a significant amount of adipose tissue and is identified and protected. Exposure of the nerve is carried both proximally and distally. The CPN is followed around the fibular neck as it passes between the two heads of the peroneus longus. The fascia overlying the peroneus longus is divided and the nerve followed distally. A fascial band is often identified overlying the nerve in this location and must be divided. The origins of the DPN and SPN should be visualized. The proximal and distal extents of the exposure should be probed for occult sites of compression or entrapment. Intraoperative NAPs may be performed at this point, as well as an external neurolysis. In patients with severe damage to the nerve and absent NAPs, nerve grafting may be required. The wound is irrigated and hemostasis is attained with bipolar coagulation. The subcutaneous tissues are reapproximated with interrupted absorbable suture, and the skin is closed with either absorbable or nonabsorbable monofilament in a running or mattress configuration. A soft compressive dressing is placed, and early mobilization is encouraged.

#### Surgery results

In 2004, Kim and associates published a large series of patients who underwent surgery for CPN lesions at LSUHSC.[133] Over a 32-year period, 318 knee-level CPN lesions were managed surgically, 51% of which were stretch/contusion injuries, 12% were lacerations, 9% involved entrapment, 7% were due to compression, and others included iatrogenic injuries, tumors, and gunshot wounds. Neurolysis was performed in patients with recordable NAPs across the injured segment. Of the 121 patients in whom neurolysis was performed, 107 (88%) recovered useful function. In patients in whom NAPs were absent, the injured segment was removed and grafted. Functional outcomes were better in patients who required shorter grafts; 75% of patients who had grafts smaller than 6 cm achieved grade 3 or better function as compared with 38% in the 6- to 12-cm group and 16% in the 13- to 24-cm group.

## NERVE BIOPSY

### NERVE SELECTION

a) relatively expendable **SENSORY nerves** (e.g. *sural* behind lateral malleolus, *superficial peroneal* at head of fibula, *superficial radial* at wrist, *greater auricular*)

Sural nerve (most commonly sampled nerve):

- pure sensory nerve that supplies *small area* of skin.
- often involved in clinically predominantly *motor neuropathies!*
- nerve *regeneration* occurs in > 90% cases (in weeks ÷ months).
- neurologists often choose simultaneous biopsy of both sural nerve and gastrocnemius muscle.

Complications of sural nerve biopsy:

- 1) annoying **causalgia** (5%), esp. when bending forward (stretching of nerve).
- 2) all patients should anticipate permanent **loss of discriminative sensation** in lateral border of foot (extending to 5<sup>th</sup> toe, heel, and lateral malleolus).

b) portions of peripheral **MOTOR nerve twigs** (as part of muscle biopsy).

- choose superfluous or accessory muscle (such as *gracilis* muscle).

### TISSUE TECHNIQUES, PATHOLOGIC FINDINGS

- see p. D32 >>

## SURAL NERVE BIOPSY

Used literature:

E. **Sander Connolly** “Fundamentals of operative techniques” (2002) p. 994-997

Mark S. **Greenberg** “Handbook of Neurosurgery” 7<sup>th</sup> ed. (2010) p. 214-215

### ANATOMY

- sural nerve is formed by merging of distal portion of medial sural cutaneous nerve (one of terminal branches of tibial nerve) and anastomotic ramus of common peroneal nerve.
- entirely sensory (except for some unmyelinated autonomic fibers) - cutaneous sensation to posterolateral third of leg, lateral heel and foot, and little toe.
- at ankle level it lies between Achilles tendon and lateral malleolus - this location is constant, superficial, and relatively protected from external trauma which might otherwise confuse analysis.

### INDICATION

- to assist in diagnosis of severe polyneuropathy.

- very accurate for vasculitis, amyloidosis, Hansen's disease, metachromatic and globoid leukodystrophy, neoplastic infiltration of peripheral nerve, relapsing polyneuritis
- may help distinguish two types of Charcot-Marie-Tooth syndrome.
- may show demyelination in diabetic amyotrophy.
- check if sensory nerve action potential (SNAP) is recordable for the nerve that ultimately needs biopsy – if not recordable, less chances of postop neuropathic pain.

## CONTRAINDICATION

- pure motor neuropathy.
- may not be indicated in chronic inflammatory demyelinating polyneuropathy (CIDP).

## ANESTHESIA

local ± MAC

- infiltrate local anesthetic subcutaneously just posterior to lateral malleolus and proximally, paralleling Achilles tendon for 10 cm.

## POSITION

- lateral (pillow between the legs) or prone (if muscle biopsy is also performed).
- leg to be biopsied is uppermost and is flexed 90° at knee (to relax tension on nerve)
- ankle is slightly everted.

## INCISION

- a) vertical linear 3-5 cm, midway (!) between Achilles tendon and lateral malleolus
- b) 7-10 cm incision overlying course of lesser saphenous vein, beginning just posterior to and 1 cm proximal to lateral malleolus
- c) if muscle also to be harvested, sural nerve is harvested more proximally in posterior calf so that adjacent gastrocnemius can be harvested at the same time through a single incision (mid upper calf between heads of gastrocnemius; here it may be as deep as 2 cm; gently tugging on exposed nerve in ankle may help in localization).

## DETAILS

- lesser saphenous vein can be seen through translucent Scarpa's fascia
- compressing calf distends lesser saphenous vein, which (when visible) reliably locates sural nerve; sterile Penrose drain is useful as temporary tourniquet for this purpose.
- Scarpa's fascia is incised over vein which is gently retracted to reveal nerve usually deep to vein
- sural nerve is deep (and posterior or anterior) to lesser saphenous vein.
  - N.B. common pitfall is to go too deep, nerve is fairly superficial; it is not necessary to go through thick fascia (if you see tendons to toes, you too deep)
- dissect sural nerve to beyond distal and proximal incision margins, at least 3-5 cm of the nerve.
- local anesthetic injection into nerve proximal to planned division site may decrease pain of procedure (0.5% lidocaine using 27 G needle)
- divide nerve sharply beyond incision margins (to minimize subsequent painful neuroma formation)
  - cut nerve with right-angle scissors with slight tension on it to allow ends to retract deep to skin incision to prevent formation of scar neuroma.
  - N.B. cut nerve *proximally first* so that patient experiences pain from transecting nerve only once!
- some pathologists request that proximal end of nerve be marked, e.g. with suture.
- deliver specimen directly to the neuropathologists for light and electron microscopy and immunohistochemistry (it is important to know exactly what kind of tests referring doctor wants to be performed)

*For light microscopy which suffices in most cases, immerse the nerve in formalin.*

*For electron microscopy, glutaraldehyde is used.*

*For biochemical and immunofluorescence studies, use rapid freezing*

- **differentiate sural nerve from lesser saphenous vein** (to avoid potentially embarrassing explanations and the possible need to repeat the procedure):
  - a) frozen section intraoperatively to ensure that nerve has been biopsied rather than vein
  - b) nerve has many branches at acute angles especially proximal to LM, vs. vein has right angle branches
- sometimes biopsy of **only portion of nerve's fascicles** may suffice - by opening epineurium for length of exposure and teasing out fascicle with minimal branching.

## CLOSURE

- interrupted inverted 3.0 Vicryl sutures in subcutaneous layer → 4.0 running subcuticular closure → Steri-Strips

## POSTOPERATIVE

- lightly applied Ace wrap and elevation for 24 hours to minimize ankle swelling.
- pressure dressing should be worn for protection for 2 weeks.
- patient is allowed to walk but should restrict activity for 2-3 days

## COMPLICATIONS

- **failure to make a diagnosis**: although biopsy may be able to exclude some contingencies, it often does not make a specific diagnosis!
- **poor healing** - ankle is a notorious region for poor circulation and the loss of sensation (from the disease or biopsy) may render the area subject to repeated trauma without the patient being aware
- **lateral foot sensory loss** and **chronic pain** (esp. diabetic).
  - **sensory loss** in the sural nerve distribution is expected, but often does not persist for more than several weeks (unless the underlying disease process prevents this).
  - **neuropathic pain** (incidence 25-50% after nerve biopsy) occurs for a combination of three reasons following nerve biopsy: direct trauma to the nerve related to the biopsy, deafferentation, neuroma formation.

Risk factors: vasculitis

Protective factors: nonrecordable preop SNAP (Sakamuri et al Neurosurgery 2020: OR 0.02 for a VAS increase > 20 at 6 months).

Treatment: relocating the cut end of the nerve into a deeper, protected location, away from the surface.

Prophylaxis of long-term pain (esp. in vasculitis, recordable SNAP): postbiopsy nerve repair using processed human allograft (Sakamuri et al Neurosurgery 2020: OR 0.02 for a VAS increase > 20 at 6 months, plus, protection from depression due to neuropathic pain). see below >>

## SUPERFICIAL RADIAL NERVE BIOPSY



- distal superficial radial nerve is a direct continuation of the radial nerve. It travels under the brachioradialis along the anterolateral aspect of the forearm. It pierces the deep fascia in the distal forearm and lies subcutaneously.
- nerve can usually be palpated directly over the distal radius, or in the anatomical snuff box laterally over the extensor carpi radialis longus, which aids in planning the approach.
- boundaries of the anatomical snuff box include posteriorly the extensor pollicis longus tendon, anteriorly the tendons of the extensor pollicis brevis and abductor pollicis longus and proximally the styloid process of the radius, while the floor consists of both the trapezium and scaphoid. A longitudinal incision is made over the distal radius anterior-laterally (Fig. 5) or over the anatomical snuff box. The cephalic veins lying medially usually need retraction to visualize the nerve lying superficial to the extensor retinaculum.

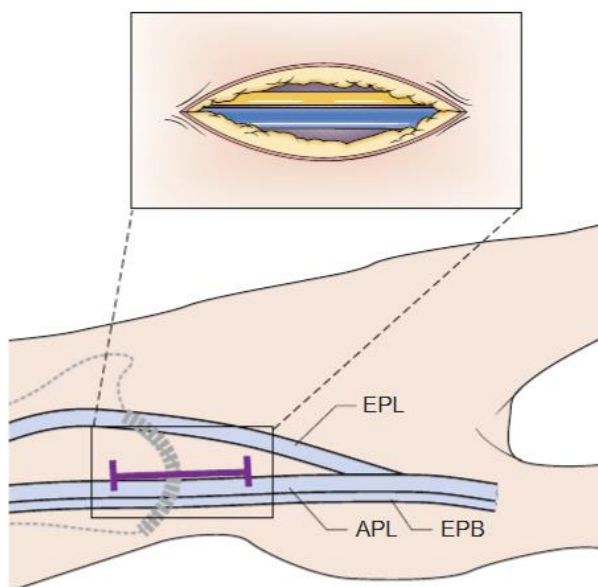
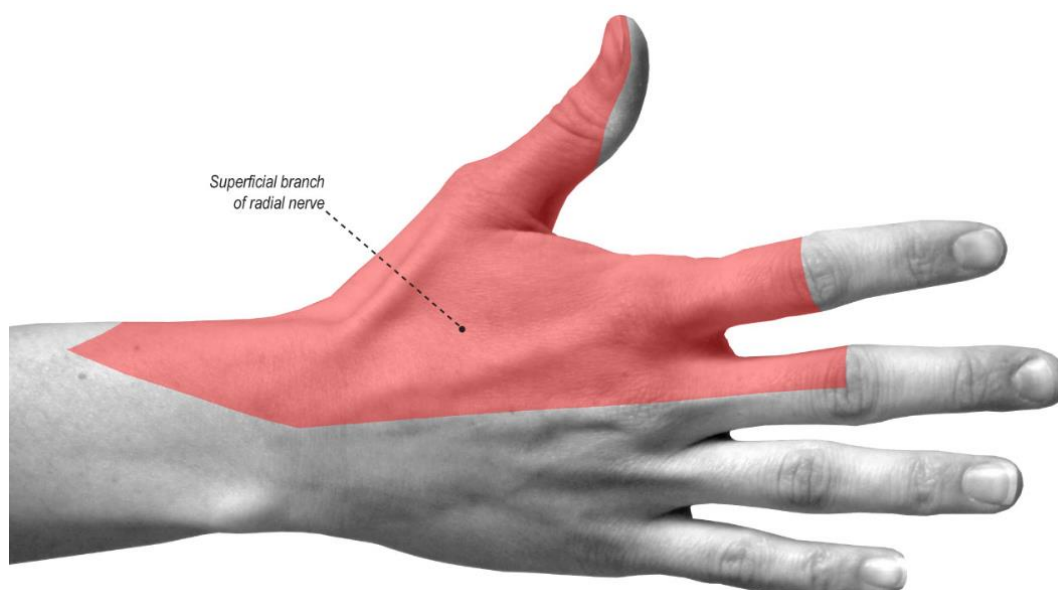


Fig. 5. Distal radial nerve biopsy technique. The nerve can usually be palpated over the distal radius as it enters the anatomical snuff box. A triangle is formed by the tendons of extensor pollicis longus (EPL) medially and abductor pollicis longus (APL) and extensor pollicis brevis (EPB) medially. The nerve lies very superficial, just deep to the skin and above the fascia, adjacent to the vein.



## ALLOGRAFT NERVE REPAIR

- coaptation between the allograft (AxoGen Avance; AxoGen Inc, Alachua, Florida) and the native nerve is performed by placing **two 8-0 nylon sutures** at each point of coaptation.
- allograft sizes: 2-3 mm by 30-50-70 mm.
- coaptation points supplemented with **fibrin sealant**.

Sural nerve biopsy with allograft nerve repair. A, The sural nerve is circumferentially isolated and separated away from the short saphenous vein. B, The allograft is then used to size the biopsy. The sural nerve is transected proximally and distally to remove the biopsy specimen. C, The allograft is then coapted proximally and distally to the cut native sural nerve.

Superficial peroneal nerve biopsy with allograft nerve repair. The superficial peroneal nerve is circumferentially isolated. D, In some circumstances, the fascia may need to be opened to have sufficient length, depending on the location of the emergence of superficial peroneal nerve from the fascial ring. E, The allograft is then used to size the biopsy. The superficial peroneal nerve is transected proximally and distally to remove the biopsy specimen. F, The allograft is then coapted proximally and distally to the cut native superficial peroneal nerve.

Superficial radial nerve biopsy with allograft nerve repair. G, The superficial radial nerve is circumferentially isolated, working between the brachioradialis and extensor carpi radialis longus. H, The allograft is then used to size the biopsy. The superficial radial nerve is transected proximally and distally to remove the biopsy specimen. I, The allograft is then coapted proximally and distally to the cut native superficial radial nerve.

