

ICP, Intracranial Hypertension

Last updated: December 19, 2020

| | |
|--|----------|
| INTRACRANIAL PRESSURE (ICP) | 1 |
| Normal ICP..... | 2 |
| ICP↑ | 2 |
| ETIOLOGY | 2 |
| PATHOPHYSIOLOGY | 2 |
| Compliance..... | 2 |
| Cerebral Blood Flow Impairment..... | 3 |
| Compartmentalization (ICP gradients)..... | 4 |
| CLINICAL FEATURES | 4 |
| Mass in posterior fossa | 5 |
| MONITORING | 5 |
| Indications for ICP monitoring..... | 5 |
| Methods of ICP monitoring..... | 6 |
| Contraindication to invasive ICP monitoring..... | 7 |
| ICP waveforms | 7 |
| OTHER DIAGNOSTIC METHODS | 10 |
| Skull X-ray | 10 |
| CT..... | 13 |
| Transcranial Doppler | 13 |
| TREATMENT | 13 |
| Reduction of intracranial blood volume | 13 |
| Brain dehydration | 14 |
| Reduction of intracranial volumes | 16 |
| Mechanical increase of cranial volume | 16 |
| Reduction of brain metabolism | 17 |
| Stabilization of cellular membranes | 18 |
| Management of blood pressure | 18 |
| Other..... | 19 |
| PROGNOSIS | 19 |

INTRACRANIAL PRESSURE (ICP)

Intracranial compartments (total intracranial volume 1500-1900 ml):

1. **Brain** (80-90%) - virtually incompressible.
2. **Blood** (4-10%)* - 70-80% are in veins.
3. **CSF** (3-12%)* - most dynamic of three compartments.

*main buffers of acutely increasing intracranial volume

- rigid skull limits total intracranial volume; craniospinal intradural space is almost nonexpandable.

Monro-Kellie doctrine (pressure-volume relationships) - in order to maintain physiological ICP, *increase in volume of one compartment must lead to compensatory decrease in volume of another compartment.*

Alexander Monro (1783 in Edinburgh) - skull is closed container and its contents are nearly incompressible.

George Kellie (1824, mentored by Alexander Monro) - blood volume within brain is constant.

Burrows (1846) - blood volume within brain could only change in reciprocal manner with CSF and brain parenchyma.

NORMAL ICP

5-15 mmHg (50-195 mmH₂O) with zero at midbrain level / foramen of Monroe. see p. D40 >>

- transient physiologic events (sneezing, coughing) can rise ICP up to 50 mmHg for a short period of time.
- normal ICP waveform *see below* >>

ICP↑

- CSF pressure > 15 mmHg (> 195 mmH₂O).

ETIOLOGY1. **Space-Occupying Lesions**

- 1) **bleeding** (intracerebral / epidural / subdural / SAH*)
- 2) **tumor** – slow growing (acute ICP problems are not common unless sudden intra-tumor hemorrhage)
- 3) **abscess**

*SAH arterial bleeding (after aneurysm rupture) causes ICP to rise instantaneously

2. **Cerebral Edema** – brain parenchyma volume↑ see S52 p.3. **Hydrocephalus** – CSF volume↑ see S60 p.4. **Venous sinus thrombosis, AVMs** - intracranial blood volume↑5. **Miscellaneous**

- 1) pseudotumor cerebri (s. idiopathic intracranial hypertension) see S56 p.
- 2) craniosynostosis
- 3) hyper- / hypo-adrenalism
- 4) altitude sickness
- 5) intoxication (tetracycline, vitamin A)
- 6) steroid-induced ICP↑;
 - vast majority of cases involve *male children*.
 - no particular dose has been implicated, but treatment duration is usually prolonged.
 - onset occurs after discontinuation, tapering, or change in type of steroid.
 - self-limited after changing type or dose of steroids (lower or higher dose).

ICP↑ - most important secondary complication of **head injury** (diffuse edema > volume of contusions, hematomas/SAH, and progressive focal edema surrounding them > hyperemia) – *causes at least 50% traumatic deaths!*

Meningitis causes both cerebral edema and blockage of CSF drainage.

PATHOPHYSIOLOGY**COMPLIANCE**

- relationship between intracranial volume↑ and associated ICP↑.

- enlarging intracranial volume is partially compensated by:
 - 1) displacement of *venous blood* into veins of chest.
 - 2) displacement of *CSF* out of skull (into spinal canal).

N.B. intracranial compensatory mechanisms can accommodate 50-100 ml (rate of volume change is very important!).

- 3) expansion of *sutures & fontanelles* in infants.
- 4) in *slow processes* (e.g. slow-growing tumors), *interstitial fluid* is expressed from brain parenchyma itself; *pressure atrophy* develops.

- when these buffering systems are **exhausted**, even small increase in volume (e.g. vasodilatation) → dramatic ICP↑↑↑

T.W. Langfitt (1966) – exponential pressure-volume relationship – ICP stays normal despite increase of intracranial volumes, however, after compensatory mechanisms reach the limit, even the smallest volume increase leads to very high ICP spike:

Spatial compensation → → Spatial decompensation

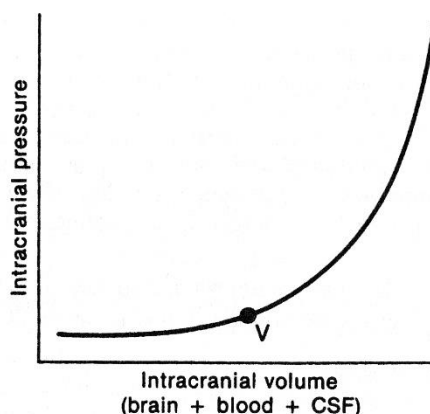
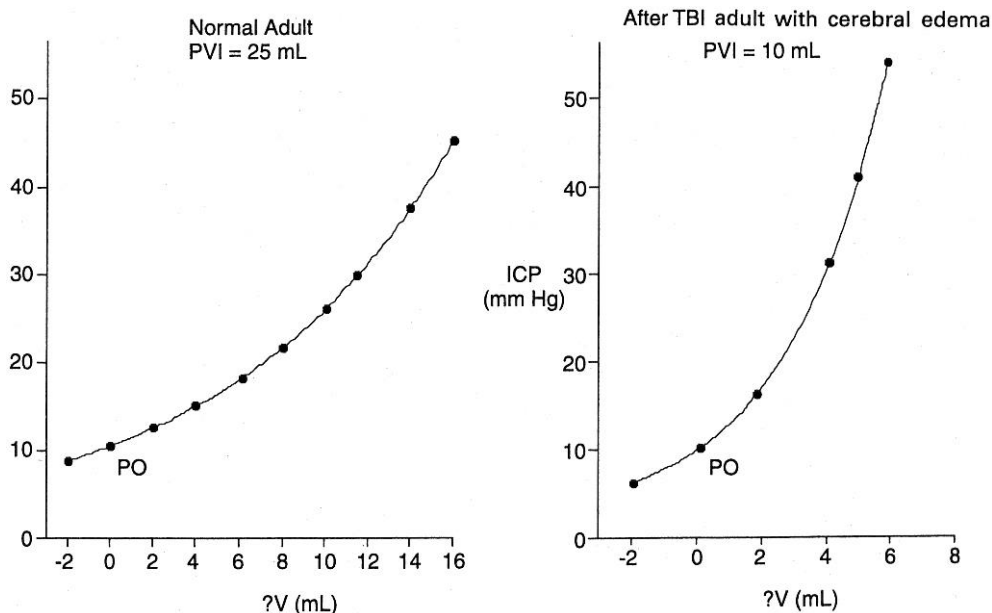


FIGURE 27-1. The pressure-volume relationship within the intracranial space can be represented by a pressure-volume curve. The ICP stays within normal limits until a critical volume (V) is reached, above which the pressure increases steeply. CSF = cerebrospinal fluid.



CEREBRAL BLOOD FLOW IMPAIRMENT

- in normal brain, *cerebral perfusion pressure (CPP)* ^{see A211 p.} must drop below 40 mmHg before cerebral blood flow is impaired; i.e. at **CPP 40 mmHg** cerebral arterioles are maximally dilated (no further mechanism to sustain blood flow);
 - in children, depending on age, normal CPP is 40-50 mmHg see p. TrH20 >>
- in damaged brain, determinate CPP is less clear (in decreased intracranial compliance, relatively small changes in volume → sudden nonlinear dangerous ICP↑).

N.B. ICP up to 40 mmHg is not harmful by itself*, but can rapidly progress to state that precipitously decreases cerebral perfusion!

*if CBF does not change, cortical physiology also does not change

In clinical practice, all patients with **ICP > 40 mmHg** have significantly diminished cerebral blood flow.

- brain arterioles maintain relatively constant blood flow over range of systemic blood pressures (**AUTOREGULATION**) ^{see p. A211 >>}; repeated ICP elevations tend to damage this autoregulation.
- when ICP↑ compromises CPP → autoregulation is lost (**vasoparalysis**):
 - CBF depends directly on systemic MAP (hypotension is extremely dangerous).
 - **massive cerebral vasodilatation** occurs → systemic pressure is transmitted to capillaries → outpouring of fluids into extravascular space → **vasogenic edema** → further ICP increase.
 - if ICP raises to the level of systemic arterial pressure → CBF ceases → ischemic brain cell death → **cytotoxic edema** → further ICP increase.

COMPARTMENTALIZATION (ICP GRADIENTS)

- pressure increase **may not be distributed evenly** throughout cranium (e.g. compartmentalized, very high pressure areas around focal mass lesions) - not accurately recorded by ICP monitoring.
- pressure compartmentalizations between dural restrictions shift brain tissue (**herniation**).

CLINICAL FEATURES

In absence of midline shift or axial brainstem distortion (i.e. impending herniation), increased ICP alone **may be asymptomatic!**

1. **Headache** – may be earliest symptom of ICP↑
 - mechanism – **direct or transmitted pressure** on cerebral arteries (particularly at base of brain), venous sinuses, dura (incl. falx and tentorium), several cranial nerves (esp. CN5 → facial sensory loss with deep facial pain).
 - N.B. injury to brain parenchyma does not generate pain!
 - onset may be insidious.
 - not necessarily severe.
 - pressure-like, dull or aching character (≈ tension-type headache > migraine).
 - localization - diffuse and generalized, bilateral frontotemporal; may be semilocalized to site of lesion (e.g. brain tumor).
 - **associated with other signs of ICP↑** (nausea-vomiting, papilledema, etc).
 - occurs intermittently, primarily in **early morning hours*** (may awaken from sleep!) or shortly after patient arises.
 - *PLATEAU WAVES (spontaneous ICP elevations) occur more commonly during sleep - ICP↑ due to hypoventilation is maximal during non-REM sleep
 - disappears minutes ÷ hours after sitting or standing.
 - N.B. headache that worsens rather than abates with recumbency is suggestive of mass lesion!
 - responds to mild analgesics (? - usually resistant to common analgesics).
 - enhanced by any activity that raises ICP (e.g. coughing, sneezing, straining, bending).
 - may be chronic progressive – becomes constant (unremitting), intensity↑ → patient seeks medical attention.
2. **Nausea & vomiting** associated with headache.
 - Early morning **projectile vomiting without nausea** (precedes appearance of headache by weeks) is especially suggestive – due to direct pressure on vomiting centers in brainstem.

3. **Papilledema** - most reliable sign of ICP \uparrow (good specificity; sensitivity observer dependent) see Eye62 p.!!!
 - possible **other ocular symptoms** - visual obscurations, visual loss (typically - **blind spot enlargement, visual field constriction**), diplopia (**CN6 palsy** due to stretching – see Eye64 p.!), photopsias, paralysis of upward gaze, pain on eye movement.
4. **Change in mental status** - psychomotor retardation, lethargy and increased sleep \rightarrow stupor \rightarrow coma \rightarrow death.
5. **Tense fontanelle** in infants (\rightarrow head size \uparrow); "**cracked-pot sound**" or **MACEWEN sign** (skull percussion produces resonant sound) due to separation of cranial sutures.
6. **CUSHING reflex** (= acute life-threatening ICP $\uparrow\uparrow\uparrow$ \rightarrow **medullary hypoxia**):
 - 1) **hypertension** (esp. systolic \uparrow $>$ 15 mmHg and/or widening pulse pressure) – compensatory attempt to restore brainstem perfusion.
N.B. antihypertensive therapy \rightarrow critical cerebral ischemia!
 - 2) **bradycardia** (esp. pulse $<$ 60/min or drop $>$ 10/min) – reflex response to systemic hypertension.
 - 3) **respiratory irregularity** (tachypnea $>$ 20/min, hyperpnea, Cheyne-Stokes respiration).
 - full triad is seen in only 1/3 cases.

Cushing ulcer (s. Rokitansky–Cushing syndrome) - gastric ulcer associated with elevated ICP; ulcers may also develop in the proximal duodenum and distal esophagus.

MASS IN POSTERIOR FOSSA

- 1) headache, nausea, vomiting, agitation \rightarrow * altered mental status
*may progress very fast – check patient frequently!!!
- 2) **nuchal rigidity**
- 3) cerebellar signs (rare)
- 4) lower cranial nerve palsies (rare)
- 5) obstructive hydrocephalus
- 6) **brain stem compression** (loss of consciousness, decerebrate rigidity, death).

MONITORING

CT for all patients!

- if there is abrupt ICP increase after pressure had previously been well controlled, CT is repeated immediately (look for enlarging hematoma, etc).

Lumbar puncture *should not be performed prior to CT!*

- opening pressure at time of LP is not appropriate for long-term ICP monitoring.

Continuously monitor – **ECG, pulse oximetry, BP (arterial line), central venous pressure.**

INDICATIONS for ICP monitoring

ICP data supplements / substitutes neurological examination when:

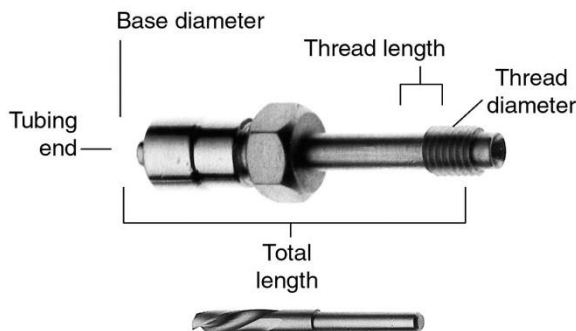
- a) examination is affected by *sedatives, paralytics*, or other factors.
- b) patient goes to *operating room* - frequent neurological examinations is not possible in this setting; often ICP monitor is left in place longer if patient will be going to OR (e.g. for ortho).

1. Severe **TBI** – most common indication! for details – see p. TrH1 >>
2. Large intracranial **hemorrhages** (esp. SAH) or **strokes** (?)
3. **Encephalitis** or bacterial **meningitis**
4. Fulminant **hepatic encephalopathy**, **Reye's syndrome**
5. **Normal pressure hydrocephalus** (historical indication) – if transient ICP elevations (\approx plateau waves) occur during REM sleep, patients could improve with shunting.

METHODS of ICP monitoring

- A) **VENTRICULOSTOMY (EVD)** – gold standard – catheter in *lateral ventricle*. see p. Op6 >>
- **most accurate method + permits CSF drainage!!!** (as potential treatment for raised ICP).
 - causes of **inaccurate information**: catheter occlusion (blood or necrotic brain), ventricle collapse around catheter tip
 - disadvantage - dėl potrauminės smegenų edemos skilveliai:
 - 1) dislokuojasi
 - 2) greitai suspaudžiami ir sunkiai vizualizuojasi CT
 N.B. jei 2-3 bandymų metu nepatekta į skilvelį, reikėtų rinktis kitą metodą
 - guidance:
 - a) stereotactic
 - b) by skull-based landmarks
 - puncture (usually on *nondominant side*): see p. Op6 >>
 - a) **frontal horn**.
 - b) **occipital horn**.
 - complications:
 - 1) brain **parenchyma damage**.
 - 2) **hematomas** (subdural, epidural, intracerebral s. “ventriculoma”) (< 2%).
 - 3) **ventriculitis** (5-10% after 5 days);
 - prophylaxis* – water-tight closure around device, tunneling catheter underneath the scalp, prophylactic antibiotics (questionable), catheter replacement q5-7 days (questionable).
 - treatment* – antibiotic into ventricle → catheter removal (if ventriculostomy is still indicated – puncture another site).
 - 4) **upward herniation** (if infratentorial mass is present and CSF is quickly removed from supratentorial lateral ventricles – drain EVD at ≥ 15 cm H₂O).
 - N.B. prepare patient for *emergent posterior fossa decompression* just before performing ventriculostomy!
- B) **SUBARACHNOID BOLT** (e.g. Richmond screw, Philly bolt) - hollow screw inserted through skull into *subarachnoid space*; tubing filled with sterile saline is attached to bolt and pressure monitor.
- directly measures pressure within subarachnoid space.
 - advantage - risk of hemorrhage and ventriculitis is lower (compared with ventriculostomy).
 - disadvantages:
 - A) *underestimate* pressure by > 10 mmHg in 25-40% patients.
 - B) *screw obstruction* by fragment of dura or gyrus (pulsatile recording becomes flattened).
 - C) CSF leaks, meningitis.
 - D) CSF cannot be evacuated.
 - modifications - measure pressure within *subdural or epidural space*.

Richmond screw:



C) **INTRAPARENCHYMAL DEVICE** – very accurate!; infection rate < 1%

- disadvantages: prone to regional inaccuracy, **silent zero drift + cannot be recalibrated externally**.
- devices and methods:
 1. **Codman microsensor** (Johnson and Johnson Professional, Inc.), **Neurovent-P** (Raumedic AG) – have **piezoresistive sensor** – pressure exerted on side-mounted diaphragm at the tip of the device changes its **electrical resistance**.
 2. **Camino fiberoptic device** (Camino Laboratories) – senses changes in **amount of light reflected** from a pressure-sensitive diaphragm at the tip of a **fiberoptic catheter** – very high and unpredictable **zero drift!**
 3. **Spiegelberg** (Aesculap, Inc.) - measures pressure in a **small balloon inserted intracranially**, containing 0.1 ml of air - the only sensor capable of self-recalibration after implantation!!!

D) **EXPERIMENTAL METHODS** - measurement of jugular venous gases* and glucose and lactate (to evaluate oxygenation and nutrition of brain), brain temperature and oxygen probes, brain microdialysis.

*as ICP rises, arteriovenous oxygen difference (AVD_{O₂}) increases due to greater oxygen extraction

Devices are zeroed at level of **foramen of Monro** or **midbrain** (*external acoustic meatus* is anatomic landmark).

Maneuvers to test function of ICP monitor

- a) **Valsalva maneuver**: **increase intrathoracic pressure** → ICP increase.
- b) **Queckenstedt test**: **jugular veins lightly compressed** → ICP increase.

N.B. neither of these tests should be performed in **critically elevated ICP**.

CONTRAINDICATION to invasive ICP monitoring

- **coagulation disturbances**.

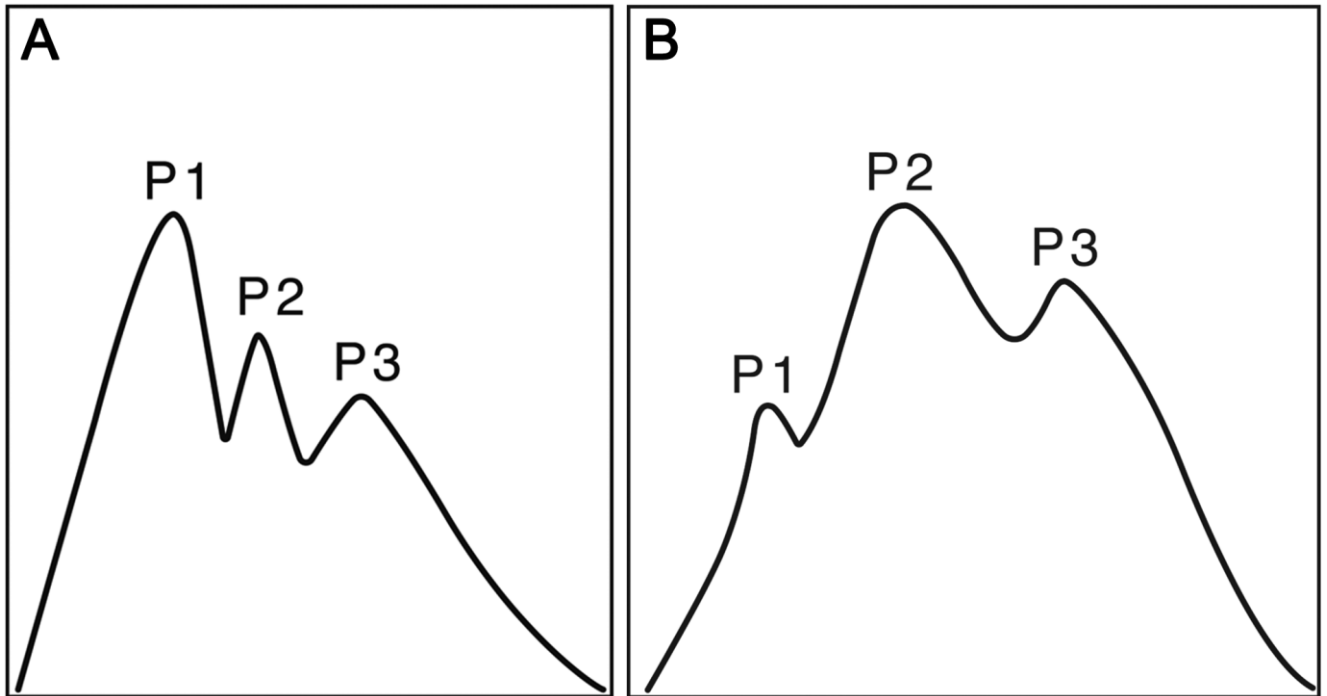
- multiple contusions detected by first CT scan = **trauma-related coagulopathy** that will correct itself within few hours.

ICP waveforms

ICP is dynamic!

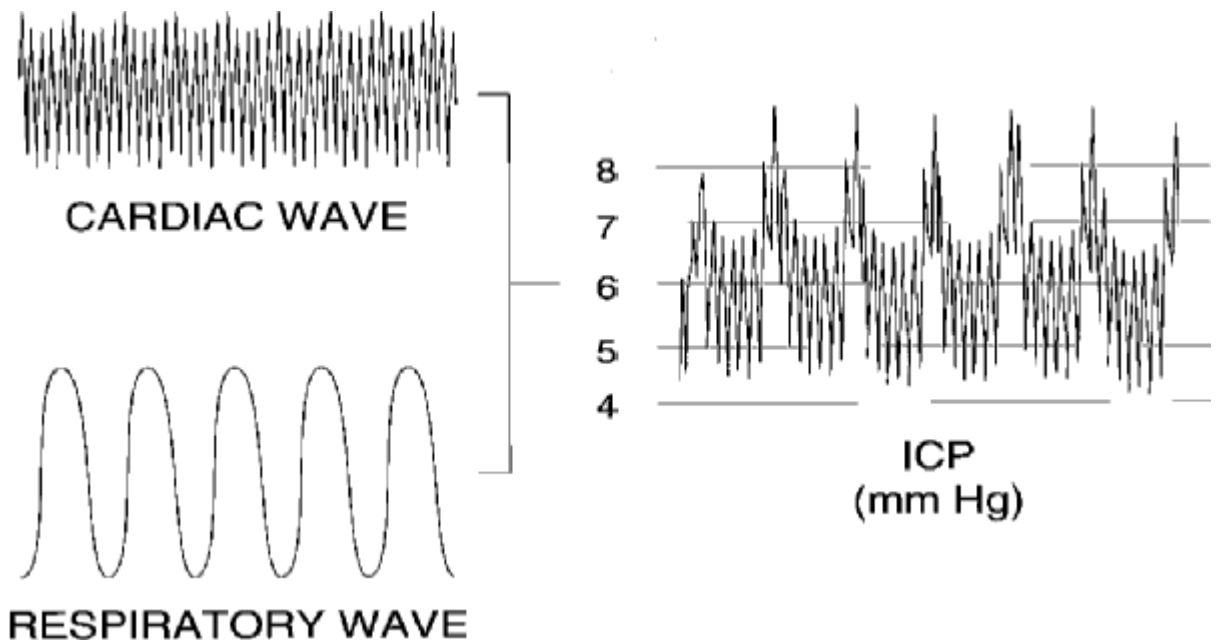
- A. Standard ICP pulse waveform in an individual with normal intracranial compliance; peak 1 (P1; percussion wave) is greater than peak 2 (P2; tidal wave) which is also greater than peak 3 (P3; dirotic wave).

B. Impaired intracranial compliance results in a modified ICP pulse waveform with P2 having the greatest amplitude.

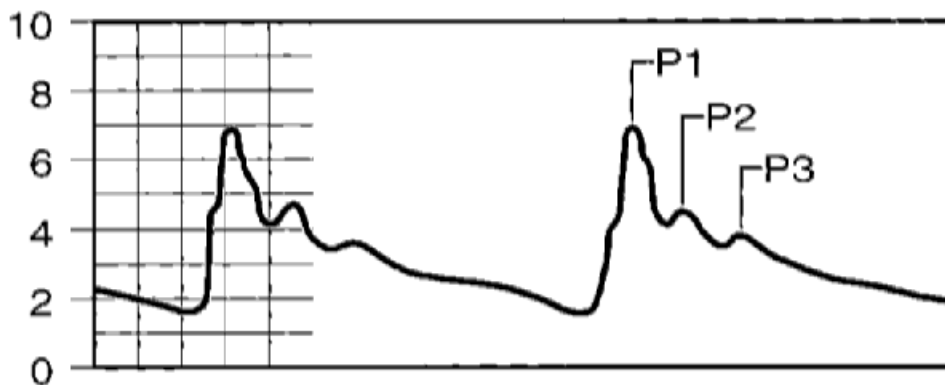


1. **NORMAL WAVES** – three major components:

- 1) **baseline** pressure level
- 2) **cardiac** pulsatile component (responsible vessels unknown; veins?, choroid plexus and pial arteries?)
- 3) **pulmonary** pulsatile component (may change considerably during mechanical ventilation)



- pulsatile components are positive deflections of **2-10 mmH₂O** - ICP variation with respirations and cardiac cycle.
- at rapid chart speed, normal ICP waveform is *triphasic*:
 - normally, first peak (W1) is largest and second (W2) and third (W3) peaks are progressively smaller:



P1 (percussion wave) – derives from pulsations of large intracranial arteries.

P2 (tidal wave) – derives from cerebral elastance.

P3 (dicrotic wave) – corresponds to dicrotic notch in normal arterial pulse waveform.

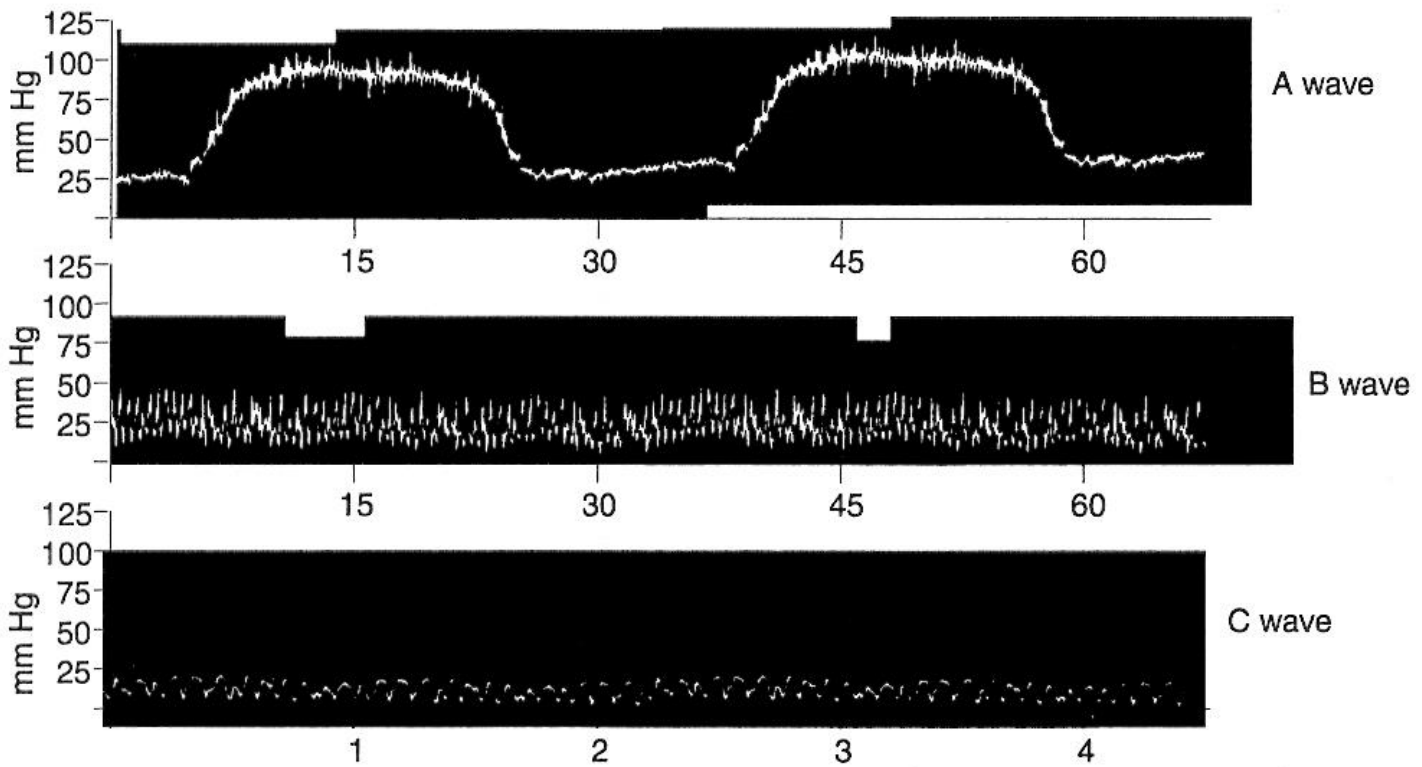
- when ICP is elevated, second and third peaks become progressively larger (increased conductance of pressure waves through “tightening” brain) + pathologic waves appear

2. PATHOLOGIC WAVES:

- LUNDBERG A WAVES (s. PLATEAU WAVES)** - acute ICP elevations 600-1300 mmH₂O (> 50 mmHg) over baseline ICP; last 5-20 minutes and then spontaneously return to baseline level that is slightly higher than when waves began.
 - *poor prognosis!* (ICPs > 30 mmHg are rarely associated with intact survival).
 - represent autoregulatory response to insufficient cerebral blood flow (secondary to elevated ICP or systemic hypotension) that produces vasodilatation → increased cerebral blood flow → further ICP elevations.

N.B. mechanism – *vasodilation*; proposed treatment – vasopressors (but they actually may worsen lesion and edema formation).
 - may be precipitated by iatrogenic maneuvers (suctioning, physical therapy, excess fluid administration, pain).
 - may lead to herniation.
- LUNDBERG B WAVES** - 10-20 mmHg 0.5-2/min waves above baseline ICP; duration < 2 minutes; not as deleterious as A waves; occur secondary to *intracranial vasomotor waves* (causing ICP fluctuations) – may be related to PaCO₂ fluctuations (however, B waves also occur in ventilated patients that have constant PaCO₂).
- LUNDBERG C WAVES** - **low-amplitude most rapid sinusoidal waves** (approx. 6/min) that may be superimposed on other waves; correspond to Hering-Traube-Mayer fluctuations in arterial pressure.
 - may be related to increased ICP; but also can occur in setting of normal ICP and compliance.

Intracranial Pressure Waves

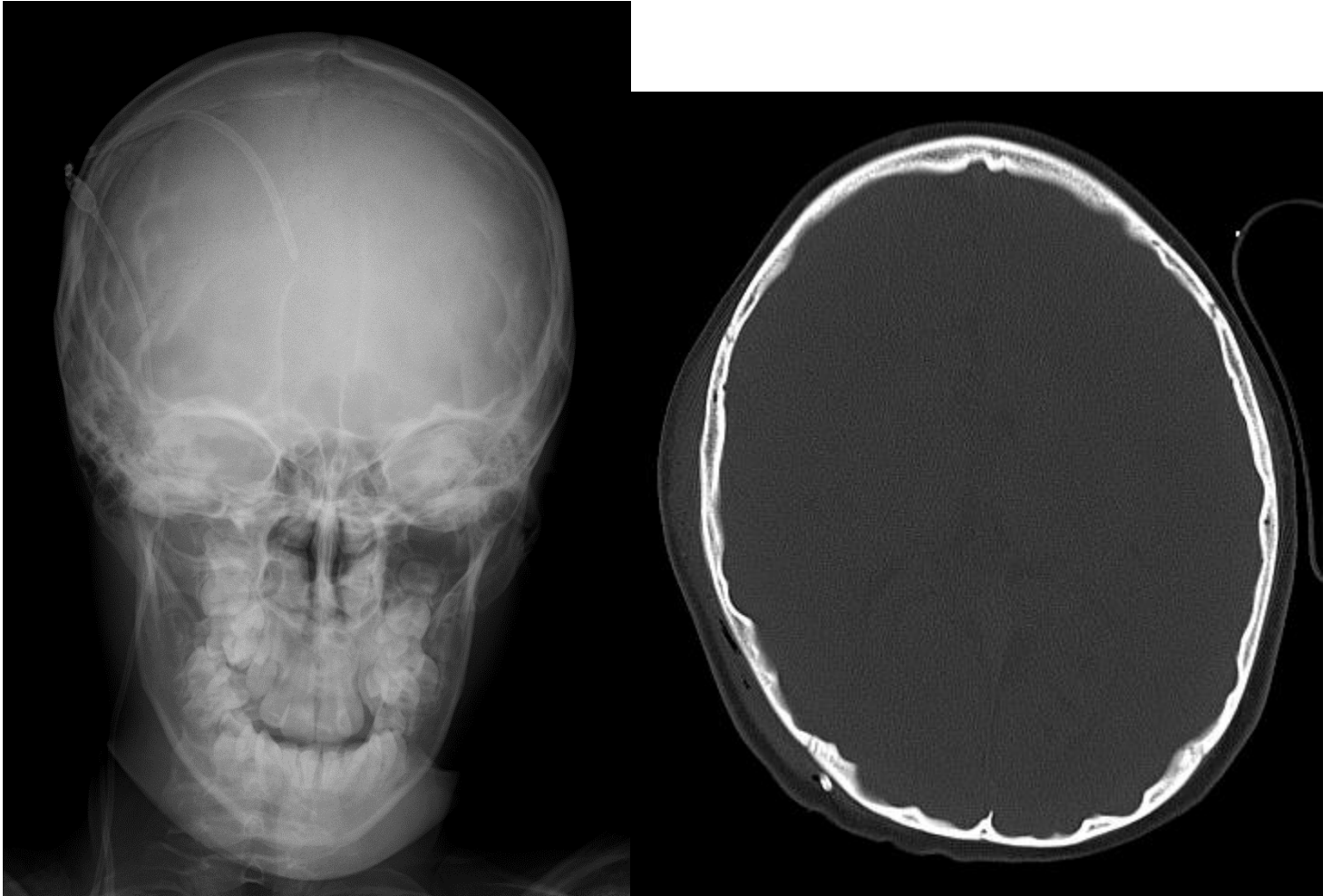


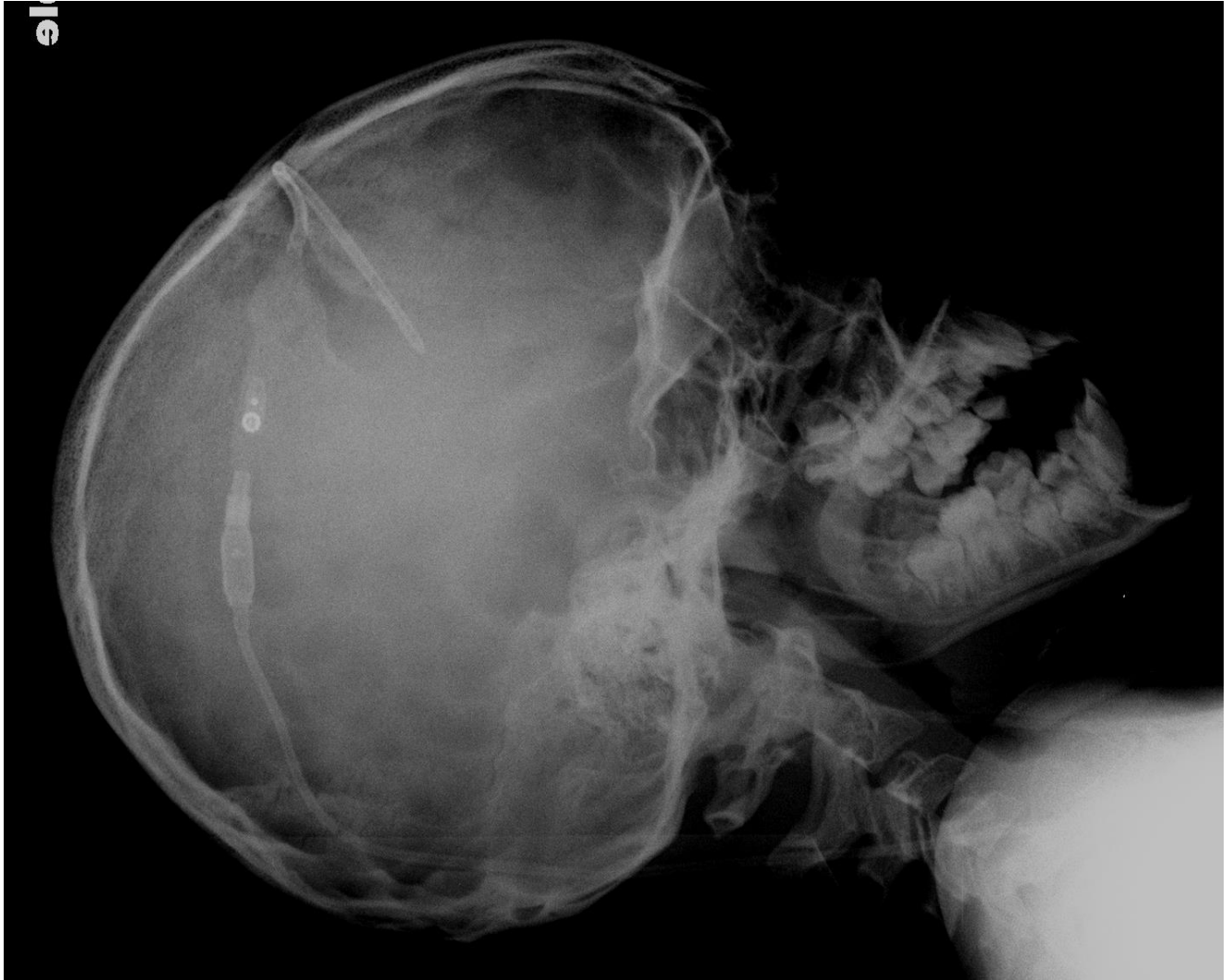OTHER DIAGNOSTIC METHODS

SKULL X-RAY

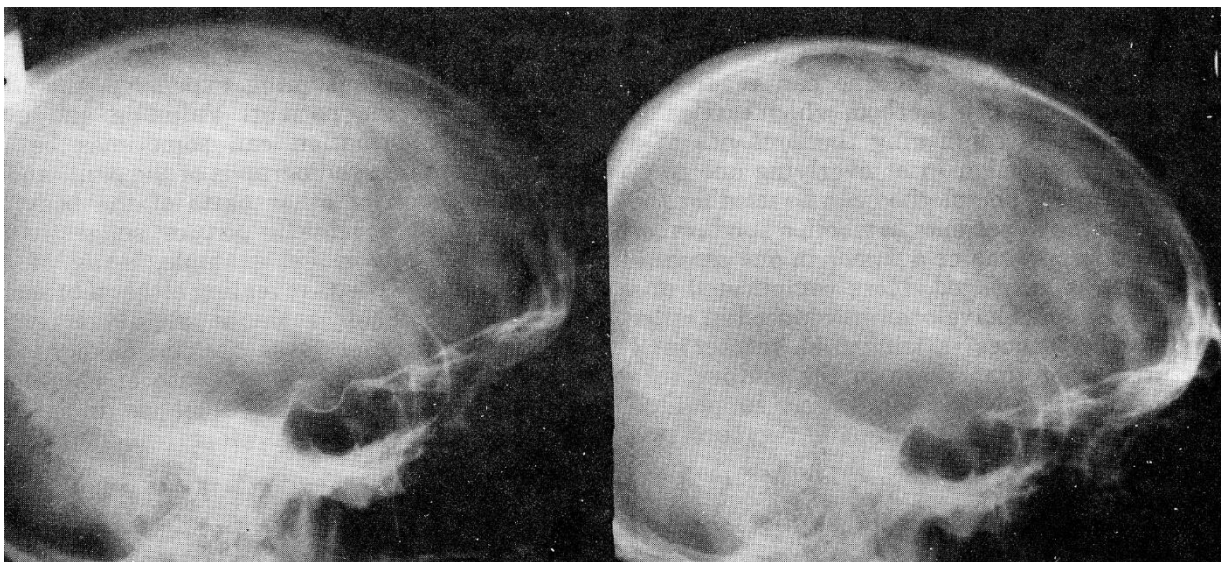
- earliest change is *erosion of lamina dura of dorsum sellae* (in children - *separation of sutures*).
 - direct pressure on sella by anterior end of enlarged 3rd ventricle in chronic hydrocephalus may give rise to '**J-shaped**' sella.
- chronic longstanding ICP↑:
 - 1) *split sutures* (when ICP has been raised since childhood).
 - 2) *increase in convolitional markings* ("**beaten-silver appearance**" - irregular, shallow scalloping of inner bone table).
- when increased ICP is relieved, cranial vault often thickens and sella turcica reossifies and may remodel.

"Beaten-silver appearance":





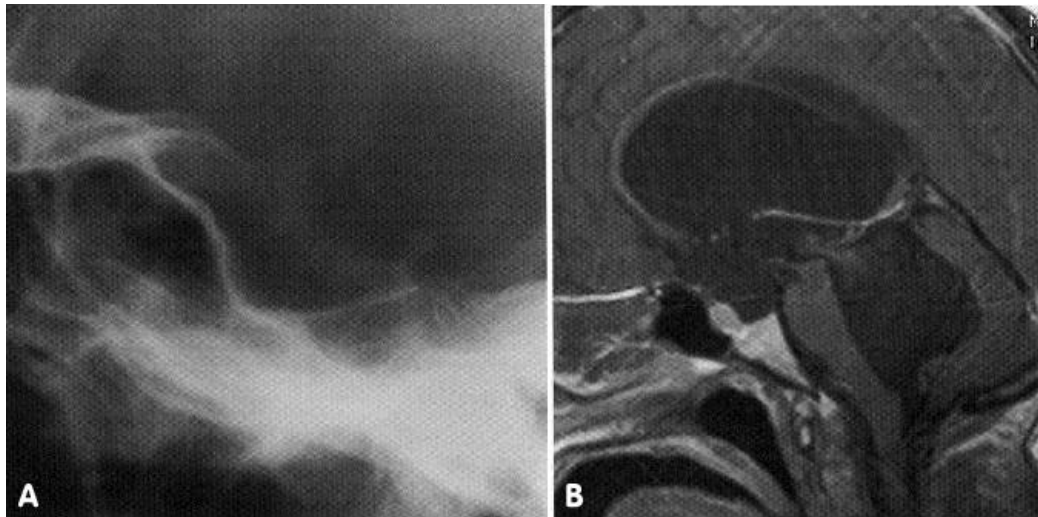
Source of pictures: Viktoras Palys, MD >>



Left, A normal lateral radiograph of the skull. Right, A radiograph taken one year later of the same patient showing loss of the lamina dura of the dorsum sellae due to increased intracranial pressure.

'J-shaped' sella in elderly patient with longstanding communicating hydrocephalus.

- A. (lateral plain radiograph of pituitary fossa) - truncated dorsum, large anterior clinoid processes and deep sulcus chiasmaticus causing pituitary fossa to appear enlarged.
- B. (T1-MRI of same patient) - dilated lateral, 3rd and 4th ventricles with patent foramen of Monro, aqueduct of Sylvius and foramen of Magendie.



CT

- 1) compression or absence of the basal cisterns
- 2) obliteration of the third ventricle
- 3) presence of small ventricles (may be normal in pediatric patient) or signs of hydrocephalus

TRANSCRANIAL DOPPLER

Intrakranijinės hipertenzijos atveju pulsatiliškumo (**Gosling**) indeksas (santykis skirtumo tarp sistolinio ir diastolinio LKG su vidutiniu LKG) viršija vienetą.

LKG - linijinis kraujotakos greitis

TREATMENT

- maintaining **cerebral perfusion pressure (CPP) > 60-70 mmHg**.

Most centers begin treatment with sustained **ICP > 20 mmHg**

- bringing ICP < 15-20 mmHg affords *margin of safety* (should transient increases in ICP occur).
- management of increased ICP is indication for care in NEUROINTENSIVE CARE UNIT.
- **LIDOCAINE** 1% 1-1.5 mg/kg IV may be used to blunt ICP elevation during airway manipulation (e.g. suctioning, endotracheal intubation).

Increased ventricles → place EVD
 Brain edema → osmotherapy
 Hyperemia → augment BP (leads to vasoconstriction)

REDUCTION OF INTRACRANIAL BLOOD VOLUME

1. **Increasing venous outflow** by **PATIENT POSITION** - elevate head of bed up to 30° (intracranial venous blood↓; CPP and CBF are not altered if head of bed is elevated < 60°)
 - avoid jugular vein compression - keep head in **neutral midline position**, check for collar-endotracheal tube ties.
 - N.B. any change in venous pressure promptly causes similar change in ICP!
 - contraindications to head elevation: hypotension, unstable spine injury.
 - N.B. remove **C-collars** as soon as feasible (C-collars cause ↑ICP)

2. **Induction of vasoconstriction** with **HYPERVENTILATION** (10-16/min) - to achieve mild **hypocarbica** (PaCO₂ 30-35 mmHg) and **avoid hypoxemia** (PaO₂ 80-100 mmHg).

PaCO₂ is most potent regulator of cerebral vessel size! PaO₂ is also important!

Between 20 mmHg and 80 mmHg, CBF is linearly responsive to PaCO₂

In adults, 1-mmHg change in PaCO₂ is associated with 3% change in CBF

PaCO₂ ↓ to 20-25 mmHg reduces CBF by 40-45% → adult cerebral blood volume reduces from 50 mL to 35 mL (only 15 mL intracranial volume decrease may have tremendous beneficial effect!)

- used ***only as temporizing measure in acute situations*** (e.g. herniating head trauma on the way to OR) and during neurosurgical procedures (e.g. craniotomy for brain tumor).
Fortunately, even if pressure autoregulation is frequently lost in TBI, CO₂ vasoreactivity remains!
- **advantages** – immediate onset (within 30 sec, peak at 8 min), well tolerated.
- **disadvantages:**
 - 1) effect duration ≈ **30 minutes ÷ 72 hours** (brain resets* to reduced level of PaCO₂ + body quickly compensates for induced respiratory alkalosis by producing metabolic acidosis), i.e. limited value beyond acute phase.
*when hyperventilation is discontinued, PaCO₂ should be tapered over 24-48 hours (to avoid rebound vasodilatation)!
 - 2) mechanical ventilation and PEEP can **increase intrathoracic pressure** → ICP↑.
Although effect of PEEP on ICP is complex, PEEP should not be withheld if necessary for oxygenation!
 - 3) over time injured vessels may lose responsiveness to hypocarbica and become vasodilated → **blood shunting to injured area** with disrupted BBB (“reverse steal”) → increased vasogenic edema.
- **complications:**
 - 1) hypotension
 - 2) barotrauma
 - 3) overventilation (PaCO₂ < 20-25 mmHg) → significant vasoconstriction → **cerebral ischemia** (especially hazardous after few hours after brain trauma when cerebral blood flow is already diminished to almost ischemic levels)

N.B. **prophylactic hyperventilation** (e.g. in head-injured patients with no signs of ICP↑) is associated with worsened neurologic outcome!

BRAIN DEHYDRATION

A. **OSMOTIC AGENT:**

- 1) 15-20% **MANNITOL** (Osmitol®, Resectisol®) 1.0 (0.25-2.0) g/kg IV bolus over 15-30 minutes* q3-6 h (practically, patient is given one bag of 20% 500 mL = 100 g of MANNITOL); renal losses must be replaced with isotonic saline.

***if IV drip** → MANNITOL accumulation in brain (esp. injured areas with damaged BBB) → reverse osmotic effect; if **more rapid bolus** → transient CBF increase (→ ICP↑)

N.B. the risk of acute tubular necrosis and renal failure has been suggested with mannitol administration with **serum osmolarity > 320 mOsm** in adults (however, the literature supporting this finding is limited in scope and was generated at a time when dehydration therapy was common).

Mannitol vs. NaCl in TBI – see p. TrH1 >>

- 2) 23.4% **NaCl** 30 mL infuse via **central line** over 15-30 minutes; risk of *hyperchloremic acidosis* (monitor Na, Cl, pH q4hrs)
 - like mannitol, the penetration of Na across BBB is low.
 - mannitol eventually causes hypotension vs. 23.4% NaCl causes increase of intravascular volume.
 - hypertonic saline may be hazardous for a hyponatremic patient (too rapid rise in [Na] may cause central pontine myelinolysis).
 - much higher levels of serum osmolality (approx. **360 mOsm**) may be tolerated in children when induced with hypertonic saline vs. mannitol.
 - 3) **SODIUM LACTATE**; small Class 3 RCT reported that ICP was significantly lower for patients who received sodium lactate than mannitol (Ichai, 2009).
 - 4) historical alternatives: **UREA** 30% IV, **GLYCEROL** 10% orally / nasogastric tube.
- mechanisms of action:
 - 1) **hypertonicity and osmotic diuresis** by drawing edema fluid from cerebral parenchyma (**brain dehydration**); effect starts after 15-30 minutes (intact BBB is needed) and lasts 6 hours.
 - 2) immediate plasma expansion* → immediate **blood viscosity**↓ (**rheological effect** – **most important mechanism of action!!!**; effect lasts < 75 minutes) → improved blood flow (esp. microcirculation) → intracranial vasoconstriction (intact autoregulation attempts to maintain constant CBF) → decrease ICP.
*also transient CBF and CBV↑
 - 3) MANNITOL is also considered **free radical scavenger**.
Mechanistic studies suggest that, based on rheological effect, **bolus administration and replacing urinary losses** are best practice!
 - advantages: titratable, predictable, rapid onset:
 - plasma expansion effect within 5 minutes.
MANNITOL may be lifesaving in impending herniation!
 - osmotic effect peaks at 20-30 minutes, peak is maintained for 180 minutes.
For elective craniotomies mannitol should be given at time of scalp incision!
 - disadvantages
 - effect duration ≈ **up to 5 days** (MANNITOL is usually given for 24-48 hours to “buy time” in acute setting); no data and guidelines exist for repeated administration to treat ICPs.
 - small amounts of MANNITOL cross BBB → **"rebound"** after stopping use (i.e. return of water intracerebrally); this is even bigger problem with smaller molecules – UREA, GLYCEROL.
 - by reducing brain volume, **tamponade of extra-axial hematoma may be lost** → rebleeding.
 - may induce **pseudoagglutination if given simultaneously with blood** (H: add at least 20 mEq NaCl to each liter of MANNITOL solution).
 - contraindications:
 - 1) **serum osmolality > 320 mOsm** (→ renal tubular failure), **serum Na > 155 mmol/L**; urine output is replaced milliliter per milliliter with isotonic saline solution.
Electrolytes and serum osmolality must be monitored q6h - keep serum osmolality ≈ 310 mOsm.
Clinically significant deleterious effects are generally seen at levels > 325 mOsm/kg
 - 2) **hypotension, dehydration** – too low CPP!!! (at least start concomitant saline IVI).

Foley catheter (for diuresis registration) is essential!

- 3) **renal failure** (initially assess renal function by *test dose* of 200 mg/kg IV over 3-5 min - should produce *urine flow* of $\geq 30-50$ mL/h over 2-3 h; same test in children should produce urine flow of ≥ 1 mL/kg/h over 1-3 h).
 - 4) severe **pulmonary congestion** or frank **pulmonary edema, progressive heart failure** (sudden increase in extracellular fluid may lead to fulminating CHF).
 - 5) **active intracranial bleeding** (?); MANNITOL increases bleeding during surgery for the first 15-30 minutes (rheological effect?)
- **complications** – MANNITOL causes significant diuresis (excretion of water > sodium): **dehydration** (H: provide sufficient hydration to maintain euvoemia), **hyponatremia** (by dilution with migrating intracellular water) then **hypernatremia, hypokalemia**.
- B. **DIURETICS** (e.g. **FUROSEMIDE** 20-80 mg or 1 mg/kg IV \times 3-6/d; max 600 mg/d; **ETHACRYNIC ACID**) – historically used as a supplement to MANNITOL (FUROSEMIDE administered 15 minutes after MANNITOL); onset of action is slower (than of MANNITOL).

REDUCTION OF INTRACRANIAL VOLUMES

1) **CSF**:

a. **mechanical drainage (CSF diversion)**:

- a) **temporary external drainage – VENTRICULOSTOMY (EVD)** (often first and most direct route of ICP control). see p. Op6 >>

N.B. in *TBI* cases, in *posterior fossa mass* cases – initial EVD setting is 20 mmHg!!!

- b) **temporary internal drainage - VENTRICULOSUBGALEAL SHUNT** - placement of ventricular catheter attached to reservoir (with or without valve mechanism) with short side arm opening into subgaleal space, which is dissected at time of surgery – provides decompression for several weeks to months without need for percutaneous aspiration of reservoir.
- c) **permanent internal drainage** - third ventriculostomy, ventriculoperitoneal or pleural or atrial shunt.

- b. **production**↓: **ACETAZOLAMIDE** (CSF production can be reduced by 16-66%; has vasodilator effect that may transiently worsen ICP - so its use is contraindicated in TBI), **FUROSEMIDE** (synergy with acetazolamide).

2) **REMOVE INTRACRANIAL MASSES** (e.g. infant hematoma aspiration).

Any intracranial mass lesion with ICP > 30 mmHg should be removed!!!

3) **BRAIN EXCISION** (e.g. contused temporal lobe).

MECHANICAL INCREASE OF CRANIAL VOLUME

by **DECOMPRESSIVE CRANIECTOMY (bifrontal, bihemispheric, hemi, bicompartamental)** (timing is critical!) - removal of bone flap with dural opening;

- **most common indications**: malignant MCA stroke (see p. Vas5 >>), severe TBI.
- may be preceded by emergency **SUBTEMPORAL BURR HOLES** (e.g. blind emergency trephination in ED).
- **advantages** – large sustained ICP reduction; children benefit more than adults!
- **disadvantages** – surgical risks; some studies indicate that DC is associated with greater risk for unfavorable outcome* at 6 months for patients with diffuse TBI.
*DC enhances formation of edema (residual brain injury may be severe)
- **complications** – tissue herniation through wound (H: opening must be large enough so that brain does not strangulate its blood supply) → white matter stretching.

- bone flap is removed (may be placed in subcutaneous pocket in RLQ of abdomen) or is left on dura without fixation (not recommended); further about surgical techniques – see p. Op320 >>

REDUCTION OF BRAIN METABOLISM

→ **neuroprotection**; blood flow demand↓ → **vasoconstriction**;

1. **SEDATION** (e.g. **PROPOFOL**, **ETOMIDATE***) *decreases ICP
N.B. *high dose propofol* may cause hyperkalemia, metabolic acidosis, myocardial failure, rhabdomyolysis, and death!
2. **NORMOTHERMIA**
 - aggressively reduce fever! (ACETAMINOPHEN is best!; then cooling blanket)
 - role in TBI: although hypothermia is effective in decreasing elevated ICP in TBI, robust clinical trials have shown a trend toward worse outcomes with hypothermia!!!! - hypothermia should be used as a last resort in severe TBI!!! see p. TrH1 >>
 - reducing temperature from 37 to 27 C → cerebral metabolic rate↓ of oxygen consumption by 64%.
Croughwell N, et al. The effect of temperature on cerebral metabolism and blood flow in adults during cardiopulmonary bypass. J Thorac Cardiovasc Surg. 1992.
3. **Anticonvulsants**
4. **Neuromuscular PARALYSIS** (e.g. to prevent ICP increase during intubation and ventilation)

PROTOCOL (indication: requires mannitol < q12hrs): start with sedation **MORPHINE** IVI + **PROPOFOL** → paralytic (e.g. **VECURONIUM** or **CISATRACURIUM** IVI – titrate to 1-2 TOF) → moderate therapeutic **hypothermia** (up to 32-34°C).

Rewarming – by 0.5°/day

5. **BARBITURATES** (**PENTOBARBITAL** 3-15 mg/kg IV load over 30 minutes → 0.5-5 mg/kg/h titrate as needed to achieve:
 - a) 10-20 seconds of burst suppression [3-6 bursts/min] continuously monitored by bedside EEG - **PENTOBARBITAL COMA**
 - b) serum concentration of 3.5-4.5 mg/dL
 - **ETOMIDATE** is effective (predicts response to pentobarbital)
 - PHENOBARBITAL and NA THIOPENTAL are less effective in reducing ICP.
 - reserved for **refractory ICP unresponsive to other measures!** in TBI – see p. TrH1 >>
 - typically, barbiturate infusion is continued for 2-5 days → patient is weaned off barbiturates; if ICP again escapes control → reload with PENTOBARBITAL and wean again in several days.
 - mechanism of action:
 - 1) eliminated BP and respiratory fluctuations
 - 2) preventing unnecessary movement, coughing, and straining against tubes
 - 3) alteration of cerebral vascular tone.
 - 4) suppression of metabolism and oxygen consumption - neuroprotection
 - 5) scavenge free radicals
 - effect duration ≈ *days*.
 - disadvantages:
 - 1) fixed small pupils.

- 2) cardiac depression and vasogenic hypotension (parallel reduction in ICP and BP without net improvement in CPP*). H: volume + DOPAMINE (keep systolic BP > 100 mmHg).
- 3) increased intrapulmonary shunting → hypoxia

N.B. PENTOBARBITAL COMA is common indication for Swan-Ganz catheter.

*PENTOBARBITAL COMA has no beneficial effect on overall outcome in TBI see p. TrH1 >>

STABILIZATION OF CELLULAR MEMBRANES

with **STEROIDS** - for **vasogenic edema** (e.g. brain tumors or abscesses). see p. S52 >>

N.B. steroids are not recommended in **strokes** (ischemic, hemorrhagic)*, **TBI**, **SAH!**

*direct glucocorticoid toxicity + elevated serum glucose exacerbates ischemic lactic acidosis

MANAGEMENT OF BLOOD PRESSURE

(maintain systolic BP 100-160 mmHg, mean arterial BP 100 ± 10 mmHg, CVP 5-15 cmH₂O, PCWP 10-14 mmHg)

Keep **normovolemia – normotension!**

- intravascular volume is maintained with balanced **salt solutions, colloids, blood**.
 - safest fluid is **normal saline** (slightly hyperosmolar to most patients);
 - avoid **hypotonic solutions** – worsen cerebral edema!
 - avoid **dextrose** (hyperglycemia exacerbates ischemic brain injury) and **free water intake**.
 - controversy exists whether **colloids** (molecular weight > 8000) are more beneficial than **crystalloids** for fluid resuscitation.
 - Some authors have found no difference;
 - Tranmer and associates showed definite advantage using Hetastarch; in laboratory model of vasogenic edema, treatment with colloid for 2 hours after injury produced no change in ICP, whereas NS and D5W infusions led to elevations in ICP of 91% and 141%, respectively.
- if normovolemia does not improve CPP to desirable levels, add vasopressor:
 - a) young and healthy - use **NOREPINEPHRINE** (max 0.2 µg/kg/min); if diuresis drops < 0.5 ml/kg/hr or metabolic acidosis → **DOPAMINE** (1-3 µg/kg/min).
 - b) old, kidney insufficiency – start with **DOPAMINE**.
 - c) cardiac index < 3 L/min/m², use inotropic **DOBUTAMINE** (2-20 µg/kg/min).
- lowering BP can lower ICP (but it may also lower CPP); **β-blockers** (or mixed β- and α-blockers – e.g. **LABETALOL**) provide best antihypertensive effects without causing significant cerebral vasodilatation; alternative – **diuretics**.
 - N.B. **Ca channel blockers** rise ICP! Also avoid **direct vasodilators!**
- increasing BP can also lower ICP (by autoregulatory vasoconstriction – in cases when ICP is elevated due to vascular engorgement; caution - damaged brain areas often have lost autoregulation)
- measures that increase BP do not necessarily improve CPP:
 - damaged brain areas may have lost autoregulation - increased vascular pressures (esp. mean BP > 110-120 mmHg) can raise cerebral blood volume and exacerbate brain edema.
 - some neurosurgeons allow BP to rise above normal on basis that this may abort plateau waves (CPP > 65-70 mm Hg → increased blood flow to injured areas of brain decreases tissue acidosis → ICP↓).

LUND protocol:

- 1) lowering CBV by **lowering mean arterial blood pressure**
 - 2) alleviating brain edema by **reducing hydrostatic forces in damaged capillary beds** (by precapillary vasoconstriction with DIHYDROERGOTAMINE) + **increasing plasma oncotic pressure** (ALBUMIN infusion).
- initial clinical trials of this approach yielded outcomes that were no worse than those achieved with more conventional techniques.
 - this protocol is in stark contrast to principles of CPP management, which state that low CPP stimulates arteriolar vasodilatation, causing increases in both CBV and ICP.

OTHER

INDOMETHACIN is effective in decreasing ICP

Godoy D et al. "Effects of Indomethacin Test on Intracranial Pressure and Cerebral Hemodynamics in Patients With Refractory Intracranial Hypertension: A Feasibility Study"

Patients with ICH or TBI and refractory ICP were treated with bolus and 2-hour IVI of indomethacin → statistically significant decrease in ICP + significant increase in CPP

PROGNOSIS

ICP > 30 mmHg is rarely associated with intact survival.

Poor neurologic outcome or death is associated with **ICP > 50 mmHg** or **CPP < 40 mmHg**.

BIBLIOGRAPHY

- L.P.ROWLAND "Merritt's Textbook of Neurology" 9th ed., 1995 (page 435)
D.SABISTON "Textbook of Surgery", 1997 (page 1359)
J.D.WILSON "Harrison's Principles of Internal Medicine", 1998 (chapter 374)
BEHRMAN "Nelson Textbook of Pediatrics" 15th ed., 1996 (page 1720)
R.VILCINIS "Neurotraumatologija", 1999