PNS ANATOMY & NEUROLOGIC EXAMINATION 1
PLEXUSES, MOTOR 1
Cervical plexus 1
Brachial plexus 3
Myotomes – Movements (arm) 13
Lumbosacral plexus 21
Myotomes – Movements (leg) 26
SENSORY 28

PNS anatomy & Neurologic Examination

NERVE FIBERS

ERLANGER and GASSER classification:

Fiber type	Function	Fiber diameter (μm)	Conduction velocity (m/s)
MYELINATED			
Aα	proprioreception, motor (somatic)	12-20	70-120
Aβ	touch (discriminative), pressure	5-12	30-70
Aγ	motor (to muscle spindles)	3-6	15-30
Aδ	pain, cold, touch (crude)	2-5	12-30
B	preganglionic autonomic	< 3	3-15
UNMYELINATED			
C	dorsal root – pain, temperature, some mechanoreception, reflex responses postganglionic sympathetic	≤ 1	≤ 2

A – storos mielinizuotos somatinės skaidulos
B – plonos mielinizuotos preganglinės skaidulos
C – nemielinizuotos (pagrinde postganglinės) skaidulos

Susceptibility to:	Most susceptible	Least susceptible
Hypoxia	B	C
Pressure	A	C
Local anesthesia	C	A

– *local anesthetics* depress pain transmission before they affect touch fibers.
– *pressure on nerve* (Saturday night / Sunday morning paralysis) causes loss of conduction in motor, touch, pressure fibers while pain sensation remains relatively intact.

PLEXUSES, MOTOR

Raumenų simetrinis silpnumas:
proksimalinių – MIOPATIJA*, distalinių – POLINEURITAS**

*exception - **Kugelberg-Welander syndrome**
exception – **myotonic dystrophy (affects distal limbs)

CERVICAL PLEXUS

N. SUBOCCIPITALIS – **motor** C1 dorsal primary ramus
N. OCCIPITALIS MAJOR – **sensory** C2 dorsal primary ramus

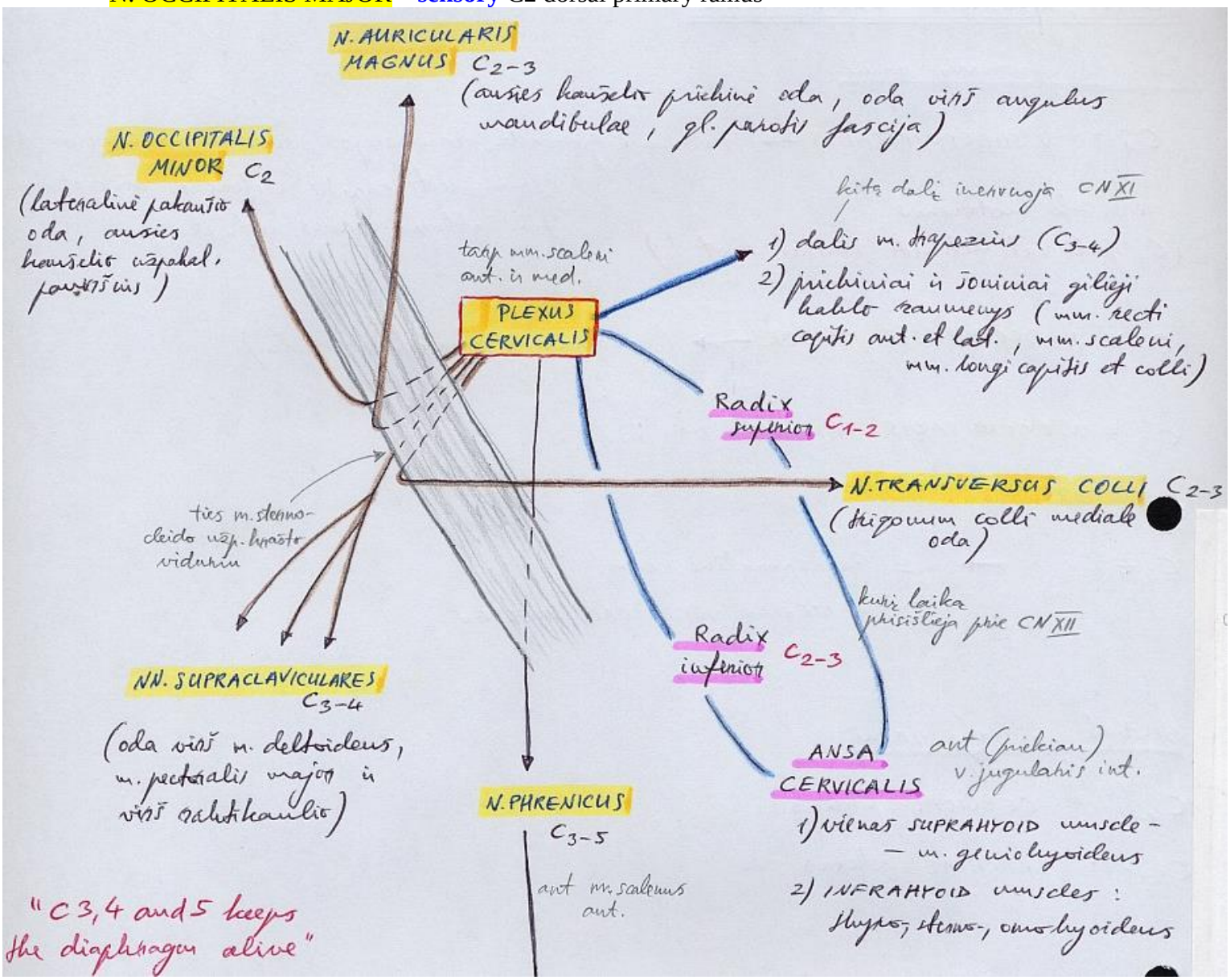

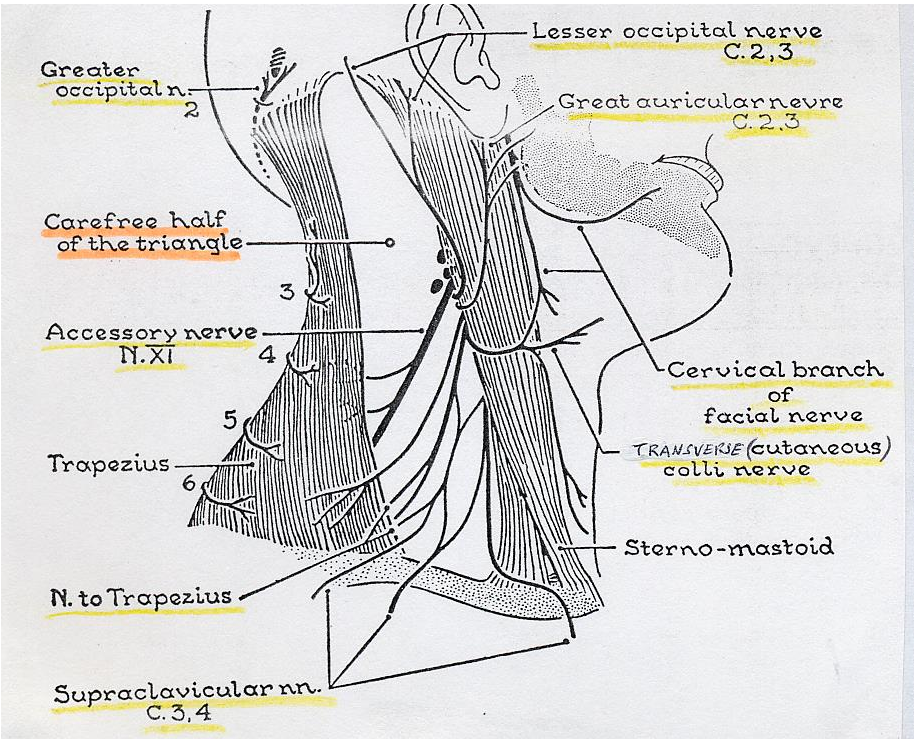

Dorsal primary rami

C_1 = N. SUBOCCIPITALIS → (trumpieji spraudo raumenys – SUBOCCIPITAL GROUP:
1) mm. recti capitis posteriores major et minor
2) m. obliqui capitis inf. et sup.)

N.B. tik motorinis
(C_1 gali net neturėti dorsal root !)

C_2 = N. OCCIPITALIS MAJOR → (medialinė pakaušio oda)
tendo m. trapezii

C_3 = N. OCCIPITALIS TERTIUS
dėn. prisijungia prie C_2

BRACHIAL PLEXUS

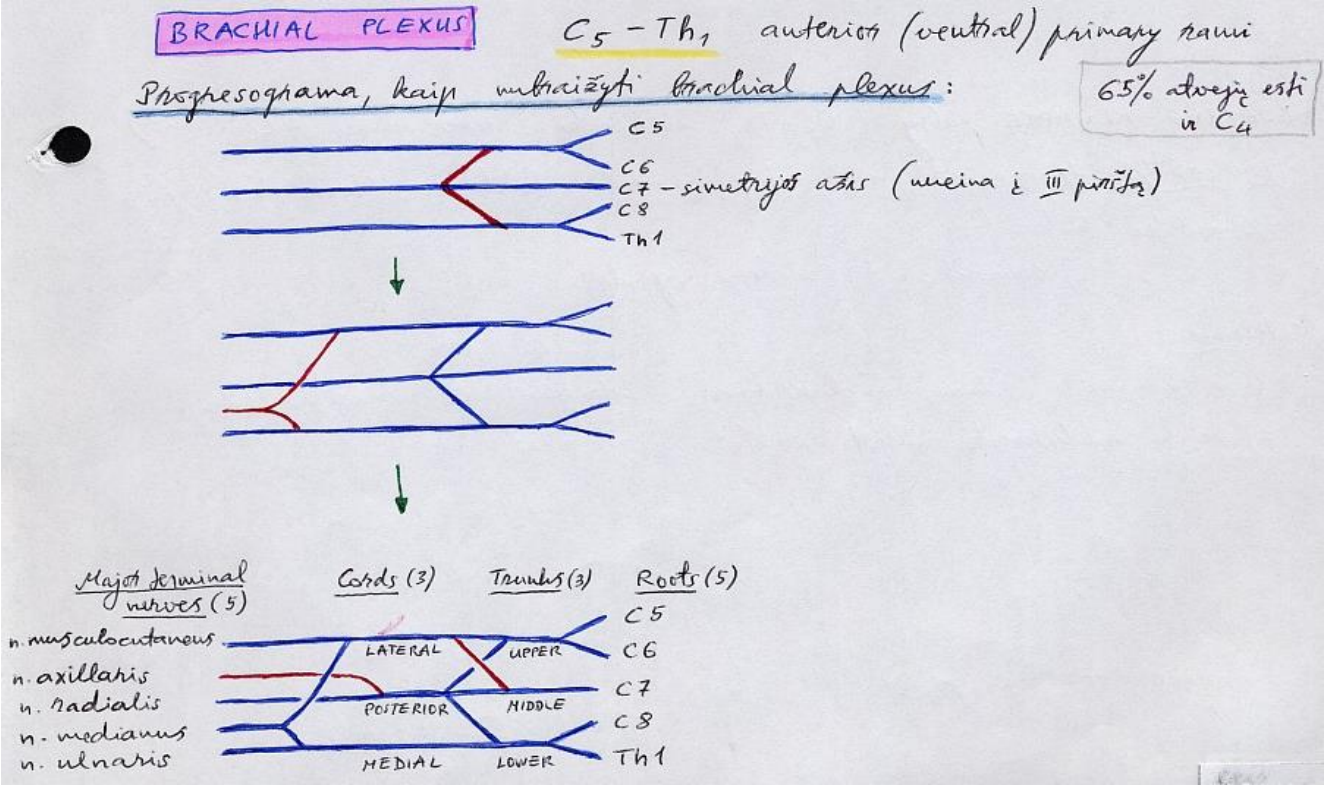

Roots – Trunks – Divisions (neduoda vardiniu saku) – Cords – Peripheral Nerves

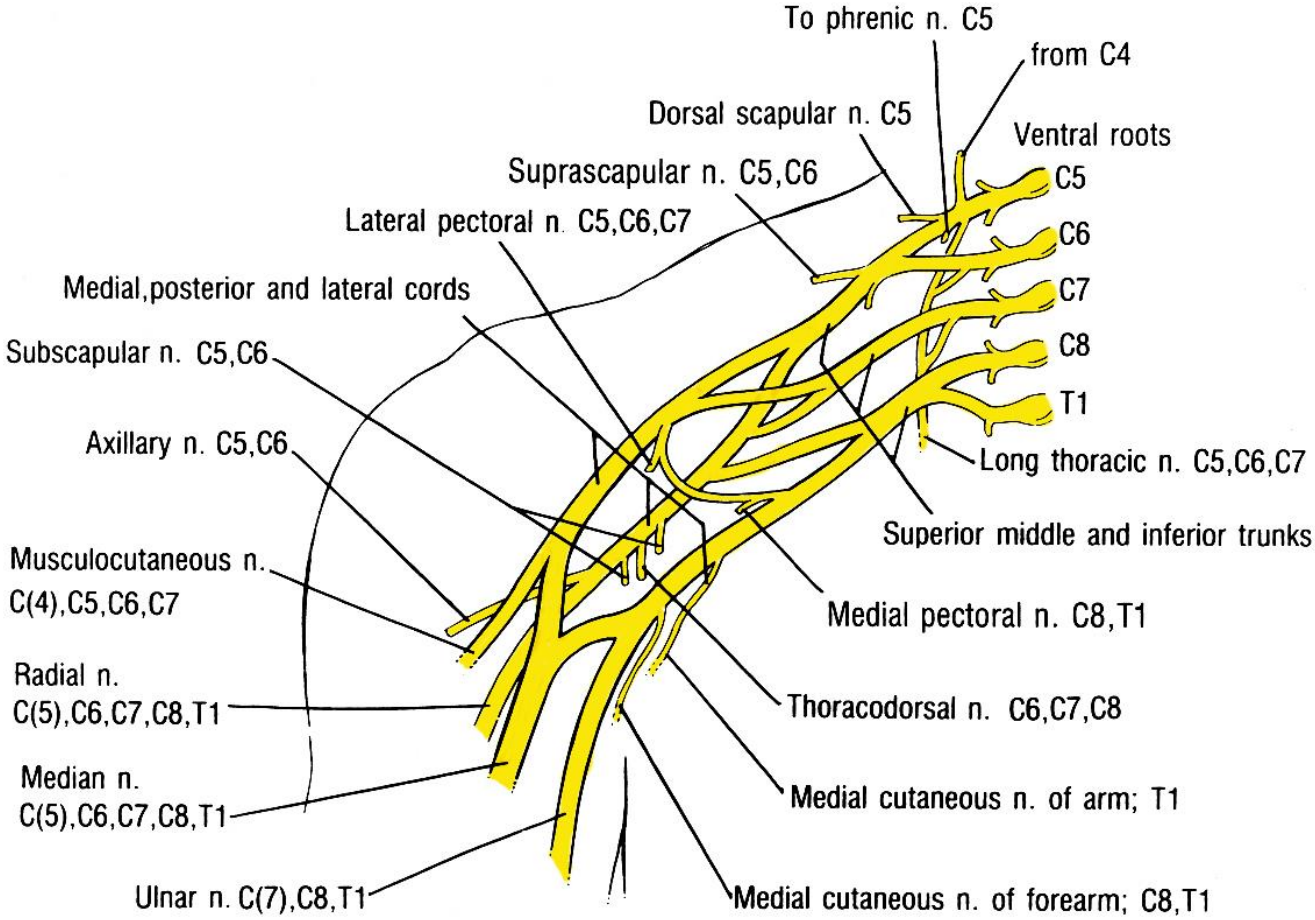

Dar: first intercostal nerve (from Th1 root), nerve to subclavius (from upper trunk)

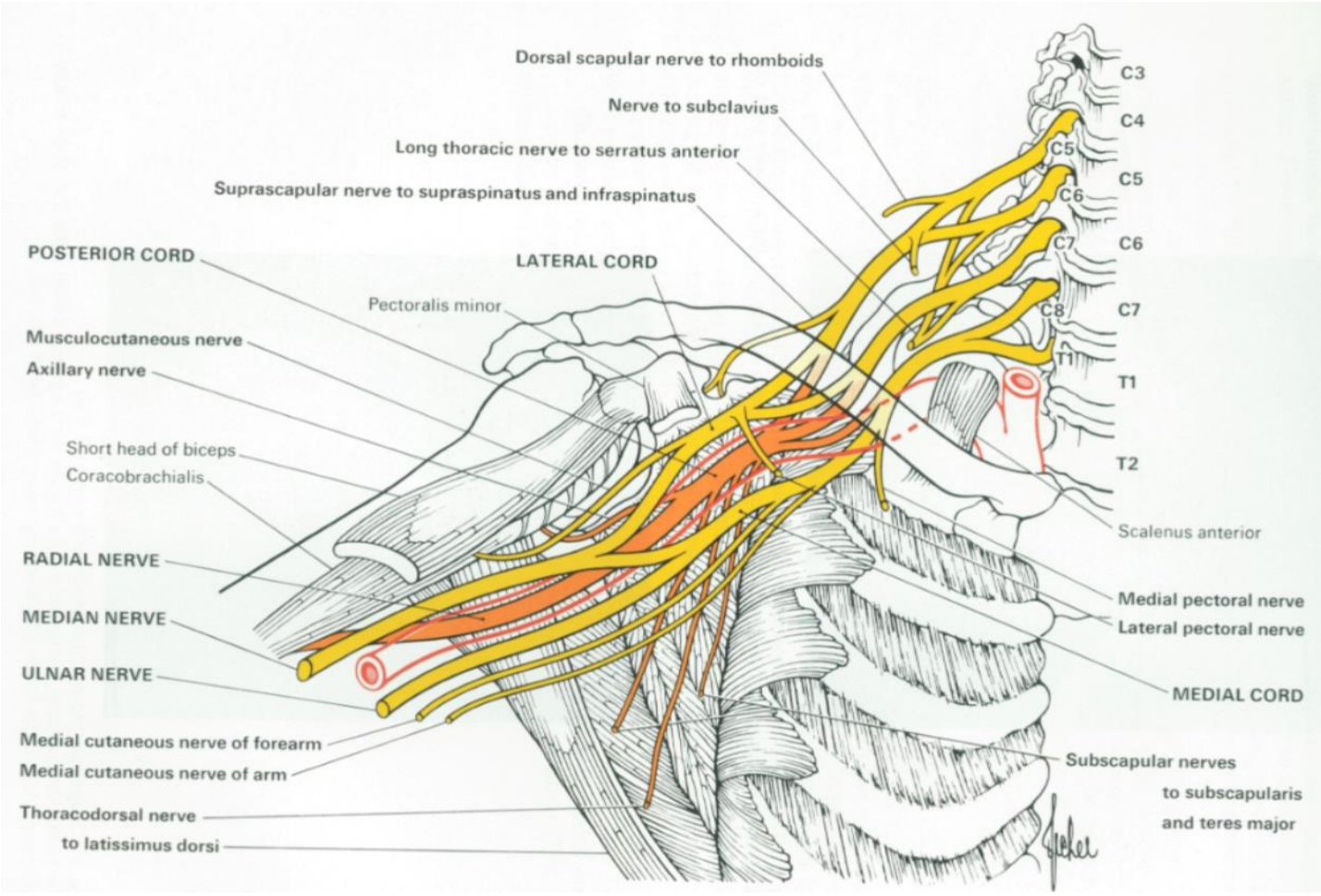

L. POSTERIOR cord (susijungę POSTERIOR divisions)
$C_5 - Th_1$

TĘSINYS →
- n. radialis (visi ekstenzoriai, m. supinator)
- n. axillaris (m. deltoideus, m. teres minor)
- upper subscapular n. (m. subscapularis)
- middle subscapular n. (s. n. thoracodorsalis) (m. latissimus dorsi)
- lower subscapular n. (m. teres major)

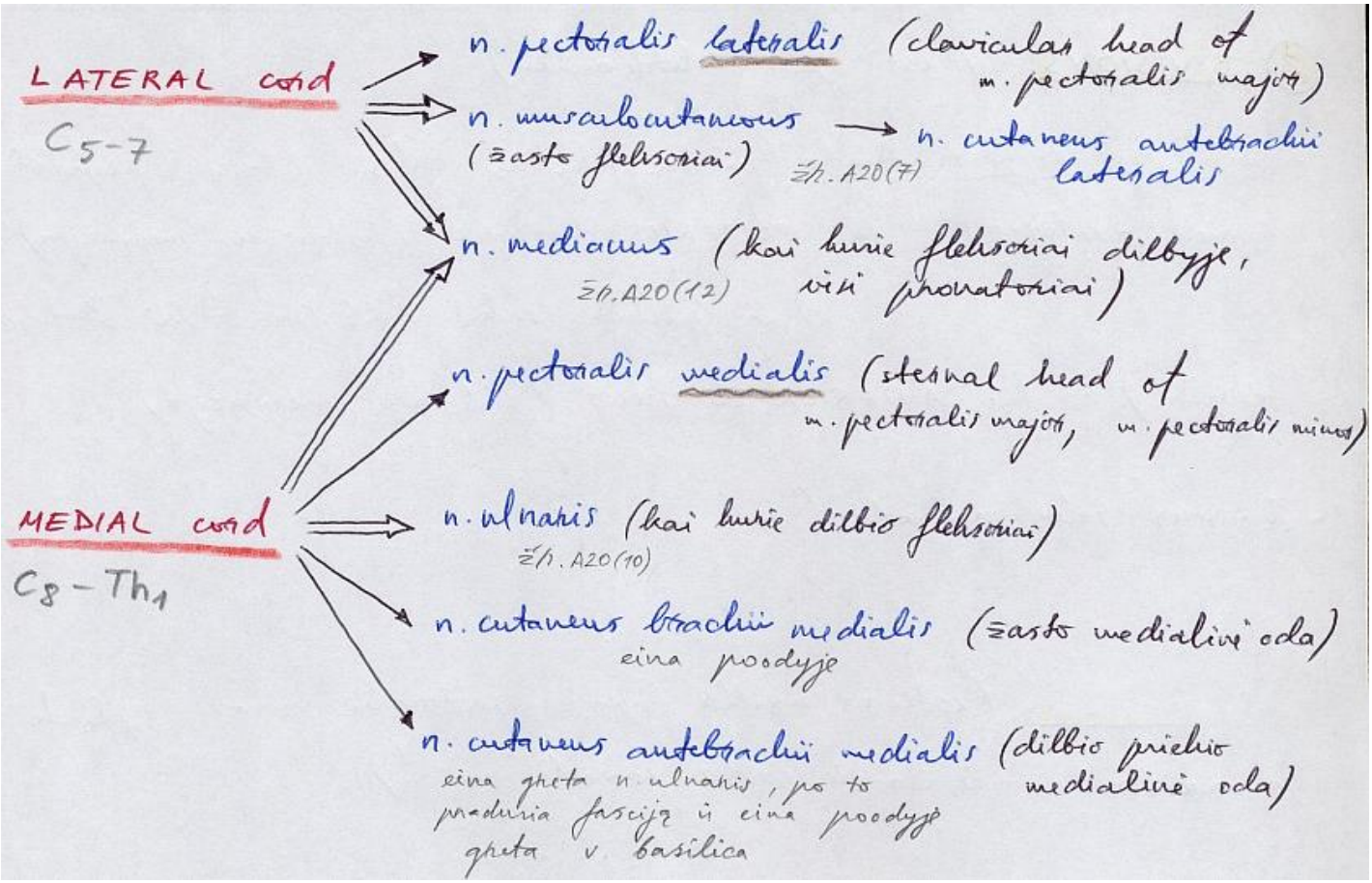

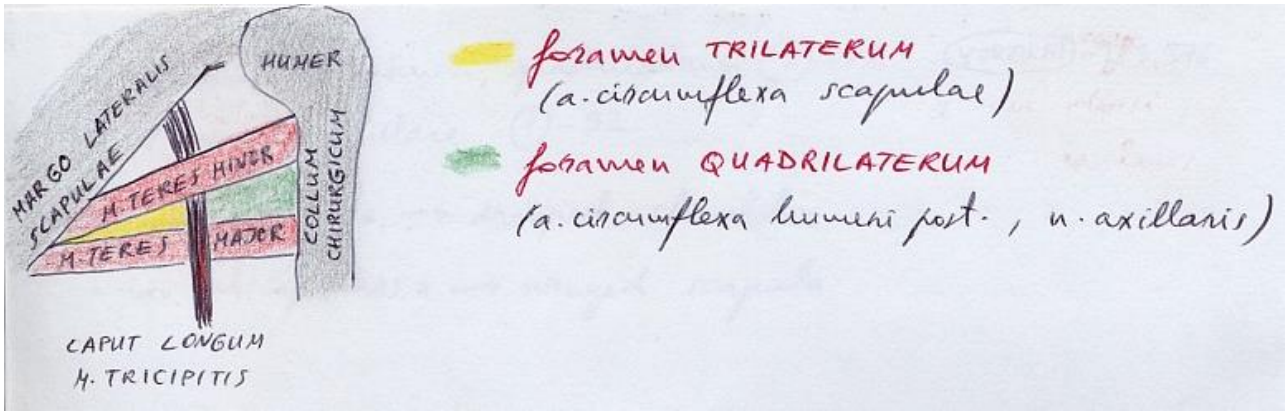

Duchenne-Erb:

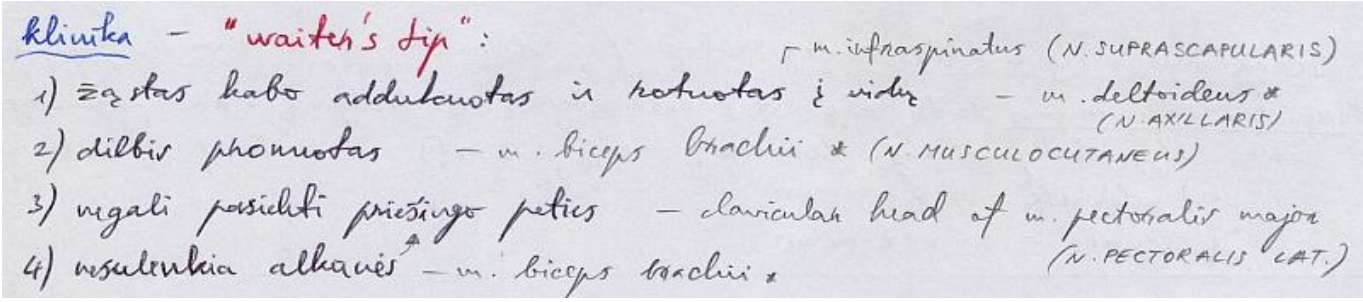

Klumpke-Dejerine:

klinika :

1) n. ulnaris * (pilnai) – "claw hand" + sutrikusi kiešo ulnarinė flekcija
2) negali adduktuoti mažasis pirštas N. PECTORALIS MED.

N. MUSCULOCUTANEUS → (ties alkūne praduria fasciją) → N. CUTANEUS ANTEBRACHII LATERALIS
(dilbio lateralinė oda)
eina poodyje šalia v. cephalica

(Žasto priekiniai raumenys:
1) m. biceps brachii
2) m. coracobrachialis
3) m. brachialis)

N. CUTANEUS BRACHII LATERALIS SUPERIOR ← N. AXILLARIS ← POSTERIOR cord
(m. deltoideus, m. teres minor)

Musculocutaneous:

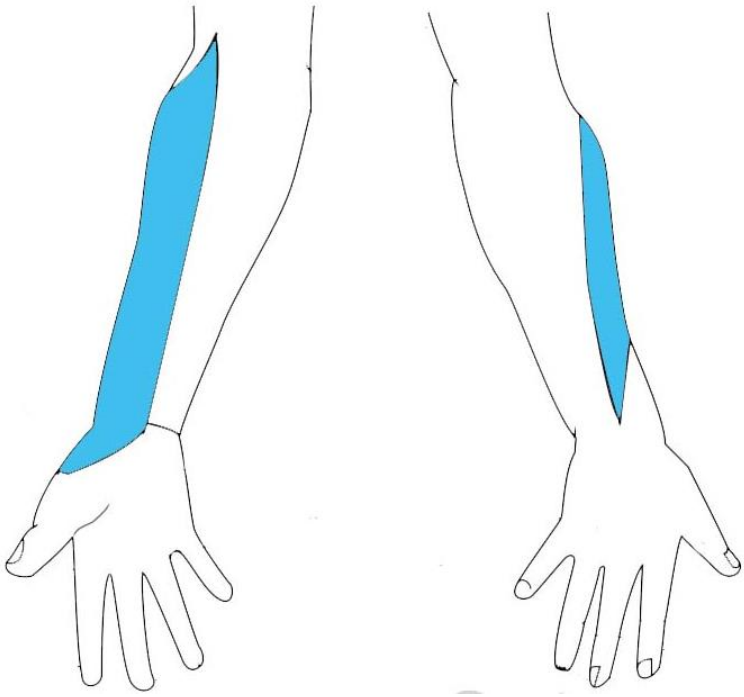

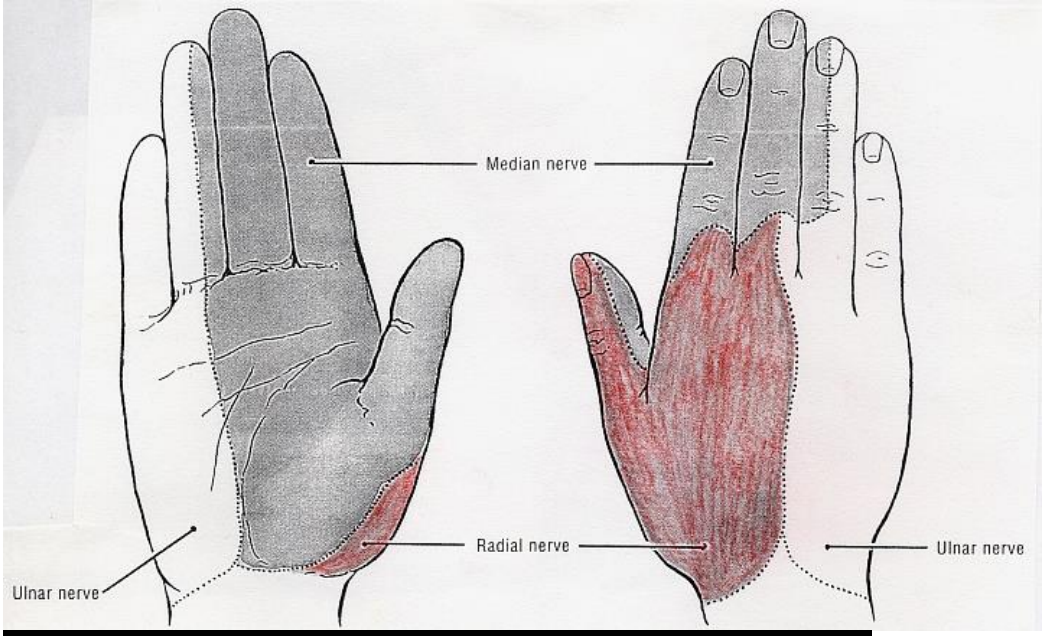
Median nerve
Radial nerve
Ulnar nerve
Ulnar nerve

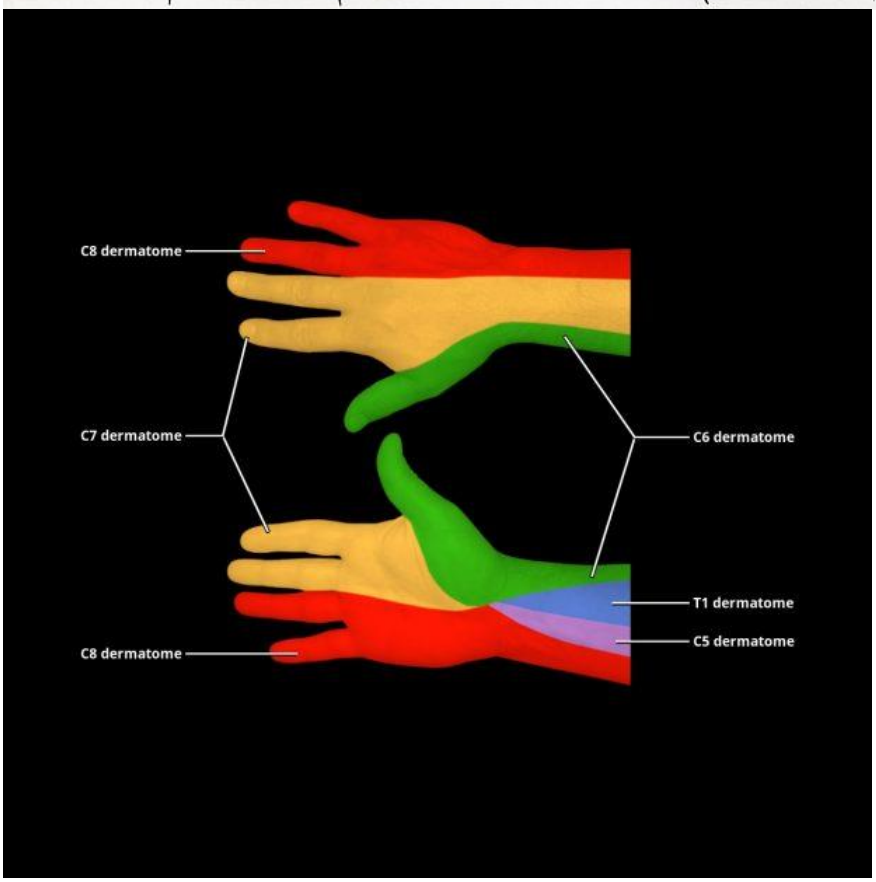
C8 dermatome
C7 dermatome
C6 dermatome
T1 dermatome
C5 dermatome
C8 dermatome

N. RADIALIS $C_5 - Th_1$ – POSTERIOR cord šakinys

Ž0. YOKOCHI 371
(jau nuskenuota – A20(8)p.)

MOTORIKA – ekstenzija per visus sąnarius, dalis supinacijos
• pažeidus n. radialis → → "wrist drop"

motorikos tyrimas – Ž0. "EXAMINATION TECHNIQUES"

N. RADIALIS

- N. CUTANEUS BRACHII POST.
- N. CUTANEUS BRCHII LATERALIS INF.
- N. CUTANEUS ANTEBRACHII POST.
- m. triceps brachii
- canalis humeromuscularis
  - atšyla dar prieš pasidalinant į šakas
  - m. brachioradialis, m. anconeus, m. extensor carpi radialis longus
- išlenda iš po m. brachialis į sulcus cubitalis anterior lateralis (tarp m. brachialis ir m. brachioradialis)
- R. PROFUNDUS
  - motorika
  - veria m. supinator
  - N. INTEROSSEUS POSTERIOR – eina tarp giliojo ir paviršinio ekstenzorių sluoksnių (šalia a. interossea post.)
- R. SUPERFICIALIS
  - sensorika
  - eina in sulcus radialis, lateralian a. radialis
  - ties dilbio viduriniu ir apatiniu 1/3 dalių riba suka (virš m. brachioradialis) į nugarinį paviršių
  - NN. DIGITALES DORSALES
    - Ž2. A20(14)

N.B. plaštaką pasiekia tik juntamoji šaka

(dilbio užpakaliniai raumenys:
1) m. supinator
2) m. extensor digitorum
3) m. extensor carpi radialis brevis
4) m. extensor carpi ulnaris
5) m. extensor indicis
6) m. extensor dig. V
7–8) mm. extensores pollicis longus et brevis
9) m. abductor pollicis longus

• midhumeral fracture – – nemuhenčia m. triceps inervacija
• radial fracture – muhenčia tik n. profundus (sensorika išlieka)

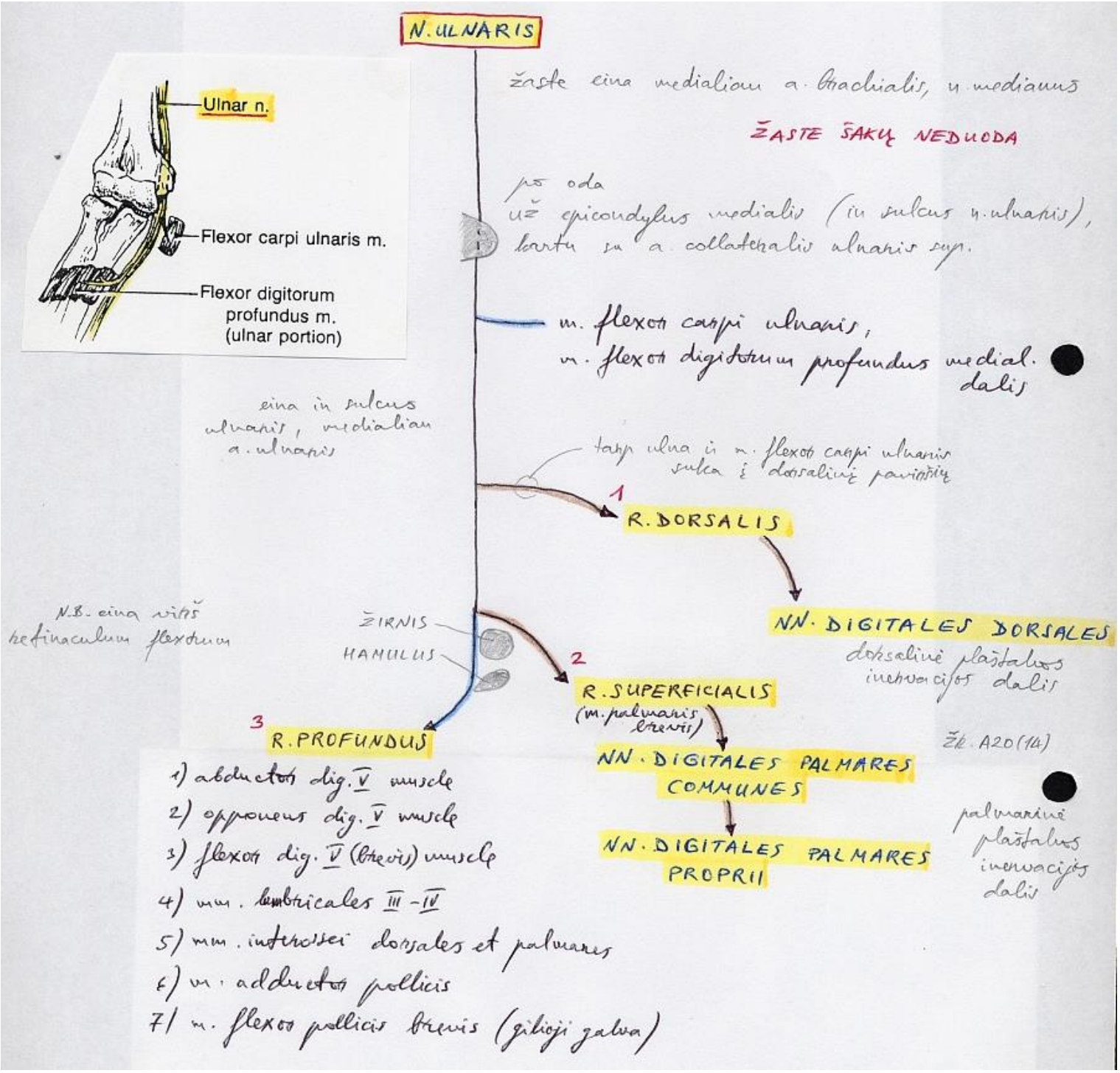

UN enters the hand through Guyon's canal, which is a fibro-osseous tunnel between the pisiform and hook of the hamate.

Su nykščiu galima pademonstruoti visus tris nervus:

N. RADIALIS – ekstenzija

N. MEDIANUS – opozicija

N. ULNARIS – adduckija

mm. interossei (n. ulnaris) – daline fleksija in MP joints, daline ekstenzija in DIP ir PIP joints

Pazeidus n. ulnaris, iskrenta:

- interossei:

  bando tiesti pirštus – bet tiesiasi tik MP ("**grifo ranka**" – neišsitiesia pirštai)

bando gniaužti pirštus – bet lenkiasi tik pirštų galiukai ("**grifas gali laikytis už uolos**")

- adductor policis: **FROMENT prehensile thumb sign**

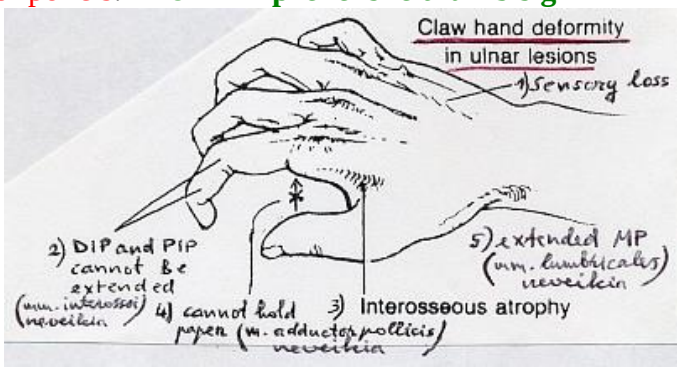

<u>Pazeidus n. radialis</u>, islieka interossei – islieka daline ekstenzija in DIP ir PIP joints!

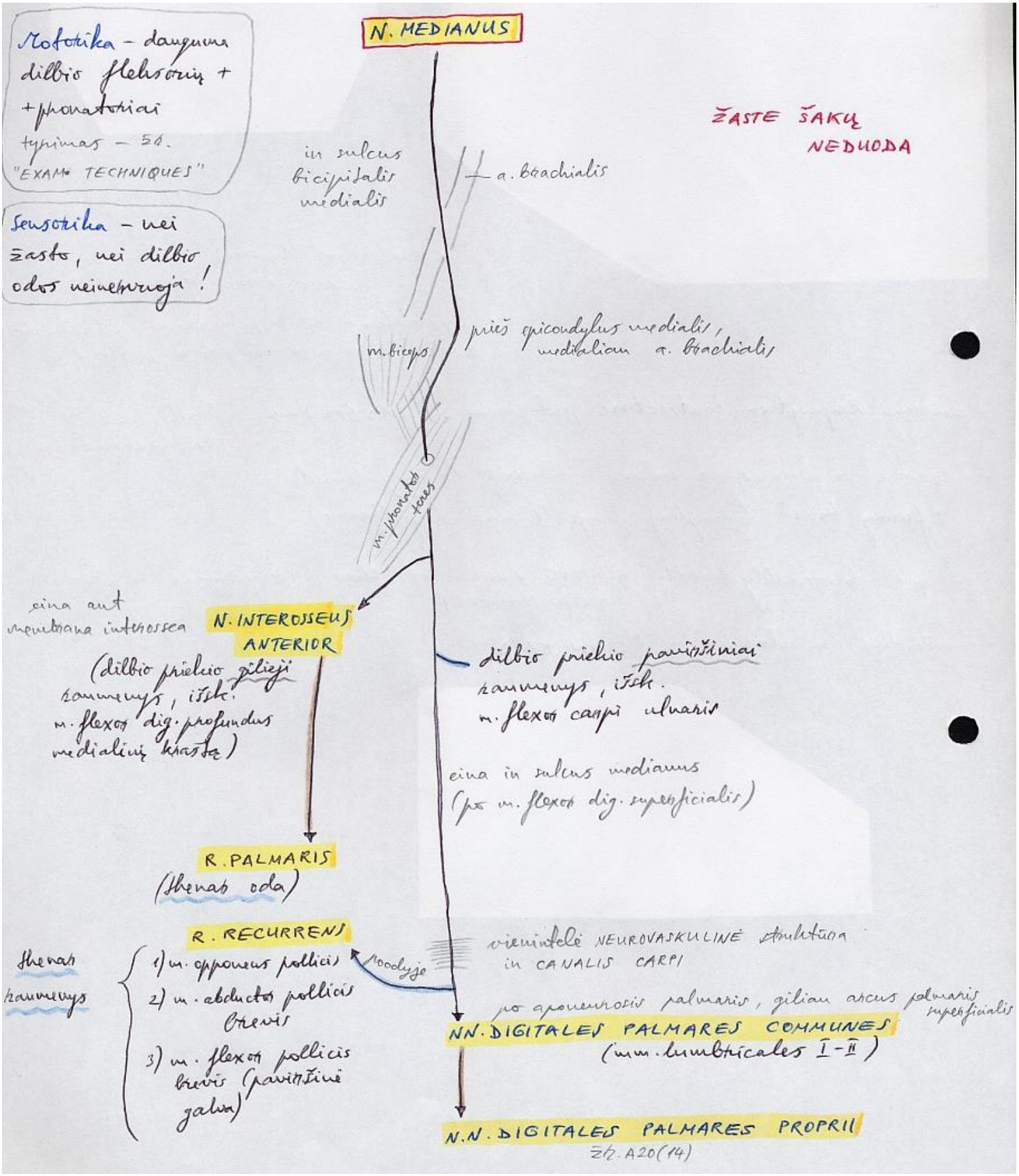
Motorika – dauguma dilbio flekserių + + pronatoriai
tyrimas – 56. "EXAM TECHNIQUES"
Sensorika – nei žasto, nei dilbio, odos neinervuoja!
N. MEDIANUS
ŽASTE ŠAKŲ NEDUODA
in sulcus bicipitalis medialis
a. brachialis
m. biceps
prieš epicondylus medialis, medialiau a. brachialis
m. pronator teres
eina aut membrana interossea
N. INTEROSSEUS ANTERIOR
(dilbio priekio gilieji žaizmenys, išsk. m. flexor dig. profundus medialinę kraštę)
dilbio priekio paviršiniai žaizmenys, išsk. m. flexor carpi ulnaris
eina in sulcus medianus (pro m. flexor dig. superficialis)
R. PALMARIS
(Sthenar oda)
R. RECURRENS
Sthenar žaizmenys
1) m. opponens pollicis
2) m. abductor pollicis brevis
3) m. flexor pollicis brevis (paviršinė galva)
Roodyje
vienintelė NEUROVASKULINĖ struktūra in CANALIS CARPI
po aponeurosis palmaris, giliau arcus palmaris superficialis
NN. DIGITALES PALMARES COMMUNES
(mm. lumbricales I–II)
N.N. DIGITALES PALMARES PROPRII
žr. A20(14)

- N. medianus pažeidimai → "hand of benediction"
- gali būti pažeistas imant kraują iš v. mediana cubiti
- paviršinis anterior wrist sužalojimas gali pažeisti tik R. PALMARIS (thenar jutimai *) ir eina virš retinaculum flexorum
- paviršinis delno sužalojimas – R. RECURRENS (thenar motorika *)
- carpal tunnel syndr. – thenar motorika *, pirštų jutimai *, bet thenar jutimai nesutrinka (R. PALMARIS neina per canalis carpi !)

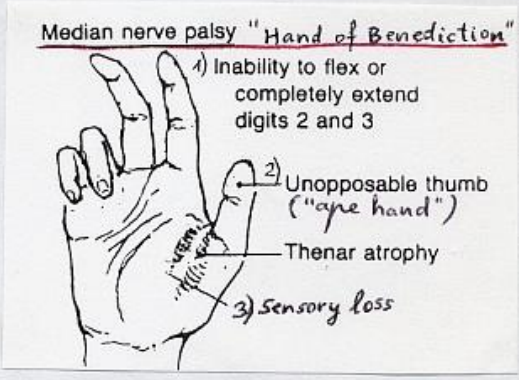

Pazeidus n. medianus – "hand of benediction", nepadaro "OK sign" against resistance (pirstu galai issitiesia – veikia interossei bet neveikia flexor digitorum).

- important anatomic variant is **RICHE-CANNIEU anastomosis** - innervation of thenar muscles is provided by ulnar nerve.

MYOTOMES – MOVEMENTS (ARM)

Root	Muscle	Action	Reflex
C_{3-4}	**Trapezius** (*spinal accessory n.*)	Shrug shoulder, adduct scapula	
C_{4-5}	**Rhomboids** (*dorsal scapular n.*)	Brace shoulder back ("like a Marine")	
C_{5-6}	**Deltoid** (***axillary n.***) **Supraspinatus** (*suprascapular n.*) **Infraspinatus** (*suprascapular n.*) **Biceps** (*musculocutaneous n.*) Subclavius (*subclavian n.*) Pectoralis minor (*medial pectoral n.*) Subscapularis (*subscapular n.*) Teres major (*subscapular n.*) Teres minor (***axillary n.***) Levator scapulae (*dorsal scapular n.*) **Pectoralis major, clavicular head** (*lateral pectoral n.*) Supinator (***radial n.***) Brachioradialis (***radial n.***)	Shoulder abduction (15-90°) Shoulder abduction (first 15°) Humeral external rotation (with arm held at side and flexed at elbow) Flexion of supinated forearm Reaching opposite shoulder Flexion of forearm midway between supination and pronation	 **C5-6** - Biceps DTR **C5** – Pectoralis DTR **C5-7** - Brachioradialis DTR
C_{5-7}	Serratus anterior (*long thoracic n.*) Pronator teres (***median n.***)	Push forward against resistance	
C_{5-8}	**Extensor carpi radialis** longus & brevis (***radial n.***)	Wrist extension (mainly C6)	

C_{7-8}	**Extensor carpi ulnaris** (***radial n.- PIN branch***) **Extensors digitorum & pollicis** (***radial n.- PIN branch***) Abductor pollicis longus (***radial n.- PIN branch***) Abductor pollicis brevis "APB" (***median n.***)	Wrist extension Finger extension (at MCP joints) Abduct 1st metacarpal Abduct thumb	
C_{6-8}	**Triceps** (***radial n.***) Latissimus dorsi (*thoracodorsal n.*) **Flexor carpi**: radialis (***median n.***) ulnaris (***ulnar n.***)	Elbow extension (mainly C7) Wrist flexion (mainly C7)	**C7-8** – Triceps DTR C7 is antigravity action in quadruple stance
C_7-T_1	**Pectoralis major, sternocostal head** (*medial pectoral n.*) **Flexor digitorum superficialis** (***median n.***)	Independently flexes **PIP** + **MCP** of each finger + **wrist** joint	
C_8-T_1	**Flexor digitorum profundus**: I-II (***median n.***) III-IV (***ulnar n.***) Flexor pollicis longus (***median n.***) Opponens pollicis (***median n.***) Adductor pollicis (***ulnar n.***) **Lumbricales**: I-II (***median n.***) III-IV (***ulnar n.***) **Interossei** (***ulnar n.*** deep branch, mainly **T_1**): **palmar** **dorsal**	Flexes **DIP** joints, then secondarily flexes PIP and MCP Flex MCP and extend IP joints All interossei assist lumbricals in MCP flexion and IP extension **Adduct** fingers towards III finger. **Abduct** fingers away from III finger.	Best way to test T_1 - 5th finger abduction

Radial nerve – extension: elbow (C7), wrist (C6), fingers at MCP (C7)
N.B. finger extension at IP is ulnar (III-IV*, interossei) and median (I-II*) nerves
*lumbricals (C8-T1)
vs. wrist flexion is mainly C7
Hand grip (finger flexion) – C8
Horner syndrome – lesion very proximal (spinal cord or within centimeters from it at T1 level)

Most common mimickers (of C5 radiculopathy):

1. **Rotator cuff tear** – also gives shoulder abduction weakness but starts from 0 degrees and no elbow flexion weakness + painful shoulder movement / significant tenderness; positive Neer and Hawkins' tests for impingement.
2. **Suprascapular nerve entrapment** - not associated with weakness of other C5 innervated muscles (such as deltoid, biceps).

Most common mimicker (of C6-7 radiculopathies):

1. **Carpal tunnel syndrome** - nocturnal dysesthesias, hypoesthesia is present distally, over the palmar side of the hand and over the first three to three and one half digits. Weakness and atrophy of the thenar and first two lumbrical muscles (← innervated by C8 and T1). Phalen's test + Tinel's sign + Durkan sign.
2. **Posterior interosseus nerve compression** – no sensory findings, does not affect triceps.

Most common mimickers (of C8 radiculopathy):

1. **Ulnar entrapment at the elbow** - tenderness along the medial aspect of the elbow; positive Tinel's sign, *sensory change does not extend proximal to wrist*.
2. **Anterior interosseus nerve entrapment** - no sensory loss, pain over proximal forearm.

	Hand intrinsics	Abductor pollicis brevis
C8 radiculopathy	+	+
Ulnar neuropathy	+	
Median neuropathy		+

Scapular winging (scapula alata)	**trapezius (spinal accessory n.)**	**serratus anterior (long thoracic n.)**	**rhomboids (dorsal scapular n.)**
degree	milder	more severe	
at rest	present	negligible	
becomes worse on	shoulder abduction	shoulder flexion	

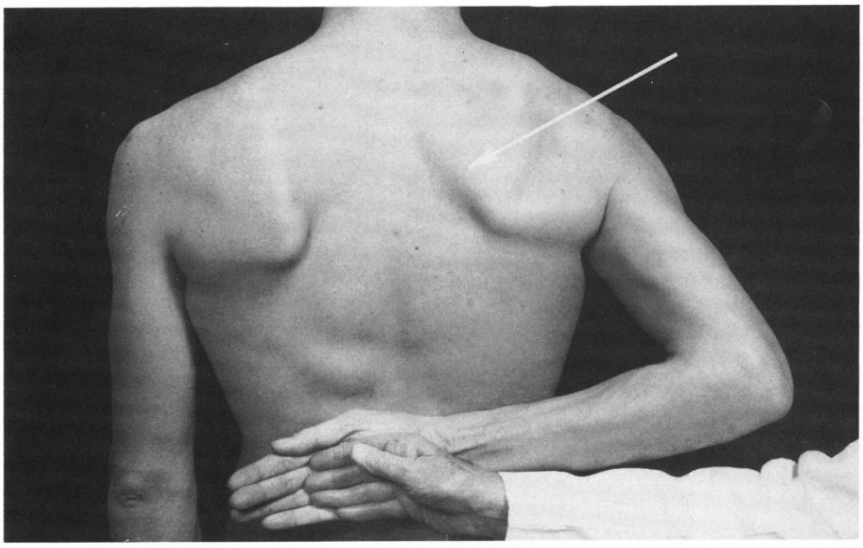

Fig. 4 Rhomboids (Dorsal scapular nerve; C4, C5)
The patient is pressing the palm of his hand backwards against the examiner's hand. *Arrow:* the muscle bellies can be felt and sometimes seen.

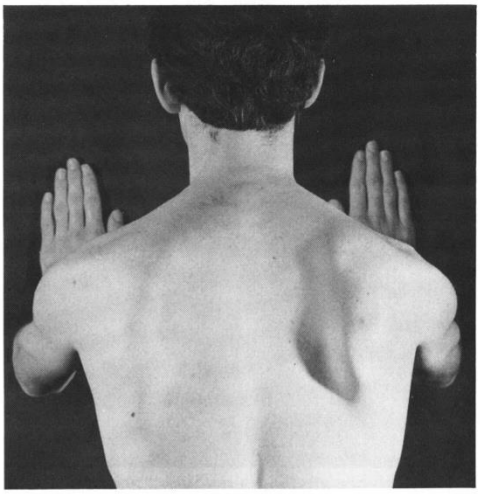

Fig. 5 Serratus anterior (Long thoracic nerve; C5, C6, C7)
The patient is pushing against a wall as in Fig. 2. The right serratus anterior is paralysed and there is winging of the scapula.

<u>Su rankos nykščiu galima pratestuoti visus tris nervus:</u>

ekstenzija – N.RADIALIS (m. extensor pollicis longus et brevis).

opozicija – N.MEDIANUS (m. opponens pollicis).

addukcija – N.ULNARIS (m. adductor policis).

abdukcija – N.RADIALIS (m. abductor pollicis longus) + N.MEDIANUS (m. abductor pollicis brevis).

fleksija – N.ULNARIS (m. flexor pollicis brevis, deep head) + N.MEDIANUS (m. flexor pollicis longus et brevis, superficial head).

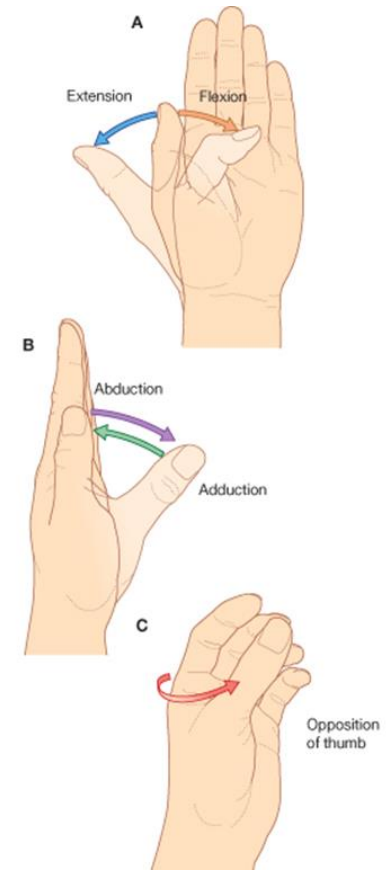

Thumb extensors (***radial n.***):

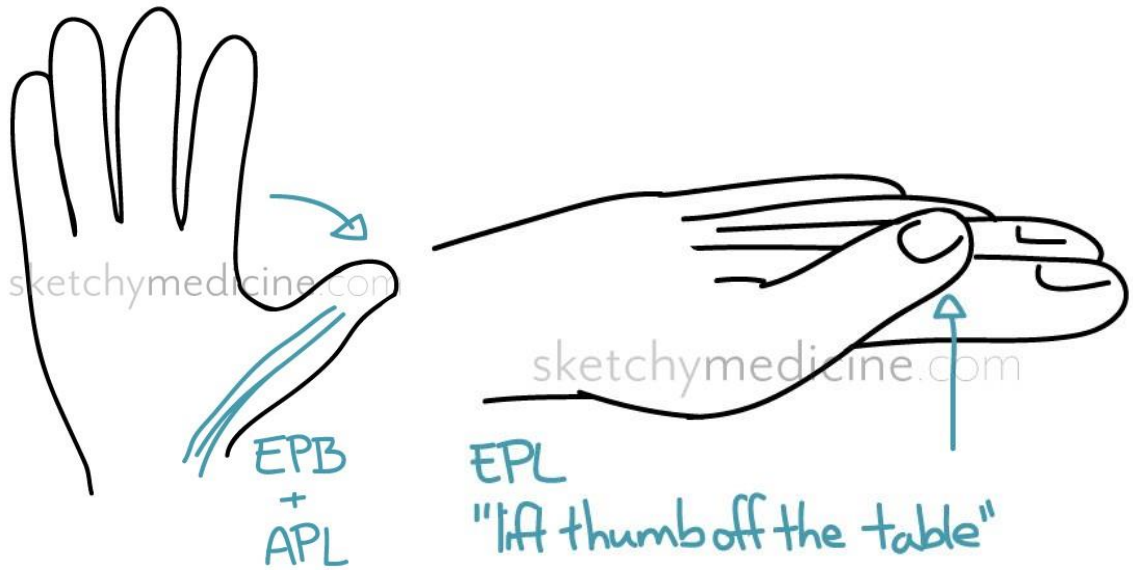

Opponens pollicis (***median n.***) – ability of thumb to move toward little finger against resistance:

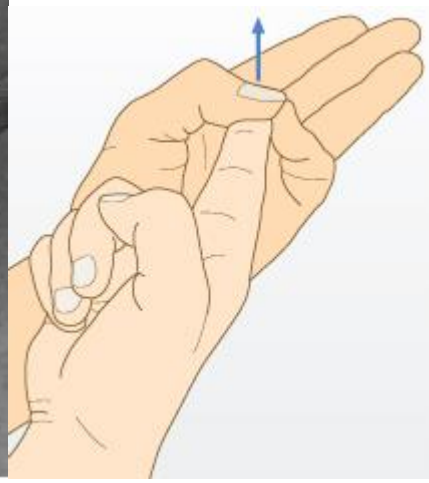

Abductor pollicis brevis (APB) (***median n.***) – ability to lift thumb proximal phalanx against resistance:

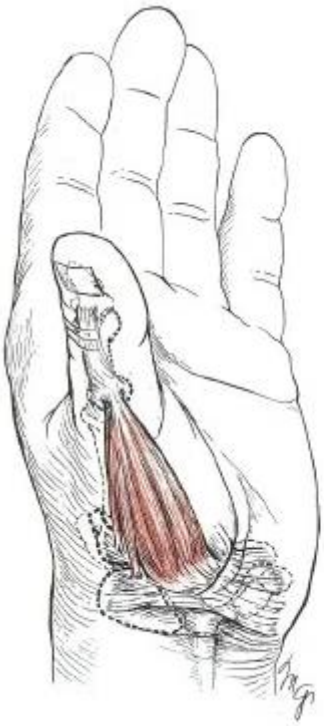

quantitative testing:

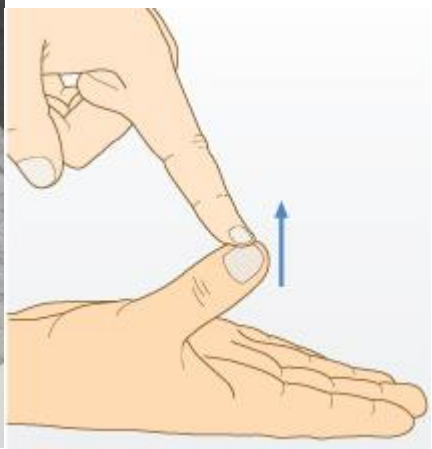

Abductor pollicis longus (APL) (***radial n.***):

Adductor pollicis (***ulnar n.***):

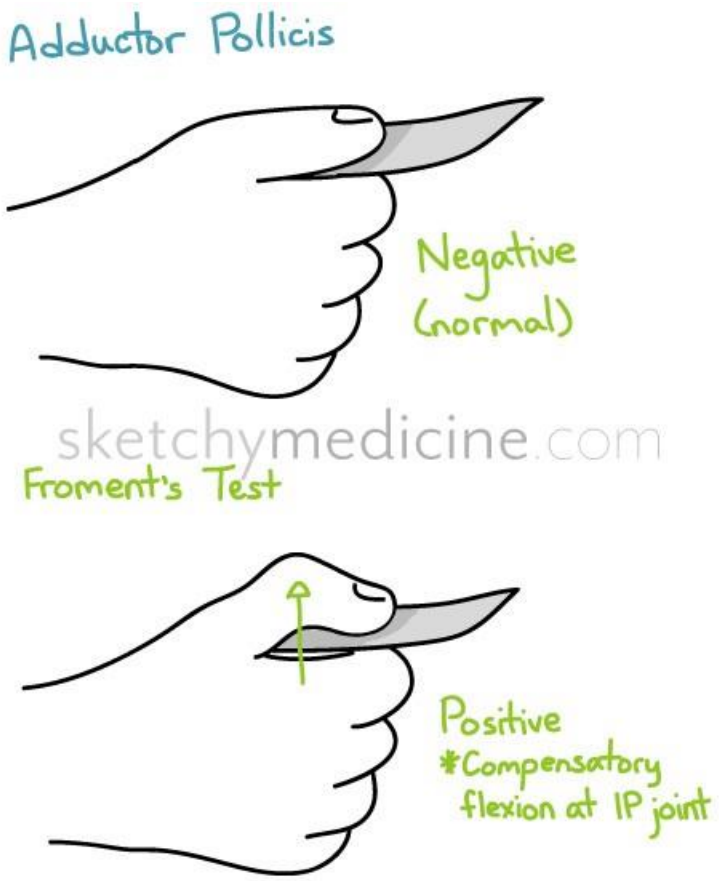

Flexors pollicis – longus (***median n.***), **brevis** (***median n.*** + ***ulnar n.***):

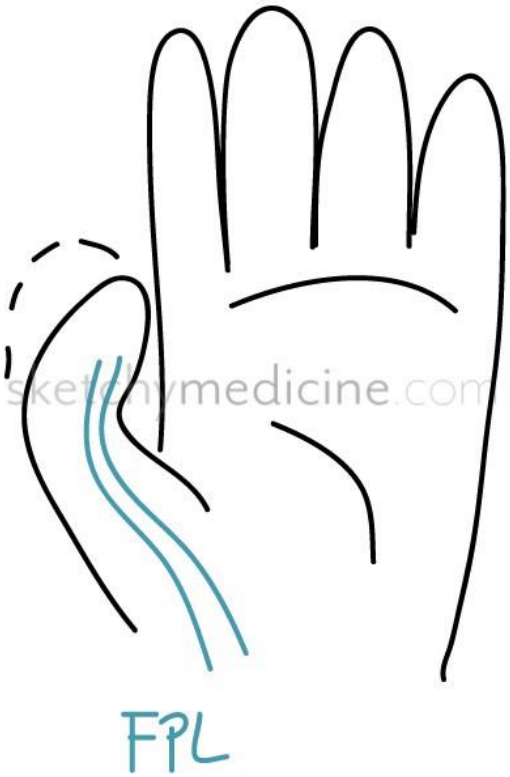

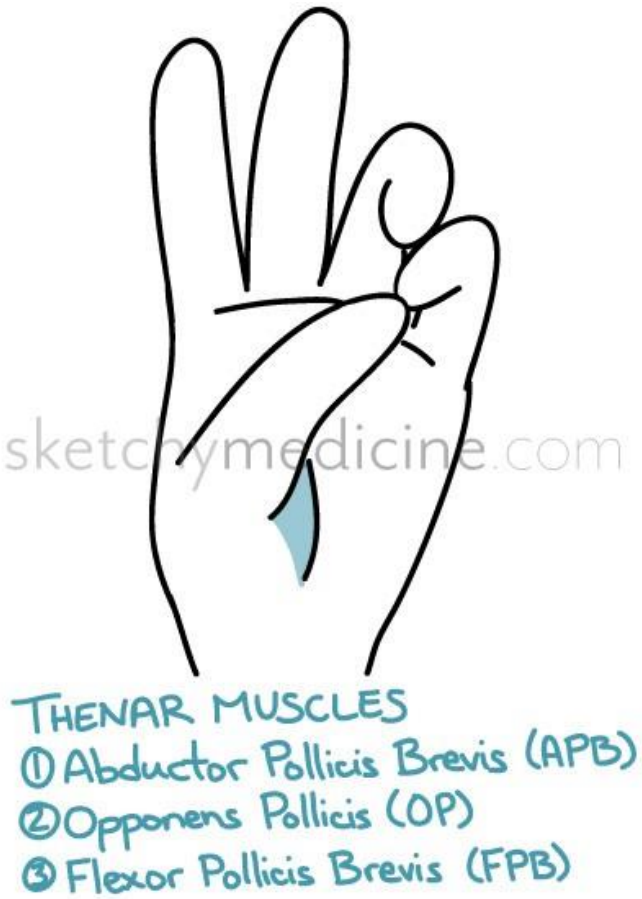

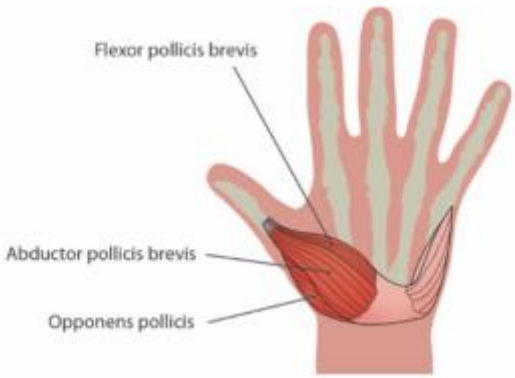

LUMBOSACRAL PLEXUS

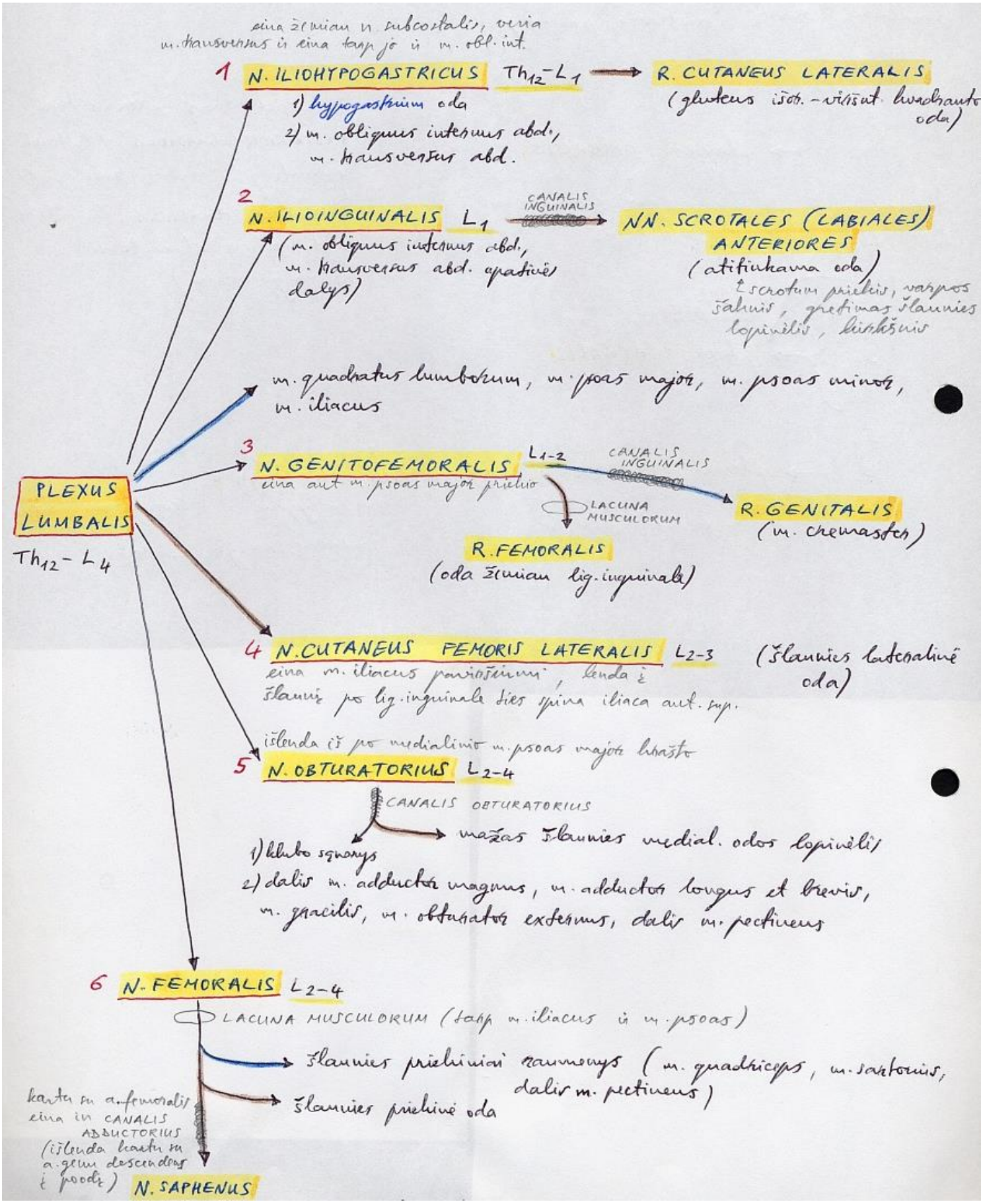
eina žemiau n. subcostalis, veria m. transversus ir eina tarp jo ir m. obl. int.
1 N. ILIOHYPOGASTRICUS Th12-L1
R. CUTANEUS LATERALIS
(gluteus išor. - viršut. kvadranto oda)
1) hypogastrium oda
2) m. obliquus internus abd., m. transversus abd.
2 N. ILIOINGUINALIS L1
CANALIS INGUINALIS
NN. SCROTALES (LABIALES) ANTERIORES
(atitinkama oda)
scrotum priekis, varpos šaknis, gretimas šlaunies lopinėlis, kirkšnis
(m. obliquus internus abd., m. transversus abd. apatinė dalys)
m. quadratus lumborum, m. psoas major, m. psoas minor, m. iliacus
3 N. GENITOFEMORALIS L1-2
CANALIS INGUINALIS
eina aut m. psoas major priekio
LACUNA MUSCULORUM
R. GENITALIS
(m. cremaster)
R. FEMORALIS
(oda žemiau lig. inguinale)
PLEXUS LUMBALIS
Th12 - L4
4 N. CUTANEUS FEMORIS LATERALIS L2-3
(šlaunies lateralinė oda)
eina m. iliacus paviršiumi, lenda į šlaunį po lig. inguinale tiesi spina iliaca ant. sup.
išlenda iš po medialinio m. psoas major kraštu
5 N. OBTURATORIUS L2-4
CANALIS OBTURATORIUS
mažas šlaunies medial. odos lopinėlis
1) klubo sąnarys
2) dalis m. adductor magnus, m. adductor longus et brevis, m. gracilis, m. obturator externus, dalis m. pectineus
6 N. FEMORALIS L2-4
LACUNA MUSCULORUM (tarp m. iliacus ir m. psoas)
šlaunies priekinioji raumenys (m. quadriceps, m. sartorius, dalis m. pectineus)
šlaunies priekinė oda
kartu su a. femoralis eina in CANALIS ADDUCTORIUS (išlenda kartu su a. genu descendens į poodį)
N. SAPHENUS

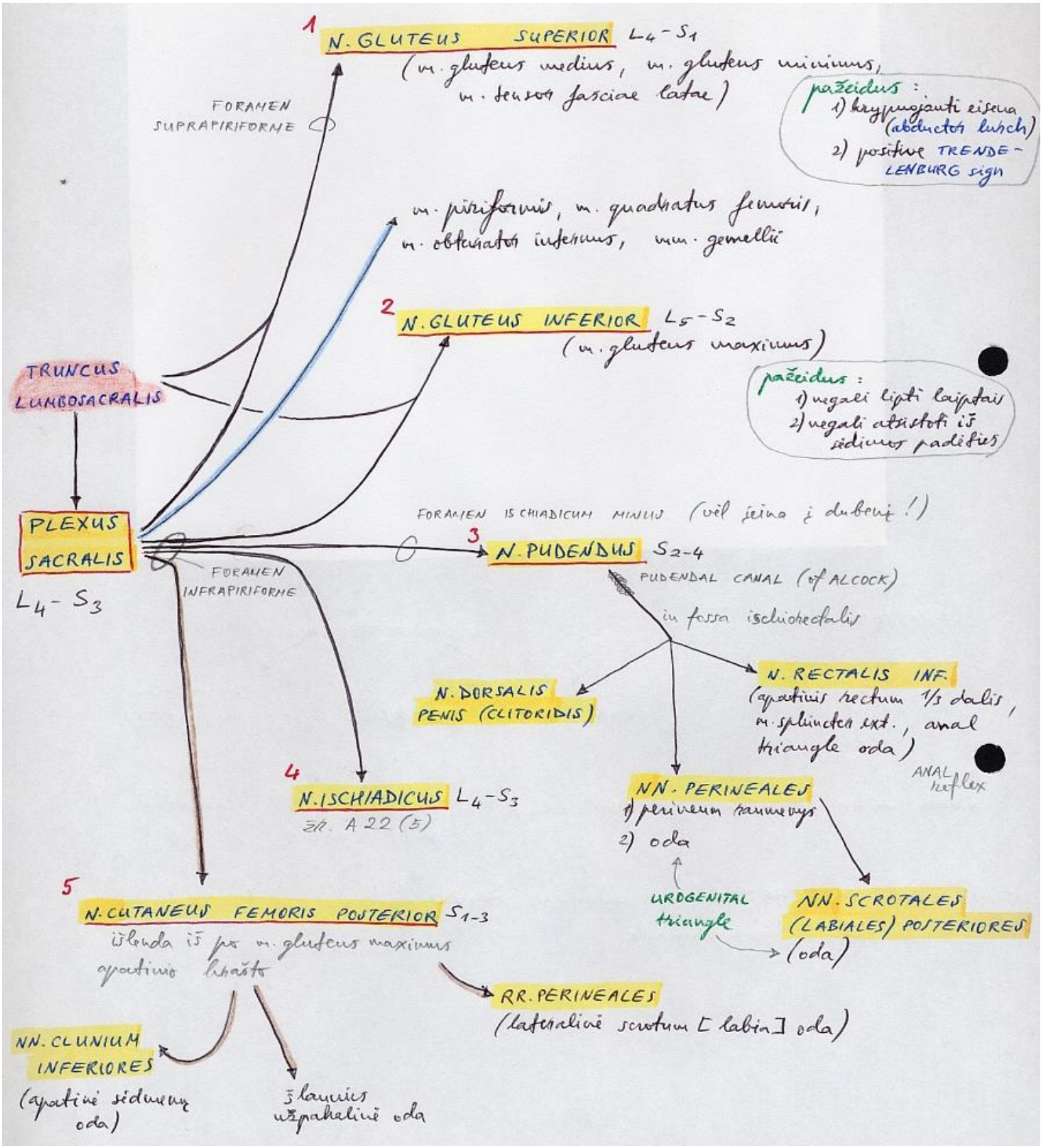
1 N. GLUTEUS SUPERIOR L4 - S1
(m. gluteus medius, m. gluteus minimus, m. tensor fasciae latae)
pažeidus:
1) kryptinguoti eisena (abductor lurch)
2) positive TRENDELENBURG sign
FORAMEN SUPRAPIRIFORME
m. piriformis, m. quadratus femoris, m. obturator internus, mm. gemelli
2 N. GLUTEUS INFERIOR L5 - S2
(m. gluteus maximus)
pažeidus:
1) negali lipti laiptais
2) negali atsistoti iš sėdimos padėties
TRUNCUS LUMBOSACRALIS
PLEXUS SACRALIS
L4 - S3
FORAMEN ISCHIADICUM MINUS (vėl jeina į dubenį!)
3 N. PUDENDUS S2-4
PUDENDAL CANAL (of ALCOCK)
in fossa ischiorectalis
FORAMEN INFRAPIRIFORME
N. DORSALIS PENIS (CLITORIDIS)
N. RECTALIS INF.
(apatinis rectum 1/3 dalis, m. sphincter ext., anal triangle oda)
ANAL reflex
4 N. ISCHIADICUS L4 - S3
žr. A 22 (5)
NN. PERINEALES
1) perineum kanmenys
2) oda
UROGENITAL triangle
NN. SCROTALES (LABIALES) POSTERIORES
(oda)
5 N. CUTANEUS FEMORIS POSTERIOR S1-3
išlenda iš po m. gluteus maximus apatinio krašto
RR. PERINEALES
(lateralinė scrotum [labia] oda)
NN. CLUNIUM INFERIORES
(apatinė sėdmenų oda)
šlaunies užpakalinė oda

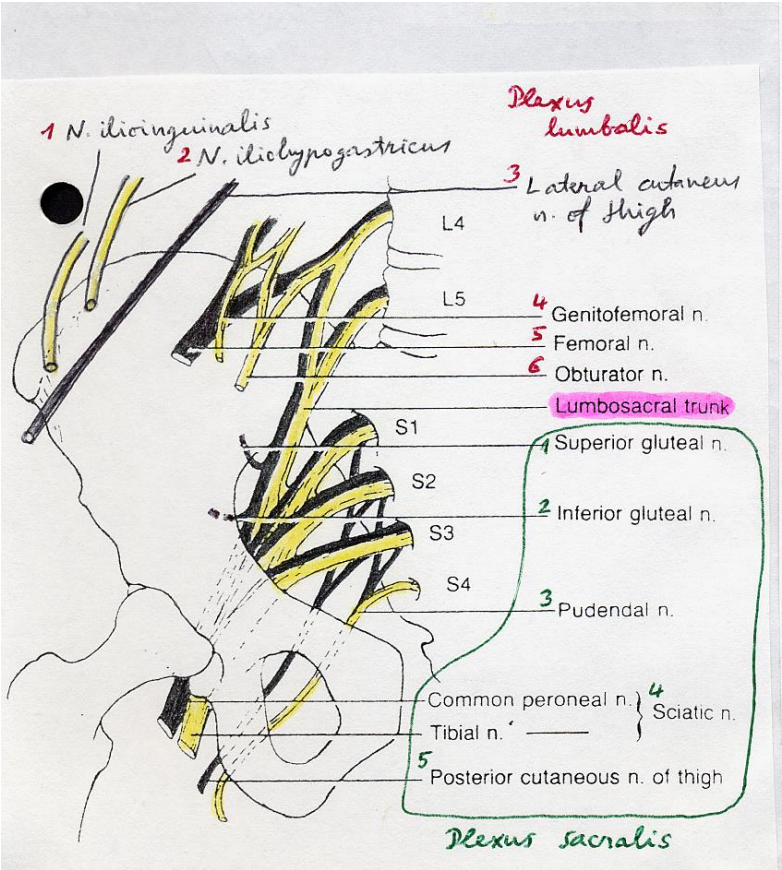

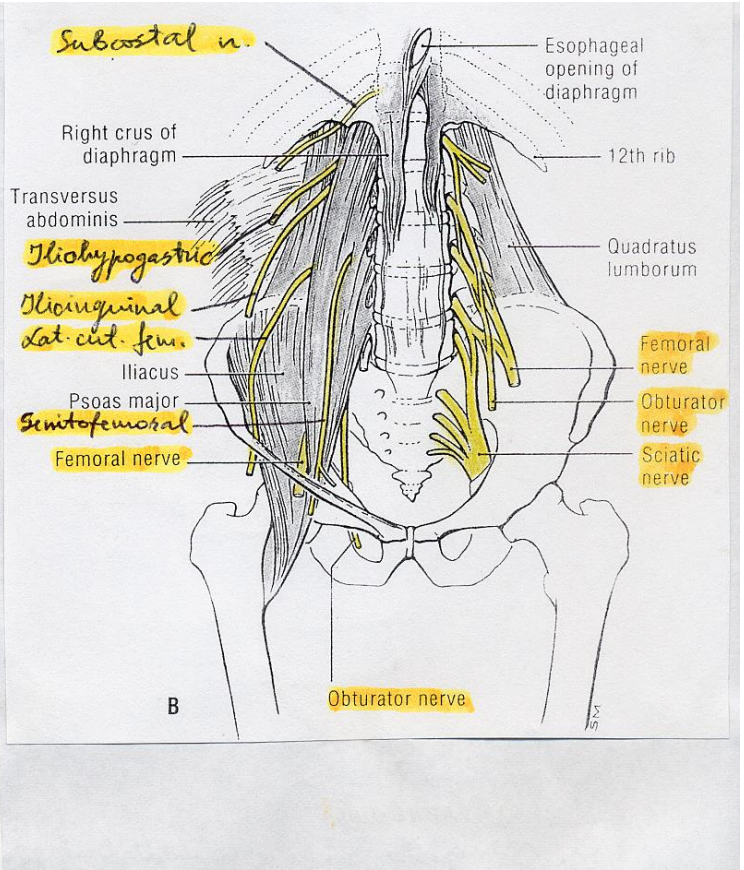

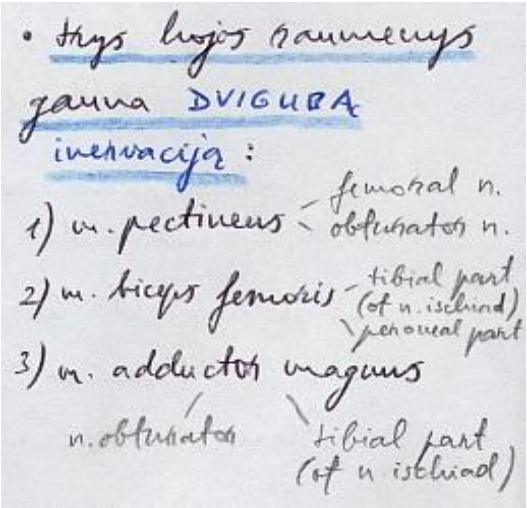

N. PERONEUS SUPERFICIALIS – mm. peronei longus and brevis.

eina membrana interossea prielyje, šalia a.v. tibialis ant.

N. PERONEUS PROFUNDUS

1) m. tibialis ant.
2) m. peroneus tertius
3) m. extensor dig. longus
4) m. extensor hallucis longus

tarp mm. extensores longi sausgysliu; palenda po m. extensor dig. brevis

1) I tarpupirščio dorsalinė oda L5
2) mm. extensores breves

- CREMASTER REFLEX (L_{1-2}) :

N. GENITOFEMORALIS

R. FEMORALIS (oda šlaunies lig. inguinale)

R. GENITALIS (m. cremaster)

- KNEE-JERK (PATELLAR) REFLEX (L_4) : aferentinė ir eferentinė dalys N. FEMORALIS

- MERALGIA PARESTHETICA – n. cutaneus femoris lateralis entrapped beneath lig. inguinale

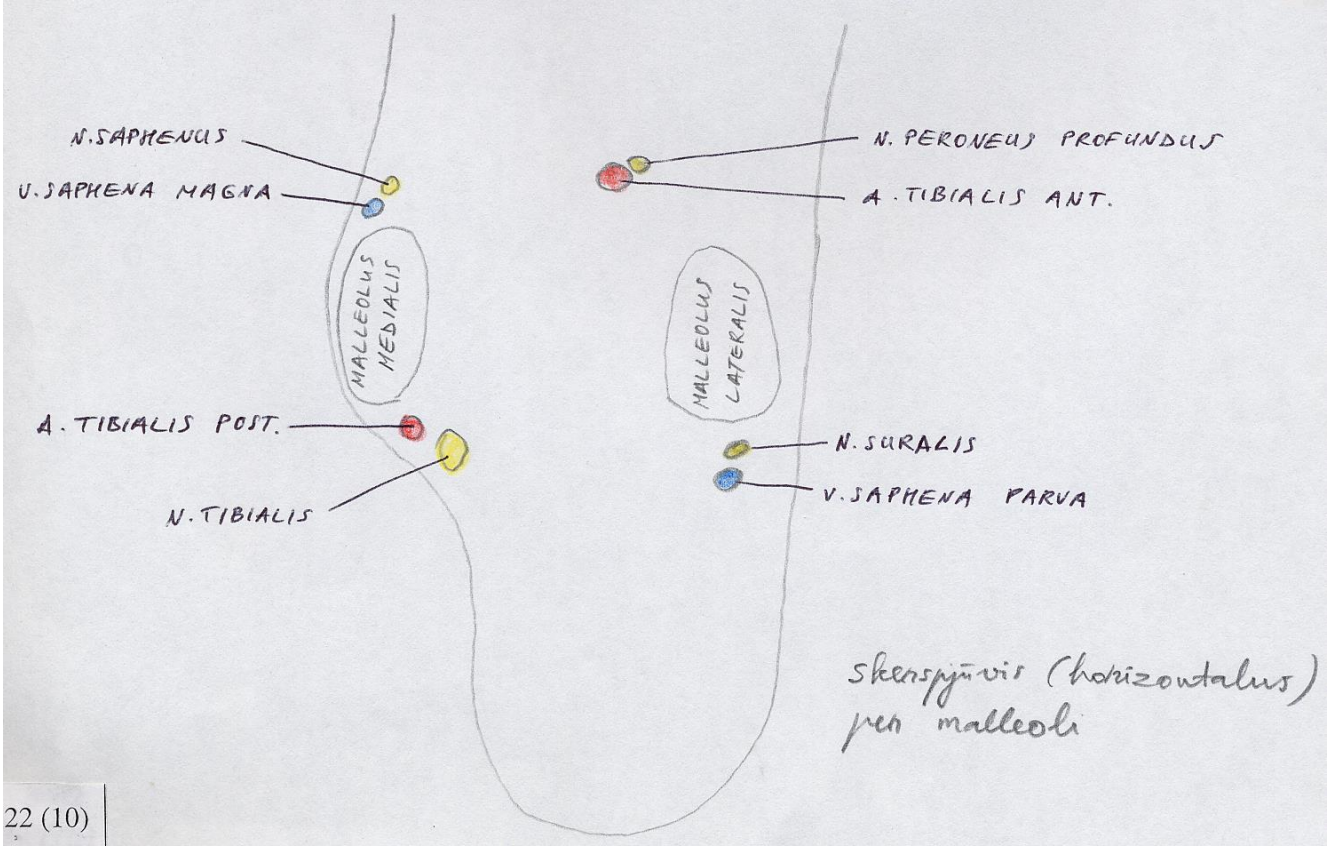

MYOTOMES – MOVEMENTS (LEG)

Root	Muscle	Action	Reflex
L_{1-3}	Iliacus (*femoral n.*) + psoas major (*anterior rami L1-3*)	Hip flexion (esp. L2)	**L1-2** – cremasteric reflex
L_{2-4}	Quadriceps (*femoral n.*) Thigh adductors (*obturator n.*)	Knee extension (esp. L3) Thigh adduction (esp. L4)	**L2-4** – knee DTR; ***femoral stretch test***
L_{4-5}	Tibialis anterior (*deep peroneal n.*)	Foot dorsiflexion (walk on heels) + inversion 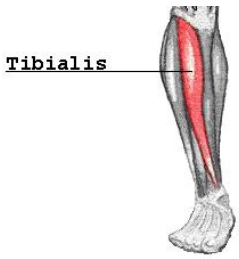	
L_5	Extensor hallucis longus + digitorum longus (*deep peroneal n.*) Tibialis posterior (*tibial n.*) Peronei (*superficial peroneal n.*)	Toe extension Foot inversion + plantar flexion Foot eversion	***straight-leg raising***
S_1	Gastrocnemius + soleus (*tibial n.*)	Foot plantar flexion (walk on tiptoes)	Achilles DTR; ***straight-leg raising***

	Extensor digitorum brevis (*deep peroneal n.*)	Toe extension	
S_{1-2}	Flexor digitorum longus & brevis (*tibial n.*)	Toe flexion	
S_{2-4}	Anal sphincter + bulbocavernosus (*pudendal n.*)	Anal sphincter	Anal sphincter, bulbocavernosus
L_4-S_2	Hamstrings (biceps, semi-) (*sciatic n.*) Gluteus maximus (*inferior gluteal n.*) Gluteus medius & minimus (*superior gluteal n.*)	Knee flexion Hip extension Hip abduction + internal rotation	

One posterior calf muscle gets L5 – posterior tibial (still via "normal nerve" – *tibial n.*)

Femoral nerve (L2-4) = hip flexion + knee extension

Sciatic nerve (L4-S3) = knee flexion + all muscles bellow knee

Common peroneal n. (L4-S2)

Tibial n. (L4-S3)

Toe extension (*deep peroneal n.* L5-S1) = extensor hallucis longus + digitorum longus & brevis

Toe flexion (*tibial n.* S1-2) = flexor hallucis longus + flexor digitorum longus & brevis

Foot plantarflexion (*tibial n.* L5-S2, mainly S1) = gastrocnemius + soleus + tibialis posterior

Foot dorsiflexion (*deep peroneal n.* L5 > L4) = tibialis anterior + EHL + extensor digitorum longus

N.B. foot drop is L5 / *deep peroneal n.*

Foot inversion (L5) – tibialis anterior (*deep peroneal n.*) + tibialis posterior (*tibial n.*):

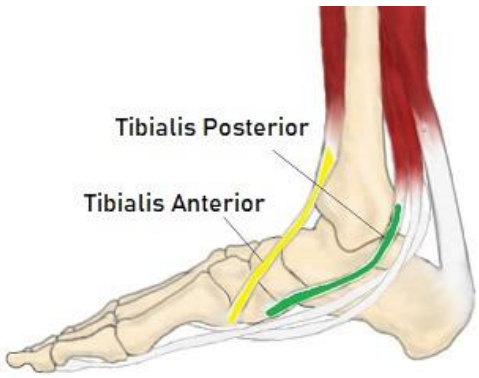

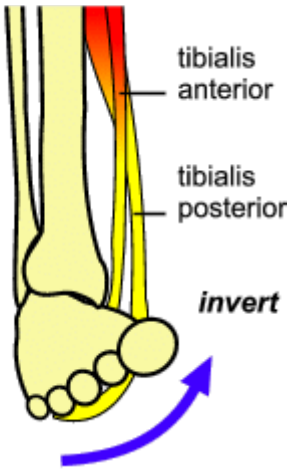

N.B. tibialis posterior is L5 (not S1) vs. gastroc and toe flexors are S1

Foot eversion (L5 – *superficial peroneal n.*) – three peronei:

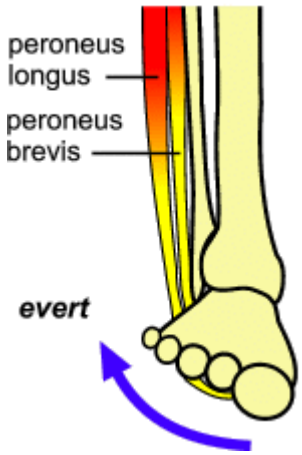

N.B. L5 affects both foot **inversion** and eversion (*deep peroneal n.* – only *partial inversion*; *superficial peroneal n.* – only eversion)

Kai jau baigsi ↑ lentele ir teksta, nukopijuok atgal i D1 p.

SENSORY

C1 – no such dermatome!
interaural line – border between C2 and n. ophthalmicus

C2 – occiput
C3 – neck, thyroid cartilage
C4 – clavicle, suprasternal notch
(**C3-4** – cape area)
C5 – below clavicle
C6 – 1st finger
C7 – 3rd finger
C8 – 5th finger

C4(5) abuts on **T2(1)**

T2 – axilla
T4 – nipple
T10 – umbilicus

L1 – inguinal (femoral pulse)
L2 – medial thigh
L3 – medial-anterior knee
L5 – big toe

S1 – little toe, lateral heel
S2 – popliteal fossa
S2-Cx converge on coccyx (bull's eye) not anus!

Reflex	Roots	
Ankle	S_1	"going from ankle to triceps, roots are
Knee	L_{2-4}	

Biceps	C_{5-6}	numbered consecutively from 1 to 8”.
Triceps	C_{7-8}	

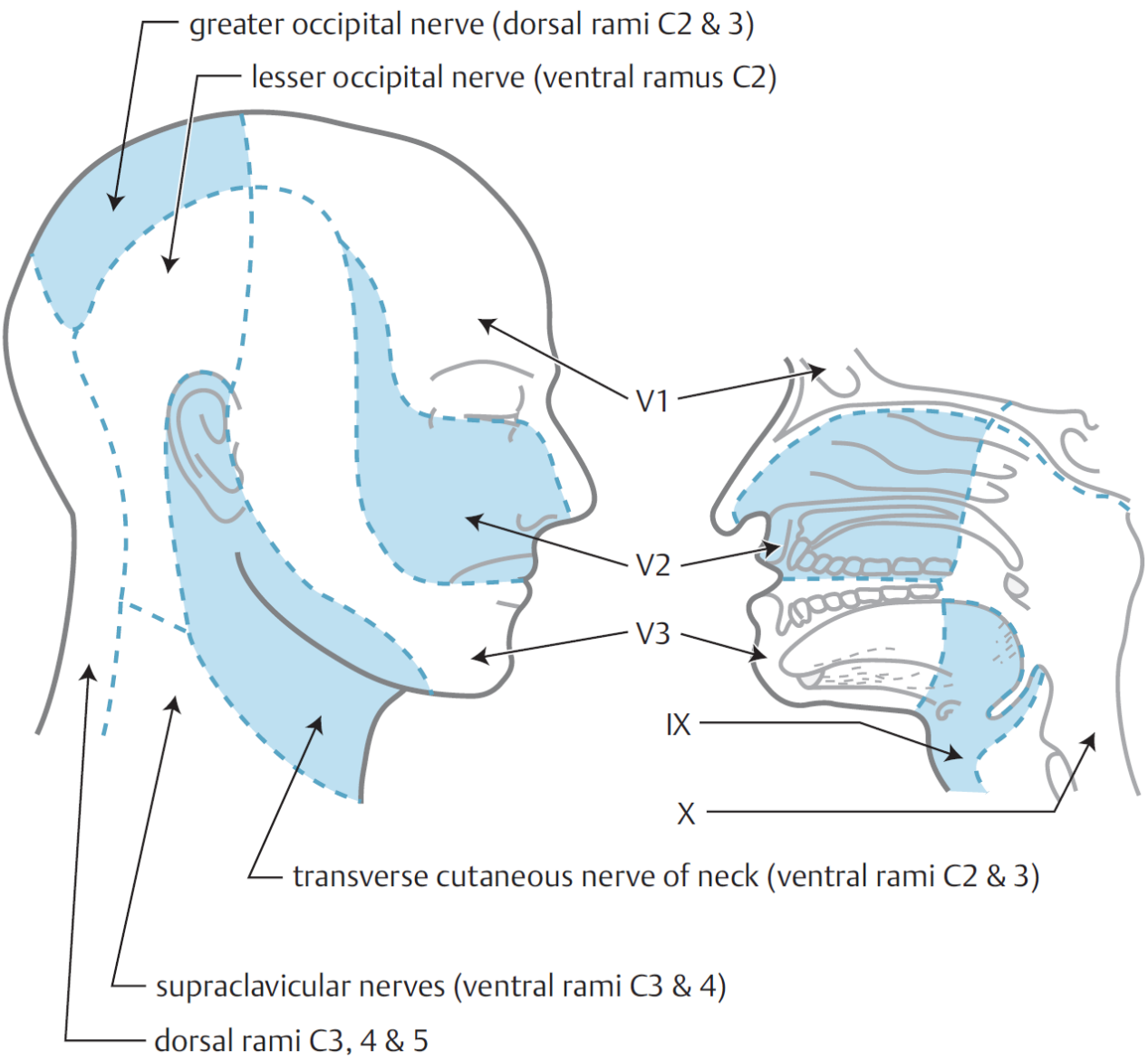

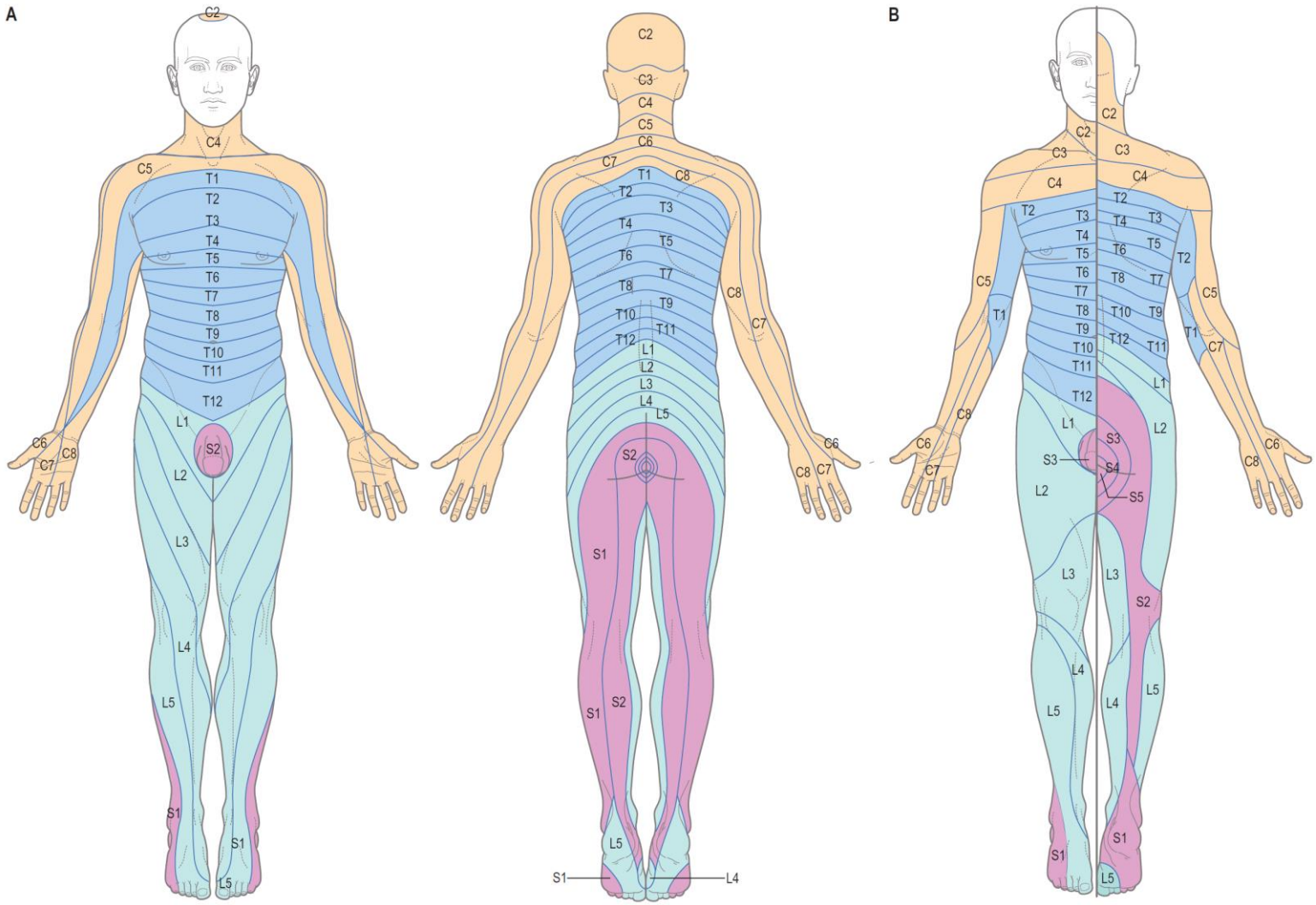
A
B
C2
C3
C4
C5
C6
C7
C8
T1
T2
T3
T4
T5
T6
T7
T8
T9
T10
T11
T12
L1
L2
L3
L4
L5
S1
S2
S3
S4
S5

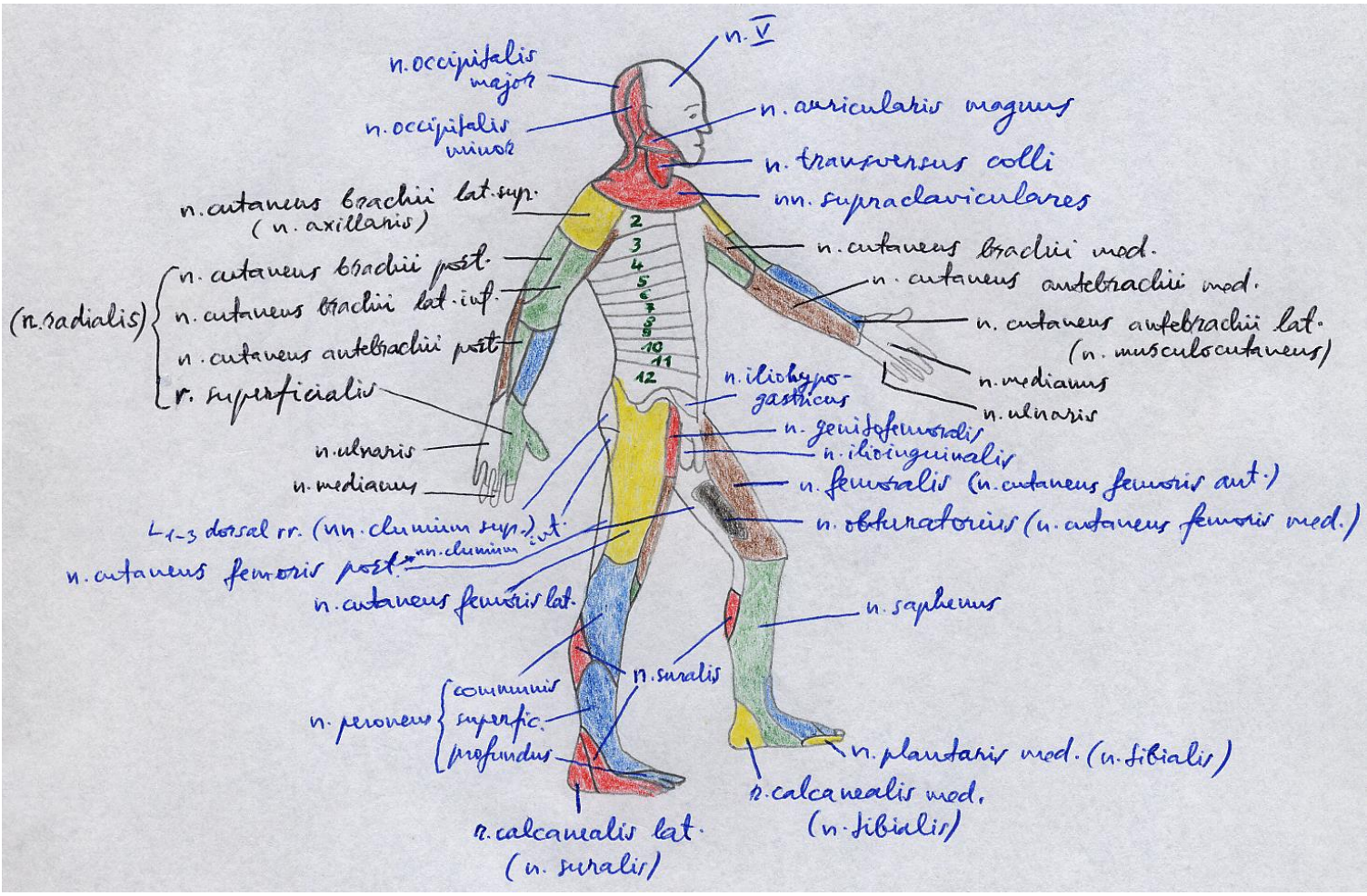
n. occipitalis major
n. occipitalis minor
n. V
n. auricularis magnus
n. transversus colli
nn. supraclaviculares
n. cutaneus brachii lat. sup. (n. axillaris)
n. cutaneus brachii post.
n. cutaneus brachii lat. inf.
n. cutaneus antebrachii post.
r. superficialis
(n. radialis)
n. cutaneus brachii med.
n. cutaneus antebrachii med.
n. cutaneus antebrachii lat. (n. musculocutaneus)
n. mediamus
n. ulnaris
2
3
4
5
6
7
8
9
10
11
12
n. iliohypogastricus
n. genitofemoralis
n. ilioinguinalis
n. femoralis (n. cutaneus femoris ant.)
n. obturatorius (n. cutaneus femoris med.)
n. ulnaris
n. mediamus
L1-3 dorsal rr. (nn. clunium sup.) nn. clunium inf.
n. cutaneus femoris post.
n. cutaneus femoris lat.
n. saphenus
n. suralis
n. peroneus
communis
superfic.
profundus
n. plantaris med. (n. tibialis)
n. calcanealis med. (n. tibialis)
n. calcanealis lat. (n. suralis)

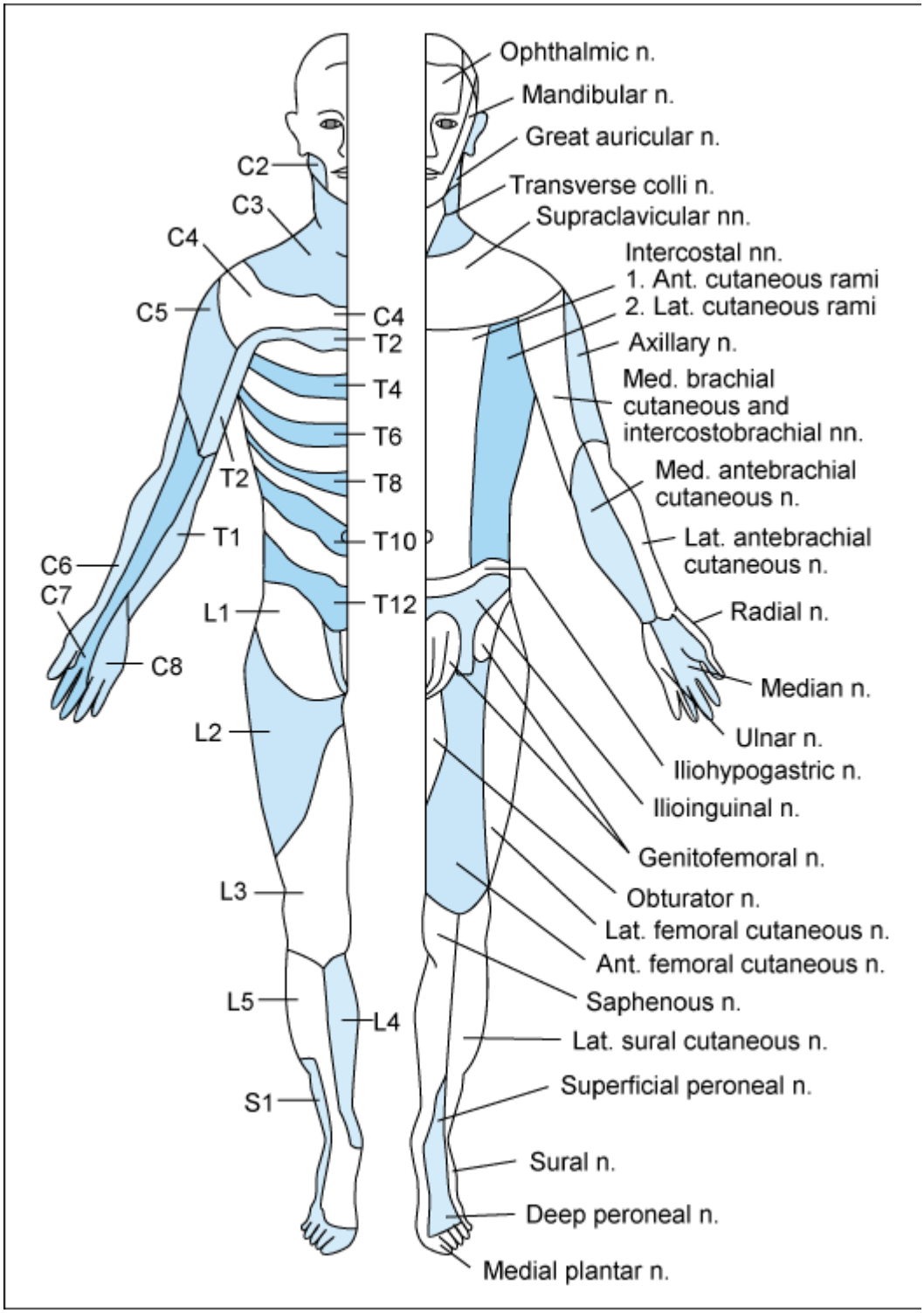
Ophthalmic n.
Mandibular n.
Great auricular n.
Transverse colli n.
Supraclavicular nn.
Intercostal nn.
1. Ant. cutaneous rami
2. Lat. cutaneous rami
Axillary n.
Med. brachial cutaneous and intercostobrachial nn.
Med. antebrachial cutaneous n.
Lat. antebrachial cutaneous n.
Radial n.
Median n.
Ulnar n.
Iliohypogastric n.
Ilioinguinal n.
Genitofemoral n.
Obturator n.
Lat. femoral cutaneous n.
Ant. femoral cutaneous n.
Saphenous n.
Lat. sural cutaneous n.
Superficial peroneal n.
Sural n.
Deep peroneal n.
Medial plantar n.
C2
C3
C4
C5
C6
C7
C8
T1
T2
L1
L2
L3
L5
S1
C4
T2
T4
T6
T8
T10
T12
L4

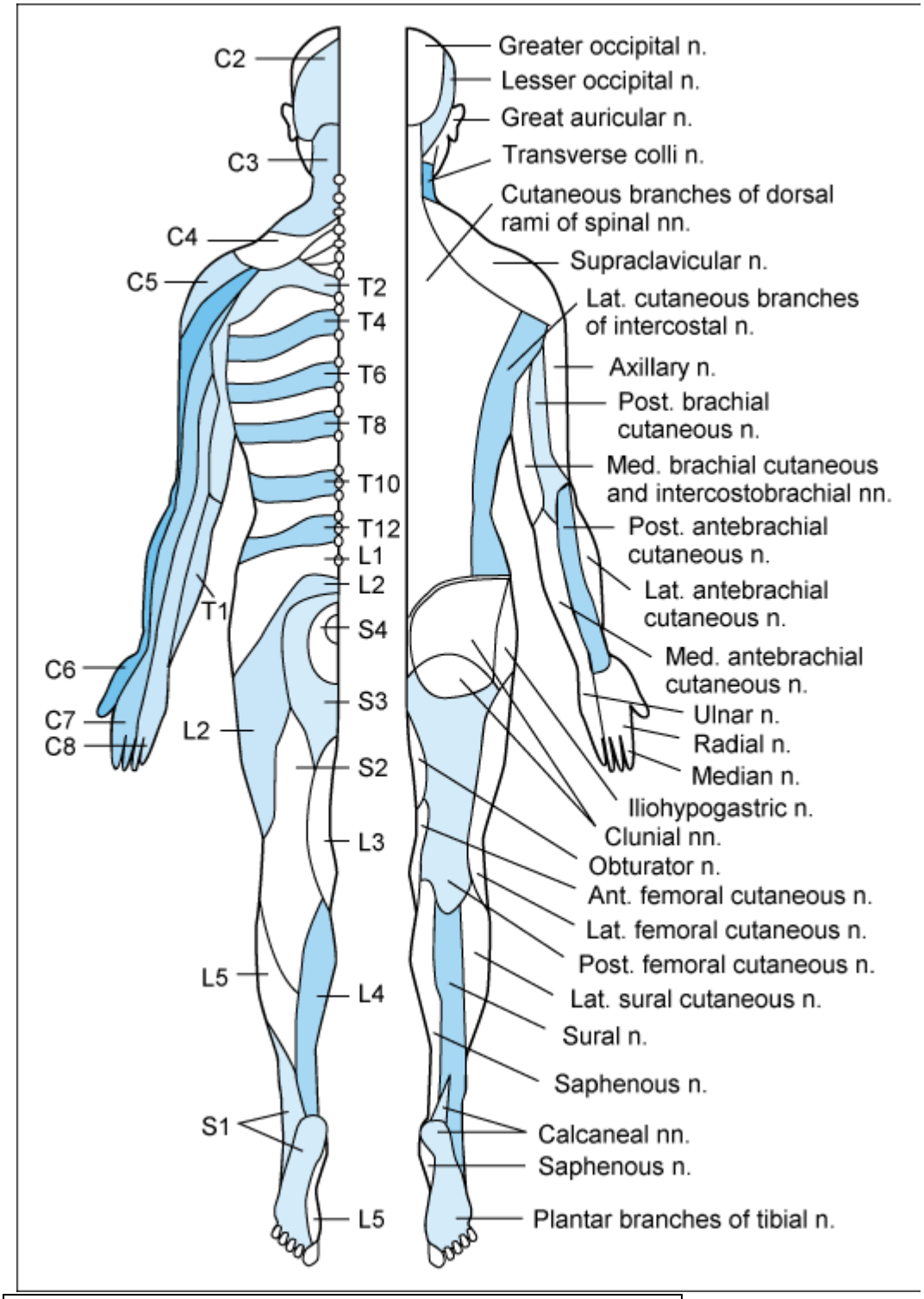

Ulnar nerve – palmar tip of 5th finger
Median nerve – palmar tip of 2nd finger + thenar
Radial nerve – dorsal aspect of skin web between 1st and 2nd fingers.
Tibial nerve – pėdos dorsolateralinis ir plantarinis paviršiai.
Peroneal nerve – pėdos dorsomedialinis paviršius.

PARESTHESIA - SPONTANEOUS abnormal sensation
DYSESTHESIA - abnormal sensations WHEN AREA IS TOUCHED

N.B. fasciculations are commonly experienced as benign phenomenon in absence of any disorder! Motor neuron disease never starts with fasciculations alone!

Lesion site	Romberg test		
	eyes-open	eyes-closed	eyes-closed tandem

fasc. gracilis et cuneatus			
cerebellar			
vestibular			

Peripheral nerves have much more precise sensory and motor borders (vs. dermatomes)
e.g. sensory loss at V and ulnar half of IV digit – ulnar neuropathy (not C8 radiculopathy)