ONCOLOGY (SPINE)

N.B. CSF removal (lumbar puncture) in presence of spinal tumor may worsen cord compression!

Spinal tumors:

extradural – 55%
intradural extramedullary – 40%
intramedullary – 5-10%

INTRAMEDULLARY

> 90% are *benign*

Frequency: EPENDYMOMAS (56-70%) > whole spectrum of ASTROCYTOMAS (30%; but 40-70% in children) > HEMANGIOBLASTOMAS > GANGLIOGLIOMA, OLIGO, DERMOID, EPIDERMOID, TERATOMA, LIPOMA

- 70% are associated with cysts (syrinx without trauma / Chiari → panspinal MRI w/wo)
- **developmental tumors** (dermoid, epidermoid [may be post LP], teratoma) - lumbar predominance, can be associated with spinal dysraphism and ***dermal sinus tract***
- **metastases** (unusual) – most commonly from *small cell lung carcinoma*

Conus tumors:

1) myxopapillary ependymoma
2) ganglioglioma

Cx: slowly (!) progressive Central Cord Syndrome (mimics syringomyelia); neurologic manifestations commonly ***begin unilaterally***

- dull, aching **back pain** characteristically at night.
- DEXTROscoliosis or torticollis can be first sign in kids!

Dx - image entire neuraxis – *multifocal*, *leptomeningeal dissemination (drop metastases)*!

- **MRI**: fusiform enlargement of spinal cord over several levels (vs. inflammatory lesions - normal or minimal increase in cord size) ± syrinx esp. with *EPENDYMOMA*, *HEMANGIOBLASTOMA* (vs. *ASTROCYTOMA* – cord edema)
  - enlarged vessels on cord surface (80% *HEMANGIOBLASTOMAS*, 10% *EPENDYMOMAS*)
- **angiography** - only if *HEMANGIOBLASTOMA* is suspected

- Rapid decline in leg function
- ?intradural or intramedullary lesion
- MRI not very definitive for tumor

- GET THE ANGIO

Rx: **DEXAMETHASONE** may improve neurologic function transiently.

Benign tumors → resection
Malignant tumors (poor prognosis despite treatment - radical surgery can lead to severe neurologic impairment) → radiotherapy
Currently, no satisfactory modality is available for malignant astrocytomas!

Biopsy - essential prior to nonsurgical treatment! (look for non-CNS biopsy site first - high risk of irreversible spinal cord damage – **biopsy is the last resort**!)

- in selected situations, watchful waiting can be considered (e.g. high surgical risk and/or mild neurologic dysfunction).

Surgical extirpation is treatment of choice for *benign tumors*! (cures have been reported only after complete surgical resections); no aggressive surgery for *high-grade tumors*!

Total removal with preservation of neurologic function!

N.B. if surgery is contemplated, better to operate early – outcome depends on preop neurological status – do not wait until myelopathy! (although COMPLETELY asymptomatic patients may be watched closely)

Neurological deficits preop correlate with poor outcome postop – do not delay surgery!

SURGERY PRINCIPLES

Preoperative

- perioperative **steroids** (start 24 h prior to surgery; begin tapering 3-5 days after surgery).
- baseline ***urodynamic studies***!
- do preop ***VA balloon occlusion test*** if anticipate vertebral artery sacrifice; if VA is nondominant, one may consider sacrificing (e.g. coiling) VA preop.

Intraop

- MAP > 85
- **IONM** (incl. D-wave, EMG of extremities + anus + bulbocavernosus reflex for conus tumors) + TIVA

  EMG, bulbocavernosus reflex – "lost or retained"
  SSEP, MEP, D-wave – decrease by 50%

Intraop alterations in evoked potentials - see "Intro (neuro - clinical).pdf"

- depending on tumor location – either laminectomy* (posterior approach) or corpectomy (anterior approach) *Dr. Jallo does **laminoplasty** for all adults (esp. true for kids)
- tumor is localized with ***intraoperative ultrasound*** or ***spinal stereotaxy***.

  Always use US to guide durotomy!
- ***perfect hemostasis*** before opening midline durotomy

  N.B. be mindful of *potential adhesions of the spinal cord or vascular structures* to the undersurface of the dura
- cord can be released by *cutting the dentate ligament bilaterally*

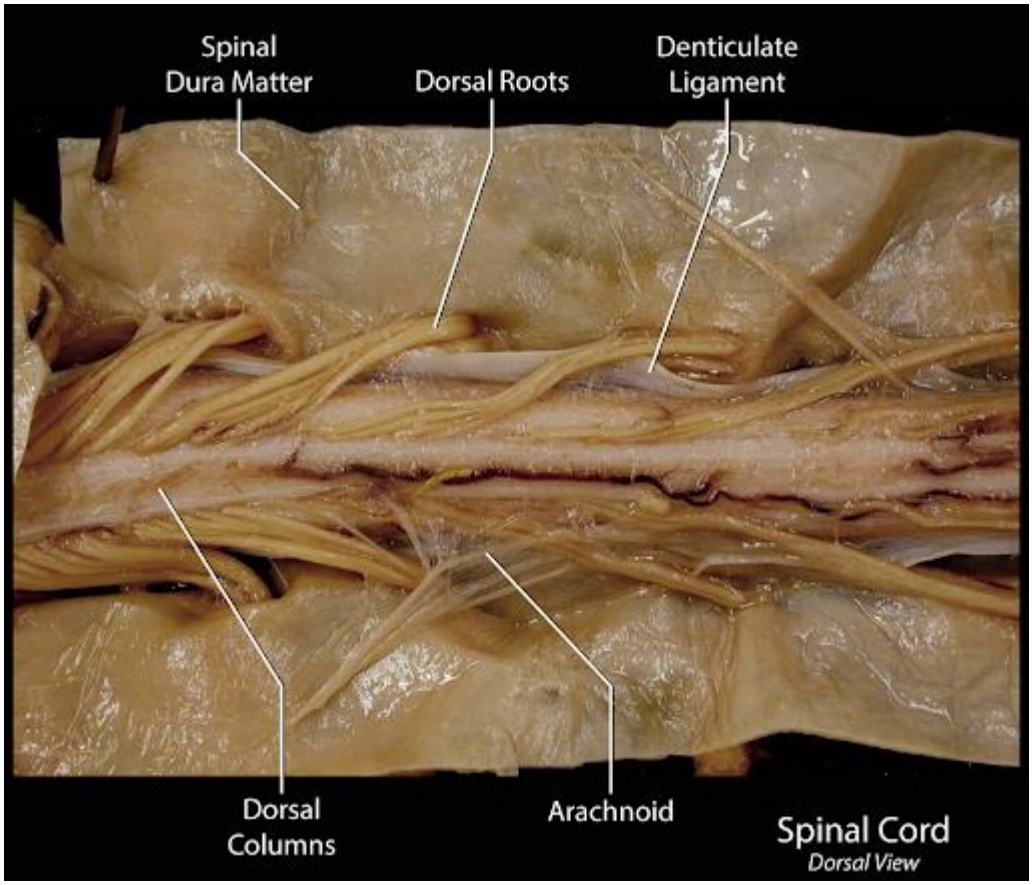

- midline myelotomy (*electrical mapping* of the posterior columns - stimulate with bipolar fork where it is safe to cut).
    - use *#11 blade* or *16G needle*
    - under microscope, linear* midline** myelotomy at thinnest area between tumor and spinal cord - visualize adjacent normal cord and follow midline raphe across the tumor (some tumors may be growing further in one hemicord than the other and may actually rotate or shift the dorsal midline); dorsal median vein is another landmark.

      *to spare vertically running white matter tracts.

      **between the sensory fibers
    - eccentric lesions may be approached through posterior intermediate sulcus or dorsal root entry zone (posterolateral sulcus):

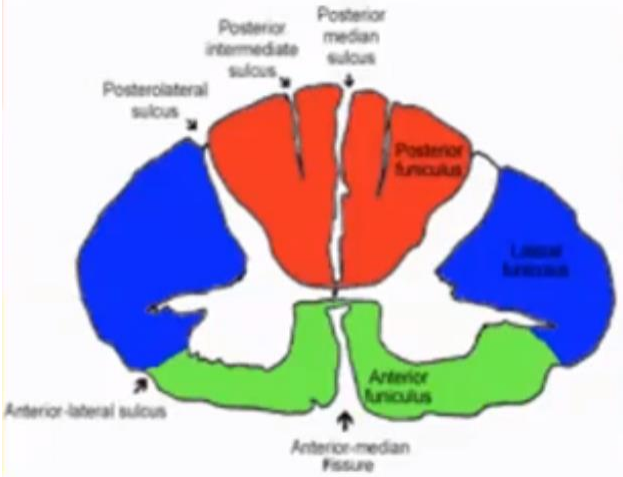

    - if tumor has exophytic component, this is initial area of approach (pia mater is opened directly over tumor), i.e. debulk any exophytic component prior to addressing tumor located within parenchyma.
    - **dorsal vasculature** is saved by dissecting it from the pia and rotating it to one side of the spinal cord.
        - blood vessels crossing the dorsal midline or penetrating into the dorsal midline are coagulated with fine bipolar forceps on the lowest coagulation setting – do

it in strict midline! Dr. Jallo cautions to minimize coagulation until cord is opened.

- 7-0 Prolene stitches (to keep myelotomy open) suturing edge of pia* to edge of dura (may place vascular Weck clips instead of tying knots).
  *Dr. Jallo recommends no pial stitches (so cord can relax in areas where surgeon is not working)
- traction on the cord should be avoided and kept to a minimum at all times.
- for vascular tumors (e.g. hemangioblastoma) first need to control* feeders – bipolar them first, then resect tumor.
  *some experts recommend intraop ICG angiography to find feeding vessels; ependymomas have ventral feeders from anterior spinal artery

- send frozen: for biopsy-proven high-grade/malignant* lesions, only biopsy and dural patch graft (to enlarge space for spinal cord) (→ radiotherapy) (but safe debulking is recommended).
  *rapid progression even after aggressive resections
  N.B. wait for frozen pathology before proceeding with resection (astrocytoma – do not do aggressive resection!)
  - if pathologist is not sure of diagnosis, better stop and come back for a second operation rather than to hurt the patient.
- nonvascular tumors can be removed in piecemeal fashion (vascular tumors – en bloc)
- try to find **cleavage plane** to dissect (Rhoton dissectors) tumor around; may start where cyst is – better definition of plane.
- tumors tend to be avascular and may have true capsule (or definable plane).
  - if ill-defined plane is present, risk-to-benefit ratio for aggressive removal is not clear (e.g. developmental tumors can be quite adherent to spinal cord).
- debulking instruments: NICO Myriad side-cutting dissector, Cavitron ultrasonic surgical aspirator (CUSA), fine-tipped contact laser (CO_2, KTP).
- for hemostasis use *irrigating bipolar* cautery (e.g. MALIS)

N.B. extent of resection must be based on combination of presence of **plane-of-dissection** and intraoperative **monitoring** data; plus, surgeon's **experience** and patient's **wishes**!!!

- any **cysts/syringes** should be drained, septations divided (spinal cord pulsations demonstrating adequate decompression are monitored).
- when operating on tumors of *conus medullaris*, filum terminale should probably also be removed.
- defect in *neural tissue* does not need to be closed (Dr. Spetzler); alternative - approximate myelotomy edges with Prolene (but leave gaps – to prevent intramedullary hematoma).
- watertight *dural* closure (may use dural grafting*).
  *esp. if unable to totally resect tumor – duraplasty gives room and time
  - irrigate intradurally – leave no blood.
  - simple running 4-0 silk / 5-0 Prolene suture (Hemo-Seal (HS-7) needle)
  - Valsalva maneuver → layers of Surgicel + DuraSeal / Tisseel / Adherus
- place drain above muscles (to avoid pulling CSF).
- consider instrumentation to prevent postoperative kyphosis.
  - Dr. Jallo avoids it during original surgery to avoid hardware artefacts on MRI.

Check postop PVR → catheterize PRN
Bladder function – preop and postop!

HOLOCORD TUMORS

- typically, low grade tumors.

- Dr. Jallo operates on upper end of tumor (to decompress arm area) and then chemoradiation for the rest of tumor.

POSTOP

- ICU for 24-48 hours.
- postop flat for 1-3 days; then sleep prone (potential for late scarring of pia to dura with a tension injury to the spinal cord).
- *cervical tumors* → continued **mechanical ventilation** in immediate postoperative period.
- *majority of patients have increased deficit* during immediate postoperative period (edema from surgical manipulation, blood flow alteration) - typically transient and most return to baseline within 3-6 months.
- new-onset urinary retention may require prolonged **bladder catheterization**.
  - *tumors around conus*, counsel preop to expect home with catheter (or straight catheterization for several weeks)
- lifelong follow-up MRIs.
- residual / recurrent tumor:
  a) repeat resection (for ependymoma)
  b) radiotherapy (for astrocytoma)
  c) watchful waiting (e.g. developmental tumors, lipomas - prolonged survival despite residual tumor).

PROGNOSIS

1. **Histology** (aggressive tumors have poor prognosis despite treatment - radical surgery can lead to severe neurologic impairment).
2. **Preoperative deficit** - those with *advanced neurologic compromise* generally have no worthwhile improvement.
3. **Completeness of resection**

SPECIFIC TUMOR TYPES

EPENDYMOMA

- clear cleavage plane - complete excision is possible – try to **resect en bloc**

Ependymoma of distal spinal cord:

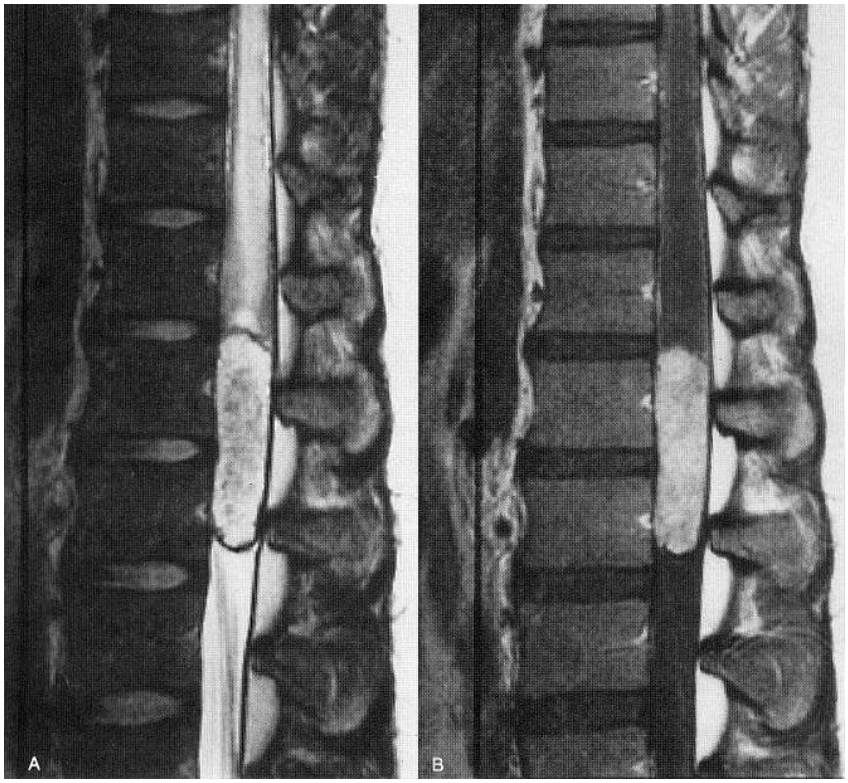

- surgically excised ependymomas need not undergo subsequent radiotherapy! (if residual tumor → **second look surgery** vs **adjuvant panspinal radiation)**
- recurrence may be delayed for as long as 19 years! (never stop follow-up MRIs)

MYXOPAPILLARY EPENDYMOMA

- *big tumors may seed CSF space* – try to **resect en bloc → adjuvant panspinal radiation**

N.B. in WHO 2021, myxopapillary ependymoma is now grade 2 – as likelihood of recurrence is similar to conventional spinal ependymoma.

Myxopapillary ependymoma - cells around papillations that have myxoid connective tissue core:

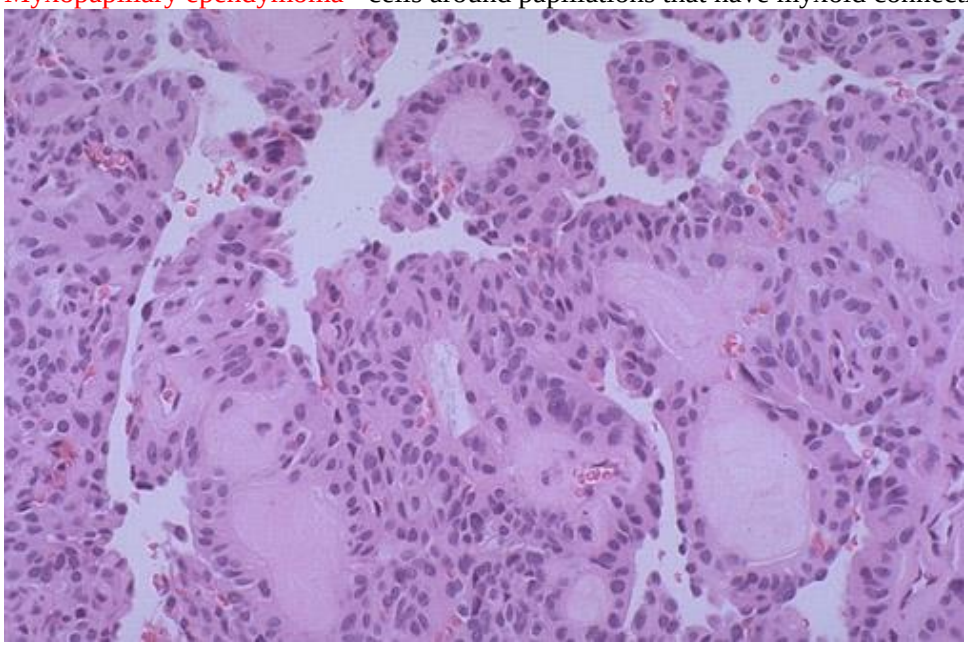

ASTROCYTOMA

- most common intramedullary tumor in pediatric group!

- *PILOCYTIC ASTROCYTOMA* with definable surgical plane – *possible to remove surgically*.
- other *LOW-GRADE ASTROCYTOMAS* - *infiltrative and impossible to remove grossly* (but residual tumor often has indolent course).
- *ANAPLASTIC ASTROCYTOMA*, *GLIOBLASTOMA* are rare; may seed CSF; *surgery does not improve course*! - death within 2 years.

Glioblastoma (T1-MRI): Pilocytic astrocytoma (contrast T1-MRI):

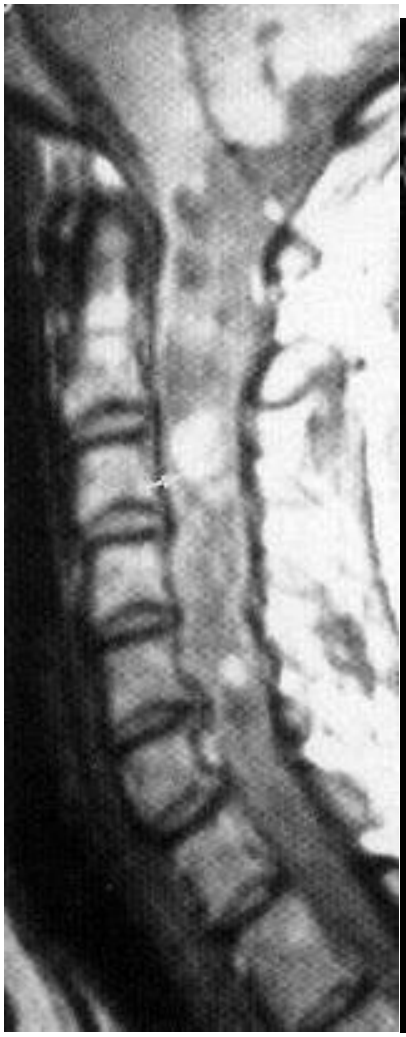

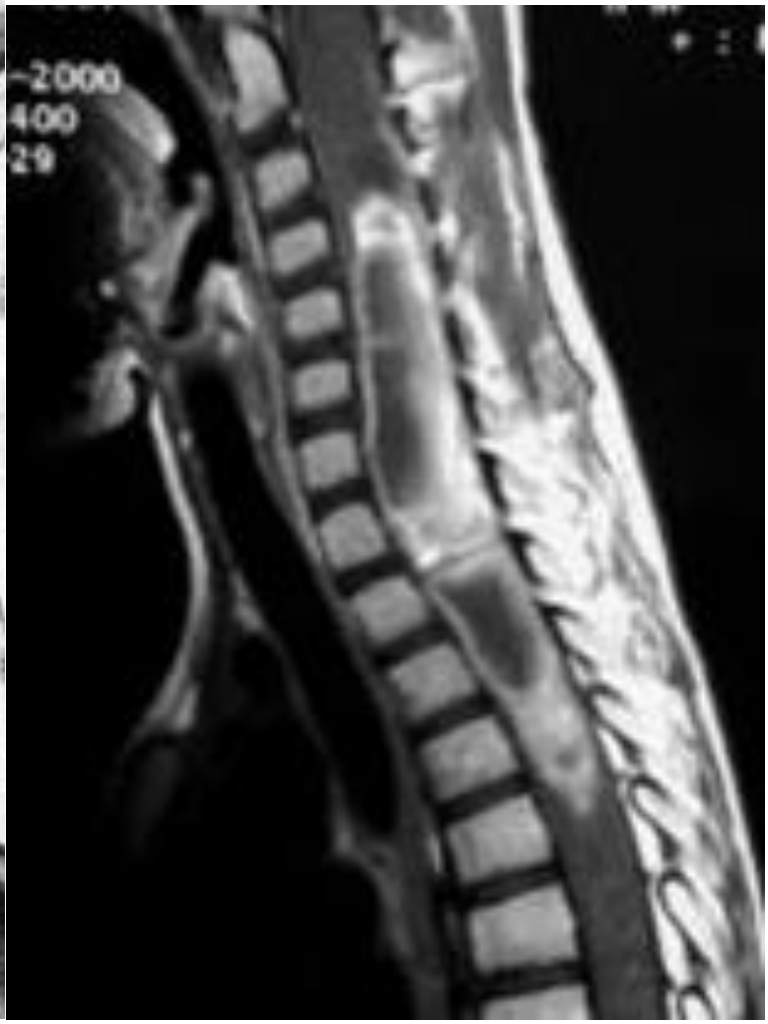

HEMANGIOBLASTOMA

- associated with von Hippel-Lindau disease in 30-80% cases.
- cyst with tumor nodule (50-70%) - ***enhances strongly***
- characteristic angiography - dense capillary blush, supplying arteries are slightly enlarged.
- can be cured by **surgical excision**
  - surgical principles similar to AVMs - feeding arteries are coagulated, and tumor is dissected and *removed en bloc* (do not remove in piecemeal fashion - significant bleeding may ensue!).
  - neuromonitoring has low value – surgery should be guided by tissue plane and tumor has to come out!

BEVACIZUMAB – for surgically unresectable cord **hemangioblastoma**.

Contrast MRI - enhancing hemangioblastoma in conus medullaris:

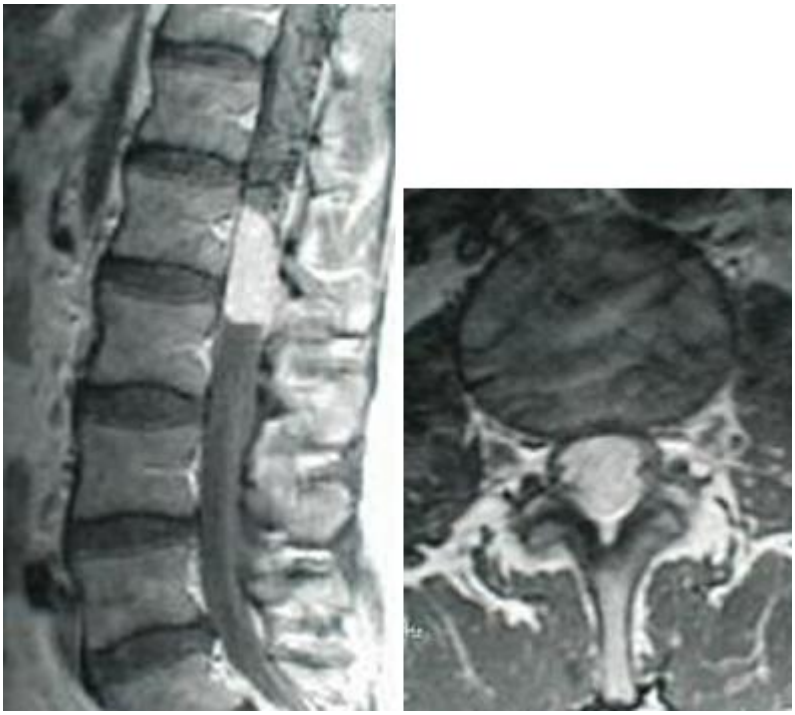

DEVELOPMENTAL TUMORS [EPIDERMOID, DERMOID, TERATOMA]

- can be associated with spinal dysraphism and ***dermal sinus tract***.
- *avoid operative spilling* of (epi)dermoid content (→ inflammation, arachnoiditis, adhesions).

LIPOMA

- not true neoplasm!

- often associated with ***spinal dysraphism*** and ***cutaneous abnormalities***
- loss of total body fat may be necessary to reduce tumor mass.
- fibrous adhesions to cord, no distinct cleavage plane make total removal difficult.
  N.B. removal is not goal of surgery (CO_2 laser is particularly useful); goal – de-tethering of cord, decrease mass effect

METASTASES

- **surgery** is recommended for solitary metastasis and limited cancer (can be completely resected through definitive cleavage plane).

LYMPHOMA

- treatment:
  1) if imaging is suggestive of spinal cord lymphoma → collect sample of CSF → promptly start STEROID → marked improvement in symptoms and a dramatic reduction of lesion size on imaging.
  2) high dose IV **chemotherapy** – mainstay as all reported case achieved full remission.

MAIN DIFFERENTIAL

MS >>
incl. tumefactive multiple sclerosis

Devic disease >>

(Acute) transverse myelitis >>

Cord infarct >>

Subacute combined degeneration of the cord >>

INTRADURAL EXTRAMEDULLARY

- most are benign (vs. epidural tumors).

Frequency: NEUROFIBROMAS > SCHWANNOMAS > MENINGIOMAS > MTS (systemic, drop), LIPOMA, DERMOID, EPIDERMOID, TERATOMA

Cx: *RADICULOPATHY* (esp. nerve sheath tumors – typically arise from dorsal roots) → Extramedullary Cord Compression → complete spinal cord transection

Dx: MRI – most enhance brightly
- enhancing tumor with both *intradural* and *extradural* components ("hourglass" with foramen expansion) is most likely nerve sheath tumor!
- *calcification* is rare (heavily calcified intraspinal mass is usually extruded disc material).
- **CSF** – cytology is key diagnostic test for *LEPTOMENINGEAL METASTASES* - not treated surgically!

Rx: **DEXAMETHASONE** may improve neurologic function transiently
Benign tumors → resection
Metastases → radiotherapy
Angiography is performed for surgical planning if tumor is in lower thoracic region – ***to locate artery of Adamkiewicz*** – must be preserved during surgery (supplies spinal cord!).
- sectioning of dentate ligament ensures access to tumor; dorsal roots can also be sectioned.
- excise involved **nerve root*** (*NEUROFIBROMA*, *SCHWANNOMA* – almost always originate from sensory rootlets - stimulate and cut). *frequently nonfunctional at time of surgery
- even ***ventral meningiomas*** likely to be excised via posterior approach (up to costo-transversectomy, no need for instrumentation) – tumor tends to be excentric (check axial images) – cut dentate ligaments and dorsal rootlets to allow gentle cord rotation but cord retraction can be detrimental!
  vs. ***ventral extra-dural tumors*** need anterior spinal approach with instrumentation

N.B. spinal meningiomas have lower recurrence rates (than cranial meningiomas) – do not resect dura but rather do watertight dural closure!

EXTRADURAL / VERTEBRAL

Common distribution of spine lesions:

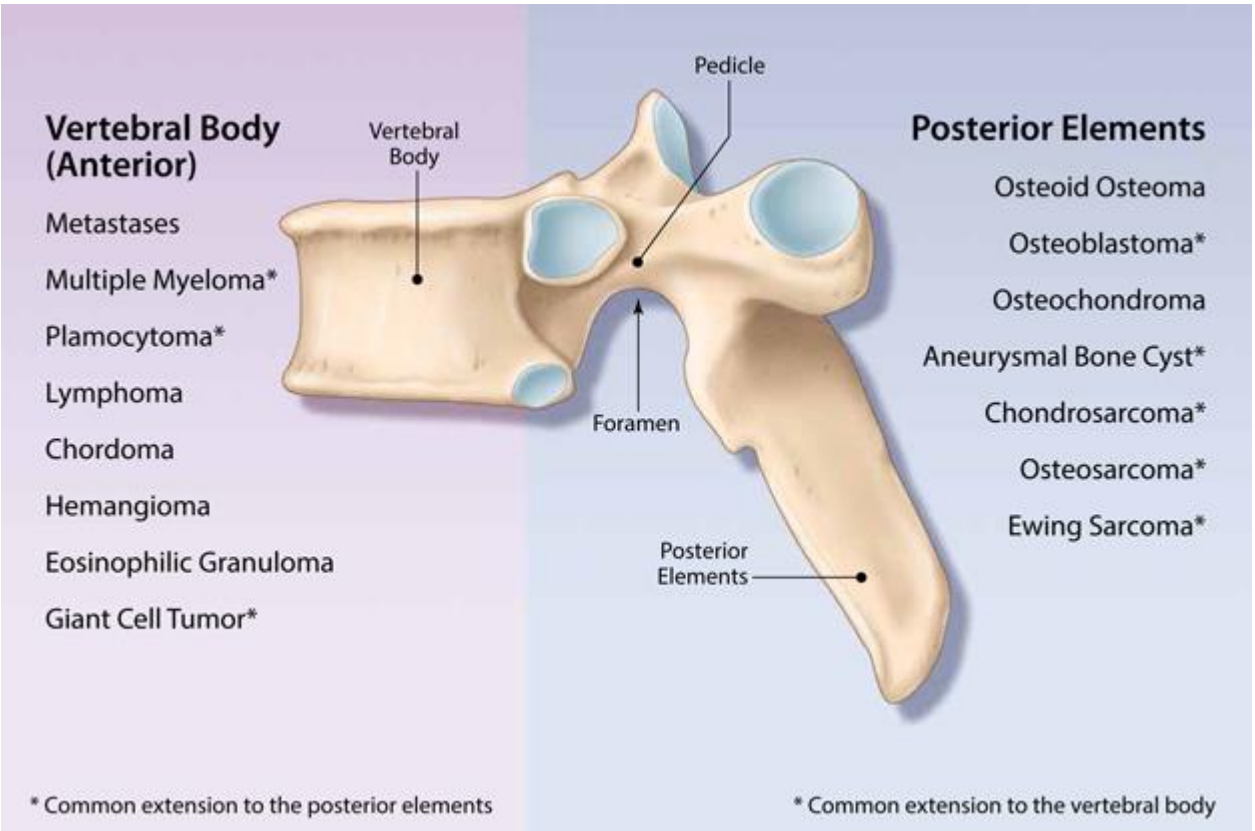

N.B. neoplastic disease often presents with back pain indistinguishable from benign causes!

Worsening constant focal **back pain** *unresponsive to rest* → rapidly progressive Extramedullary Cord / Root Compression

- pain usually precedes the development of neurologic symptoms by several weeks or even months.

CORD COMPRESSION

Rx: emergent **DEXAMETHASONE** (10-100 mg IV → 4-24 mg q6h) or METHYLPREDNISOLONE in Bracken protocol

Benign tumors → resection

Malignant tumors, metastases → radiotherapy

- indications for **surgical decompression**:
  1) cord compression worsens despite radiotherapy (or maximum tolerated dose of radiotherapy has been delivered previously to site)
  2) bony compression (e.g. vertebral fracture) contributes to cord compression.
- paraplegic patients are rarely operated on because of significantly low rate of recovery, particularly after 24 hours.

N.B. *laminectomy (removal of posterior elements) might be harmful* in anterior compression cases:

1) does not remove tumour - does not result in immediate decompression.
2) can cause destabilization because often only the posterior elements are intact and removal of these elements causes instability (at least add pedicle screws).

- surgery is followed (> 2 weeks after surgery - to prevent dehiscence) by radiotherapy

---

Decompressive surgery + radiotherapy vs. radiotherapy alone for metastatic spinal cord compression – class I evidence.

Patchell RA et al. Direct decompressive surgical resection in the treatment of spinal cord compression caused by metastatic cancer: a randomised trial. Lancet 2005.

- randomised, multi-institutional, non-blinded trial:

50 patients – surgery (***immediate direct circumferential decompression***) + XRT within 14 days
51 patients - XRT alone

- significantly more patients in surgery group than in XRT group were able to walk at 3 months after treatment (odds ratio 6.2 p=0.001) and retained ambulation significantly longer (122 vs. 13 days).

Critique:

1) study used conventional XRT (e.g. renal cell carcinoma is radioresistant); modern radiotherapy (SRS) is much more powerful.
2) study excluded highly radiosensitive tumors where results of XRT may be more comparable to surgery.

WORKUP

Multimodal imaging studies is mandatory for evaluation of spinal tumors and surgical planning!

Metastatic work up → biopsy → embolization

1. **Panspine MRI**

- disc space is not involved (if yes, **infection** is more likely).
  - ***contrast-enhanced fat-suppressed T1-MRI*** (differentiates contrast enhancement from bone marrow fat) and especially ***STIR*** provide exquisite sensitivity for pathology within vertebral bodies.
  - super bright STIR – suspect vascular tumor (hemangioma, angiosarcoma, etc).

2. **Chest-abdomen-pelvis CT**
3. **Whole body FDG-PET** (not all tumors appear "hot")
   vs. bone scans (99mTc-MDP) are low resolution and low specificity (overlap with inflammatory conditions)
4. **Biopsy** (transpedicular) - ultimate way to make diagnosis (unnecessary in patients with known preexisting cancer or if other biopsy sites* / diagnostic methods** available); hold steroids prior to biopsy due to oncolytic effect (unless cord compression requires steroids)
   *e.g. lung mass
   **e.g. multiple myeloma laboratory diagnosis and bone marrow biopsy.

Avoid going to surgery without knowing diagnosis (biopsy role is paramount* in **primary tumors**** and in **metastases with unknown primary***)

*if acuteness of neurologic status permits
**some may need neoadjuvant treatment, some may not need aggressive resection; plus, avoid radiographic mimickers that do not need surgery at all (tumor radiologically appearing as osteosarcoma could be hemangioma; tumor radiologically appearing as chordoma could be schwannoma)
***need to know radiosensitivity (choose XRT modality), the need to embolize preop

N.B. for primary tumors, choose biopsy tract so it is resectable within definitive surgical approach!

Primary tumors showing good results with neoadjuvant **chemotherapy** (thus, need biopsy):

1. **Osteosarcoma** – cisplatin, ifosfamide, bleomycin, actinomycin D, and alfa-interferon
2. **Chordoma** – tyrosine kinase inhibitors
3. **Ewing sarcoma**

If surgery is indicated → spinal preoperative **angiography**:

1) localizing artery of Adamkiewicz
2) delineation & ***embolization*** of vascular tumors - *METASTATIC* (renal cell, thyroid, hepatocellular, germ cell, neuroendocrine), *HEMANGIOMA*, *HEMANGIOBLASTOMA*, *ANEURYSMAL BONE CYST*, *MULTIPLE MYELOMA* and *PLASMACYTOMA* → surgery within a day or so.
   - ***trial occlusion*** of larger radiculomedullary arteries
     e.g. vascular supply directly from the vertebral artery → 20-minute trial balloon occlusion with serial neurologic examination - if patient remains asymptomatic, vessel may be sacrificed, significantly reducing both hemorrhage and the risk of intraoperative neurologic decline

N.B. > 60% of spinal metastases, 40% of benign and 85% of malignant primary spinal neoplasms are hypervascular – either attempts of radical surgery or surgery with tumors extending into paraspinal tissues – risk of life-threatening bleeding (up to 6 liters EBL)

- other risk factors of hypervascularity – purely lytic, rapidly growing, large-flow voids / avidly enhancing on MRI.
- embolize segmental arteries 4-5 levels below and above pathology; tumor has to be casted for embolization to be effective.

Surgical decision-making is based on two features:

1. **Neurological symptoms**, s. cord compression – ESCC (Bilsky) score
2. **Spine stability** – SINS score

± **Intractable back pain** (despite brace + medications) - indication for radiotherapy or thermal ablation → vertebral augmentation

Three types of spine pain:

1. **Local (biologic, oncologic) pain** – caused by tumor growth (periosteal stretching + tumor-induced inflammation): aching, deep during the night (endogenous steroids↓) and improving with activity; elicited by palpation over the posterior spinal elements. H: **NSAIDs, corticosteroids, opioids, XRT, vertebral augmentation**
2. **Mechanical pain** – caused by fracture, instability: variable with position and movement, unresponsive to NSAIDs and corticosteroids. H: **brace, surgical stabilization**.
3. **Radicular (neuropathic) pain** - caused by direct tumor compression of nerve roots: sharp, shooting. H: GABAPENTIN, tricyclic antidepressants, lidocaine patch, opioids.
   - obtain input from pain management specialists.
   - ***neurosurgical ablations*** (rhizotomy, spinothalamic tractotomy, cordotomy) are not commonly used in spinal metastases.

Multidisciplinary approach - NOMS

NOMS, neurologic (N), oncologic (O), mechanical (M), and systemic (S) disease flowchart:

1. **Neurologic** category takes into consideration *radiographic* findings such as epidural spinal cord compression, as well as *clinical* findings such as myelopathy – ESCC score >>
2. **Oncologic** category accounts for:
   1) tumor histology (may add – ***genotyping*** and ***molecular profiling*** of primary tumor).
   2) sensitivity to radiation and whether received radiation to this area before.
3. **Mechanical instability** accounts for spinal instability and fractures – SINS score >>
4. **Systemic disease** - overall metastatic disease burden – survival, overall prognosis.
   N.B. *oncologists very often cannot predict life expectancy* (as many patients with spine mts were excluded from trials so nobody knows how they will fare); more important is to discuss and see patient's perspective for treatment goals!

If surgery is considered, last question remains – **can patient tolerate surgery**?

- prerequisite - **life expectancy** > **3** (or 6) months
  < 3 months – only palliative pain control measures

Do not forget the role of preoperative embolization in vascular tumors*!

*blood loss usually liters

- use TXA; avoid CellSaver.

Modern indications for surgery in spine metastases – **instability** or **neuro when radiation is not feasible**:

a) *Symptomatic* (e.g. acute paraplegia) *high-grade* (Bilsky grade 2-3) cord **compression** with:
   i. bone / disk fragments - radiation is ineffective (as opposed to radiosensitive tumor tissue – can be treated with XRT) → **decompression**
   ii. radioresistant histology (e.g. melanoma, RCC, sarcomas) – need for SRS but risk for cord → **separation + perc stabilization**
   iii. previous radiation → **decompression**

b) Spinal **instability** **(SINS scale ≥ 7 points)** → restoration of alignment, **stabilization**

Historic indications

1) **uncertain diagnosis** that requires tissue diagnosis (now replaced by biopsy)
2) **single** lesion and no systemic disease → spondylectomy

- spondylectomy / en bloc resections are not anymore indicated (as opposed to primary vertebral tumors); corpectomy with cage support (or vertebral augmentation with cement via Jamshidi needle) can be done if needed for structural support in solitary metastasis.

N.B. ***tumor radiosensitivity does not affect surgical decision making*** (i.e. radiosensitive tumor with SINS ≥ 13 needs operative stabilizations vs. more favorable SINS → brace + radiotherapy)

BILSKY CLASSIFICATION - EPIDURAL SPINAL CORD COMPRESSION (ESCC) SCORING

- 6-point system:

Low grade – no cord deformation

Grade 0 - bone-only disease.
Grade 1a - epidural impingement, without deformation of the thecal sac.
Grade 1b - deformation of the thecal sac, without spinal cord abutment.
Grade 1c - deformation of the thecal sac with cord abutment, but without cord compression.

High grade – cord compression:

Grade 2 - spinal cord compression, but with CSF visible around the cord.
Grade 3 - spinal cord compression, no CSF visible around the cord.

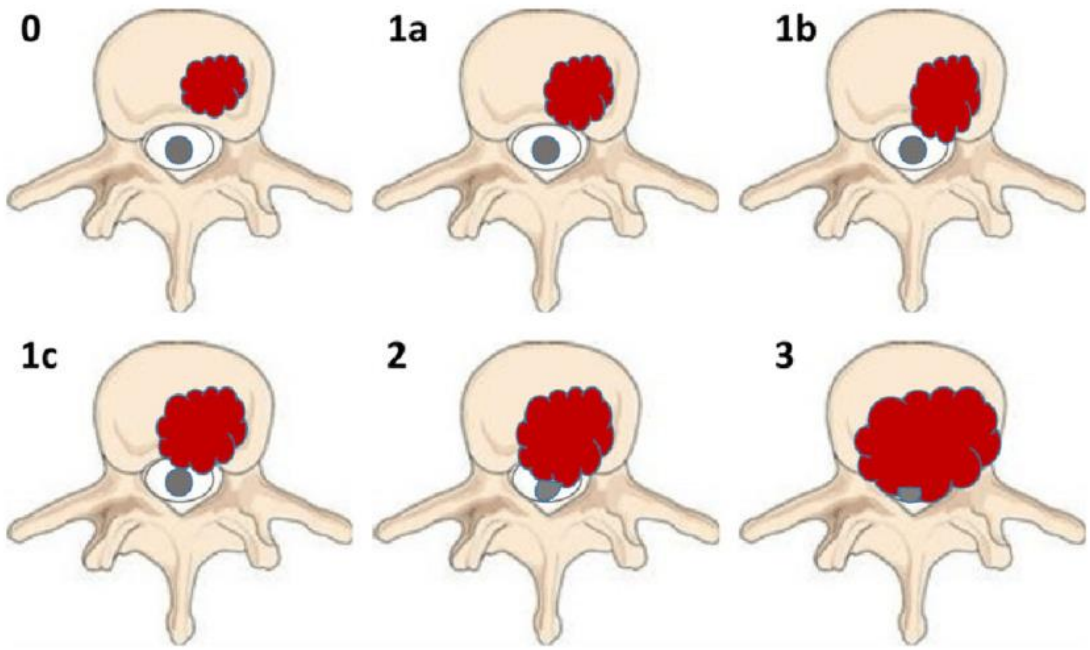

Grades 2-3 require separation surgery before radiation!

SPINAL INSTABILITY NEOPLASTIC SCORE (SINS)

1. **Pain**:
   - mechanical pain* (pain with movement or spinal loading or upright position [postural] or pain improves with recumbency): 3 points
     - *vs. periosteal stretching or nerve root/spinal cord compression pain – worsens with recumbency (venous congestion), improve with steroids (edema)
   - occasional pain but not mechanical: 1 point
   - painless lesion: 0 points
2. **Bone lesion** (on CT):
   - lytic: 2 points
   - mixed: 1 points
   - blastic (sclerotic): 0 points
3. **Location**:
   - junctional (occiput-C2, C7-T2, T11-L1, L5-S1): 3 points
   - mobile spine (C3-C6, L2-L4): 2 points
   - semirigid (T3-T10): 1 point
   - rigid (S2-S5): 0 points
4. **Alignment**:
   - subluxation/translation: 4 points
   - kyphosis/scoliosis: 2 points
   - normal alignment: 0 points
5. **Vertebral body collapse** (**anterior** and **middle** columns):
   - > 50% collapse: 3 points
   - < 50% collapse: 2 points
   - no collapse with > 50% vertebral body involved: 1 point
   - none of the above: 0 points
6. **Posterior spinal element involvement** (pedicles, facets, and/or costovertebral joints):
   - bilateral: 3 points
   - unilateral: 1 point
   - none: 0 points

1 (pain) is the only feature that need to ask patient; other features (**2-6**) are radiological.

- low bone mineral density (in unaffected spine) also strong risk factor for instability.
- in the case of multiple spine lesions, ***stability scores are not summed***.
- previous laminectomies or other surgical procedures and previous radiation therapy (including radiosurgery) may also influence the fracture risk.
- body weight and activity level may also influence spinal loading and impending instability.

Treatment and prognosis:
score 0-6: stable → radiotherapy / thermal ablation+cement
score 7-12: potentially unstable (warrant surgical consultation) → **surgery** vs. ***radiotherapy*** / thermal ablation + ***cement*** + ***brace***
score 13-18: unstable → surgery → radiotherapy

SURGICAL ASPECTS

Do not forget the role of preoperative embolization in vascular tumors!

- experts use TXA; avoid CellSaver (ok for en bloc resections - use leukocyte-trap)

- over time, instrumentation constructs fatigue, loosen, and fail unless bony fusion ensues; in the case of malignant disease, the limited life expectancy may, in fact, make bony fusion unnecessary (no role for biologics; if long term survival is a goal – autografts are the best).
- ***titanium implants*** should be standard for spine tumor reconstruction; ***carbon fiber*** have been adopted to lessen artifact on imaging (esp. for primary tumors).

FOLLOW-UP

- **PET** scans to monitor status of spinal disease for recurrence.

METASTASES

- ***spine*** is 3rd most common site for metastasis (after ***lung*** and ***liver***).
- most common tumors with predilection to metastasize to vertebrae:
  - prostate
  - breast
  - lung
- osteoblastic (osteosclerotic) changes:
  1) prostate cancer
  2) breast cancer
  3) osteomas
  4) sarcomas
  5) occasionally - lymphoma, hemangioma

85% cases of epidural spinal cord compression arise from ***vertebral metastases***!

– isolated epidural involvement is particularly common in lymphoma and renal cell carcinoma.

Metastatic tumors – high likelihood of distant metastases – surgery goal is palliation through intralesional resection (plus, adjuvant therapy options are often available).

- rare exception - single metastatic lesion in which oncologic cure (with en bloc resection) may be achieved.

Modern approach to metastatic spine - concept of "separation surgery" = microsurgical restoration (circumferential decompression) of CSF cuff (2-3 mm) between tumor and cord (to allow SRS) without attempting extensive tumor debulking and reconstruction → percutaneous instrumentation above and below to provide biomechanical stability

Historical: radical surgical resection → low-dose conventional radiotherapy
Modern: separation surgery → SRS

- spondylectomy is no longer indicated (as opposed to primary vertebral tumors); corpectomy with cage/cement support can be done if needed for structural support.

Boards: avoid big surgeries*; only palliative actions to treat symptoms – multidisciplinary approach!
Isolated vertebral body mass, neuro stable – obtain biopsy.

*if still contemplating corpectomy (e.g. to restore anterior support and alignment), always consider preop embolization (+ have TXA, blood ready and tamponade locally)

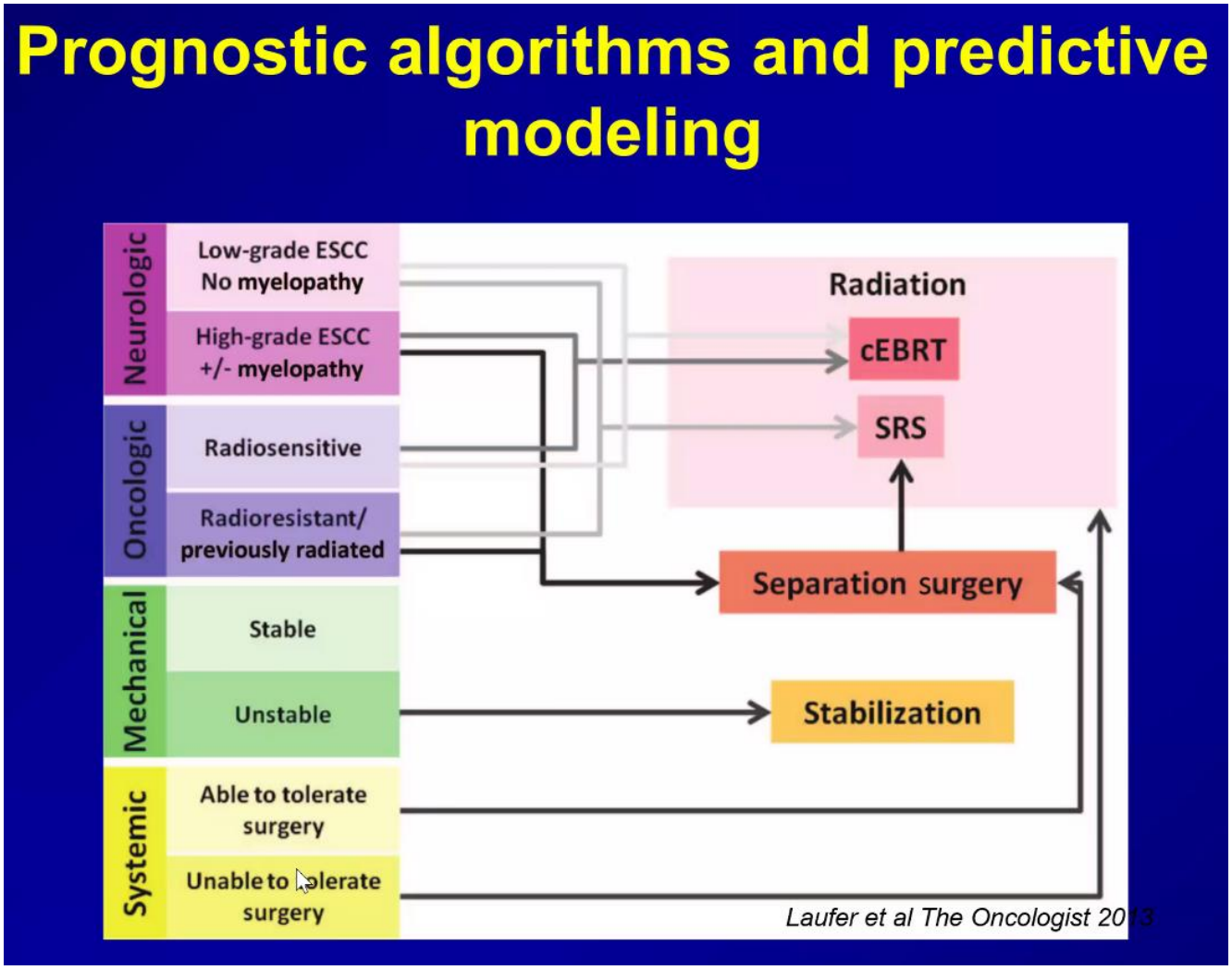

Management Algorithm (NOMS)

Neurologic (Cord compression)	Oncologic (Is the tumor radiosensitive (cEBRT)?)	Mechanical (Is the spine stable?)	Systemic (Can the patient tolerate surgery?)	Treatment Decision
Low-grade	Yes	Yes		External beam radiation (cEBR)
		No		Surgical stabilization -> cEBR
	No	Yes		Stereotactic radiosurgery (SRS)
		No		Stabilization ->SRS
High-grade	Yes	Yes		cEBR
		No		Stabilization -> cEBR
	No	Yes	Yes	Separation surgery -> SRS
			No	cEBR
		No	Yes	Stabilization & Sep surgery ->SRS
			No	Stabilization (cement) -> cEBR

Modified from Laufer, I et al. The Oncologist 2013

Radiotherapy

To minimize wound complications

- **adjuvant**: > 2 weeks after surgery (ideally, at 3-4 weeks; in rare cases with ongoing cord compromise – within 5 days).

- **neoadjuvant**: delay elective surgery for 6 weeks

Radiation is mainstay of treatment based on NOMS concept (unless need separation or stabilization*)
*for sick patients – just cement

CONFORMAL EXTERNAL BEAM (CEBRT)

Indication – mainstay of treatment for **radiosensitive metastases**.
- if there is instability, stabilization surgery first.

Contraindication - prior radiation.

Methodology
- 30 Gy in 10-15 daily fractions.

Outcomes
- 60-80% of ambulatory patients remain ambulatory.
- 19-33% of nonambulatory patients regain ability to walk.
- 50-70% of patients demonstrate pain improvement (vs. 85-100% with SRS)
- 61-89% of patients achieve local control defined as the absence of recurrent cord compression.
- tumor histology represents important prognostic factor:
  favorable histologies - lymphoma, myeloma, seminoma, breast cancer, prostate cancer, small cell lung cancer;
  unfavorable histologies - sarcomas, melanomas, renal cell carcinomas, gastrointestinal carcinoma, and non-small cell lung cancer (NSCLC).
- XRT appears to be safe (1 case of radiation myelopathy has been described).

SRS

Indication – mainstay of treatment for **radioresistant histology**.
- extent of disease should be **< 3 contiguous vertebral levels**.
- if high-grade cord compression exist, precede with **separation surgery**
  N.B. high-grade epidural compression with radiosensitive etiology → cEBRT (no need for separation as dose and risk for cord are lower with cEBRT)
- *local control rate of solitary met with SRS is similar to en bloc resection* (e.g. solitary renal metastases: 6-13% vs. 7.5%), thus, Bilsky et all have been advocating for SRS as a first line of treatment as a way of avoiding morbidity of en bloc resection.

Dose: 16-24 Gy (or 8-10 Gy x3 or 6 Gy x5) (higher dose = better local control)
- SRS has risk of complications: radiation myelopathy, vertebral compression fractures as a late complication (***within 4 months;*** prophylaxis: pre-SRS cement augmentation)

SEPARATION SURGERY

(converting high-grade epidural disease into low-grade i.e. ***downgrading epidural disease*** i.e. ***restoring CSF cuff around the cord***) → SRS is done 2-3 weeks after SS
- SS is done through posterior approach
- SS is not just a simple laminectomy – also need (bilateral) pediculectomy, PLL section/resection, removal of ventral epidural tumor without significant vertebral body resection – thus, need **instrumentation** to provide biomechanical stability.
- check with **intraop US** that thecal sac is reconstituted (need 2-3 mm of CSF)
  N.B. separation surgery is for ventral disease! (for dorsal disease, complete tumor removal is recommended)

PROGNOSTIC AND SURGICAL STRATEGY GUIDANCE SYSTEMS

No treatment increases life expectancy in spinal metastasis!

30-day postoperative mortality – 8.5%
median survival – 10 months

Revised Tokuhashi score (2005)

- multiple myeloma and lymphoma are excluded.

Characteristic	Score
General condition (performance status)	
Poor (PS 10%–40%)	0
Moderate (PS 50%–70%)	1
Good (PS 80%–100%)	2
No. of extraspinal bone metastases foci	
≥3	0
1–2	1
0	2
No. of metastases in the vertebral body	
≥3	0
2	1
1	2
Metastases to the major internal organs	
Unremovable	0
Removable	1
No metastases	2
Primary site of the cancer	
Lung, osteosarcoma, stomach, bladder, esophagus, pancreas	0
Liver, gallbladder, unidentified	1
Others	2
Kidney, uterus	3
Rectum	4
Thyroid, breast, prostate, carcinoid tumor	5
Palsy	
Complete (Frankel A, B)	0
Incomplete (Frankel C, D)	1
None (Frankel E)	2

Predicted prognosis:

Total Score	Prognosis	Treatment strategy
0-8	87% patients lived ≤ 6 mos	conservative treatment
9-11	87% patients lived ≥ 6 mos	palliative surgical procedures (stabilization ± laminectomy); except score of 9-11 with a single spinal lesion and no metastases to major organs → excisional surgery (tumor excision with stabilization).
12-15	95% patients lived ≥ 1 yr	excisional surgery

Tomita score - three factors:

1) **malignant grade of primary tumor** (as determined by tissue of origin): (1) slow growth, (2) moderate growth, (3) rapid growth
2) **visceral metastases to vital organs**: (1) none, (2) present but treatable, (3) present untreatable
3) **bone metastases**: (1) isolated to the spine or (2) not isolated to the spine

Total Score	Prognosis	Treatment strategy
2-3	49.9 months (range 18-84 months)	wide or marginal excision
4-5	23.5 months (range 7-57 months)	intralesional excision ± marginal excision when possible
6-7	15.0 months (range 5-33 months)	palliative decompression and stabilization
8-10	5.9 months (range 1-14 months)	nonoperative palliative care

Game changes in spinal metastases treatment (in historical order)

1. Decompressive surgery
2. SRS
3. Separation surgery

Pretreatment neurological status is one of most important prognostic factor affecting outcome (importance of early diagnosis!!!)

- *rapidly progressing* deficits = worse prognosis (than slowly evolving ones).
- loss of bowel / bladder function is usually irreversible.

STEROIDS

Indications:

1) oncolytic effect (lymphoma, myeloma)
2) biologic pain control
3) control of vasogenic cord edema in high-grade cord compression (e.g. periop, during XRT)

HYPERCALCEMIA

- can result in cardiac or kidney dysfunction, and even death.
- H: IV fluid rehydration + bisphosphonates.

LYMPHOMA

- tends to spread in epidural space, through foramina (but not destroying bone).
- biopsy only.

MULTIPLE MYELOMA, PLASMACYTOMA

N.B. ***hematological tumors*** (lymphoma, multiple myeloma) – treatment is **medical**; surgery indications are rare:

1) acute neurological deficit
2) intractable pain without neurological deficits → vertebral augmentation (soft tumor allows impressive cement filling with good pain relief), XRT

- very soft vascular tumors (near-fluid consistency).
- back pain that might be relieved by recumbency (different than other metastases).

Plasmacytoma

– solitary benign neoplasm of monoclonal plasma cells (no signs of myeloma – anemia / hypercalcemia / renal impairment, serum/urine monoclonal protein / other lesions)

- up to 50% dedifferentiate into *MULTIPLE MYELOMA* (monitor for 20 years following original diagnosis).
- **CT/MRI** – pathognomonic **"mini-brain" appearance** (curvilinear low signal intensity areas within the lesion, giving an appearance of sulci in the brain):

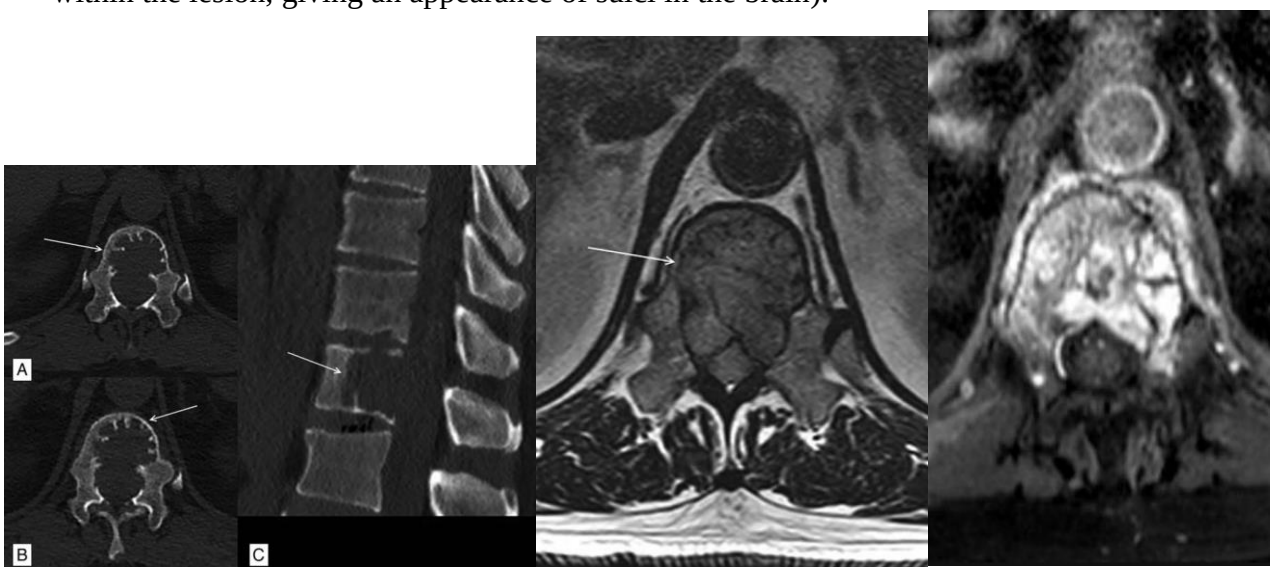

- may need **biopsy** for definitive diagnosis.
- <u>treatment</u>: ***radiation*** 35-50 Gy (highly radiosensitive tumor - most effective for local disease control incl. neurological deterioration with epidural involvement) and ***bracing***
    - if pathologic fracture / risk of instability → ***stabilization*** / ***kyphoplasty*** → adjuvant ***radiotherapy***
    - if progressive neurological compromise* → surgical ***en-bloc resection*** (consider preop embolization given abundant vascularity) → stabilization → adjuvant ***radiotherapy***.

      *vs. if neurological compromise just because of epidural tumor (and not due to bony elements or kyphosis), then XRT alone is effective treatment

<u>Multiple Myeloma</u>

– disseminated malignant form of plasmacytoma, potentially fatal: **chemotherapy, palliative irradiation** to affected spine (MM is radiosensitive – radiotherapy can be used if cord compression is due to epidural disease)

- osteolytic bone destruction - "punched-out" or "moth-eaten" appearances
- look for other lesions:
    1) serum and urine protein electrophoresis (Bence Jones monoclonal antibody protein in urine)
    2) bone marrow evaluation
    3) skeletal survey
    4) bone scan – in 33% cases, "cold" lesions (so false negatives risk - MM is exclusively osteolytic)

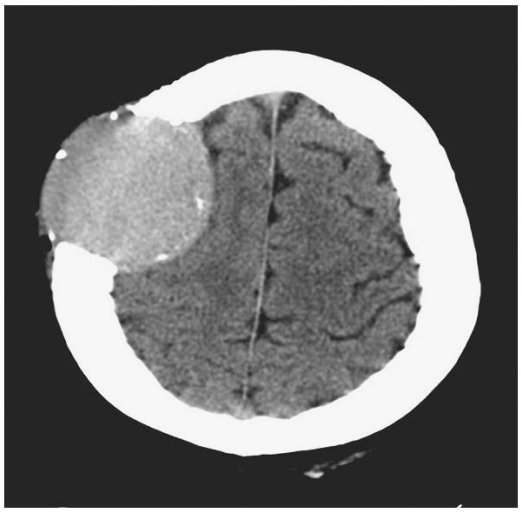

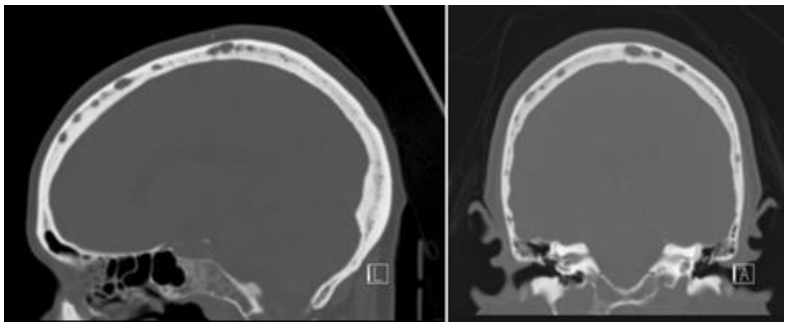

N.B. hematological malignancies – no oncological indications for surgery!

RENAL CELL CARCINOMA

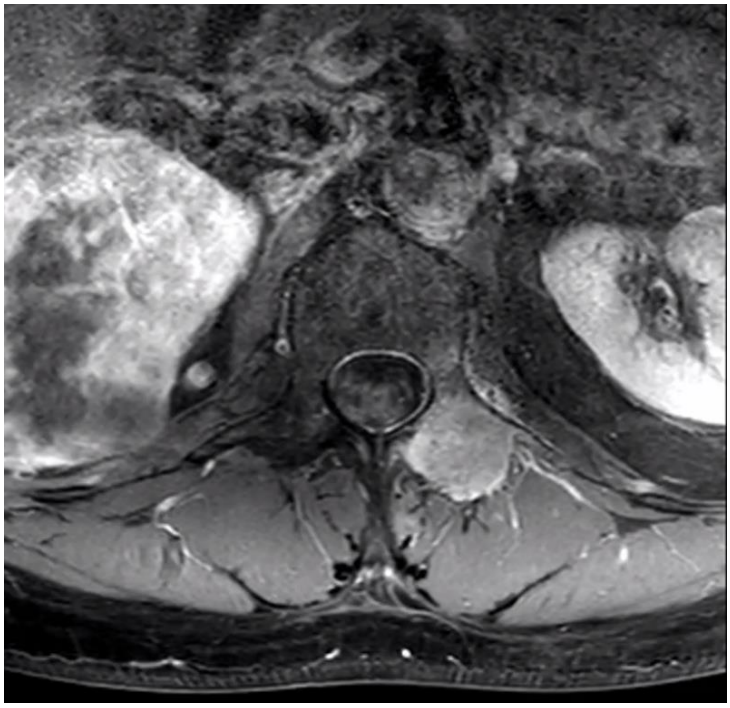

- most experts agree that in RCC treatment is palliative (urologist may not even perform nephrectomy) but life expectancy may be prolonged (5-7 yrs)

See Case S4 >>

PRIMARY VERTEBRAL TUMORS

(3-25 times less common than metastatic tumors!)

Primary tumors – low likelihood of distant metastases – surgery goal is ***cure*** through ***en bloc resection*** (plus, adjuvant therapy options* are limited) – especially true for chordomas, chondrosarcomas.

*adjuvant treatments are advancing rapidly (experts do less and less en bloc resections!) – all primary tumors should be presented to ***multidisciplinary tumor board***

Weinstein, Boriani, Biagini (WBB) Surgical Staging System

- surgical terminology and strategy guidance.

- particularly suited to the **thoracolumbar spine**.
- vertebra (in axial plane) is divided in clock-face fashion into 12 equal segments and 5 layers from superficial to deep:

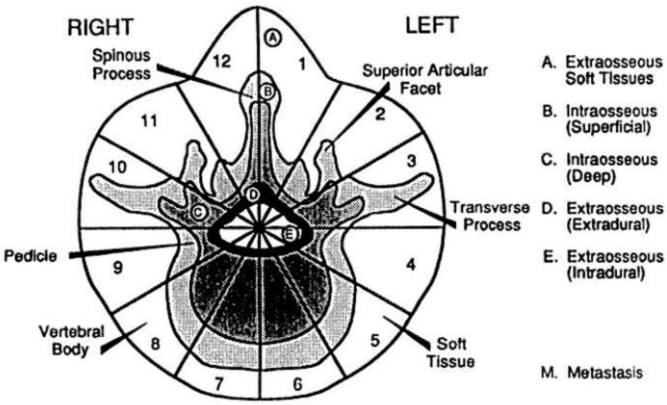

Enostosis (Bone Island) – mass of proliferating bone tissue within bone (Not a tumor!) - remain stable

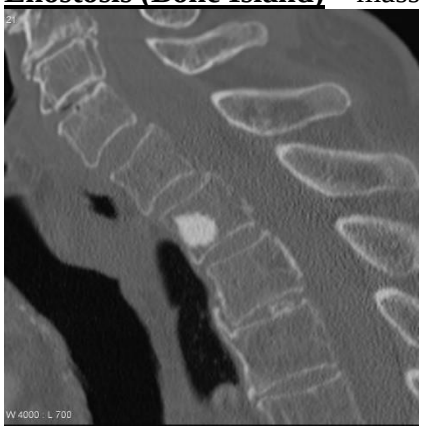

- considered one of the skeletal "don't touch" lesions; main dif – osteoblastic mts – if exhibits diameter increase > 25% in 6 months → **biopsy**.

Osteoid osteoma (*locally self-limited*); nocturnal pain relieved by NSAIDs

- oval radiolucent nidus, with surrounding rim of sclerotic bone (on bone scan lucent nidus is "cold" and sclerotic rim "hot")

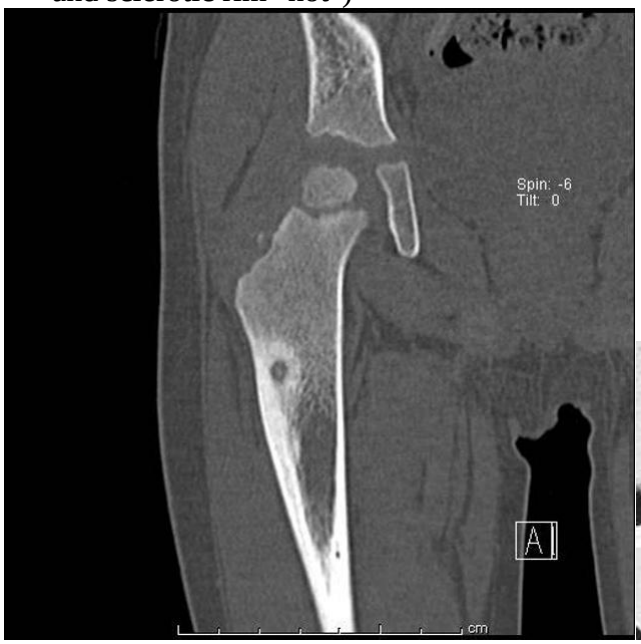

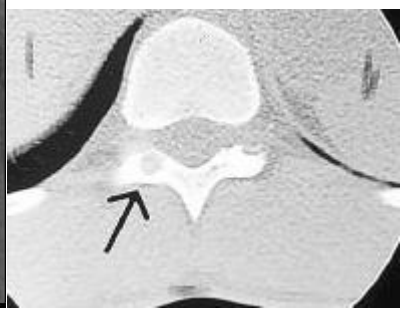

- treatment – ***complete nidus resection / percutaneous RF***

Osteoblastoma (as osteoid osteoma but *locally aggressive* – grows big):

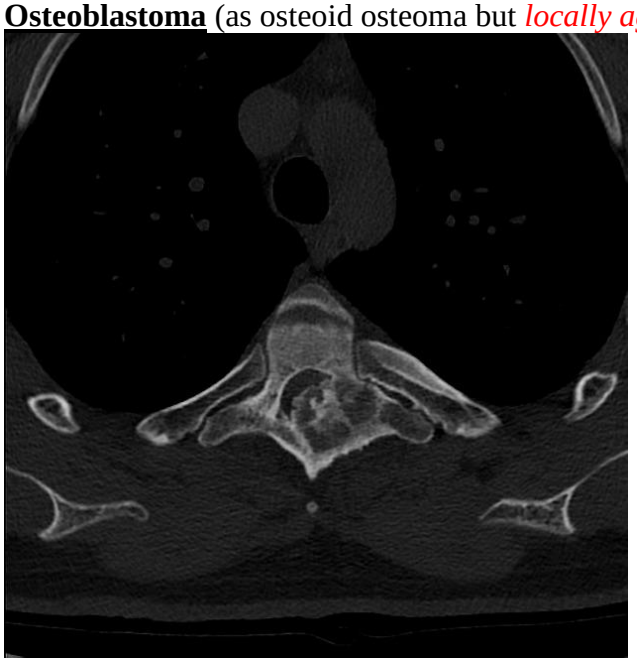

- treatment - ***wide local resection*** with spine stabilization.

Osteosarcoma

- most common sarcoma of the spine.
- the most common primary malignant bone tumor in the pediatric population (one of the *lowest survival rates among pediatric cancers*).
- risk factors: Paget's disease (Paget patients make up as much as 50% of the patients)
- osteolytic or osteoblastic:

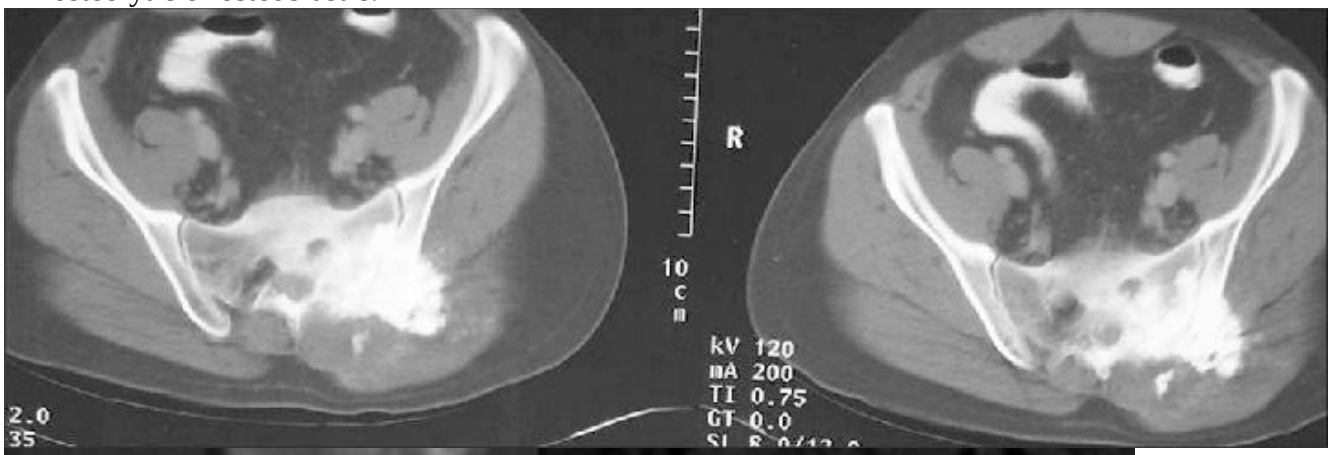

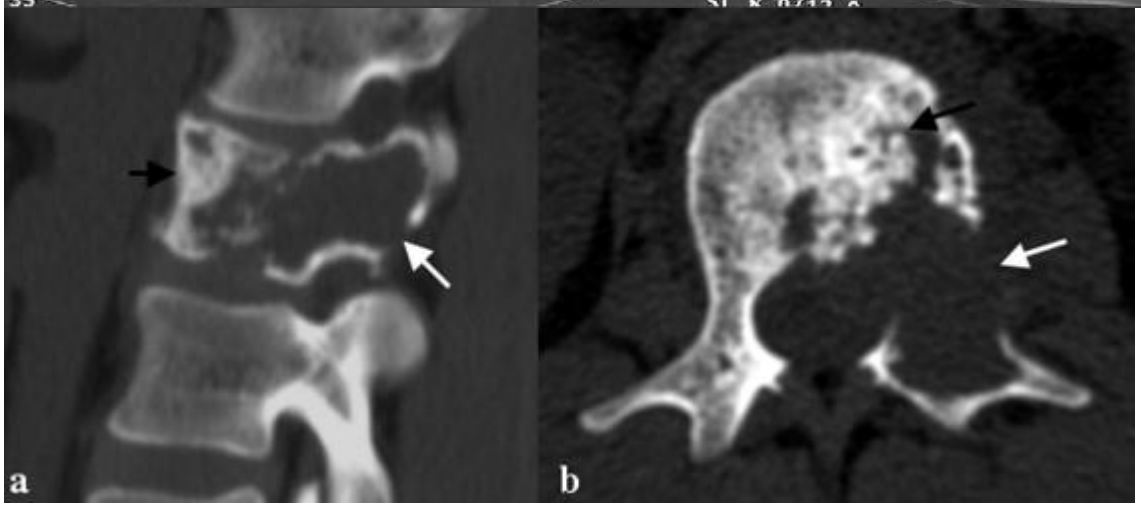

All patients: **neoadjuvant chemotherapy**! → **surgical resection** → **radiation**

Giant cell tumor (osteoclastoma)

- benign hypervascular, but locally aggressive - large osteolytic expansile lesions – "*soap bubbles*":

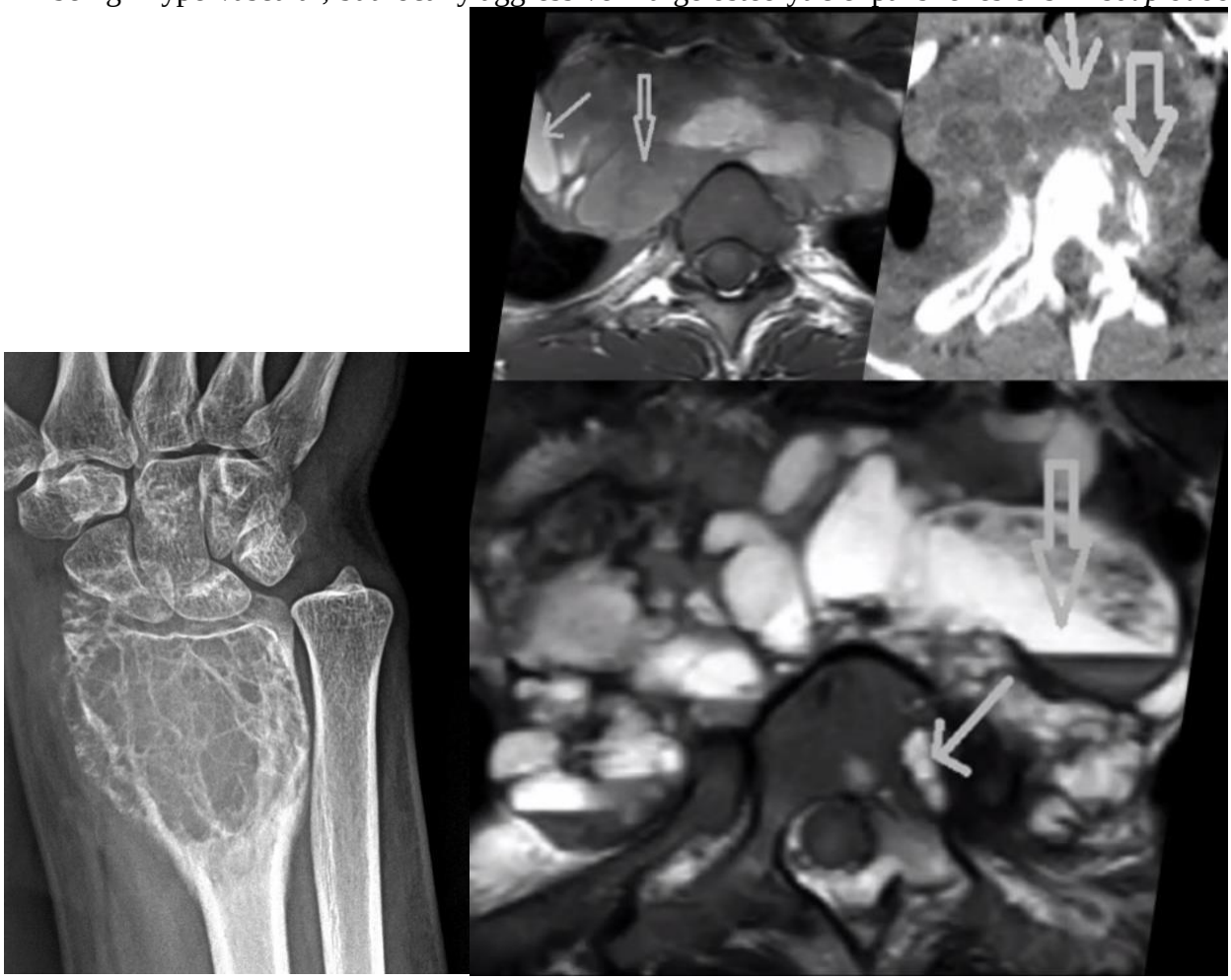

Treatment: (arterial embolization +) ***complete resection*** (better *en bloc*).

- ***radiation*** reserved for surgically inaccessible tumors; another effective option - DENOSUMAB

Osteochondroma

- benign lesion – trapped physeal cartilage outside growth plate during skeletal development.
- do not increase in size after skeletal maturity.
- calcified bony exostosis attached to a bony surface via a bony pedicle; no bony destruction

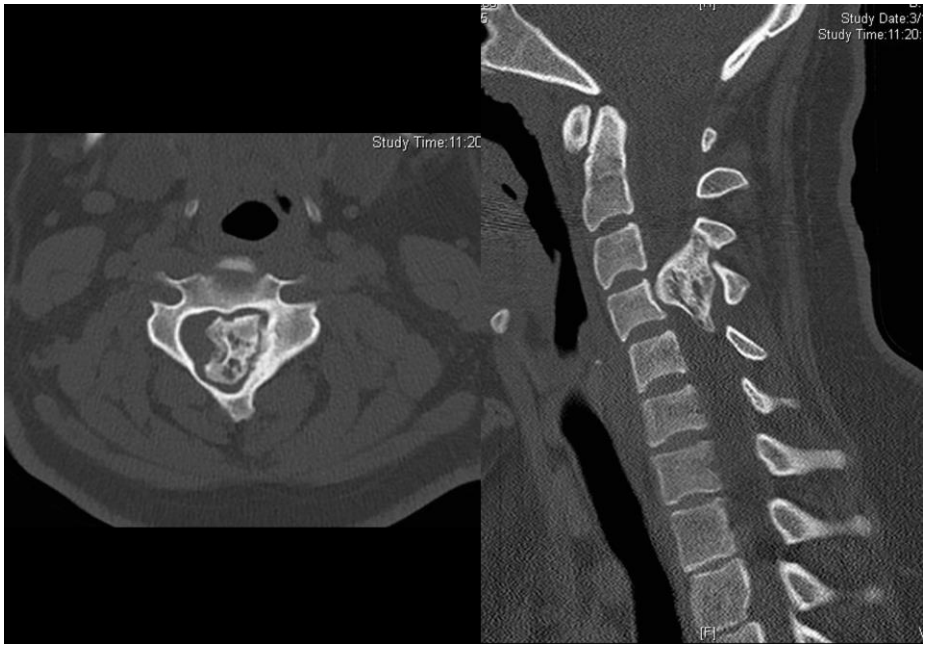

- treatment: ***complete surgical resection*** without radiation

Chondrosarcoma

- low-grade malignancy
- very vascular
- 35% involve adjacent vertebral levels (by extension through disc).
- second most common nonlymphoproliferative tumor of spine

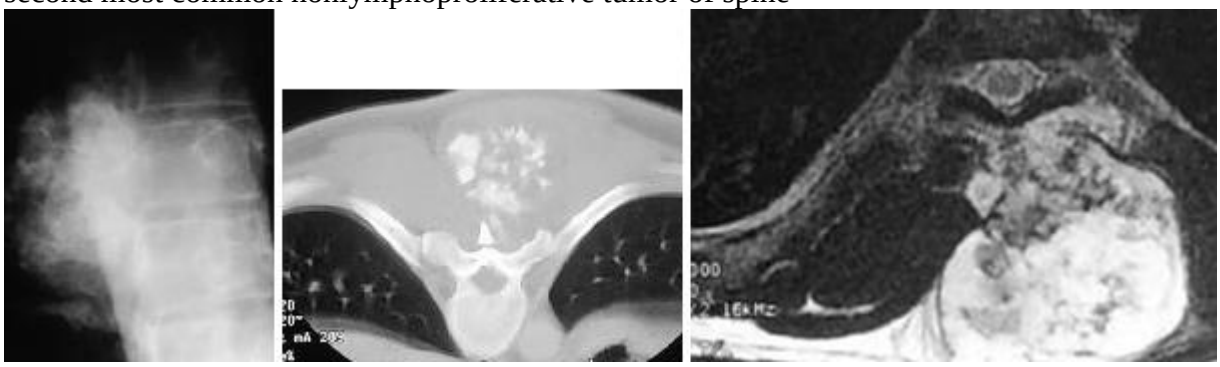

- treatment: ***en bloc surgical resection***

Aneurysmal bone cyst (ABC)

Benign, proliferative, non-neoplastic lesion

- etiology:
  Primary ABC (65-95%) - result from micro-trauma.
  Secondary ABC - result from underlying neoplasms.
- macro - expansile (locally aggressive) area of bone remodeling, septations within mass, thin outer periosteal rim of bone.
- micro - multiloculated blood-filled cystic spaces not lined by endothelium (i.e. not vascular channels).
- hypervascular mass (multiple vascular "lakes"); lakes containing *fluid levels*

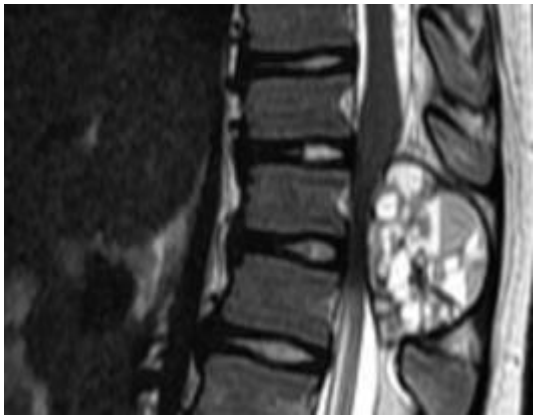

- if biopsy is required (rare, given characteristic imaging), open biopsy are preferred to allow for adequate control of hemorrhage.
- **embolization → complete resection with thin margin** (simple curettage → rapid recurrence).
- successful treatment with stand-alone arterial embolization has been reported.

Ewing sarcoma

- malignant **round cell** tumor.
- treatment - ***radiation & chemotherapy*** - almost 100% local control.

  N.B. Ewing sarcoma – very chemo/radiosensitive – neoadjuvant therapy may cure it (may avoid surgery)!

Eosinophilic granuloma

- one end of spectrum of systemic diseases, including Letterer-Siwe and Hand-Schiller-Christian disease.
- **X-ray** - classic "*vertebra plana*" (symmetrically flattened and thinned vertebral body).
- treatment: ***curettage*** → low-dose ***radiotherapy***; multiregimen ***chemotherapy*** for systemic eosinophilic granulomas.

Hemangioma

- benign tumor of newly formed blood vessels
- usually* do not produce symptoms.

  *pathologic vertebral fractures or epidural extension can occur - most frequently in thoracic region of teenaged girls.
- **X-ray** - *coarse vertical striations* or *trabeculae* ("corduroy cloth" impression).
- **CT** - dilated vascular spaces (characteristic appearance - polka-dot appearance on axial images and corduroy / jail bar sign on coronal and sagittal images).

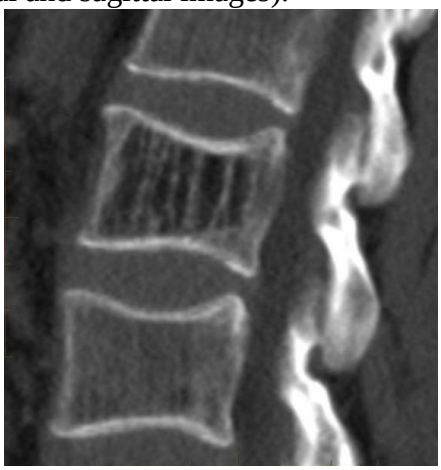

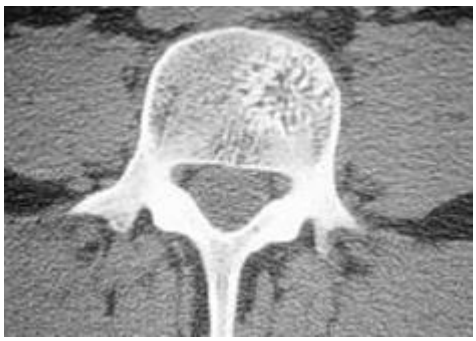

- **MRI**: T2 bright; T1 – bright or dark or iso (depends on fat content – usually T1 bright vs. metastases are T1 dark); significant enhancement due to high vascularity.

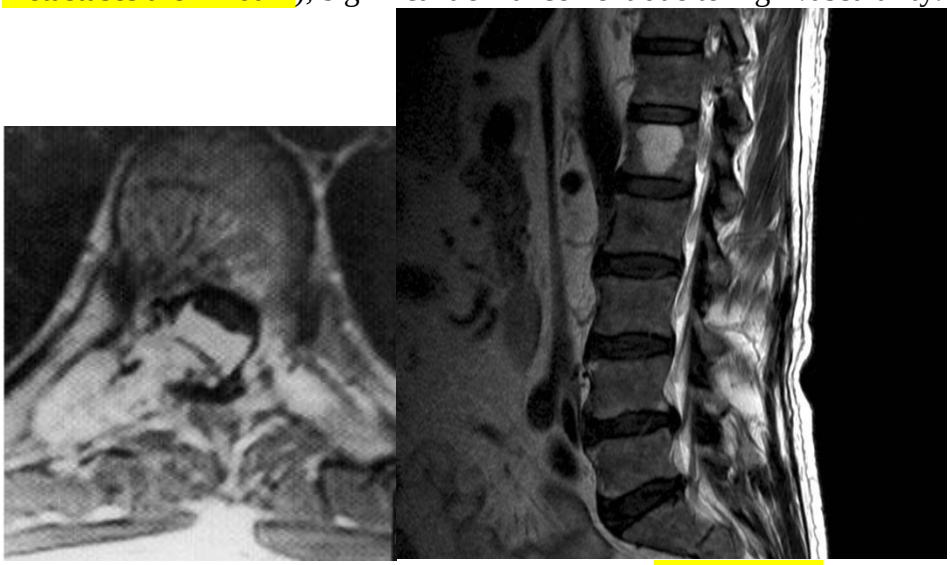

- **bone scan** – usually normal or decreased uptake ("cold vertebra"):

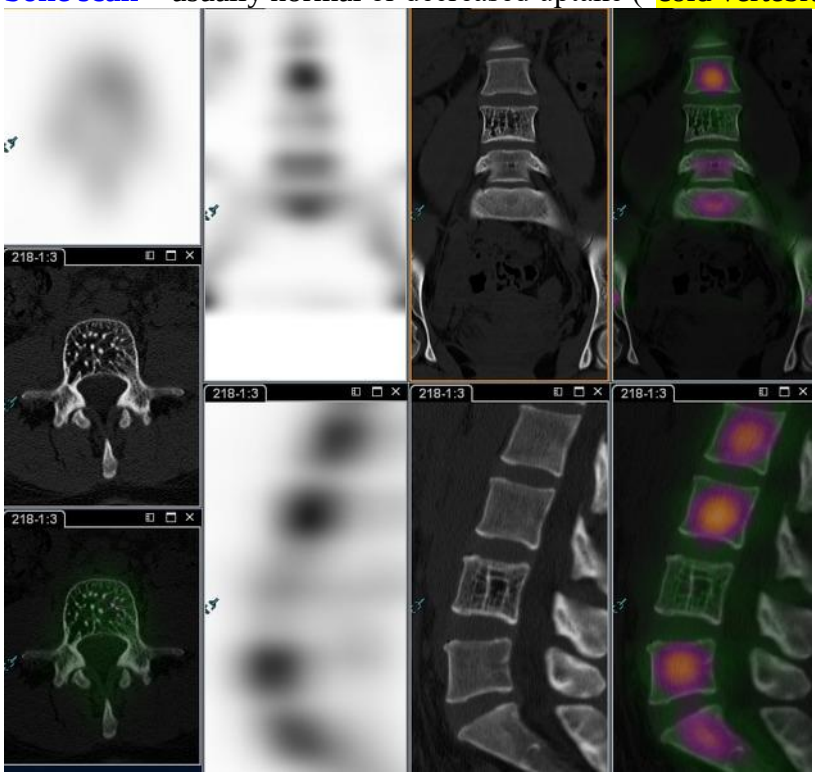

- **angiography** - vascular lacunae and multiple feeding vessels (readily amenable to embolization).
- **biopsy** – just blood.
- treatment - low-dose ***radiotherapy*** and ***bracing***;
  - asymptomatic hemangiomas are left untreated!
  - ***vertebroplasty****
  - spinal cord compression → ***vertebrectomy*** and spine ***stabilization*** (preoperative embolization is recommended).

*percutaneously puncturing vertebral body and injecting acrylic within it (vertebroplasty).

ONCOLOGY (PNS, CRANIAL NERVES)

- WHO grade I
- MRI distinction between two types is usually difficult!

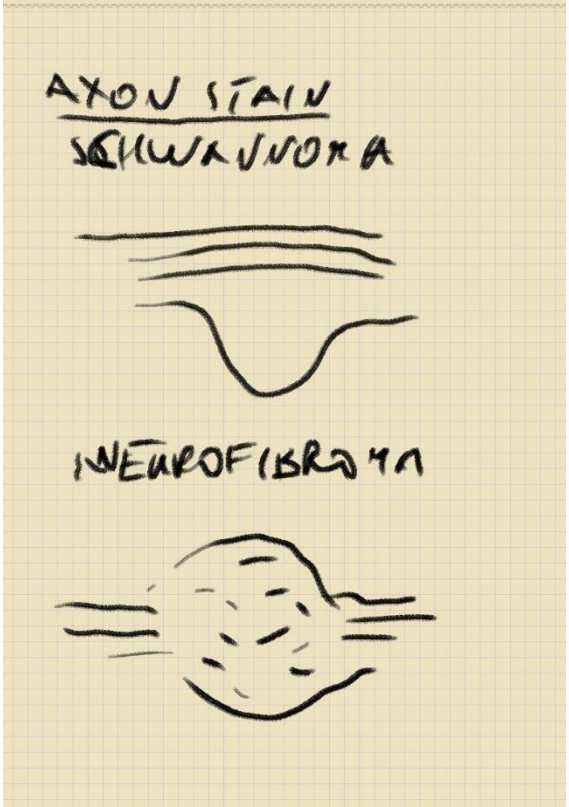

PNS tumor – check for NF stigmata!
Do not resect every nerve mass (it can be neuroma, cyst, hamartoma, intraneural ganglion [extending from neighboring joint], etc)! – only large / enlarging / symptomatic / uncertain pathology
If going to OR – request **stimulator**! (involved nerve fascicles are nonfunctional – always can sacrifice, but for Boards – always use stimulator!)

SCHWANOMA

- benign tumor of ***Schwann cells*** (stain for S-100!).
- universal finding - alteration or loss of *NF2* gene (22q12) product (Merlin).
- solitary (multiple in NF2, SCHWANNOMATOSIS).
- grows eccentrically in nerve sheath - easy to dissect.

Compress, rather than invade, parent nerve

- well-defined, fibrous ***capsule*** (vs. *NEUROFIBROMA*).
- almost exclusively on ***sensory nerves*** (CN8 > CN5 > CN9 > CN10); motor and autonomic nerves are far less often affected.
- **bilateral** vestibular tumors are sine qua non of NF2.
- ***no malignant degeneration*** *(or extremely rare)*
- histologically – alternating 2 distinct regions:

  Antoni A areas – *compact cellular regions*; spindle cells palisade around eosinophilic ***Verocay bodies*** (tight, discrete aggregate of spindle-shaped, palisaded nuclei with central "nuclear-free" fibrillary area, representing collection of cytoplasmic processes of tumorous Schwann cells); little matrix.

  Antoni B areas – *much less cellular* - cells arranged haphazardly in myxomatous loose connective tissue with microcystic changes.

Verocay body:



1. **Plexiform form** (5%) – predominantly Antoni A tissue.
2. **Ancient form** – entirely composed of Antoni B tissue.

- nontender **cosmetic deformity** → compressive neuropathy (burning pain, constant but might be intermittent)
- **CT / MRI** - prominent enhancement.
    - **PET** – if uptake is high, suspect malignant peripheral nerve sheath tumor.
- insertion of **biopsy** needle → *excruciating pain* - clue in diagnosis of nerve tumors!

A. **Resection** – lesion is excised marginally, and nerve fibers are spared; most common complication is initial neurapraxia (can be permanent!).
B. **SRS** – for small intracranial schwannomas.
C. If resection would lead to significant functional deficit (unusual case):
    a) **observation**.
    b) **intralesional resection**.

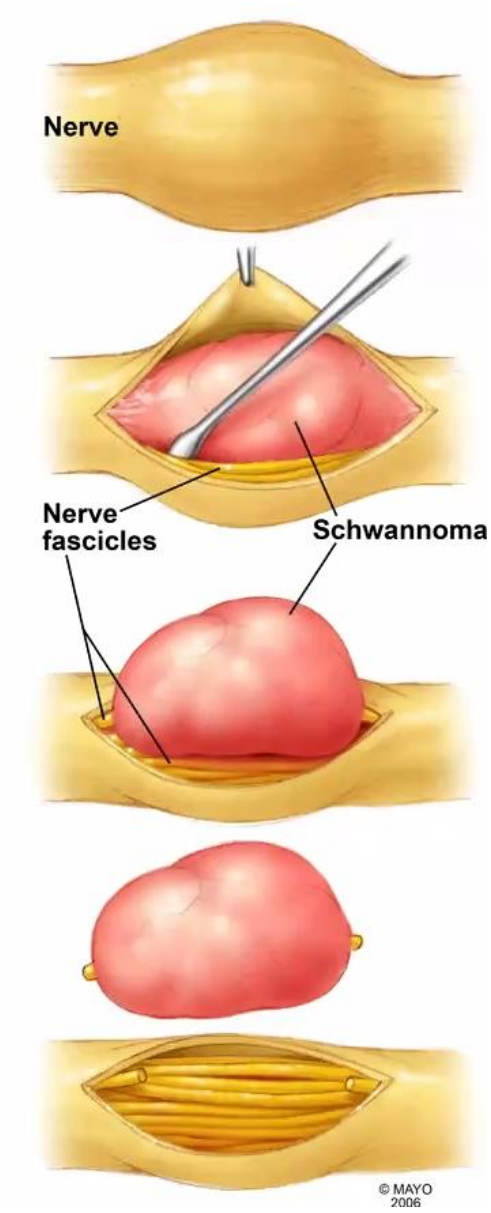

VESTIBULAR SCHWANNOMA

(wrong term - Acoustic Neuroma)

- CN8 remains sheathed in oligodendroglia for 15 mm (almost to point at which it passes into internal auditory canal) - *longest oligodendroglial investment of any peripheral nerve* – schwannomas arise within most lateral portions of CP angle or internal auditory canal.
- BILATERAL tumors are pathognomonic for **NF2**
- **VESTIBULAR** division : AUDITORY division = 3-20 : 1
- *grow slowly* (2 mm/year)
- **compression: CN8** (hearing loss in speech frequencies & tinnitus; *true vertigo is rare*) → **CN5** and **CN7** (test CORNEAL REFLEX; *facial weakness is rare*) → **cerebellum** and **pons** (ataxia, hydrocephalus)

Clinical stages: otologic → neurologic → neurosurgical.

N.B. *any asymmetric sensorineural hearing loss* requires acoustic tumor be ruled out!; *unilateral tinnitus alone* is sufficient reason to evaluate for acoustic tumor!

N.B. in modern neuroimaging era, audiologic testing is no longer used for diagnosis, but provides pretreatment baseline!

50/50 rule - individuals with pure-tone average > 50 dB and speech discrimination < 50% do not have useful or salvageable hearing.

MRI:

1) postcontrast 3D T1 MPRAGE - *intense enhancement*!
2) high-resolution T2 (constructive interference in steady state [CISS] or fast imaging employing steady-state acquisition [FIESTA]) – useful for observation scans (saves patient from gadolinium)

- if MRI is contraindicated but suspicion is high → **air-contrast CT cisternography** (high sensitivity - can detect relatively small intracanalicular tumors - injected intrathecal gas is maneuvered to outline CN8).

Koos grading:

stage I – intracanalicular tumor
stage II – protrusion into cerebellopontine angle
stage III – occupying cerebellopontine cistern with no brainstem displacement
stage IV – brainstem and cranial nerve displacement

Rx:

Most patients eventually develop nonserviceable hearing as a result of disease or treatment (esp. tumor diameter ≥ 1.5-2.0 cm)

1. **Surgical** excision - mainstay of treatment! (esp. < 45 yo); preservation of *acoustic nerve* is rare; *facial nerve* preservation is important goal; for residual tumor → wait 1.5-3 mos, then SRS
   Dade Lunsford: surgery only for symptomatic mass effect on brainstem!

2. **SRS (12-13 Gy** to margin**)** – better (than surgery) preservation of CN5, CN7, hearing
   N.B. **radiosurgery** is still *not hearing preservation approach* (patient is counseled that likelihood of hearing loss is similar to continued observation); SRS *does not improve tinnitus, balance, hearing*.
   Multiple meta-analyses reveal that from the patients' perspective, SRS provides a more desirable outcome than microsurgery!
   - SRS is for Koos I-III; SRS may be used even for > 4 cm tumors if minimally symptomatic (KOOS grade 4) but recommend debulking first.

     N.B. *brainstem compression* is not improved by radiation – use surgery instead!
   - Cleveland Clinic: 1 dose of METHYLPREDNISOLONE at the end of SRS procedure.
   - SRS can be repeated if first SRS failed (usually repeat SRS is fractionated).
   - Dade Lunsford: fractionation is not advantageous (some claim better hearing preservation).

3. Serial **observation** (not recommended for tumors > 1.5–2 cm - higher probability for growth) – MRI annually for 5 yr, with interval lengthening thereafter with tumor stability.
   Dade Lunsford: in 4.4 yrs tumor volume doubles – observation only for elderly / poor treatment candidates.

NF2:

a) surgical > 180 degree decompression + learn sign language
b) SRS
c) BEVACIZUMAB
d) ERLOTINIB (not recommended per CNS 2017 guidelines)

SURGERY

A. ***Retrosigmoid (suboccipital)*** approach - for small tumors with minimal extension into IAC (less than ½ of proximal IAC with predominantly CPA component) when patient desires hearing preservation; best view of posterior fossa

- drill off posterior wall of IAC (endolymphatic sac is the landmark how posteriorly we can drill) – avoid injury to labyrinth

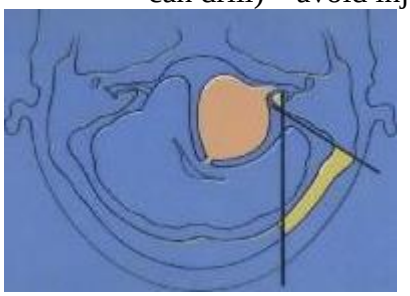

- practically *can be applied to all acoustic tumors* but highest incidence of tumor *recurrence / persistence* - due to poor control of IAC fundus.

B. ***Translabyrinthine*** approach – preferred if deaf by 50/50 rule; best view of brainstem and CN7

- *fat graft* (from abdomen) or hydroxyapatite cement is required.
- complete *hearing sacrifice* is unavoidable.

Contraindications:

- high-riding jugular bulb (above level of inferior internal auditory canal).
- anteriorly placed sigmoid sinus (distance between sigmoid sinus and external auditory canal few millimeters or less - limited corridor).
- absent flow in contralateral sinus (injury to remaining sinus → catastrophic venous infarction).
- contracted sclerotic mastoid (little room for tumor removal)

C. ***Middle cranial fossa*** approach - for small intrameatal tumors ≤ 1.5 cm; fully exposes lateral IAC without sacrificing hearing – better hearing preservation than retrosigmoid!

- *CN7* is in way during tumor removal (CN7 courses across anterior superior portion of tumor) - temporary postoperative paresis is more common.

- vestibular nerves are generally sacrificed, and unless hearing is to be preserved, cochlear nerve is sacrificed as well.
- CN7 is usually anteriorly to tumor (so nerve is hidden).
- tumor removal begins by incising capsule and carefully debulking - enough room is created within IAC to carefully remove tumor capsule from inferior surface of CN7
- may leave 1 mm "tumor carpet" on CN7 to avoid nerve injury.
- CN7 paresis tends to be temporary (if not, branch of CN11 is joined to *facial nerve* peripherally or *facial-to-facial nerve graft*).
- CN8 fibers fan out into modiolus – it takes very minimal force to disrupt those fibers – *no lateral-to-medial motion while resecting*, i.e. all sweeping motions must be very gentle medial-to-lateral.

- perioperative NIMODIPINE + **steroids** should be considered to improve facial nerve and hearing outcomes.
- **intra-operative monitoring** of CN7 and CN8 → dramatic reduction in morbidity.
    - facial nerve – EMG
    - vestibulocochlear nerve – BAEPs (signal summation average – delayed feedback), ECOG, direct CNAPs.
- spillage of bone dust into subarachnoid space → severe and intractable postoperative headache.

POSTOP

- ***vestibular rehabilitation*** begins on POD1
  - vertigo improves over several days; it is predicted if patient never had in a history the episode of severe vertigo (if patient had it in the past and it went away, it most likely means that vestibular system is already nonviable); prophylaxis – *never leave one division of vestibular nerve intact* (i.e. if superior division got damaged, then cut also inferior division).
  - palliative treatment for ***persistent vertigo*** - transtympanic GENTAMICIN injection to kill remaining vestibular input so brain will no longer receive weird signals from malfunctioning vestibular apparatus.
- **Follow-up MRI** (completeness of tumor removal) within 3-6 months → at 5 years → at 10 years (if all are normal, further imaging is performed only if clinical circumstances require it).

SCHWANNOMATOSIS

- **multiple** painful **peripheral** schwannomas in absence of other NF2 features.

FACIAL SCHWANNOMA

- slowly progressive (> 3 weeks) **CN7 dysfunction** (paresis, often preceded by facial twitching).
- classic presentation - *recurrent increasingly severe acute paralytic episodes* with partial / complete recovery.
- radiographically distinguishing between *INTRACANALICULAR CN7 TUMOR* and *VESTIBULAR SCHWANNOMA*
- treatment - primarily **SURGICAL** – when CN7 function has deteriorated beyond House-Brackmann grade III/IV

NEUROFIBROMA

- benign tumor of ***Schwann cells*** + ***fibroblasts***, ***perineurial cells***, and frequently ***nerve fibers***; extensive amounts of collagen with axons dispersed throughout tumor - excision impossible without sacrificing nerve

- lack thick collagenous capsule (vs. *SCHWANNOMAS*)
- multiple in NF1 (vs. NF2 in *SCHWANNOMAS*)
- immunoreactivity for S-100 in only portion of cells (vs. uniform reactivity throughout *SCHWANNOMA*).
- 5-15% undergo *malignant degeneration* to sarcoma.

Extensive collagen - 'shredded carrots' appearance:

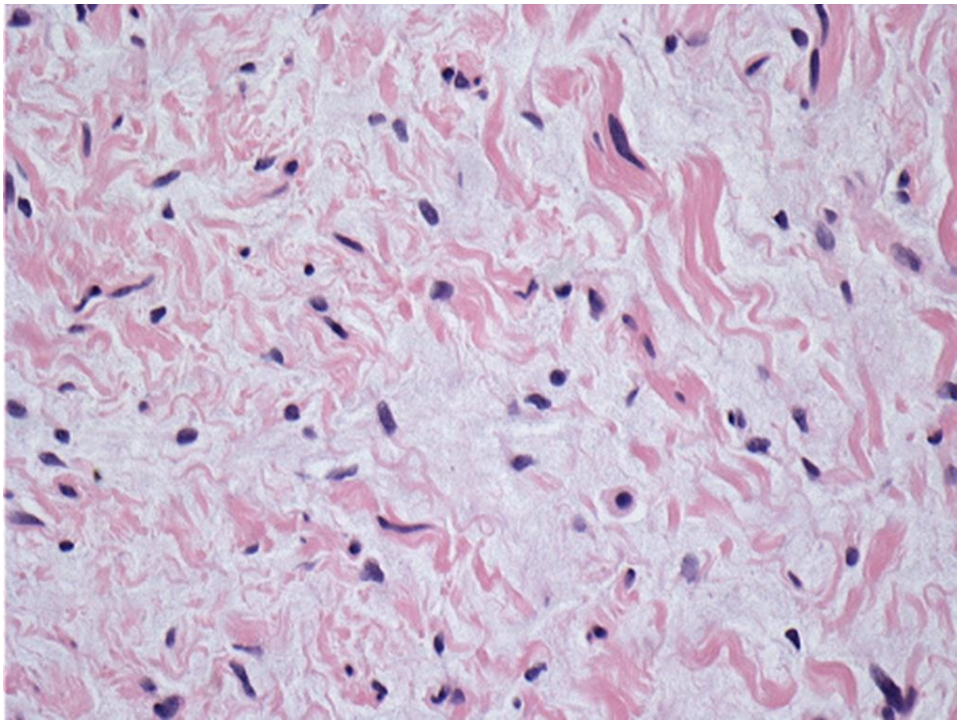

PLEXIFORM NEUROFIBROMA

- only in NF-1?
- large nerve trunk - **multinodular tangles** ("bag of worms") or **rope-like lesions**
- significant potential for malignant transformation – keep watching closely (for symptomatic – debulking surgery)

See Case PN1 >>

MALIGNANT PERIPHERAL NERVE SHEATH TUMOR

- highly malignant sarcoma.

- ½ cases are diagnosed in NF1 – as transformation of pre-existing neurofibroma
  Do not arise from malignant degeneration of schwannomas!
- typical herringbone pattern:

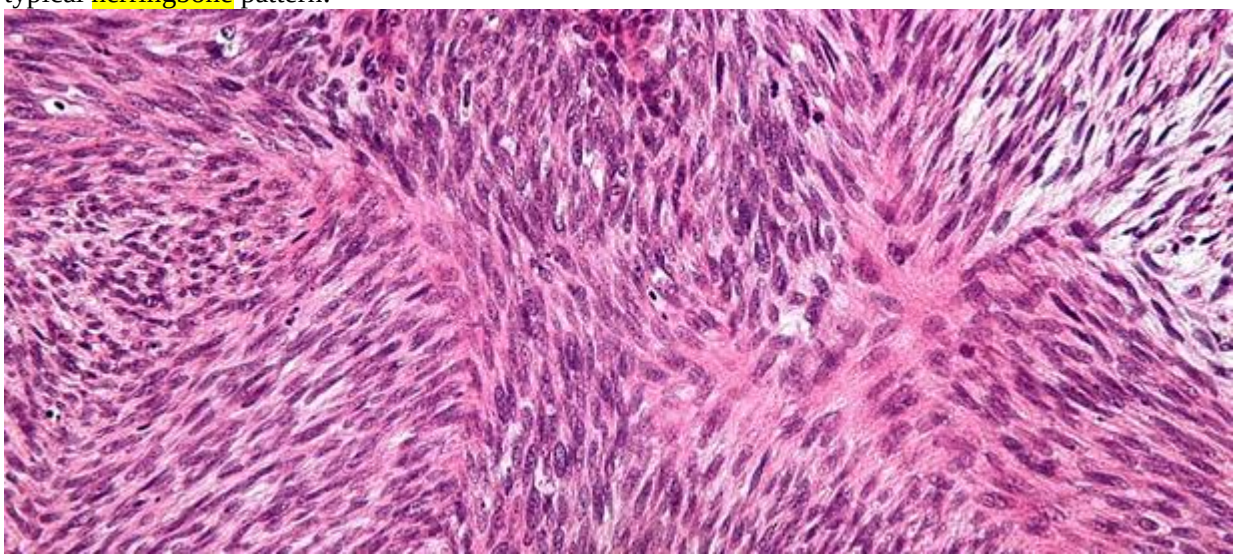

- diagnosis clinical - pain at rest, rapidly enlarging immobile mass, early progressive motor loss.
  N.B. benign tumors – no weakness!

- MRI cannot differentiate malignant vs benign (unless gross local invasion)
- PET (> 7) is diagnostic in dif from benign tumors (< 2).

- **resection with wide margins** → **chemotherapy** ± radiotherapy

N.B. practically – need biopsy and staging in preparation for large surgery:

A. If highly suspected preop → **open biopsy** or **percutaneous needle*** **biopsy** → **further work up****

*Board's choice but risk of false negative

B. If became suspicious only during surgery (firm, no planes) → **open biopsy** and send frozen:

a) if pathologist certain it is benign → **simple resection**
b) if frozen uncertain / malignant (frozen can be wrong!) → close → **further work up****

****staging** (PET, CT chest-abdomen-pelvis) + **final path** → **tumor board**

- multiple recurrences, eventual metastatic spread, frequently fatal (5-year survival only 20%)

MALIGNANT TRITON TUMOR - MPNST with rhabdomyoblastomatous component; highly characteristic for NF1.

Rhabdomyosarcomatous component:

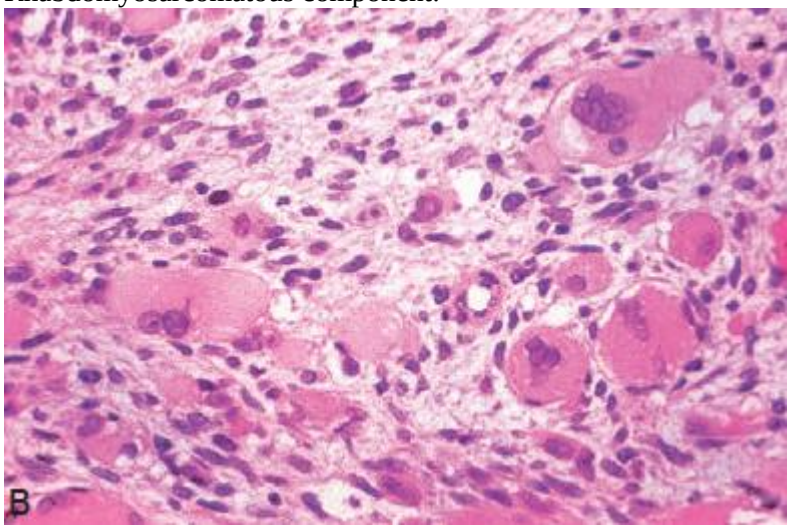

PARASPINAL TUMORS

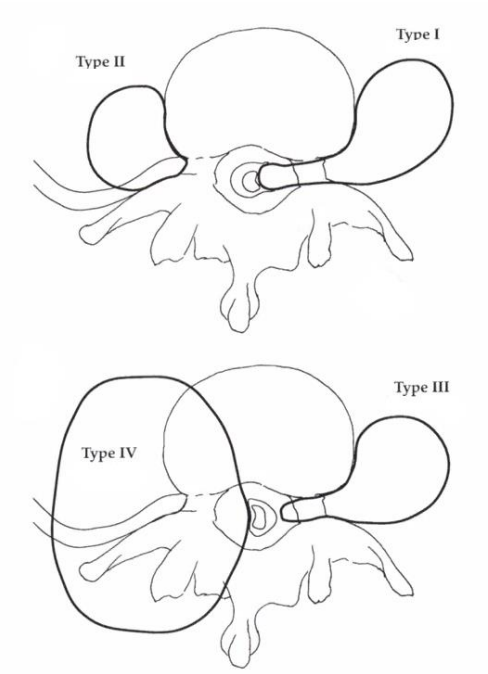

Type I – Dumbbell tumors
Type II – Anterior paraspinal, lateral paraspinal
Type III – Anterior paraspinal with minor foraminal intrusion
Type IV – Significant vertebral, epidural, and paraspinal involvement, e.g. metastasis

Mc Cormick, PC Neurosurgery 38 67-75, 1996

Cervical: laminectomy → anterolateral approach via posterior triangle
Thoracic: laminectomy → lateral extracavitary / transthoracic approach
For type II – thoracoscopy alone

PARAGANGLIOMAS

- benign, slow-growing but locally invasive, highly vascular neoplasms derived from PARAGANGLIA.

Paraganglia (s. chromaffin bodies) – small (< 1.5 mm) roundish bodies, function as **chemoreceptors** in *diffuse neuroendocrine system* (formerly called *APUD*) - specialized neuroendocrine cells of sympathetic (usually *secrete catecholamines*) and parasympathetic (*nonfunctional*) nervous system

1) **glomus intravagale** – minute collection of chemoreceptor cells on auricular branch of vagus nerve, in proximity to ganglion vagale inferior (nodosum).
2) **glomus jugulare** – minute collection of chemoreceptor cells in adventitia of jugular bulb (within jugular foramen of temporal bone).
3) **glomus tympanicum** – on tympanic (Jacobson) nerve (on promontory of middle ear) - most common tumor of middle ear
4) **carotid body (s. glomus caroticum)** – **chemoreceptor** (O_2, CO_2, H^+) innervated by CN9.
5) **glomus pulmonale** – structure similar to carotid body, found in relation to pulmonary artery.
6) **paraaortic bodies (s. glomera aortica, organs of Zuckerkandl)** – chemoreceptors (O_2, CO_2, H^+) innervated by CN10.
7) **coccygeal body (s. glomus coccygeum)** ?

Term "glomus" mistakenly was attached to these organs when their origin was believed to be similar to true glomus (arteriovenous) complexes, and although now recognized as inaccurate, nomenclature has persisted.

PHEOCHROMOCYTOMA – paraganglioma of adrenal medulla.
CHEMODECTOMA – nonchromaffin paraganglioma; i.e. tumor of chemoreceptors in paraganglia (tumor does not include chromaffin cells).

N.B. majority of paragangliomas arising within the skull base and neck region are not associated with catecholamine secretion!

- metastatic behavior is rare (15-35%)

Clinical features

- types of presentation:
  1) asymptomatic incidental finding - painless mass
  2) catecholamine hypersecretion

Diagnosis

- biochemical testing (urinary and/or plasma fractionated metanephrines and catecholamines) is indicated for all.
- imaging: **MRI** (intense enhancement, classic "salt and pepper" reflecting hypervascular signal voids), **angiography** (delayed washout; enlarged *ascending pharyngeal artery* – pathognomonic; trial carotid balloon occlusion).
- genetic testing: patient with skull-base or neck paraganglioma.
- **biopsy** → significant hemorrhage, severe *catecholamine crisis*.

Glomus jugulare tumor

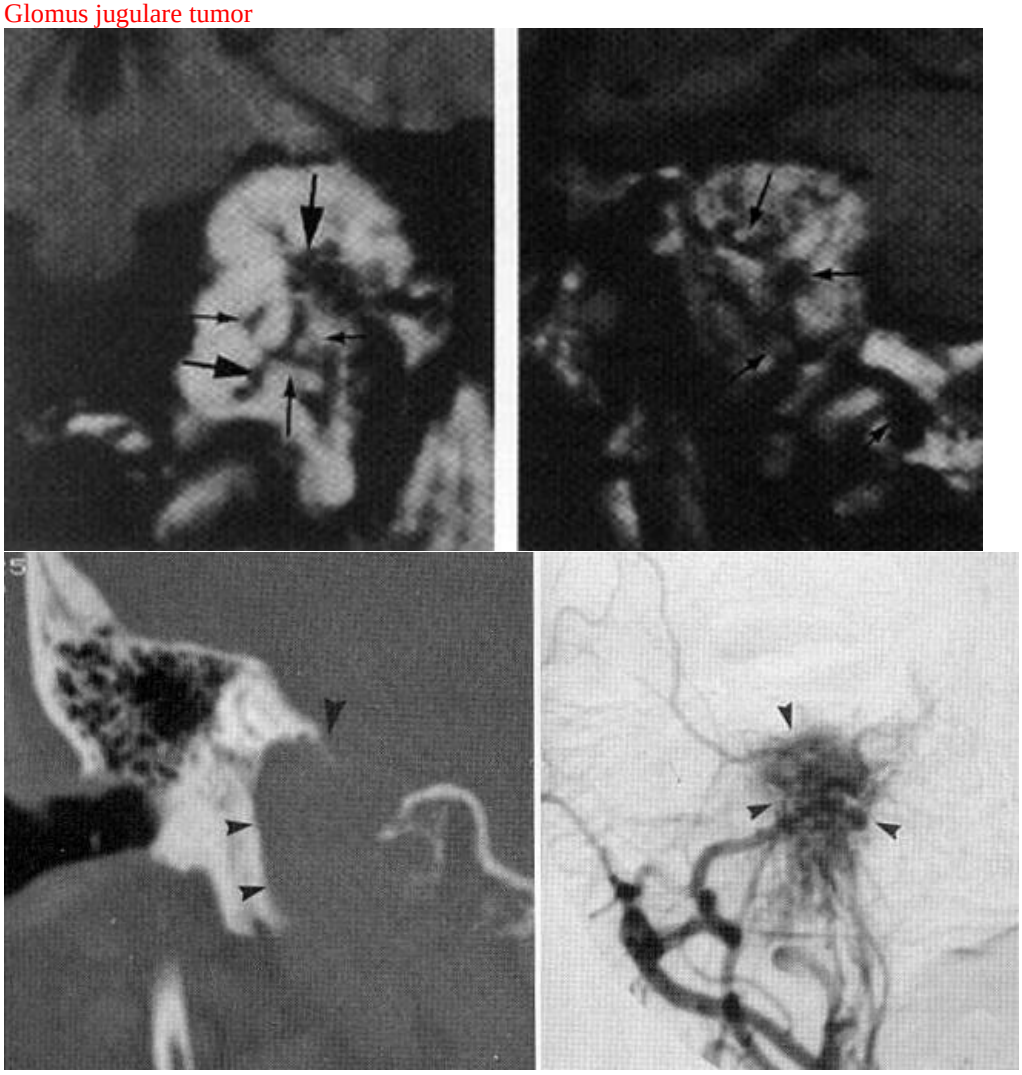

Surgery – treatment of choice! Prognosis is excellent! (94% 20-yr survival)

- preoperative embolization (esp. for > 3 cm, immediately after diagnostic angiogram).
- may need vessel (carotid, jugular) sacrifice – occlusion test with EEG monitoring (→ bypass PRN).

- alpha-blockade (PHENOXYBENZAMINE is the preferred drug) is started 10-14 days before surgery + high-sodium diet (> 5000 mg daily) because of catecholamine-induced volume contraction → orthostasis associated with alpha-adrenergic blockade.

  N.B. *beta-adrenergic blocker should never be started first*
- poor surgical candidate, elderly, subtotal resection → radiation (*radiosensitive** but *not radiocurable*) - Cleveland Clinic uses 14-16 Gy SRS

  *paragangliomas used to be nonsurgical tumors
- postoperatively be aware of baroreflex failure syndrome.

CAROTID BODY PARAGANGLIOMAS

- most common paragangliomas of the skull base and neck

- painless pulsatile mass in the lateral neck → dysphagia, deficits of cranial nerves VII, IX, X, XI and XII, hoarseness, Horner's syndrome.
- mass is more freely movable in the horizontal plane than vertically - **Fontaine's sign**.