

Red Eye

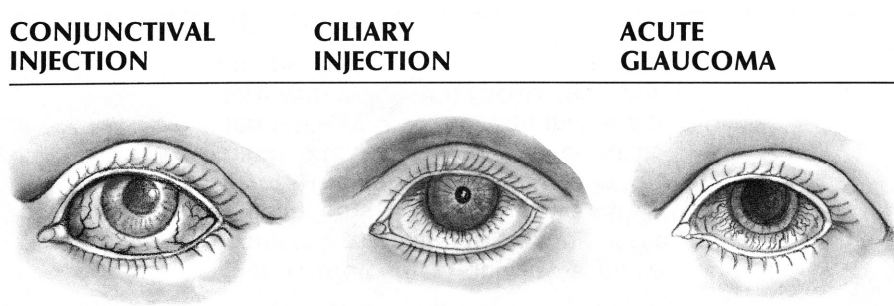
Updated: May 22, 2010

- caused by **dilation of blood vessels** - cardinal sign of **ocular inflammation**.

Diagnostic algorithm:

- 1) **fluorescein staining** – detects **corneal etiologies** (abrasions, keratopathy, ulcers, infection).
- 2) **measure intraocular pressure** - detects **acute glaucoma**.
- 3) **check anterior chamber** - inflammatory cells suggests **iritis** or **endophthalmitis**.

for types of eye vessel dilation → see p. Eye78 >>



	Acute Conjunctivitis	Acute Iritis	Acute Glaucoma	Episcleritis / Scleritis
Pain	+ (burning)	++, photophobia	++++ (with nausea, vomiting)	+ (irritation) / +++
Vision	normal	↓	↓↓↓	normal
Discharge	mucopurulent	lacrimation	lacrimation	lacrimation
Hyperemia	conjunctival diffuse (globe + eyelids)	circumcorneal	circumcorneal & conjunctival	large patch (20-100%) of bulbar conjunctiva
Cornea	normal	transparent, precipitates on posterior surface	cloudy (edema)	normal
Iris	normal	dull, swollen	congested and bulging	normal
Pupil	normal	irregular miosis, minimally reactive	mid-dilated, unreactive	normal

Primary care physicians should refrain from treating any patients with steroids without ophthalmologic consultation!

BIBLIOGRAPHY for ch. "Ophthalmology" → follow this [LINK](#) >>