Surgery for Movement Disorders

Last updated: January 16, 2021

Condensed Table of Contents

METHODS **5**
DEFINITION, PHYSIOLOGY **6**
BENEFITS **6**
INDICATIONS **7**
CONTRAINDICATIONS **11**
PATIENT COUNSELLING **11**
PREOPERATIVE WORK UP **12**
CLINICAL TRIALS - PRINCIPLES **12**
TARGETING (TARGET LOCALIZATION) **13**
TRAJECTORIES (PRINCIPLES) **20**
TARGETS **21**
LESIONING SURGERY **57**
TARGETING PLATFORMS **60**
FRAME LINK **61**
O-ARM **66**
DBS HARDWARE **67**
DBS ELECTRODE IMPLANTATION **77**
PLACEMENT OF DBS EXTENSIONS AND GENERATOR **86**
REPLACEMENT OF DBS GENERATOR **88**
EXPLANTATION OF DBS LEADS **89**
POSTOPERATIVELY **89**
FOLLOW UP, PROGRAMMING **92**
COMPLICATIONS **94**
OUTCOMES **98**
FUTURE PERSPECTIVES **100**

Detailed Table of Contents

Resources 5
METHODS **5**
DEFINITION, PHYSIOLOGY **6**
DBS 6
BENEFITS **6**
Improvement of Symptoms 6
Neuroprotection 7
INDICATIONS **7**
According to disorders 7
According to symptoms 9
Tremor 9
Dystonia 9
Gait disturbances 9
Speech Problems 10
Medication side effects / suboptimal efficacy 10
Neuropathic Pain 10

COMPARISONS OF DIFFERENT NUCLEI 10
CONTRAINDICATIONS 11
PATIENT COUNSELLING 11
Goal of DBS 11
Complications 12
PREOPERATIVE WORK UP 12
Off/on testing 12
Neuropsychological Evaluation 12
Physical exam 12
CLINICAL TRIALS - PRINCIPLES 12
Parkinson's disease 13
TARGETING (TARGET LOCALIZATION) 13
COORDINATE SYSTEM 13
IMAGING 14
Imaging modalities 14
Intraoperative CT 14
A. Direct 15
B. Indirect (Atlas-based mapping) 15
MRI 15
Ventriculography 17
Target coordinates 17
ELECTROPHYSIOLOGIC SIGNATURES – MER (MICROELECTRODE RECORDING) 18
Multiple MER tracks 19
Commercial platforms 19
Leadpoint system (Medtronic) 19
Micro guide Pro (Alpha Omega, Nazareth, Israel) 19
STIMULATION 19
ERRORS IN TARGETING 19
AWAKE VS. ASLEEP DBS 20
TRAJECTORIES (PRINCIPLES) 20
TARGETS 21
STN 21
History 21
Indications, Side Effects 21
Imaging 22
Coordinates 23
Electrophysiology 30
Stimulation 32
Malpositioned electrode 32
VENTRALIS INTERMEDIUS (VIM) NUCLEUS OF THALAMUS (S. VENTRAL LATERAL NUCLEUS) 33
Indications 35
Imaging 35
Side Effects 35
Coordinates 36
Electrophysiology 40
Stimulation 42
Malpositioned electrode 42
GPI 47
Indications, Side Effcets 47
Imaging 47
Trajectory 48

Coordinates 48
Electrophysiology 52
Microstimulation 55
Nucleus topography 56
LESIONING SURGERY 57
Drawbacks 58
RF 58
Thalamotomy 58
Bilateral thalamotomy 59
Pallidotomy 59
SRS 59
FOCUSED ULTRASOUND 60
TARGETING PLATFORMS 60
STEREOTACTIC FRAME 60
STARFIX SYSTEM 60
CLEARPOINT® SYSTEM 60
Procedure details 60
ROSA ROBOT 60
MAZOR ROBOT 60
FRAME LINK 61
PLANNING 61
Managing exams 61
Planning 62
Calculate bur hole position 63
Burning CD / USB 64
INTRAOPERATIVELY 64
O-arm 64
Fiducials 65
Registration 65
Setting trajectory 65
Microelectrodes in 66
O-ARM 66
"Nexframe O-arm" mode (fiducial-less) 67
DBS HARDWARE 67
DBS PULSE GENERATORS (IPG) 67
Medtronic 67
Activa® PC (model 37601), Kinetra (model 7428) 67
Activa® RC (model 37612) 69
Activa® SC (models 37602, 37603), Soletra (model 7426) 70
Medtronic – Closed-Loop s. Adaptive DBS (aDBS) 72
Percept® (model B35200) 72
Boston Scientific 72
Vercise 72
St. Jude 72
Infinity 72
"POCKET" ADAPTORS 72
DBS ELECTRODE LEADS 73
Medtronic 73
Abbott / St. Jude - Infinity 75
DBS ELECTRODE LEAD CANNULAS 76
Alpha Omega 76

DBS EXTENSION LEADS 77
Medtronic (model 37086) 77
DBS ELECTRODE IMPLANTATION 77
PREOP 77
ANESTHESIA 77
POSITIONING 78
Bone fiducials 79
Fiducial-less 79
APPROACH 79
Bone fiducials 79
Incision 80
Bur Hole 80
Fiducial-less 81
Dura opening 81
INSERTION 81
Drives 82
MICROELECTRODE RECORDING (MER) 82
STIMULATION 83
VTA (volume of tissue activated) 83
Beneficial Effects 83
Side Effects 83
Micrelectrode Stimulation 84
Macrostimulation 84
DBS LEAD INSERTION 84
END 84
POSTOP (IN HOUSE) 85
SPECIAL SITUATIONS 85
Bilateral surgery 85
GPi under general anesthesia without MER 85
Revision of DBS due to lack of efficacy 85
Pediatric Patient 86
PLACEMENT OF DBS EXTENSIONS AND GENERATOR 86
ANESTHESIA 86
CHOOSING SIDE 86
POSITION 86
INCISION 86
DETAILS 87
CLOSURE 87
POSTOP 88
REPLACEMENT OF DBS GENERATOR 88
INDICATIONS 88
PREOPERATIVELY 88
ANESTHESIA 88
POSITION 88
OPERATIVE DETAILS 88
POSTOP (IN HOUSE) 89
EXPLANTATION OF DBS LEADS 89
POSTOPERATIVELY 89
Wound care 89
Electrosurgery 89
MRI 90

Follow-ups 92
FOLLOW UP, PROGRAMMING 92
GPi 93
VIM 93
Battery capacity 94
COMPLICATIONS 94
Bleeding 95
Infection 95
Ischemic Stroke 96
Venous air embolism 96
Adverse Effects 96
Behavior and Neuropsychiatric Complications 96
Hardware-related postoperative Complications 97
Lead fractures 97
Erosion 98
"Bowstringing" or "wire tethering" 98
Lead migration 98
Foreign body reaction 98
OUTCOMES 98
Tremor 98
Dystonia 99
FUTURE PERSPECTIVES 100
IMPROVEMENTS 100
ALTERNATIVES 100
STEREOTACTIC NEUROSURGERY – see p. Op30 >>
DBS USING ROSA ROBOT – see p. Op40 >>
O-ARM – see p. Op140 >>

RESOURCES

Medtronic - DBS for STN, GPi, VIM - 3D Anatomy >>
Medtronic - DBS for STN, GPi, VIM - Active Fact Sheet >>

http://professional.medtronic.com/pt/neuro/dbs-md/prod/index.htm#tabs-3 – read this!!!

METHODS

A) **ABLATIVE** (e.g. stereotactic lesioning) – largely irreversible but some symptoms may recur.

B) **NEUROMODULATION** (e.g. deep brain stimulation) can reversibly (!) inactivate function (of any target structure) - by high-frequency overstimulation (depolarization blockade); risks of foreign bodies and thin electronic wires that can break; general radius of action – 2 mm (but voltage dependent).

DEFINITION, PHYSIOLOGY

DBS

- placing electrodes deep into brain to stimulate subcortical structures with electrical current.
  - DBS stimulates axons (not cell bodies).

Proposed mechanisms of DBS:
1) target inhibition - classic reversible functional lesioning paradigm ("reversible functional lesion" - depolarization block of efferent activity, local GABA-mediated inhibitory effects).
2) target activation
3) combined target inhibition and activation
4) disruption of pathological ongoing oscillations to restore rhythmic activity and synchronization ("noisy signal" hypothesis s. "modulation of brain rhythms" hypothesis)

About the effects of various stimulation parameters – *see below >>*

BENEFITS

IMPROVEMENT OF SYMPTOMS

The main instrument for analyzing intensity of symptoms in patients with PD is UPDRS. This scale has been validated by evidence-based medicine studies[156] and is considered reference standard in comparison to other less specific and global scales[157],[158] or those specially aimed at QOL (e.g., Parkinson's Disease Questionnaire [PDQ-39]).[8,49,71,80,107,112,115,159-170] The estimated decreases in absolute UPDRS-II (activities of daily living) and UPDRS-III (motor) scores after surgery in stimulationon/ medication-off state versus preoperative medication-off state were 50% and 52%, respectively.[9,49,71] Neurostimulation results in significantly greater improvements than medication alone in PDQ-39 and the UPDRS-III. The mean UPDRS-III score improves by 41% in medication-off state and by 23% in the medication-on state.[49] The STN-DBS–associated improvement in UPDRS-III, as compared with baseline values, is stable over time, 66% and 54% at 1 and 5 years, respectively; in additional studies with follow-up periods ranging from 2 to 4 years, improvement of 43% to 57% was reported.[79,80,165,171-173] The improvement was 70% to 75% for rigidity and tremor and 50% for akinesia. STN-DBS has direct effect on off-period dystonia, which was observed in 71% of patients preoperatively and in only 19% and 33% at 1 and 5 years, respectively. Postural stability and gait also improve, but speech improves only during first year and then progressively returns to baseline at 5 years. UPDRS-II improves similarly, but with significant worsening over time. The average postoperative reduction in dopaminergic drugs was 50%[49] to 56%.[129] As result, levodopa-induced dyskinesias, ensuing disability, and their duration are decreased by 69%, 58%, and 71%, respectively, which has major impact on QOL.[49],[52] This finding mainly reflects desensitization secondary to both long-term stimulation-induced neuronal plasticity and levodopa withdrawal. [174-176] This is explained by mechanism of induction of dyskinesia related to pulsatile administration of levodopa.[53] As stated earlier, decrease or arrest of these pharmacologic adverse effects achieved by the beneficial effects of STN stimulation restores more normal pharmacokinetic regimen of striatal dopaminergic receptors. On-period motor symptoms are moderately[112],[163] or not[8] improved by STN-DBS. Moreover, these UPDRS-III data neglect temporal dimension of improvement in that fluctuating benefit after drug intake is replaced by stable improvement reflected by an increase in "on" time of about 47% to 71%.[9,49,52,71,112,160,166] Speech is generally less improved with STN-DBS[8,9,112] than other parkinsonian signs. Hypophonia may improve, or dysarthria may be aggravated because of diffusion of current to corticobulbar fibers.[177] As a consequence, patients' satisfaction, particularly regarding hypophonia and ability to communicate with their family, can decline after surgery. Improvement in sleep architecture[178] and quality[179] have been reported, with increase in total sleep time (by as much as 47%) resulting indirectly from improvement in nighttime akinesia and early morning dystonia.[178] STN stimulation can also be effective in improving voiding control by decreasing detrusor hyperreflexia.[180],[181] Progression of symptoms over time closely resembles natural history of PD with medical treatment but without motor complications. Therefore, these changes are believed to represent progression of the disease rather than side effects of stimulation. This is compatible with longitudinal positron emission tomography (PET) study showing continuous decline in dopaminergic function in patients with advanced PD managed with clinically effective bilateral STN-DBS, and rates of progression were within range of previous studies in nonstimulated patients.[182]

Improvement in Quality of Life

QOL is direct index of what patients expect from treatment. A large randomized controlled multicenter study involving 156 patients compared bilateral STN-DBS in combination with medical treatment versus best medical therapy alone over 6-month period.[49] Neurostimulation resulted in improvements of 24% to 38% in PDQ-39 subscales for mobility, activities of daily living, emotional well-being, stigmata, and body discomfort and 22% improvement in physical summary score of 36-item short-from health survey (SF-36) versus practically no change in medication group. The mean improvement in PDQ-39 summary index score was 24%, and dyskinesia score in off-medication patients was improved by 54%. The total number of adverse events was higher in medication-only patients. This result confirmed previous uncontrolled studies on QOL after STN-DBS[183],[184] that consistently reported greater improvements in subscores of mobility, activities of daily living, stigmata, emotional well-being, and body discomfort than in social support, cognition, and communication.[183] The QOL of caregivers was also improved.[130]

Medications and Stimulation Settings

After surgery, most groups use dopamine agonists rather than levodopa to avoid risk of dyskinesias. This strategy has not yet been validated by controlled studies. With 5 years of follow-up after STN-DBS, levodopa was still arrested in third of patients, decrease in levodopa-equivalent dose was 67%, similar to that at 1 year,[9] and less than 1% took any dopaminergic drugs. A dramatic and early reduction in medication intake may have accounted for some of the complications, such as dysarthria, apathy, and cognitive problems.[9],[185] The amplitude of stimulation was 2.9 ± 0.6 V, frequency was 139 ± 18 Hz, and pulse duration was 63 ± 7.7 μsec. Monopolar stimulation was used in majority of patients in most studies, with comparable values.[112] There is no indication of tolerance in that effects were stable over 5-year period, with no increase in stimulation parameters after first year.[9] STN-DBS is mostly bilateral because candidates for surgery usually exhibit bilateral motor symptoms and effects of unilateral stimulation are primarily contralateral[7] and do not provide maximal improvement in walking,[7],[186] except in some patients with asymmetric motor symptoms.[187] Postoperative management of dopaminergic drugs may be difficult after unilateral STN-DBS. The batteries may last up to 7 years.

NEUROPROTECTION

It has been demonstrated that in parkinsonian patients, as well as in animal models, neuronal activity of the STN is profoundly altered, with appearance of rhythmic pattern composed of bursts, in addition to a general increase in firing rate. STN neurons are glutamatergic, and glutamate is an excitatory amino acid that has excitotoxic effects on dopaminergic neurons of projection area of STN. The increased glutamate output of STN on dopaminergic neurons of SNc participate in their degeneration, which led to idea that decreasing output by antagonists such as MK-801 would slow down degeneration process involving dopaminergic neurons.[30] Because one of mechanisms of HFS might be a decrease in firing rate of neurons submitted to this type of stimulation, one can suppose that this (as well as ablation of this structure) would play similar role and would be slowing down neurodegenerative process involving nigral dopaminergic system. Several studies in rodent and primate models of PD have provided experimental evidence that manipulation of STN, by either lesions or long-term stimulation, can protect dopaminergic neurons in SNc and significantly decrease cell loss induced by neurotoxins used in these models.[31,35,38,142,188-192] In humans, only study using PET scanning did not confirm these experimental data, but it was performed in patients with very advanced stage of disease.[182] One may also consider that in early stages, the putative neuroprotective effect might not only slow down neurodegeneration but also allow the dopaminergic neurons that had lost their dopaminergic production but were still alive[193] to recover sufficiently to again produce dopamine, which would stabilize but even improve patient's condition. To clarify this important issue, there is an urgent need for controlled randomized clinical trials of patients investigated with both clinical and nonclinical tests (such as PET) and operated on early enough in the course of disease.

INDICATIONS

ACCORDING TO DISORDERS

Originally treatment for essential tremor (FDA approval in 1997), DBS is now used / under investigation across wide spectrum of neurological and psychiatric disorders:

1. **Movement disorders**:
    1) **PD** (if PD is nonresponsive to medications, patient is poor candidate for DBS with the exception of tremor)
        - FDA approved in 2002.

- "positive" symptoms (tremor, rigidity, and bradykinesia) improve substantially; "negative" symptoms (balance) are typically refractory; gait has a variable response (freezings that respond to levodopa, tend to respond to DBS).
- ideal patient – classical L-dopa-responsive Parkinson's disease with worsening unpredictable wide fluctuations in medication response.
- good candidates for surgery typically have > 30% improvement in UPDRS motor score with levodopa challenge.
- beware *"Parkinson's plus" syndromes* - unlikely to benefit from DBS.
- there are no insurance requirements of how severe UPDRS has to be and how much it has to respond to medications.

N.B. symptoms not part of idiopathic PD triad (dementia, autonomic disorders, cognitive decline and dementia, oculomotor disturbance, and so on) are not usually improved significantly!

Dr. Holloway: DBS improves **tremor** 80%*, **other PD symptoms** 40-60%** (but only if responsive to medications)

*compare: Class I evidence exists for propranolol and primidone as first-line medications that reduce tremor by approximately 60% in 50% of patients
**parkinsonian dystonia and dyskinesias respond better than 40-60%

2) **ET**
   - FDA approved in 1997.
   - tremor control is best for arms and tends to be better for distal tremors than for proximal ones.
   - head or vocal tremors are typically refractory (they may be improved with ***bilateral implantation***, but this cannot be accurately predicted).

3) **dystonias** see below >>
   - FDA approved in 2003.

2. **Epilepsy** see p. E >>

3. **Psychiatric disorders**:
   1) OCD see p. Psy25 >>
   2) depression see p. Psy17 >>
   3) Gilles de la Tourette's syndrome
   4) addiction – nucl. accumbens, ALIC (anterior limb of internal capsule)
   5) post-TBI frontal dysfunction see p. TrH1 >>

4. Chronic **pain disorders**

5. **Minimally conscious and vegetative states** see p. S32 >>

6. **Obesity**

7. Alzheimer's disease and other **dementias**. see p. S11 >>

ACCORDING TO SYMPTOMS

TREMOR

(essential tremor, Parkinson's disease, multiple sclerosis*, myoclonic tremor in myoclonus dystonia).
*outcomes are much less predictable and tremor control is less effective than in essential tremor

1. **Ventralis intermediate (VIM) nucleus of thalamus**; likely where ***dentato-rubro-thalamic tract*** ends
   Coenen VA "Modulation of the Cerebello-thalamo-cortical Network in Thalamic Deep Brain Stimulation for Tremor: A Diffusion Tensor Imaging Study." Neurosurgery. 2014 Aug 25.
   Effective contacts were located inside or in proximity to dentato-rubro-thalamic tract. In moderate tremor reduction - on its anterior border. In good and excellent tremor reduction - on its center.
2. Caudal **zona incerta (cZI)** – may give good tremor control (probably same as VIM).
3. **Posterior subthalamic region (PSA)**

- 2 circuits that are thought to contribute to the essential tremor pathophysiology are the Guillain-Mollarets triangle and the dentorubrothalamocortical tract.

DYSTONIA

- not a cure, but long-term therapy whose efficacy doesn't wane significantly.
- primary generalized dystonias respond best! DYT1-positive dystonia has 80-95% response rate (dyskinesias respond first) to DBS.
- segmental dystonias also respond well.
- secondary dystonias (e.g. TBI, cerebral palsy) – DBS is off-label use; outcomes are less predictable and usually more limited (possible exception - tardive dystonia - increasing evidence for DBS effectiveness).
- **GPi** – target is slightly different than for PD. Implantation is always **bilateral**!
- improvement is frequently not observed during intraoperative testing; several months of stimulation and programming may be required before significant improvements are detected.
- **Parkinsonian dystonia** – GPi and STN help for both medication-responsive and –nonresponsive dystonia (GPi is better for "on" dystonia).

Outcomes of DBS for dystonia – see below >>

GAIT DISTURBANCES

Freezing is part of patterns of akinesia and usually responds to levodopa treatment. When freezing of gait occurs, persists, and is not improved in on-medication period, it is not usually improved by STN or GPi DBS (but might be improved by low-frequency stimulation of new target, such as PPN) - should be taken into account during decision-making and counseling process.
Summary: if gait freezing is responsive to medications, DBS may help.

Postural stability – DBS helps.

Falls – may increase after DBS as patients become more mobile.

SPEECH PROBLEMS

- speech is usually improved, but much less than other motor symptoms.
- **GPi** is not helpful.
- when patients are hypophonic before surgery, hypophonia might be impaired or worsened afterward, particularly when doses of medication are significantly decreased, which might not be compensated for by improvement from DBS.
- **voice tremor** (check with sustained "eeee" for 5 seconds) usually needs bilateral **VIM** but exceptions exist; don't get confused with spasmodic dysphonia (Botox may help for it).

MEDICATION SIDE EFFECTS / SUBOPTIMAL EFFICACY

- **GPi** helps for both medication-on and –off dyskinesias.
- AMANTADINE is mostly used for dyskinesias so often can be stopped after DBS.

NEUROPATHIC PAIN

Centrolateral thalamus

COMPARISONS OF DIFFERENT NUCLEI

Feature	GPi	STN	VIM
Speech	Less affects but also does not help	More problems	Dysarthria is common
Tremor	Helps only tremor responsive to medications	Helps with tremor responsive and unresponsive to medications	Helps with tremor responsive and unresponsive to medications
Dystonia	GPi helps for both medication-responsive and –nonresponsive (GPi better for "*on-meds*" dystonia)	STN helps for both medication-responsive and –nonresponsive (STN better helps "*off-meds*" dystonia)	
Bradykinesia		STN is better than GPi	
Dyskinesia	GPi helps for both medication-*on* and –*off* dyskinesias	STN helps by decreasing levodopa dose (GPi is better for *off* dyskinesia) N.B. STN DBS may induce dyskinesias!	
Falls, gait disturbance		Significant worsening with STN DBS (vs. best medical management)	
Levodopa usage reduction	3%	Up to 3-fold (38%)	
Neurocognitive measures*	Better than STN	Slight but significant worsening** with STN	

		DBS (vs. best medical management)	
Depression	Better than STN	Slight worsening with STN DBS (vs. best medical management)	

*working memory, processing speed, delayed recall, phonemic fluency (esp. for elderly people)
**selectively of frontal cognitive functions

FOG (freezing of gait) – improves with PPN DBS but effect lasts only several months

CONTRAINDICATIONS

1) **parkinsonism-plus syndromes / parkinsonism unresponsiveness to levodopa**

2) ≥ **moderate cognitive dysfunction**
   Dementia usually starts 10 years* after PD diagnosis (protective factors – tremor-predominant, no axial symptoms, young-onset PD [dementia is delayed until age 70])
   *if much earlier – Lewy body dementia
   Patient must be able to properly operate the neurostimulator.
   Dementia, as well as cognitive deficits, are not improved by DBS and might even be made worse by trauma of surgery.
   N.B. patients with cognitive decline or full-blown dementia may be at increased risk for DBS
   Limousin P, Krack P, Pollak P et al. (1998). Electrical stimulation of the subthalamic nucleus in advanced Parkinson's disease. N Engl J Med 339: 1105–1111.
   Hariz MI, Johansson F, Shamsgovara P (2000). Bilateral subthalamic nucleus stimulation in a Parkinsonian patient with preoperative deficits in speech and cognition: persisting improvement in mobility but increased dependency: a case study. Mov Disord 15: 136–139.

3) **anxiety** – difficulty postop DBS programming;
   if anxiety is reactive to PD, then DBS helps;
   if anxiety is lifelong, then patient knows how to cope with it;
   worst if anxiety is due to PD affecting limbic circuits – patients very difficult to program.

4) **depression** – risk of postop suicide, so must be controlled and psychiatrist established preop.

5) **general surgical contraindications** (anticoagulants, terminal cancer, infectious disease, immunodeficiency, poorly controlled HTN, and so on); for diabetics, HbA1c has to be < 8.0%

PATIENT COUNSELLING

GOAL OF DBS

– achieve the best score as patient had on meds* preop and smoothen fluctuations!

*this applies only to early stages of PD; in advanced stages, PD patients are frozen no matter how much medication they get (becomes obvious if DBS battery dies)

COMPLICATIONS

See below >>

PREOPERATIVE WORK UP

OFF/ON TESTING

- to establish baseline
- to detect other PD features - will require GPi in otherwise "only tremor" patient, i.e. in patients with seemingly only resting tremor (VIM would suffice).
- to establish which features respond to medications.

NEUROPSYCHOLOGICAL EVALUATION

- to establish baseline and detect contraindications (see above):
  1) cognitive decline
  2) anxiety
  3) depression

PHYSICAL EXAM

- check scalp skin (treat lesions prior to DBS).
- check chest skin; if there is pacemaker, DBS IPG should be implanted > 8 cm from it (not to interfere with programming).

CLINICAL TRIALS - PRINCIPLES

- crossover studies are common in neuromodulation: after being implanted with stimulation systems, patients are often randomized to receive active ("on") or sham ("off") stimulation for a period of time, followed by inverse treatment.
- confounder effects in DBS studies include:
  1) **carryover effect** (ie. persistence of clinical improvement after stimulation is discontinued)
  2) **insertional effect** (ie, improvement in clinical scores due to implantation of electrodes and not delivery of stimulation per se).
- DBS effects are:
  a) **immediate** (e.g. tremor control)
  b) **accrue over weeks to months** (e.g. dystonia) – careful with crossover studies!
- patients must receive active or sham stimulation with **washout period** (ie, stimulation discontinued) in between crossover arms.
- studies with ***open-label phase before blinded evaluations*** (ie, comparing active and sham treatment) - patients exposed to therapy and know what to expect from therapy before blinding.

- in functional neurosurgery, results from double-blind studies often vary from those recorded in open-label trials, thus, significant improvement is:
  A. In double-blind studies comparing active ("on") vs. sham stimulation ("off"), differences between scores must reach statistical significance AND have ***magnitude of ≥ 25%.***
  B. In open-label studies, there must be ***≥ 35% improvement*** when postoperative "on" stimulation scores are compared with those recorded before surgery.

PARKINSON'S DISEASE

- outcomes to test:
  1) improvement in UPDRS Part III "off" medication score
  2) increase in "on" medication time without troublesome dyskinesia
  3) improvement in dyskinesia rating scale "on" medication score
  4) decrease of levodopa equivalent daily dose*
  5) UPDRS Parts II and IV, total UPDRS
  6) cognitive or mood declines

*LEDD = a dose of 100 mg levodopa, which is equal to 125 mg controlled-release levodopa, 10 mg bromocriptine, 1 mg pergolide, 4 mg ropinirole, 100 mg amantadine, 333 mg entacapone, 1 mg pramipexole, and 80 mg Stalevo (according to Wenzelburger et al., 2002)

- 5-point difference in UPDRS represents ***minimum difference for clinical significance***; given mean of 30 and variance of 13.7 (as reported in the study by Weaver et al.*) — then sample size of > 200 subjects would be required for 80% probability of detecting a clinically meaningful difference** (one-tailed unpaired t test), far more if confidence of 90% is required.

**Weaver FM, Follett K, Stern MB, et al. Bilateral deep brain stimulation vs best medical therapy for patients with advanced Parkinson disease: a randomized controlled trial. JAMA 2009;301:63–73.*

**i.e. exclude type II error

TARGETING (TARGET LOCALIZATION)

Ideal electrode location - track with the longest stretch of active, sensorimotor cells.

1. Imaging
2. Electrophysiologic signatures – MER (microelectrode recording)
3. Intraoperative stimulation

COORDINATE SYSTEM

xyz location: The anterior and posterior commissures are identified on MRI in the StealthStation FrameLink. The roll, pitch, and yaw are corrected through the selection of several midline points. The midpoint between these 2 commissures serves as the zero point, and all other locations on the screen are assigned an xyz location. This allows the operator to then record a location for each object to be measured. The xyz location and the AC-PC location are synonymous.

IMAGING

IMAGING MODALITIES

1. **CT** – stereotactic, without contrast 0.6 mm – reference exam; MRI provides high anatomical resolution, while CT eliminates MRI distortion.
2. **T2**:
   a) axial (VCU)
   b) **cube FLAIR** – GE (VA)
   c) **dark fluid SPACE** - Siemens
3. **T1**:
   a) **T1-weighted 3D Magnetization Prepared-Rapid Acquisition Gradient Echo (MPRAGE)** - sagittal (VCU) or axial (VA); postcontrast – to see vessels.
   b) **Fast Gray Matter Acquisition T1 Inversion Recovery (FGATIR)** on 3T MRI scanner
4. **DTI** (2NEX scan duration 8 minutes; or 3NEX – 12 minutes) – some experts use it routinely asa additional source of information

- MRI scans must be 3D (volumetric), i.e. without gaps between slices.
- best MRI sequences for each target – see individual nuclei below.

	T1-w 3D MP-RAGE	T2-w 3D FLAIR	T1-w 3D FGATIR
Repetition time (TR)	1600 ms	6000 ms	3000 ms
Echo time (TE)	4.38 ms	353 ms	4.39 ms
Inversion time (TI)	800 ms	2200 ms	409 ms
Inversion pulse angle	90°	180°	180°
Matrix	384×288	256×240	320×256
Field of view (mm)	256×192	256×240	256×192
Slices	160×1 mm	160×1 mm	160×1 mm
Orientation	Axial	Sagittal	Axial
Bandwidth	130 Hz/Px	1302 Hz/Px	130 Hz/Px
Acquisition time	6:45 min	12:08 min	11:14 min

INTRAOPERATIVE CT

O-arm

Ceretom – small bore
Bodytom, Airo – large bore, good soft tissue resolution

- if patient cannot have MRI (e.g. pacemaker), intraop ventriculogram can be used: standard EVD catheter is passed free-hand through the right frontal burr hole into the lateral ventricle → Omnipaque 3 cm3 (180 mg/mL) is injected into the ventricle → immediate O-arm;
    - anterior commissure is not well visualized in the ventriculogram as a result of gravitational layering of the contrast but could still be estimated from the preop CT scan (fused to O-arm).

A. DIRECT

- target visually chosen directly from CT / MRI);
    - prior to introduction of CT / MRI, target localization involved injecting ***air*** or ***positive contrast*** into lateral ventricle to outline third ventricular structures (ventriculography) adjacent to diencephalic targets
- with current MRI, **GPi** and **STN** are ***visualized directly***, but **VIM** is derived from Schaltenbrand and Wahren ***atlas***, utilizing intercommissural plane and midcommissural point for reference.
- ongoing debates ***should stereotaxis be just image-guided*** (without MER);
    - Larson et al. place DBS on first trajectory in 98% patients.
    - Montgomery et al. (2012) found that imaging-based targeting was consistent with the physiologically defined target only 70% of the time; in 30% of subjects, additional MER trajectories were required (25% required 2 additional MER penetrations and remaining 5% required 3 additional penetrations).

B. INDIRECT (ATLAS-BASED MAPPING)

MRI

- based upon position of AC-PC:

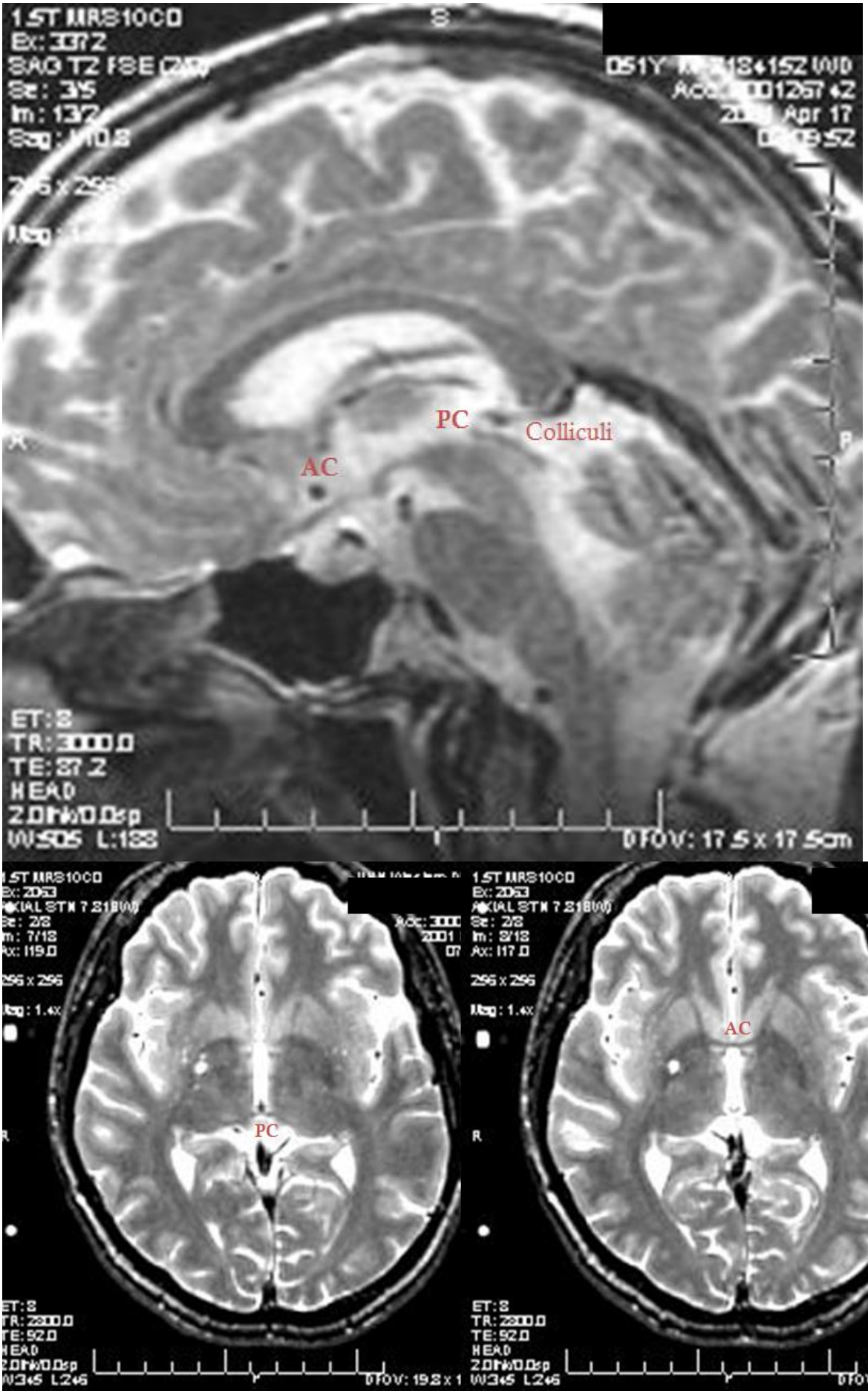
PC
Colliculi
AC
PC
AC

- **AC-PC line** approximates to **orbitomeatal line**.
- choose posterior AC and anterior PC edges that face 3rd ventricle (imitates historical ventriculogram).
- average AC-PC distance is 23-27 mm; greater than 30 mm should raise accuracy concerns.

VENTRICULOGRAPHY

(historical) – relates target position to anterior and posterior commissures.

- large number of centers do not use it for fear of complications or because they consider MRI localization to be satisfactory.
- hole through skull, 9 cm from nasion and 2.5 cm from midline, is created with twist drill.
- right frontal horn of ventricle is tapped with Cushing cannula at depth of 6.5 cm from skin surface.
- 2-mL air bubble is injected to check for correct placement of tip of cannula.
- during injection of 6.5 mL of contrast medium, 12-second sequence of x-ray images is recorded in lateral direction, immediately followed by radiographs taken in anteroposterior direction.
- these x-ray images provide internal landmarks for third ventricle, to which various atlases and coordinates of targets can be related.
- construction of target is based on ventriculographic landmarks:
    1) anterior commissure (AC): 3-4 mm below foramen of Monro.
    2) posterior commissure (PC): 1 mm above superior colliculi, 1 mm below pineal recess.
    3) height of thalamus (floor of lateral ventricle)
    4) midline of third ventricle

A, Ventriculographic determination of target coordinates and final x-ray control of electrodes and implanted generator. In this case, two electrodes had already been implanted in subthalamic nucleus in previous session and connected to Kinetra. Later, freezing of gait developed and patient was scheduled for implantation in pedunculopontine tegmental nucleus (PPN). **B** and **C,** Targeting of PPN based on ventriculogram. **D** and **E,** Final controls after PPN implantation (more medial and more posterior electrodes).

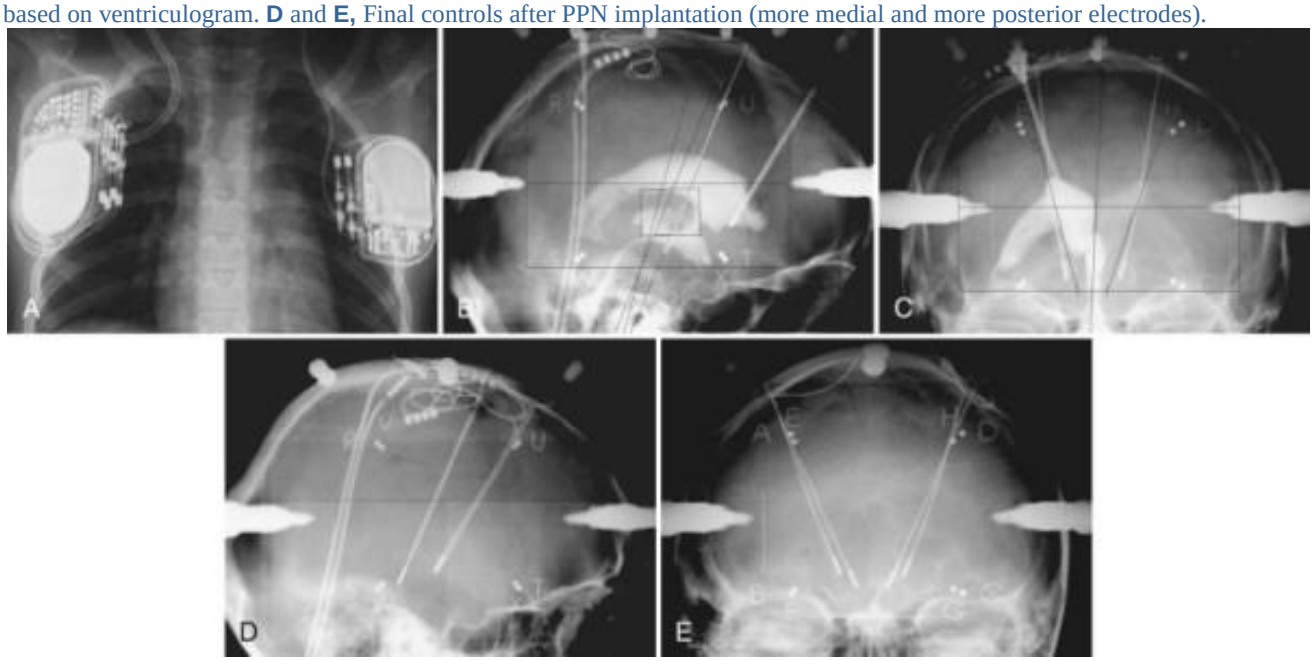

TARGET COORDINATES

A) **Standard fixed coordinates** (Leksell's pallidotomy target is classic example) - relative to midcommissural point – see individual targets

B) **Adjusted map** (**Schaltenbrand-Wahren**) and **grids to adjust map** (**Talairach-Tournoux**)

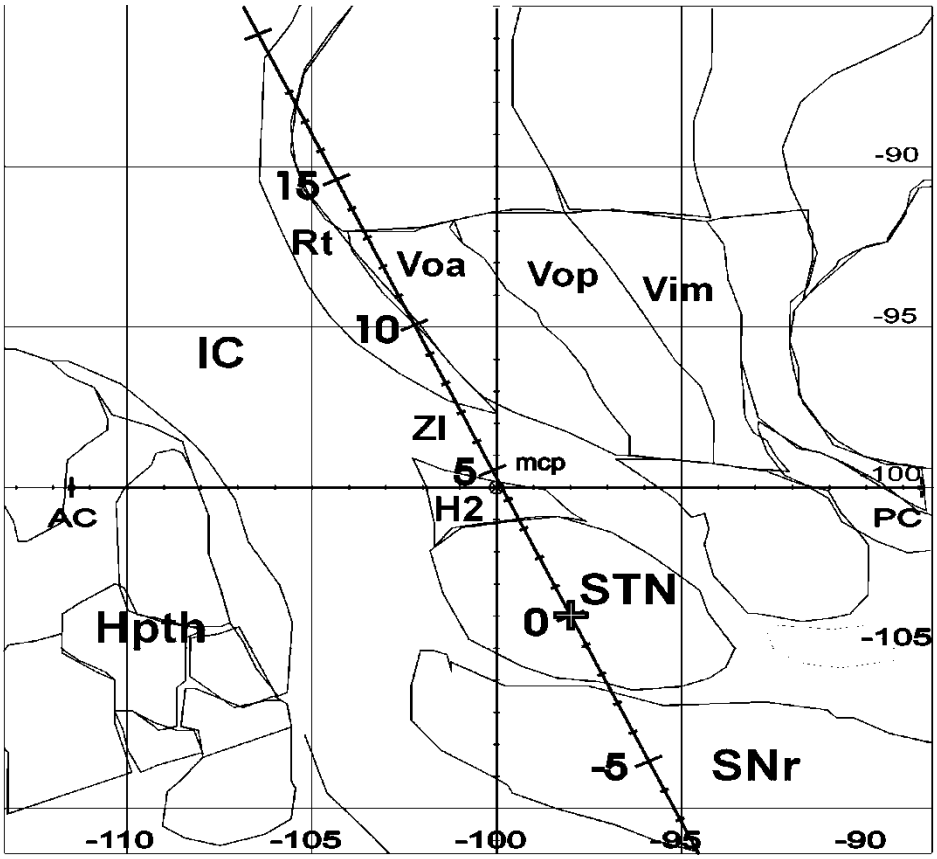

ELECTROPHYSIOLOGIC SIGNATURES – MER (MICROELECTRODE RECORDING)

1) differentiation of (sub)nuclei on basis of intrinsic neuronal firing properties
2) localization of white matter tracts with particular responses to stimulation

MER records single units (single cell, extracellular recordings) – resolution 0.2 mm (vs. local field potentials – 1 mm; ECoG – 1 cm; EEG – 3 cm).

- microelectrodes are designed to ***isolate single action potentials*** and to ***withstand microstimulation***, which degrades electrode - achieved by constructing electrodes from platinum-iridium alloy or from tungsten, producing tapered tip, and insulating with glass.
- microelectrode impedance should be 500-1200 kOhm which is required to isolate single units.
  if < 500 - multi-unit recording will result, and it is therefore more difficult to identify motor responsiveness with the background noise;
  if > 1200 – difficult to capture neuronal responses and electrical interference is problematic
- electrophysiological map is compared with SW atlas → DBS electrode is placed to optimal position.
- *atlas maps can be transformed* to match either AC-PC line in isolation or AC-PC line along with other structures, such as margins of third ventricle or internal capsule.

MRI gets you near target, but physiology proves that you have exact spot!

Maximum precision – **MER + iCT or iMRI**

- MERs can be done using PROPOFOL or DEXMEDETOMIDINE for sedation; if needed MER can be done under DEXMEDETOMIDINE anesthesia.
- MER is used in 83% USA DBS centers (2013 data).

MULTIPLE MER TRACKS

- introducing ***simultaneous*** parallel ME tracks does not reduce target localization errors (as compared to ***sequential*** tracks) but makes it easier to interpret physiological data as there is more clarity on the relative position of each ME.
- Dr. Abosch uses 3 simultaneous tracks for STN

COMMERCIAL PLATFORMS

LEADPOINT SYSTEM (MEDTRONIC)

MICRO GUIDE PRO (ALPHA OMEGA, NAZARETH, ISRAEL)

STIMULATION

- see below >>

ERRORS IN TARGETING

See chapter 15 (Palys, Holloway 2016)

Often leads end up posteromedially – due to friction forces (when inserting cannula) pushing brain in opposite direction.

Hardware imperfections
with Nexframe tends to deviate medially, posteriorly, and superiorly:

TABLE 3. Analysis of the Direction of Error in Targeting of the Parallel Tracks Demonstrate the Preferred Direction of Error and the Tendency to Overshoot or Undershoot the Target Depending on Whether the Track Was Going With or Against the Preferred Direction

Axis of Move	Preferred Direction	Overshoots	Undershoots
Mediolateral	15/20 more medial than intended (P = .01)	3/3 medial moves were overshoots	10/17 lateral moves were undershoots
Anteroposterior	16/25 more posterior than intended (P = .14)	7/9 posterior moves were overshoots	9/16 anterior moves were undershoots
Superoinferior	22/33 were more superior than intended (P = .02)	12/17 superior moves were overshoots	9/15 inferior moves were undershoots

Holloway et al. 2013

Pneumocephalus – usually causes significant shifts only on the second side.

- if a second side is to be done for DBS implantation during the same procedure, it is not useful to adjust the initial second side target based on the first side results.

AWAKE VS. ASLEEP DBS

There are strong expert advocates of either approach.
- awake was a must in early DBS era; current imaging quality permits asleep DBS.
- some argue that asleep DBS is good only in experts hands who trained on awake DBS.

Awake DBS	Advantage	Disadvantage
Outcomes	Only UPDRS-IV off meds is better (all other outcomes are similar to asleep DBS)	
Complications		Higher bleeding rate Higher infection rate

TRAJECTORIES (PRINCIPLES)

- safe trajectory avoids *major blood vessels*, *sulci*, *ventricles*, and areas of *eloquent brain*.
- safe **ENTRY POINT** - within watershed zone between ACA and MCA (or PCA and MCA); this zone is usually centered ≈ 3 (2-4) cm off midline; most frequently, level of coronal suture or within 1-2 cm anterior to it - paucity of draining veins in this area.
- **burr holes** or **larger openings** allow CSF escape + air entry → shift of intracranial structures → suboptimal probe placement; H: use **small twist drill hole** instead.
- risk of hemorrhage is decreased by studying preoperative ***angiograms*** and minimized by preoperative ***stereoangiography***.
  e.g. CT or MRI localizer is replaced with angiographic localizer → digital subtraction angiography → selected views are transferred to computer → computer derives stereotactic coordinates of avascular cortical entry point.
- trajectory (probe tract) goes through white matter - blunt probe tip pushes axons aside (rather than transecting them).

Trajectory planning is accomplished in either of two ways:

A) ***ENTRY POINT technique*** - choosing entry point on scalp; target and entry points define straight trajectory.

B) ***ENTRY ANGLES technique*** (particularly useful when operating on superficial lesions*) - best accomplished with *computer-generated graphic simulation* (if initial angles of trajectory appear unfavorable, computer may be used to modify them, and new angles can then be transferred to stereotactic device); can be utilized with:
   a) ***arc-radius system*** - type of instrument, AP and lateral angles are used to construct trajectory.
   b) ***polar coordinate system*** - some use AP and lateral entry angles; others use horizontal (azimuth) and vertical (declination) angles of entry.

*even slight misplacing of entry point may make trajectory almost tangential to skull (twist drill will need enlarging in order for probe to pass to target).

TARGETS

STN

Comparisons of different nuclei – see >>

- STN has average dimension of 3 × 6 × 4 mm
- ANATOMY, HISTOLOGY & PHYSIOLOGY → A103 >>, A110 (1) >>

N.B. modern discovery – STN has direct communication with motor cortex via internal capsule collaterals – **hyperdirect pathway** – gets stimulated earlier that pyramidal fibers!

HISTORY

- identification of the STN as a target for DBS in the treatment of PD was the direct result of findings in primate models (Bergman et al ., 1990 ; Aziz et al ., 1991).
- Pollak et al. were the first to report STN DBS for the treatment of PD (Pollak et al . 1993).

INDICATIONS, SIDE EFFECTS

1) **tremor** unresponsive to medications (vs. GPi – tremor needs to be responsive to medications)
2) rigidity, bradykinesia.

- STN does job of both VIM and GPi but worse *cognitive & mood outcomes, increased risk of falls.*
- preoperative L –dopa responsiveness predicts STN DBS efficacy.
- 80% chance of 80% reduction in tremor (may add second lead to VIM), but other features of Parkinson's will improve in range of 40-60%.
- STN DBS reduces motor complications equally in all PD patients, QOL improves postoperatively only in patients younger than 65 years.
- bilateral STN – risk of *cognitive & mood problems* (for patients with a hint of psychotic or dementia-related issues – better choose bilateral GPi).

N.B. STN and GPi have similar efficacy in tremor control but *STN causes longterm cognitive problems*, so STN will be used less and less.

0.5% of patients implanted with STN DBS commit suicide due to the development of a major depression (Voon et al., 2008).

EARLYSTIM trial

Schuepbach, et. al. N Engl J Med 368:610- 622

251 patients with an average disease duration of seven years and early motor complications to either subthalamic nucleus (STN) DBS or best medical therapy. This on average was a relatively younger group

of patients (mean age of 52 years) with shorter disease duration and more limited motor complications than those patients included in several of the large, randomized studies which previously compared DBS to best medical therapy. Two years following randomization, the DBS group improved an average of 7.8 points on the PDQ-39 questionnaire, which was the primary quality of life outcome measure, while the best medical group worsened by 0.2 points (p=0.002). Interestingly, several secondary outcome measures not generally believed to improve in traditional DBS patients seemed to respond to neurostimulation in this earlier population. This included on-medication motor function (26 percent improved in DBS vs. 11 percent worse in best medical group; p<0.001) and several patient-reported and objective measures of depression and cognition. As with the intestinal gel study, there was a roughly 98 percent overall adverse-event rate, which did not differ between groups. However, there was a 17.8-percent device-related complication rate, of which included a roughly five-percent rate of infection/wound complications and a 1.6-percent reoperation rate. While this data supports the use of DBS in patients with slightly more mild disease than prior large studies, common practice often includes patients such as those enrolled in this study. Therefore, this study may not dramatically change practice but rather may reinforce the rationale for minimizing delay in considering DBS among patients who are beginning to have motor complications.

IMAGING

- **T2-weighted MRI** - gold standard but STN cannot be reliably visualized (hypointense almond-shaped structure located anterolateral to the red nucleus on coronal, axial, and sagittal planes; surrounded by white matter (zona incerta above and fields of Forel bundles below) separating STN from SNr).
  e.g. FLAIR sequence with TE 140 msec, TR 14,000 msec, slice thickness 2.5 mm, voxel size 1.02, matrix 256 × 256
- STN is best seen in coronal plane.
- STN is not seen on T1.
- hypothesis - contrast of STN relative to surrounding structures is result of iron-concentration specificities of basal ganglia and that T2 effect has to be exploited.
- even at 7 T (more distortions), STN cannot be delineated without special contrast medium, such as ultrasmall superparamagnetic iron oxide.

Siemens protocol - sampling perfection with application-optimized contrasts using different flip angle evolutions (SPACE, Siemens), use nonspatially selective refocusing pulses with short-echo spacing to achieve extended echo trains and subsequent volumetric acquisition of a single slab of thin-slice sections. Such turbo spin echo sequences offer the advantages of being less sensitive to susceptibility artifacts and less sensitive to geometrical distortion artifacts than T2WI sequences at 3 T.[24] With such a sequence, a higher magnetic field may be used to directly visualize the STN and stereotactically target it accurately and reliably
It involves both T2 and T1 effects!

- **susceptibility-weighted imaging (SWI)** - significantly improved visibility of STN compared with traditional T2. However, STN representation on SWI does not correspond to electrophysiological STN borders (21% incongruence - SWI does not correctly display the lateral part of the STN for aiming to target the superolateral sensorimotor part).
  Bot, Maarten "Can We Rely on Susceptibility-Weighted Imaging for Subthalamic Nucleus Identification in Deep Brain Stimulation Surgery?" Neurosurgery: March 2016 - Volume 78 - Issue 3 - p 353–360

- **quantitative susceptibility mapping (QSM)** – offers STN visualization for direct targeting of the sensorimotor STN (QSM demonstrates MER correlation thus obviating the need for MER).
  Rasouli J, Kopell BH et al. Utilization of Quantitative Susceptibility Mapping for Direct Targeting of the Subthalamic Nucleus During Deep Brain Stimulation Surgery. Operative Neurosurgery, *Volume 14, Issue 4, 1 April 2018, Pages 412–419*

Ron L Alterman. Commentary: Utilization of Quantitative Susceptibility Mapping for Direct Targeting of the Subthalamic Nucleus During Deep Brain Stimulation Surgery. Operative Neurosurgery, *Volume 14, Issue 4, 1 April 2018, Pages 420–421*

N.B. if patient cannot get MRI, it is easier to target VIM (than STN) from CT.

COORDINATES

Relative to midcommissural point:

- 4 (1-5) mm posterior
- 4 (3-6) mm inferior
- 12 (11-14) mm lateral

- 4-4-12 coordinates rarely need any adjustment.
- surgeon could elect to modify this position, depending on individual's unique anatomy (e.g., width of third ventricle).

Anatomically: **motor (dorsolateral) STN** (on MRI – medial border is well visible vs. lateral border)
center of STN in AP direction;
slightly lateral in ML direction.

- 3-3.5 mm posterior to the anterior border and 2.5-3 mm medial to internal capsule boundary with deepest electrode contact placed at STN/SNr boundary (but not into SNr)
- best angle of trajectory in sagittal plane - 45°

Alternative – targeting relative to red nucleus:
Axial plane: line is drawn perpendicular to midline, tangent to anterior border of red nucleus, extending 2 mm lateral to medial border of STN:

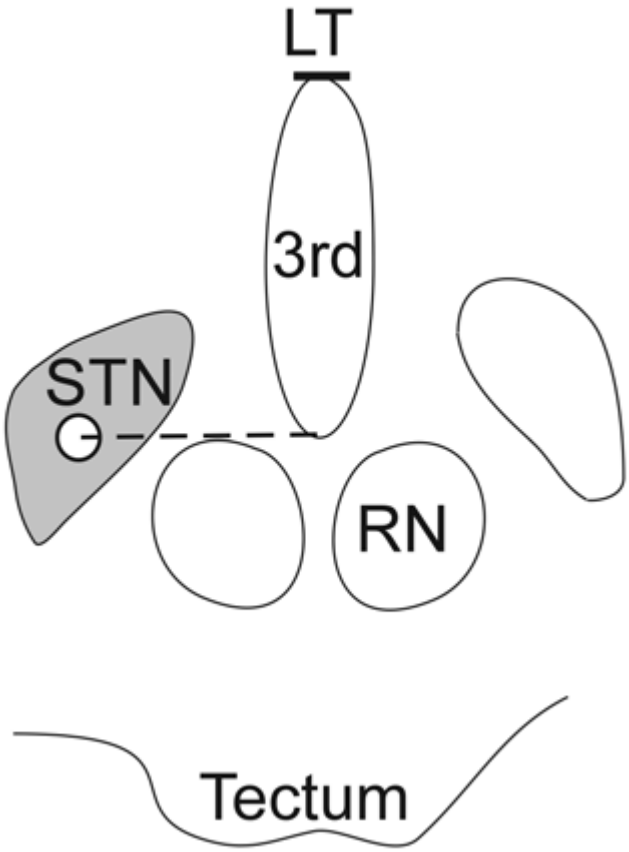

A, axial projection; B, coronal projection:

x - 3 mm lateral to the lateral border of red nucleus
y – anterior border of red nucleus
z - 2 mm inferior to the superior border of red nucleus

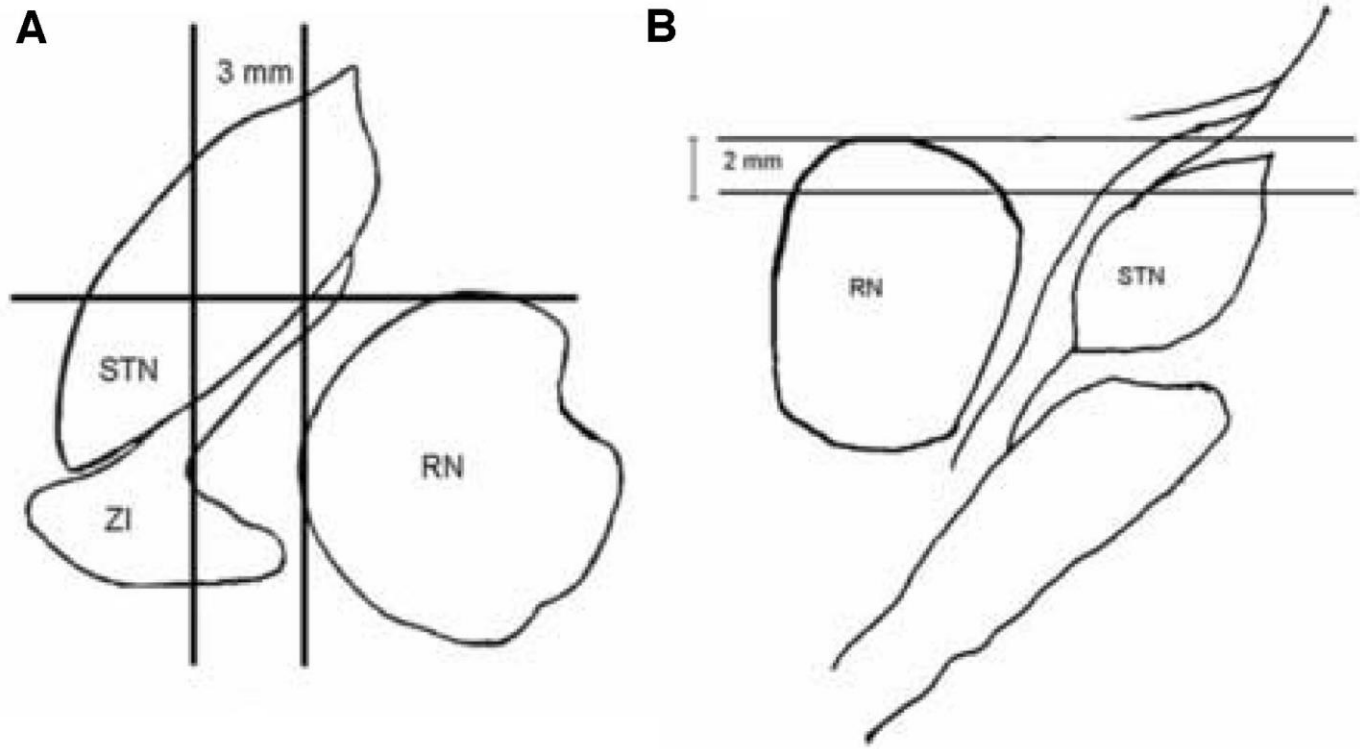

Andrade-Souza,Y.M.; Schwalb,J.M.; Hamani,C.; Eltahawy,H.; Hoque,T.; Saint-Cyr,J.; Lozano,A.M. "Comparison of three methods of targeting the subthalamic nucleus for chronic stimulation in Parkinson's disease" Neurosurgery, 2008, 62 Suppl 2, 875-883

Sagittal:

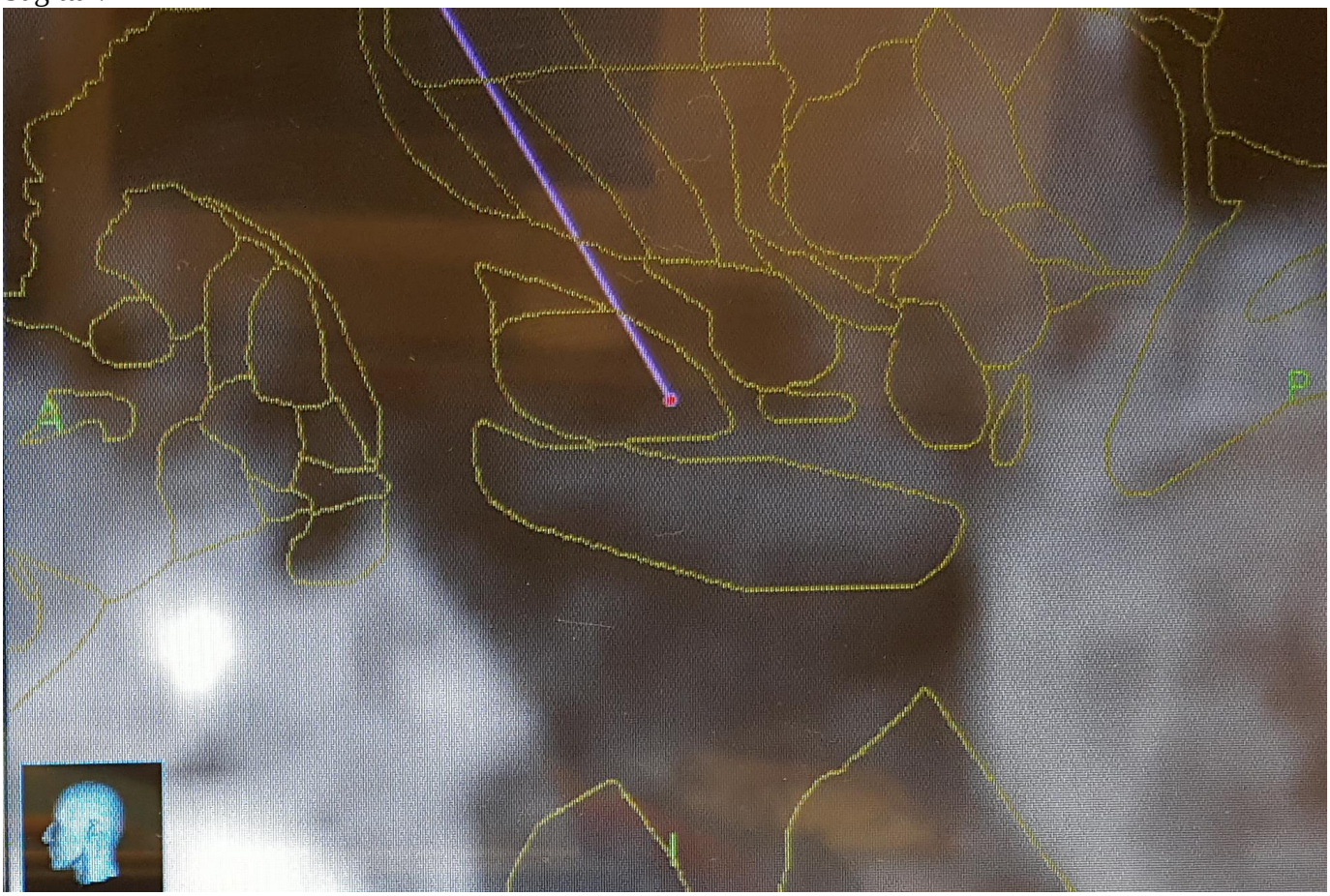

Sagittal (not target; just location of nucleus on SW atlas):



Axial:

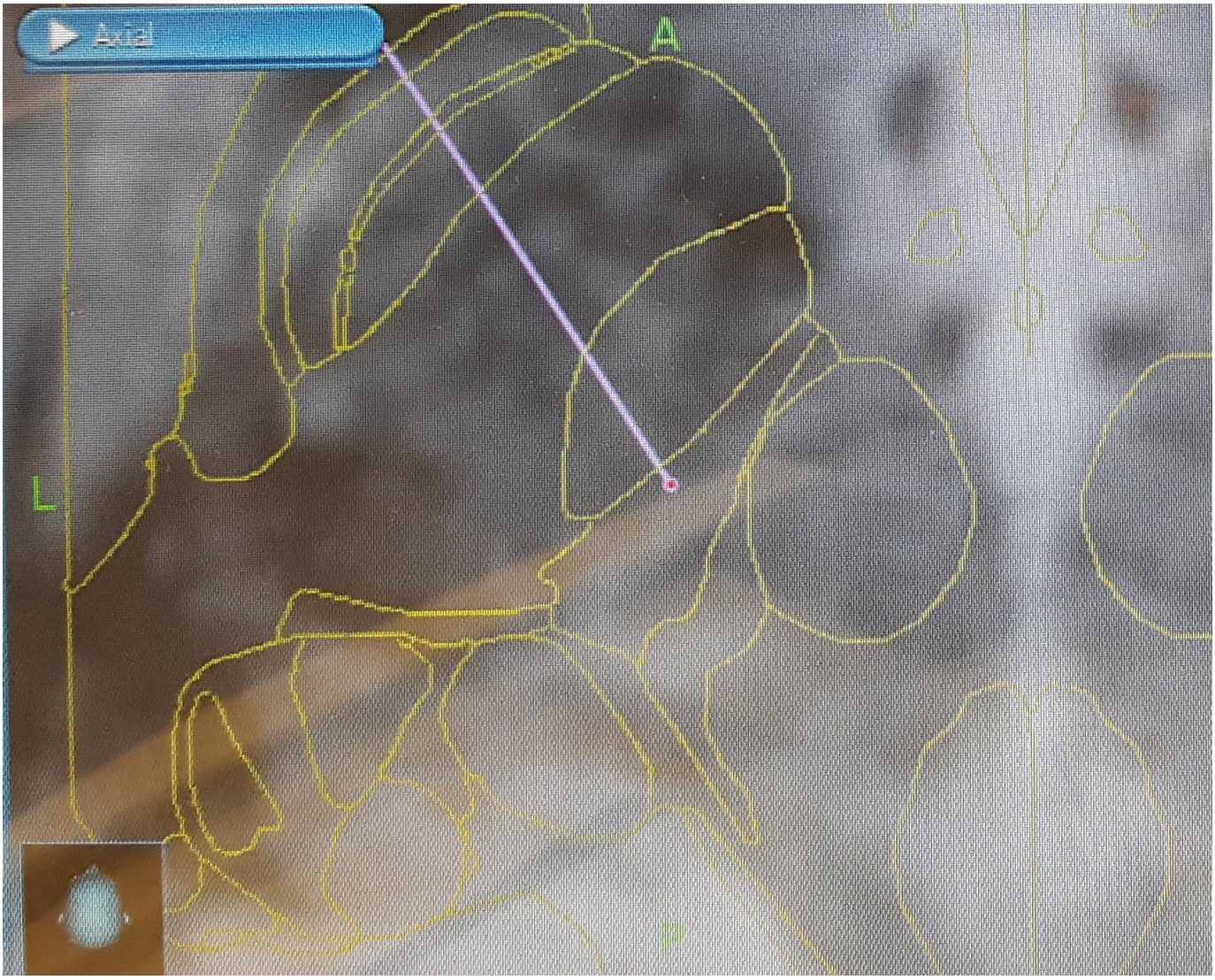

Axial (not target; just location of nucleus on SW atlas):

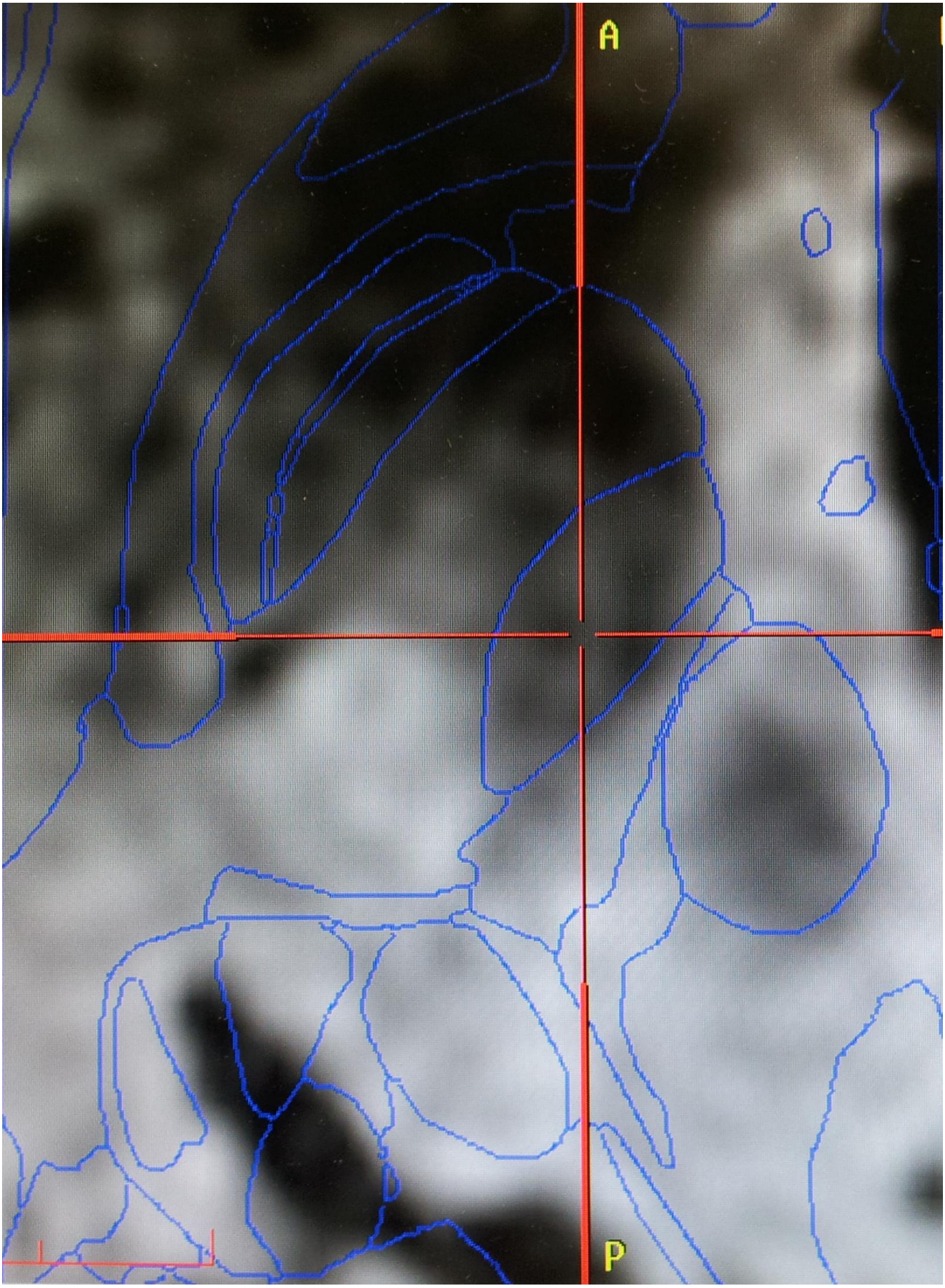
A
P

Coronal:

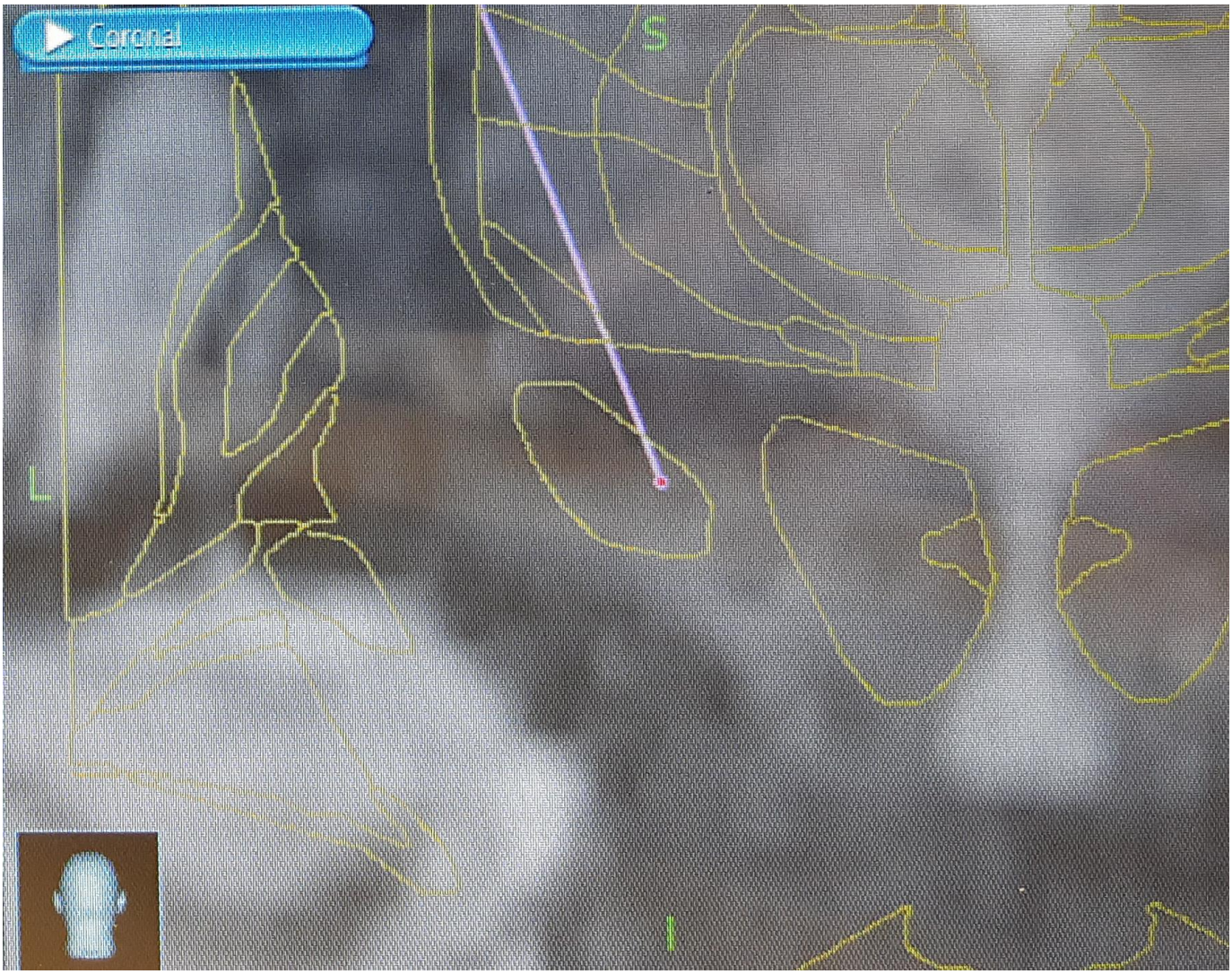

Coronal (not target; just location of nucleus on SW atlas):

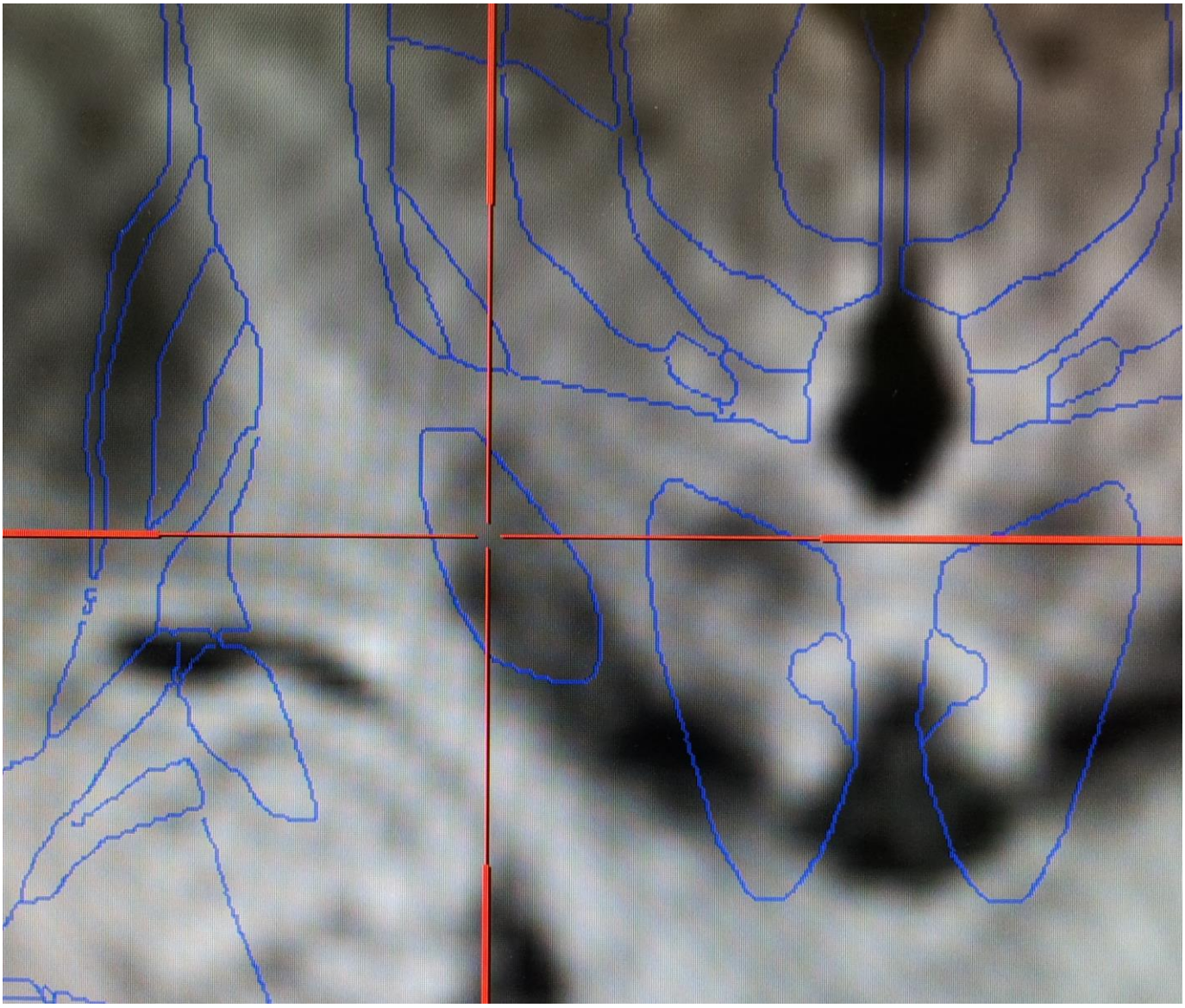

ELECTROPHYSIOLOGY

- Dr. Holloway starts with microelectrode cannula 10 mm above the target; advancing microelectrode travels down to target while recording.
- Dr. Abosch uses 3 simultaneous tracks for STN.
- start recording 15 mm above target.

HaGuide (Alfa Omega) – software for real time automatic MER+LFP analysis – defines visually STN entry and exit (very high correlation with DBS expert STN coordinates)

STN - large asymmetrical spikes at rather high frequency (30-40 Hz) and biphasic spikes at 10-13 Hz responsive to passive movement and tremor;

- STN cells have high spontaneous tonic activity with irregular bursts of activity; during typical electrode track through, STN is characterized by *sudden increase in background noise* (from relatively quiet of zona incerta; ZI sounds like STN but very sparse);

- location of electrode within sensorimotor sector of STN is verified by *response* (increased audible firing) *to passive movement of contralateral limbs* (in fact, there is segregated map of body found within STN); also responds to passive contralateral limb movements and proprioceptive input, such as muscle pressure
- exhibits burst patterns in PD - exhibit synchronous contralateral tremor activity
- recording length in STN varies from 5 to 6 mm between two silent zones corresponding to white matter, - first one between 0 and 2-3 mm below AC-PC plane (subthalamic area and anterior zona incerta) and other one corresponding to white matter between 9 and 11 mm just above SNr.
    - successful neurophysiological identification of the STN is considered accomplished if a pass of ≥ 4 mm of STN is encountered; if < 4 mm → O-arm is obtained of the microelectrode at the direct target → second microelectrode trajectory is chosen on the basis of the location of the microelectrode.

N.B. just recording cells from STN is not sufficient to delineate sensorimotor STN as one cannot electrophysiologically recognize a sensorimotor cell from a non-sensorimotor cell; thus, looking for kinesthetic cells is necessary!

- microelectrode is passed several millimeters past the ventral margin of the STN until a typical high-frequency solitary neuron in the substantia nigra pars reticularis is identified.
- place DBS with the distal edge of contact 0 at the ventral margin of the STN but excluding the tip from the substantia nigra pars reticularis as a priority.

SNr neurons fire in tonic pattern: regular, symmetrical, large-amplitude spikes that are generally unresponsive to external stimuli.

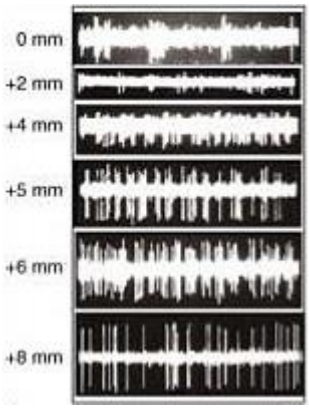

thalamic neurons

silent zona incerta

STN

STN

STN

substantia nigra pars reticulata (−8 mm).

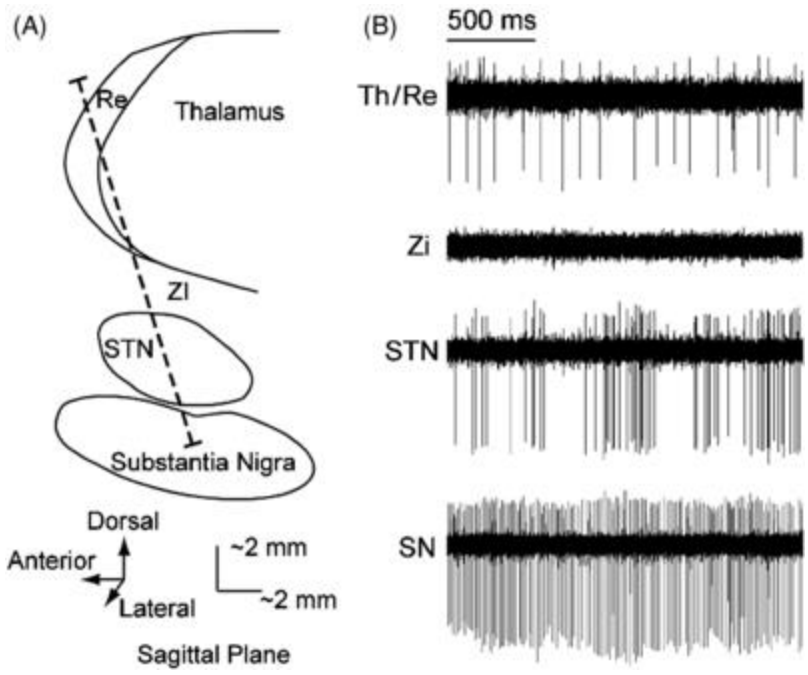

Computer aid – integrates MER and MRI data to guide adjustments PRN.

Sunjay S. Dodani, PhD Charles W. Lu, MS J. Wayne Aldridge, PhD Kelvin L. Chou, MD Parag G. Patil, MD, PhD. A Computerized Microelectrode Recording to Magnetic Resonance Imaging Mapping System for Subthalamic Nucleus Deep Brain Stimulation Surgery Operative Neurosurgery, opx169, https://doi.org/10.1093/ons/opx169 Published: 05 August 2017

STIMULATION

- Dr. Holloway: when MER reaches target, retract microelectrode into its cannula and use its collar for monopolar stimulation (thus, stimulation starts 10 mm above the target).
- once new final target depth is established, microelectrode cannula is removed (if were using two parallel microelectrode tracks, the other cannula is left in place to stabilize brain and prevent DBS lead sliding into wrong track) and replaced with DBS cannula ("at target" length).
- stimulation of STN normally induces dyskinesias (sign of electrode location at target)

MALPOSITIONED ELECTRODE

1) lateral to STN, muscular contraction (face and upper limb primarily) is induced by excitation of **corticospinal fibers**; stimulation of **corticonuclear fibers** induces conjugated binocular deviation toward contralateral side.
2) medial to STN and deeper, stimulation of **oculomotor nerve** induces monocular deviation toward midline or either upward or downward.
   N.B. eye deviation with stimulation:
   a) one eye only – too medial (CN3)
   b) both eyes (conjugate) – too lateral (corticonuclear fibers from frontal eye field)
3) too anterior – risk of permanent hypophonia.
4) more posteriorly to STN, stimulation of **lemniscus medialis** fibers induces paresthesias.
5) stimulation of **SNr** induces profound depression.

VENTRALIS INTERMEDIUS (VIM) nucleus of thalamus (s. ventral lateral nucleus)

Comparisons of different nuclei – see >>

- afferents:
  1. Contralateral **cerebellum**: VIM is cerebellar relay nucleus to motor cortex (i.e. VIM is terminus of cerebellar afferents – dentatorubrothalamic tract via superior cerebellar peduncle).
  2. Ipsilateral **globus pallidus**

- efferentes: all parts of VIM project to ipsilateral **motor cortex**.

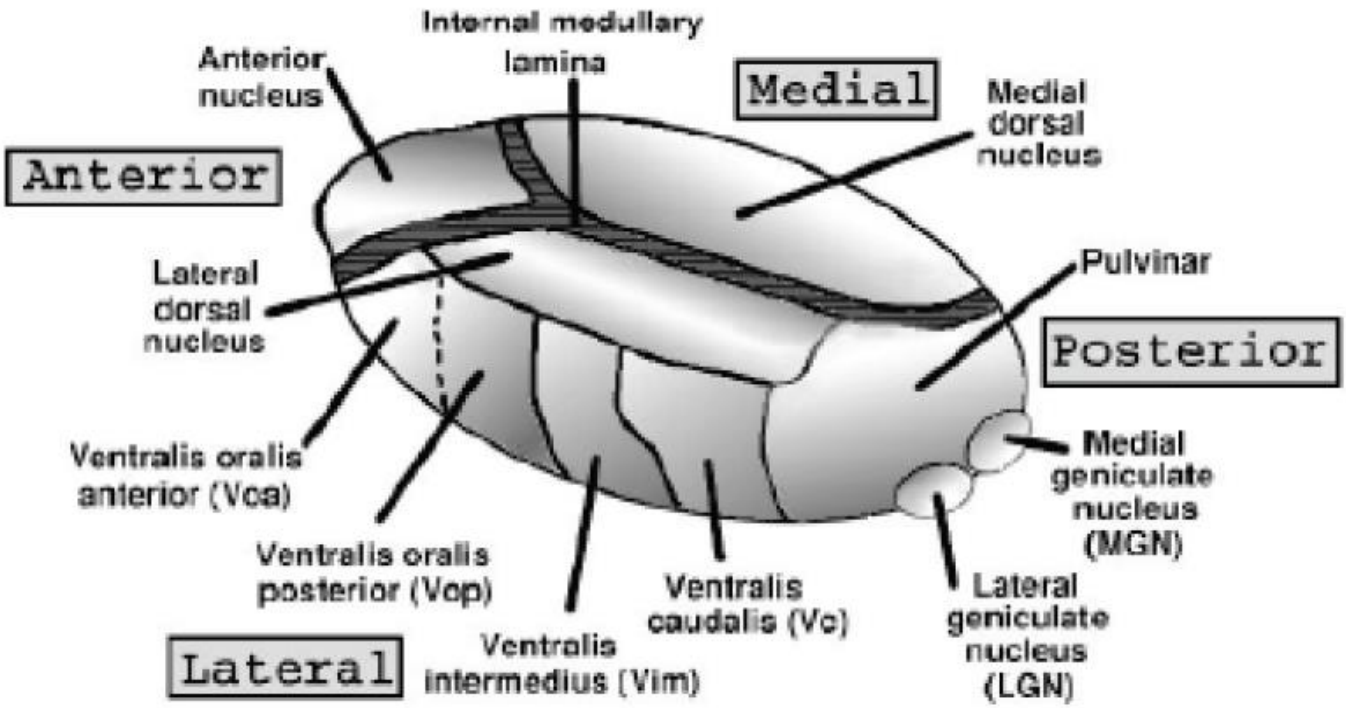

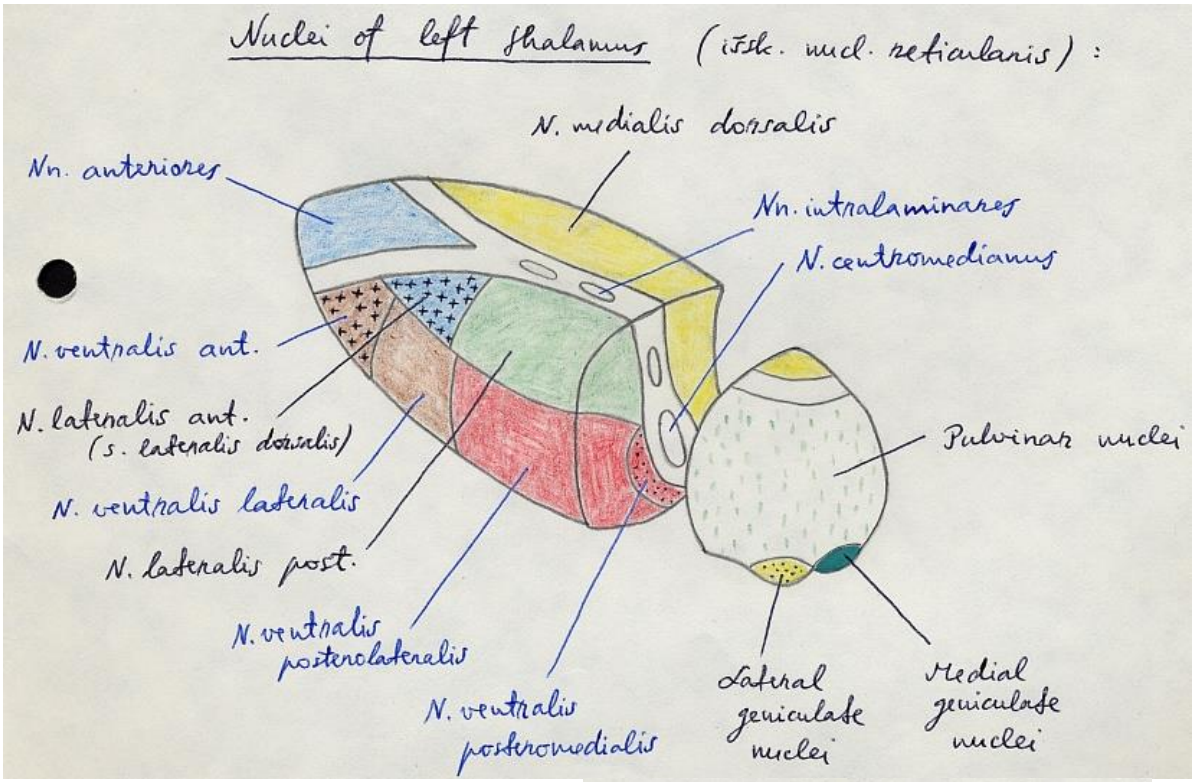

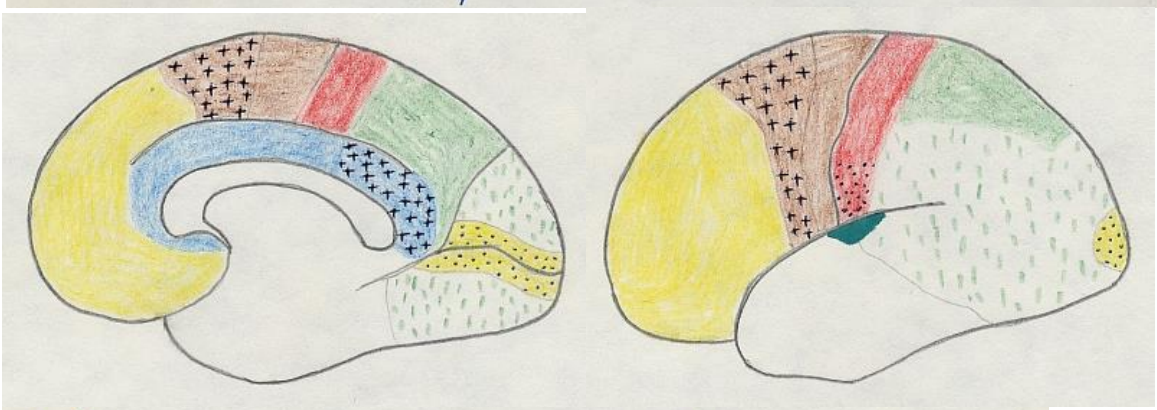

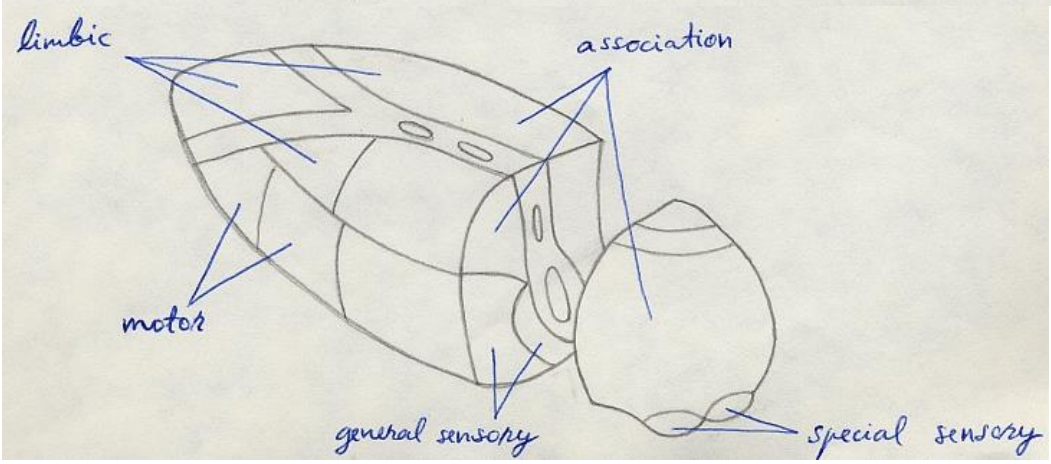

- <u>blood supply to thalamus</u>
  Anteromedial part – posteromedial central (s. thalamo-perforating) arteries ← PCA, PComA
  Posterolateral part – posterolateral central (s. thalamogeniculate) arteries ← PCA
  Ventrolateral part – anterior choroidal artery ← ICA
  Dorsomedial part – posterior medial choroidal artery ← PCA

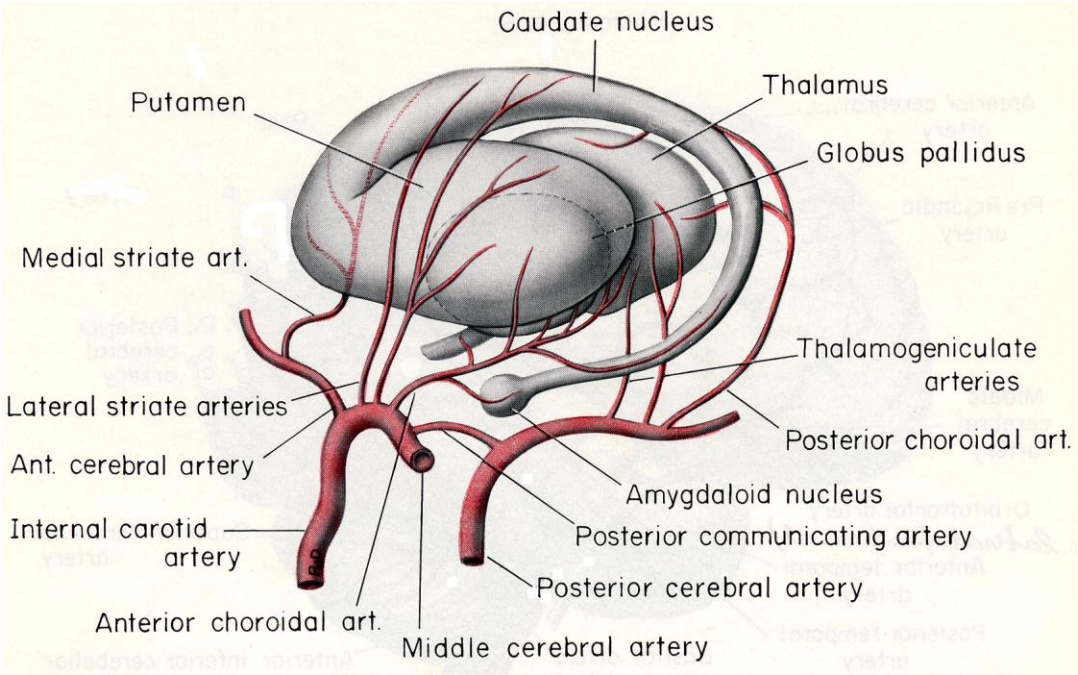

INDICATIONS

1) **tremor** (parkinsonian, intention, essential) refractory to medication (vs. GPi – tremor needs to be responsive to medications)
   VIM is target of choice for treatment of all types of tremor!
   Distal upper extremity tremor responds best!
2) dystonia, chorea, hemiballism, athetosis, some types of myoclonus.

IMAGING

Standard 3D T1-weighted image with TE 4.61 msec, TR shortest, flip angle 30, voxel size 1.02, matrix 256 × 256

DTI may allow ***direct targeting*** of VIM – seed from dentate nucleus to precentral gyrus

SIDE EFFECTS

- bilateral surgery is too often associated with neurocognitive deficits and dysarthria (patients are taught to increase voltage when they need fine motorics in hands and decrease when they need to speak); bilateral VIM may also cause mutism (but it is rare)
  Don't do bilateral thalamotomy! (for DBS - space implantations apart by several months)*
  **it is OK to do bilateral simultaneous VIM DBS implants in patients < 55 yo, but programming has some specificities* >>
- generally better tolerated in demented patient with quicker recovery and has same success with tremor control as STN.

COORDINATES

N.B. do not modify target point when doing planning – default coordinates always work (vs. GPi)!

Relative to midcommissural point:

- 1-7 mm posterior (anterior to PC by 20% of AC-PC length)
- 0-3 mm superior
- 12-17 mm lateral (11.5 mm lateral + ½ width of 3rd ventricle)

Trajectory:

Sagittal - 60-80 degrees
Coronal – parallel to sagittal plane

Trajectory that takes too steep an anteroposterior angle may limit the ability to choose DBS contacts that limit side-effects, whereas an approach that is too shallow may limit the number of contacts that show beneficial effect.

Anatomically:

- target - middle of nucleus, 1-2 mm anterior to VC border (hand region of VC), contact 0 at base of VIM
  Dr. Kopell places more anteriorly to avoid paresthesias (not anymore with directional lead).
- VIM is somatotopically organized along medial-lateral axis - face/tongue representation is medial, foot is lateral.

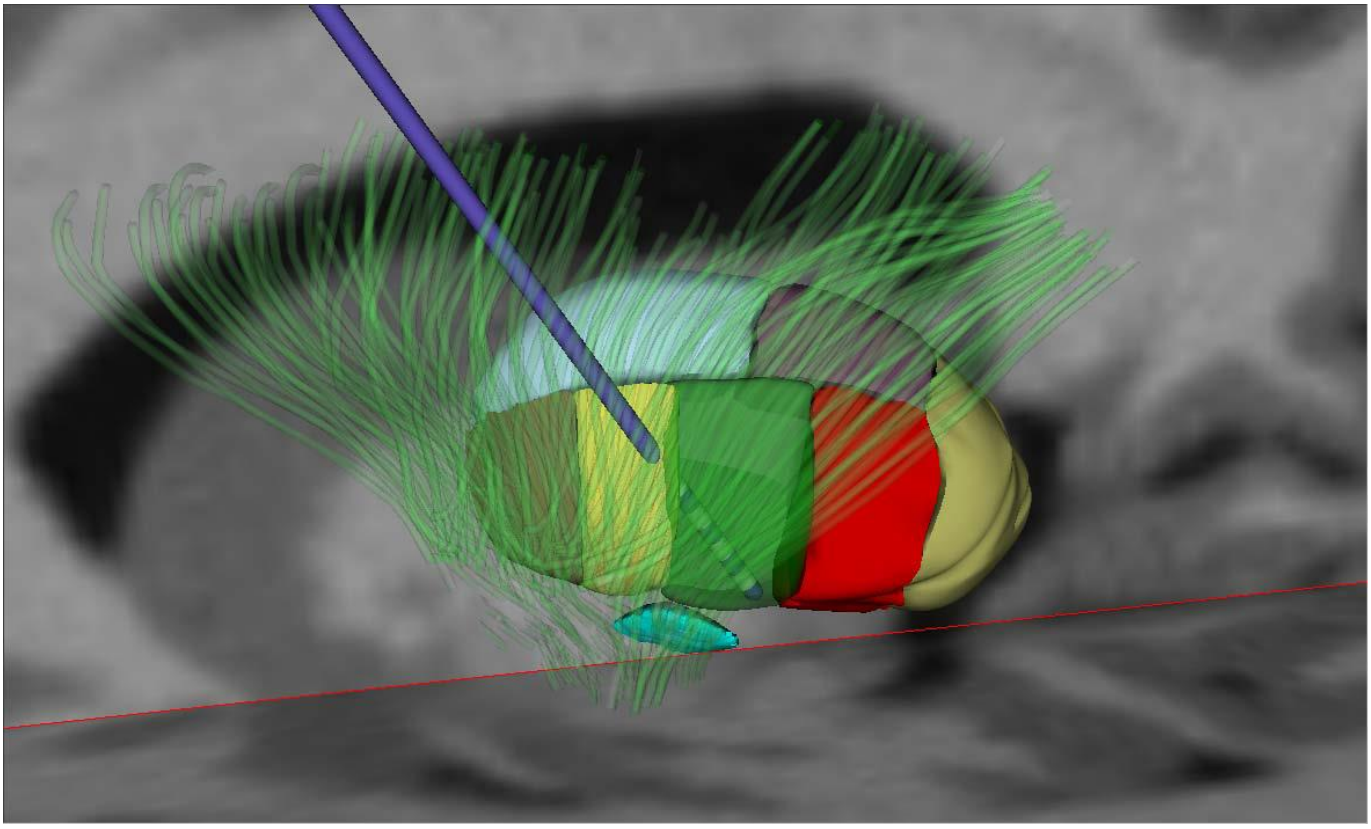

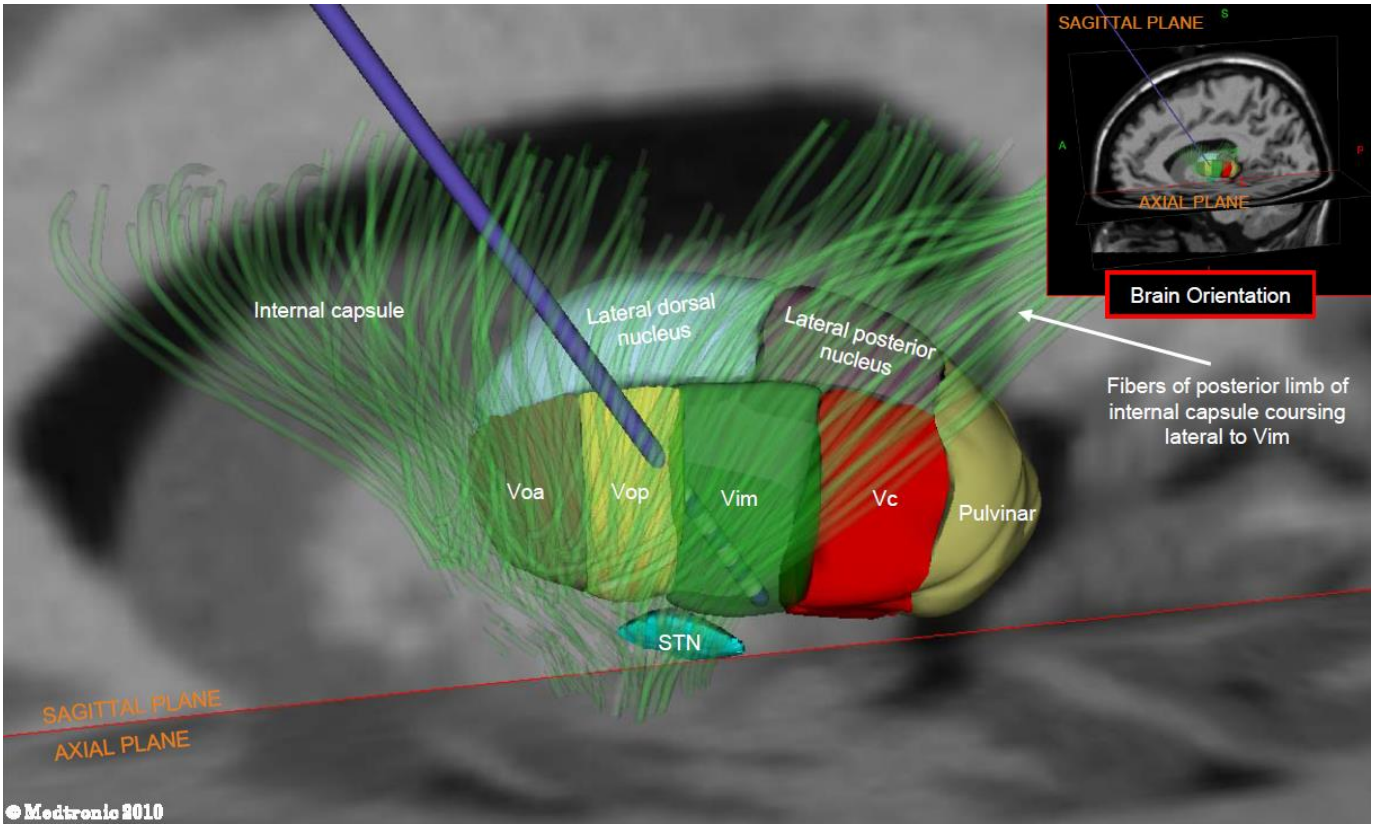
SAGITTAL PLANE
AXIAL PLANE
Brain Orientation
Internal capsule
Lateral dorsal nucleus
Lateral posterior nucleus
Fibers of posterior limb of internal capsule coursing lateral to Vim
Voa
Vop
Vim
Vc
Pulvinar
STN
SAGITTAL PLANE
AXIAL PLANE
© Medtronic 2010

Coronal:

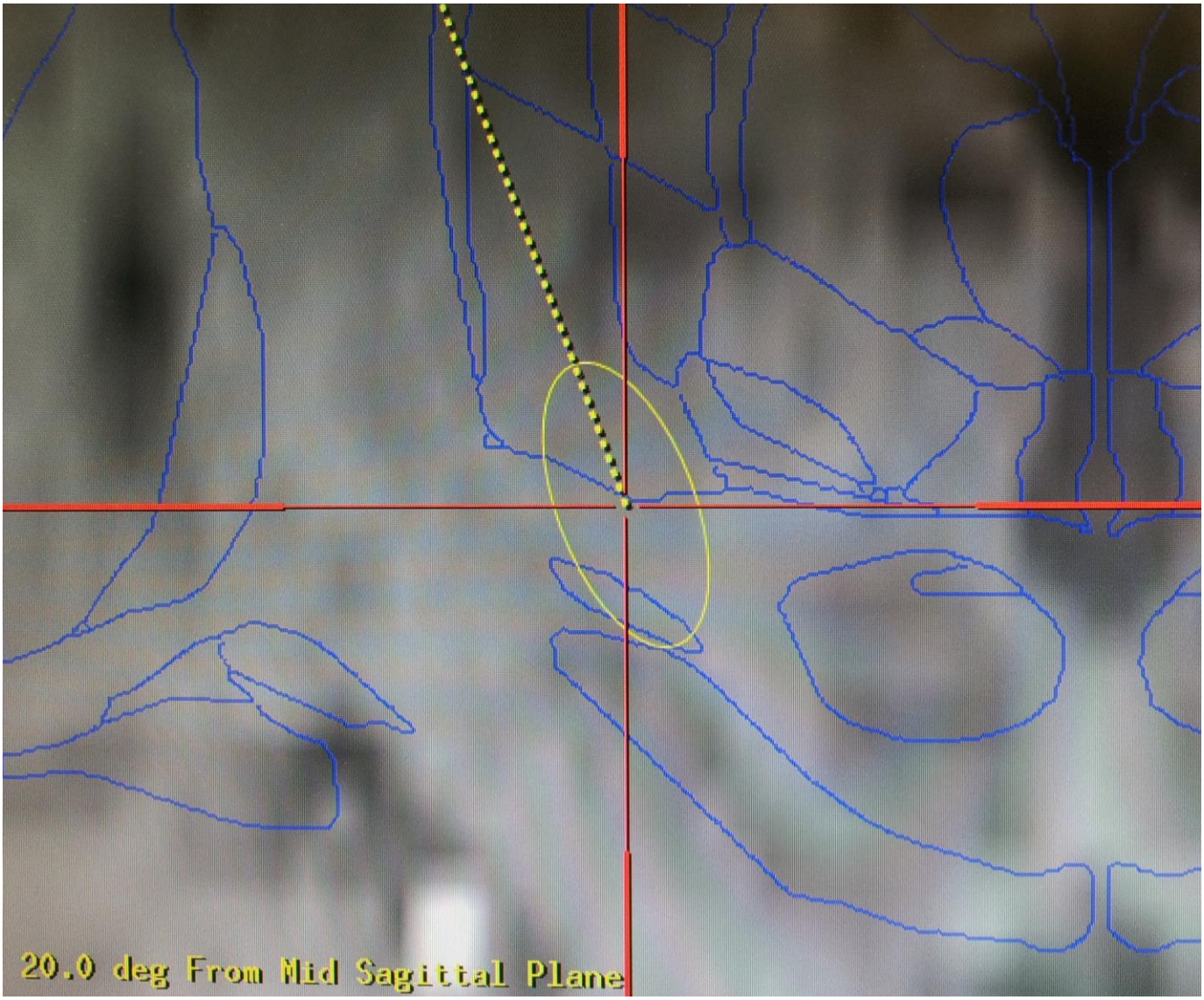

Sagittal:



Axial:

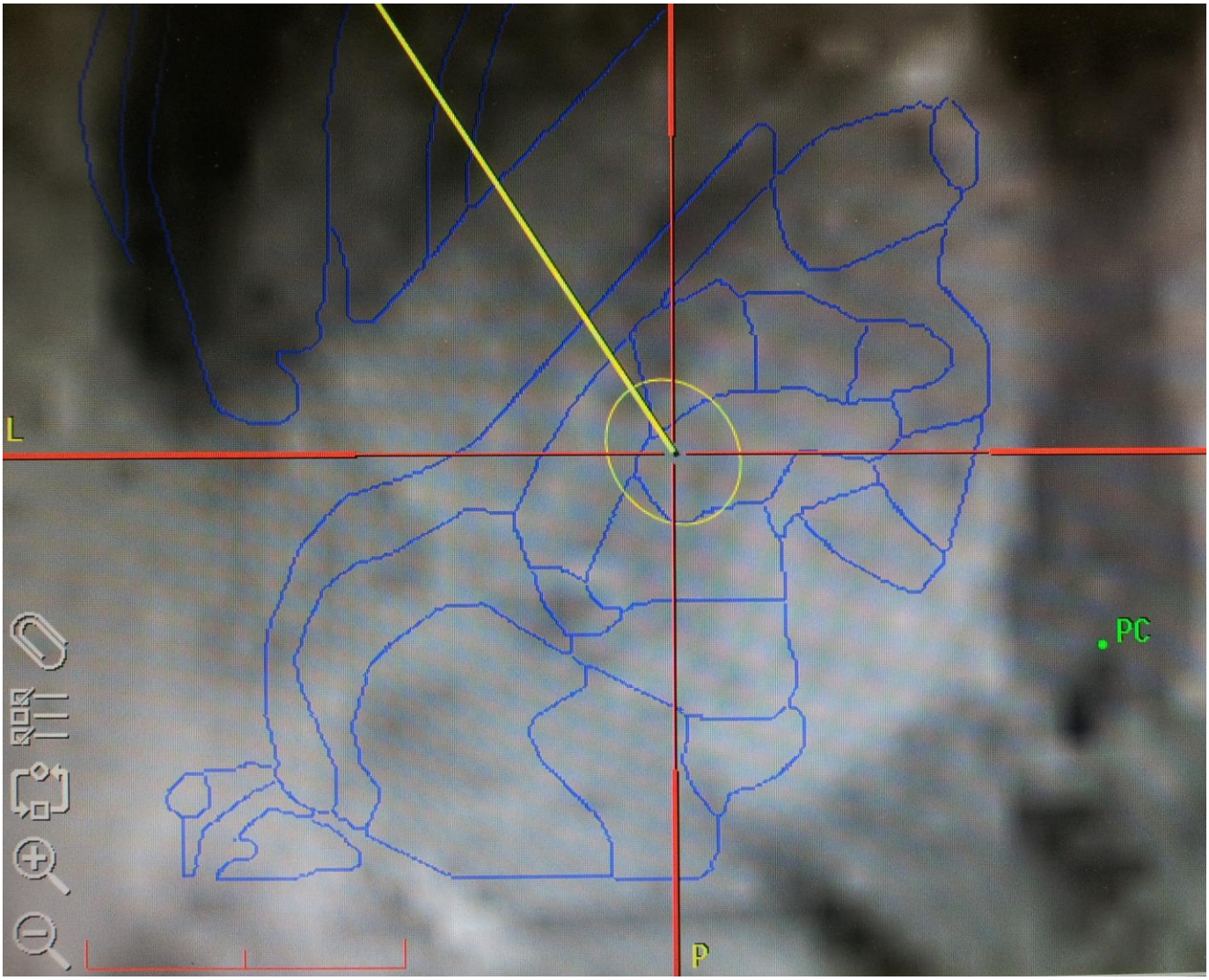

ELECTROPHYSIOLOGY

- typically not done; so DBS cannula is inserted to 6 mm above intended target and DBS lead is advanced towards target while macrostimulating.

- VIM has highest concentration of tremor cells (rhythmic bursting activity close to frequency of tremor).
- kinesthetic cells present.
- electrode is inserted at slightly shallower angle than that of plane of typical VC / VIM boundary – allows to locate anterior border of VC as electrode passes through VIM side of VC / VIM border superiorly and VC side of that border inferiorly.
- transition from VIM to VC - change from motor-responsive to sensory-responsive cells.

A trajectory with target situated at the anteroventral aspect of the Vc and using an anterior angle of 60 degrees parallel to the midsagittal plane will typically encounter the following structures.

Structure	MER Baseline Activity Observations
Lateral Dorsal nucleus	- low density of spontaneously firing neurons, bursting cells present
Dorsal Vop	- low density of spontaneously firing neurons, bursting cells, tremor cells possible
Vim	- increased density of neuronal firing, more rapid and regular
	- neuronal firing rates in Vim > Vc, Vop, Voa
	- tremor cells may be heard (3-6 Hz) fire in synchrony with physical tremor
Vc	- decrease in firing rates and few, if any, tremor cells are detected
Base of thalamus	- neuronal activity will cease

Spontaneous firing rates in the Vim nucleus are disease dependent. In ET patients, higher frequency spontaneous activity may be observed in the 20-30 Hz range

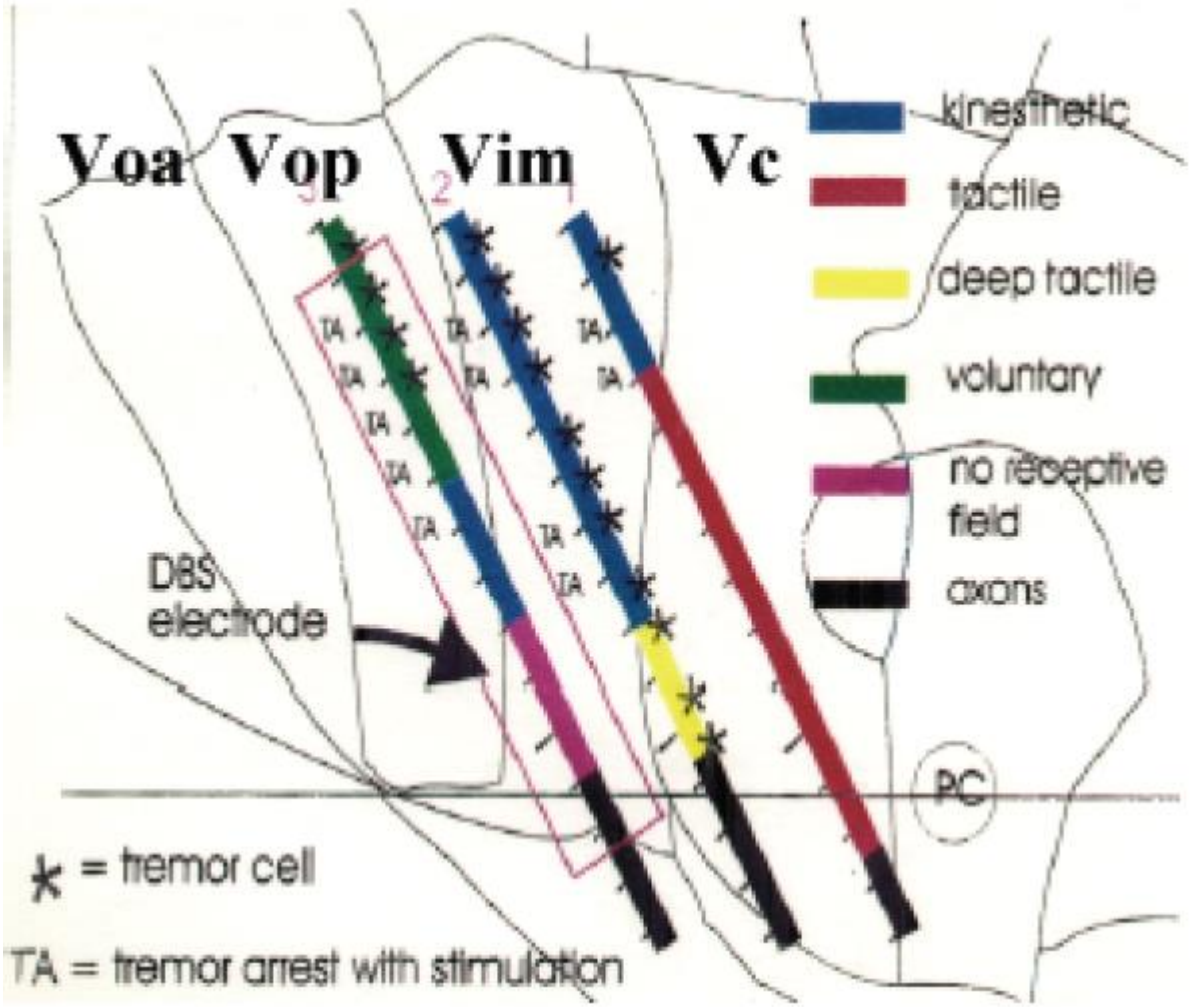

The following cell type classifications are frequently observed during thalamic exploration

A. Kinesthetic Cells
- cells that fire in response to passive movement around a joint of the contralateral body
- kinesthetic neurons populate the Vim
- excitation of firing rates is heard coincident with movement (although inhibition is also possible)

B. Tremor Cells
- cells which fire in synchrony with patient tremor
- populate Vim and less so Vop and Vc

C. Tactile Cells
- tactile cells fire in response to light touch on the patient
- indicative of the Vc, the posterior border of the Vim

D. Voluntary Cells
- unlike classic Vim neurons, these cells respond when movements are made voluntarily by the patient
- found in highest concentration in the Vop

STIMULATION

- tremor arrest
- expect transient (!) paresthesias – sign of correct position!
- if overshoot with voltage for tremor control, then start seeing dysmetria.

MALPOSITIONED ELECTRODE

Location relative to VIM	Nucleus	MER	Observed Effect If Stimulated
Anterior	Vop	Bottom of thalamus higher than expected. Minimal kinesthetic activity. Bursting cells, low frequency and sporadic firing	Possible reduction in tremor at voltages higher than typically used in VIM
Anterior to Vop	Voa		No effect

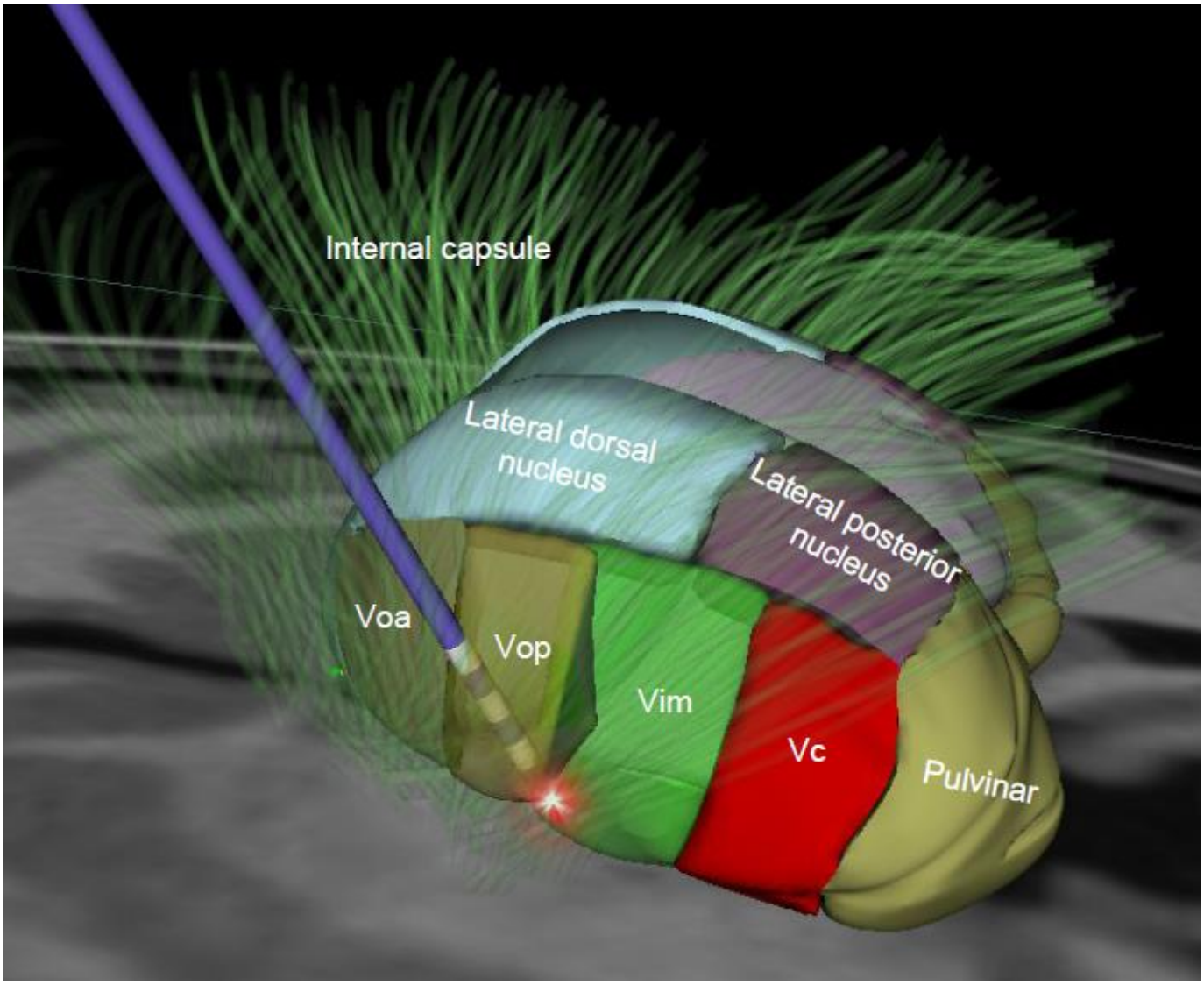

Location relative to VIM	Nucleus	MER	Observed Effect If Stimulated
Posterior	VC	Bottom of thalamus lower than anticipated. Tactile cells. Low background noise	Paresthesias (long lasting) that increase in severity with increasing voltage

N.B. VC is somatotopically organized along medial-lateral axis - face/tongue representation is medial, foot is lateral.
Transient paresthesias do not necessarily indicate a lead that is too posterior.

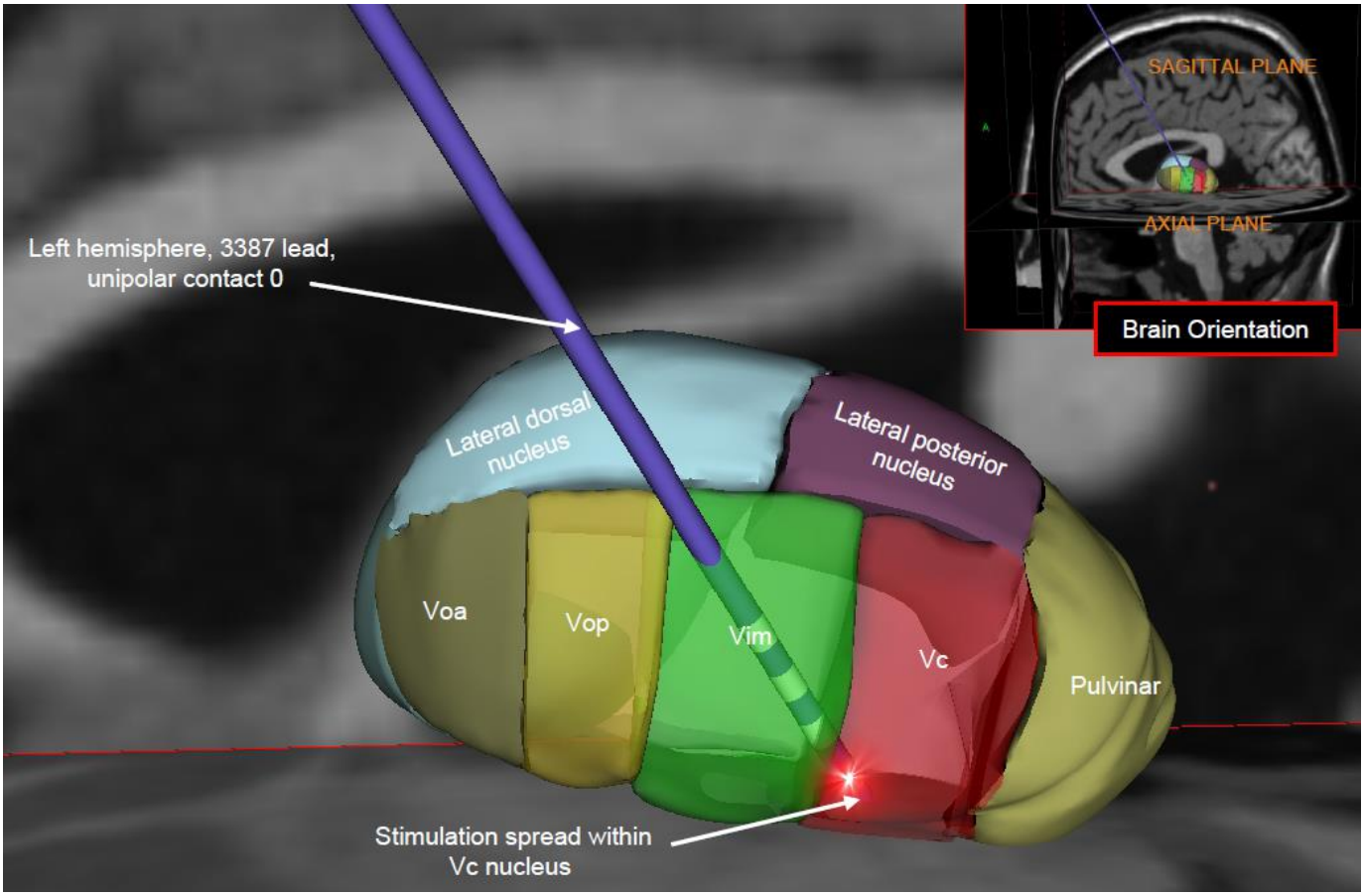

Location relative to VIM	Structure	MER	Observed Effect If Stimulated
Medial	Medial aspect of VIM	Jaw kinesthetic cells. Face tactile cells (VC)	Dysarthria, dysphagia in addition to tremor control
	Centromedian/Parafascicular Complex		No effect

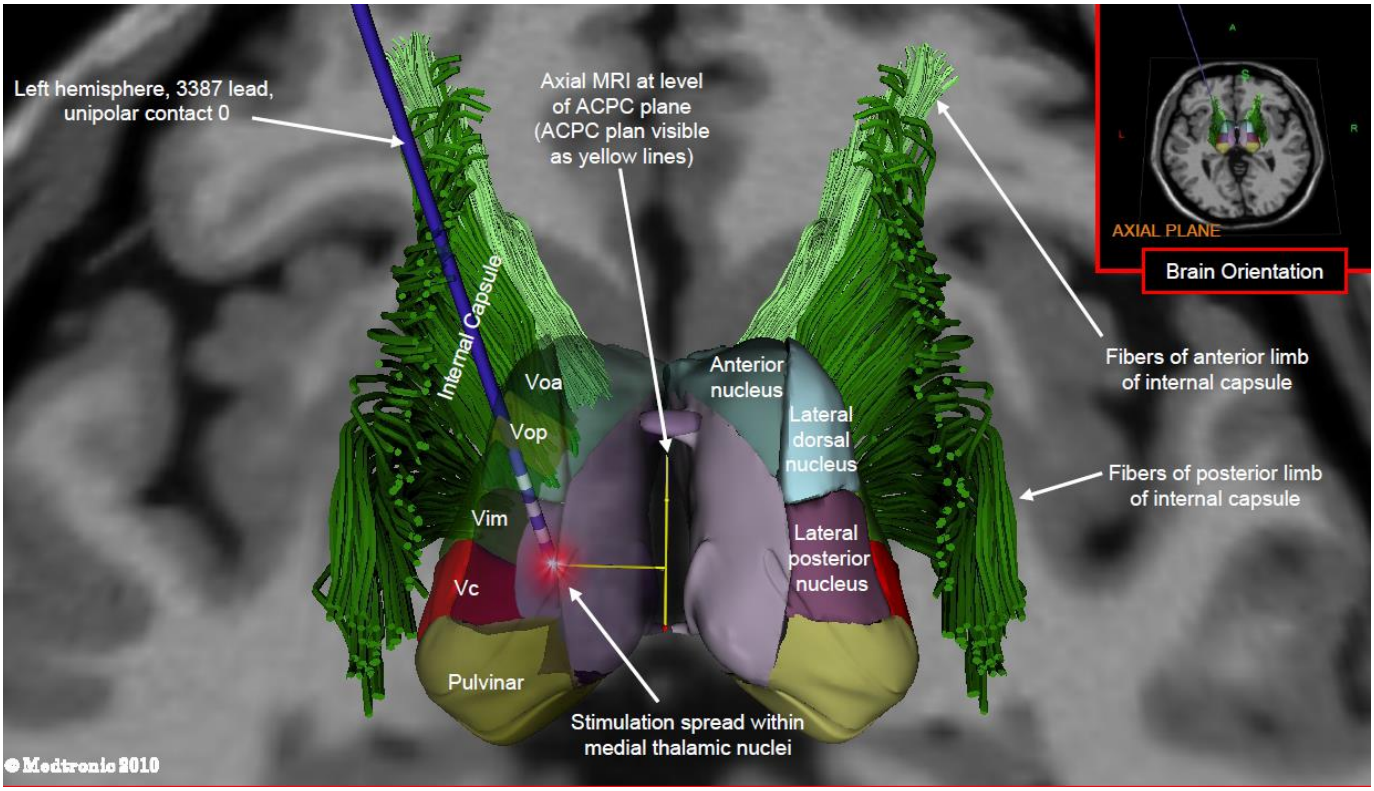

Location relative to VIM	Structure	MER	Observed Effect If Stimulated
Lateral	Posterior limb of internal capsule	No or sparse cellular activity. Kinesthetic cells only to leg.	Dysarthria, facial pulling, muscle contractions

N.B. Internal capsule is somatotopically organized along anterior-posterior axis - face representation is anterior, foot is posterior.

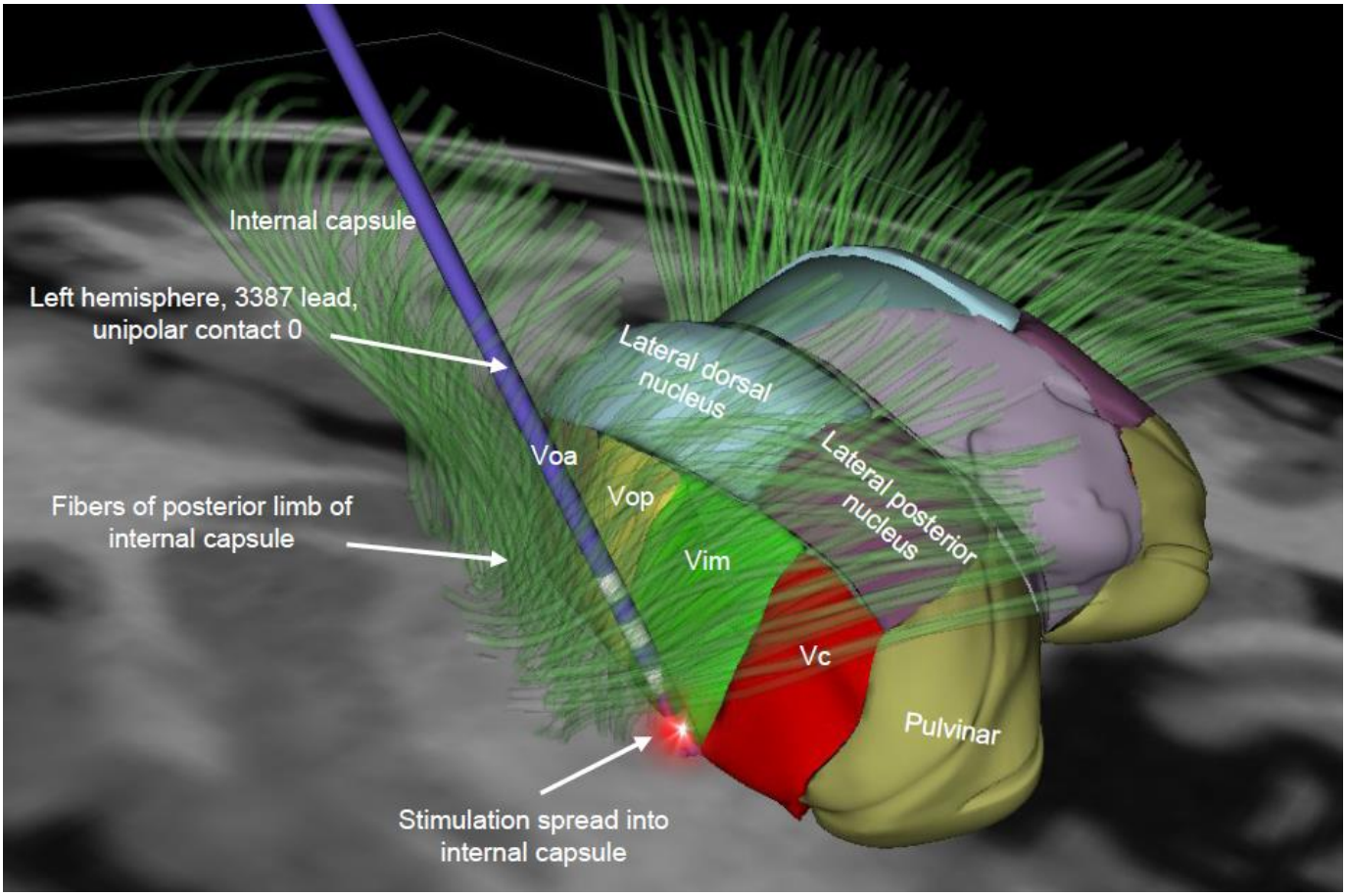

Location relative to VIM	Structure	Observed Effect If Stimulated
Ventral and medial	Brachium conjunctivum (cerebellar fibers)	Ataxia
Ventral	Zona incerta	No effect on tremor
Ventral and posterior	Medial lemniscus	Paresthesias
Ventral and lateral	Internal capsule	Dysarthria, muscle contractions

MER – no cellular activity

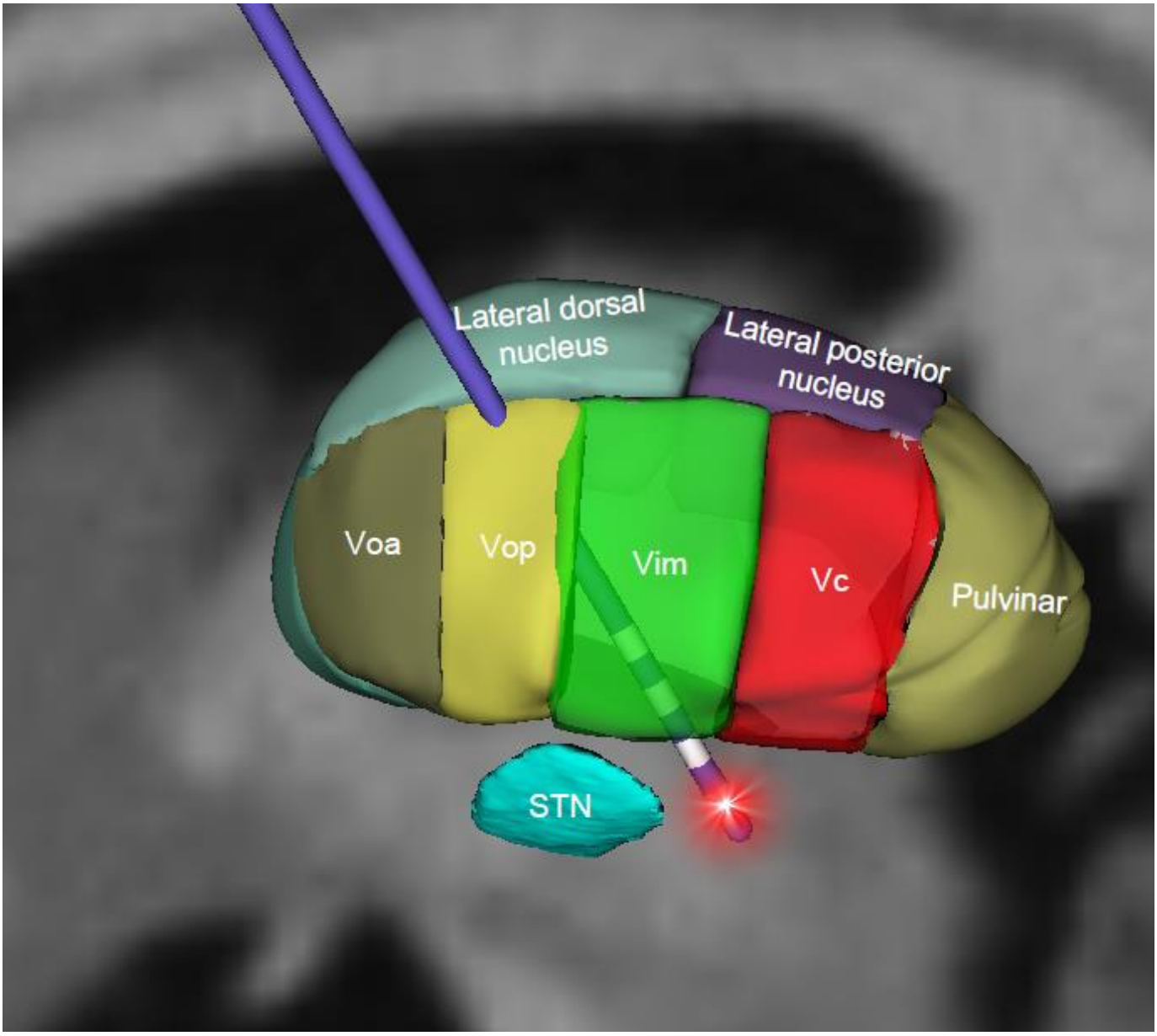

GPi

Comparisons of different nuclei – see >>

INDICATIONS, SIDE EFFCETS

- tremor* and other parkinsonian symptoms
  N.B. do not put DBS into GPi if tremor is not responsive to medications (vs. VIM and STN).

IMAGING

FLAIR

MPRAGE sequence with TE 80 msec, TR 8000 msec, slice thickness 2 mm, voxel size 0.6, matrix 256 × 256

TRAJECTORY

- 0° in coronal plane; i.e. GPi is very sensitive to trajectory (STN is more forgiving).

COORDINATES

Relative to midcommissural point (classic Leksell's pallidotomy target):

- 2-3 (2) mm anterior
- 2-6 (-4) mm inferior
- 18-23 (21) mm lateral

Anatomically: **motor (posterolateral) GPi**

- **somatotopy** – arm is lateral, ventral, and posterior in GPi.
- inferior border of motor territory of GPi, 2.5-3 mm anterior to posterior border (internal capsule) and 2-3 mm from lateral border (GPe) with the deepest electrode contact placed immediately superior to optic tract.
- ***rule of thirds***: target is selected on axial plane of commissures by measuring pallidocapsular border, dividing it into thirds, and drawing 3-4 mm line perpendicular to the pallidocapsular border at the junction of its posterior one-third and anterior two-thirds:

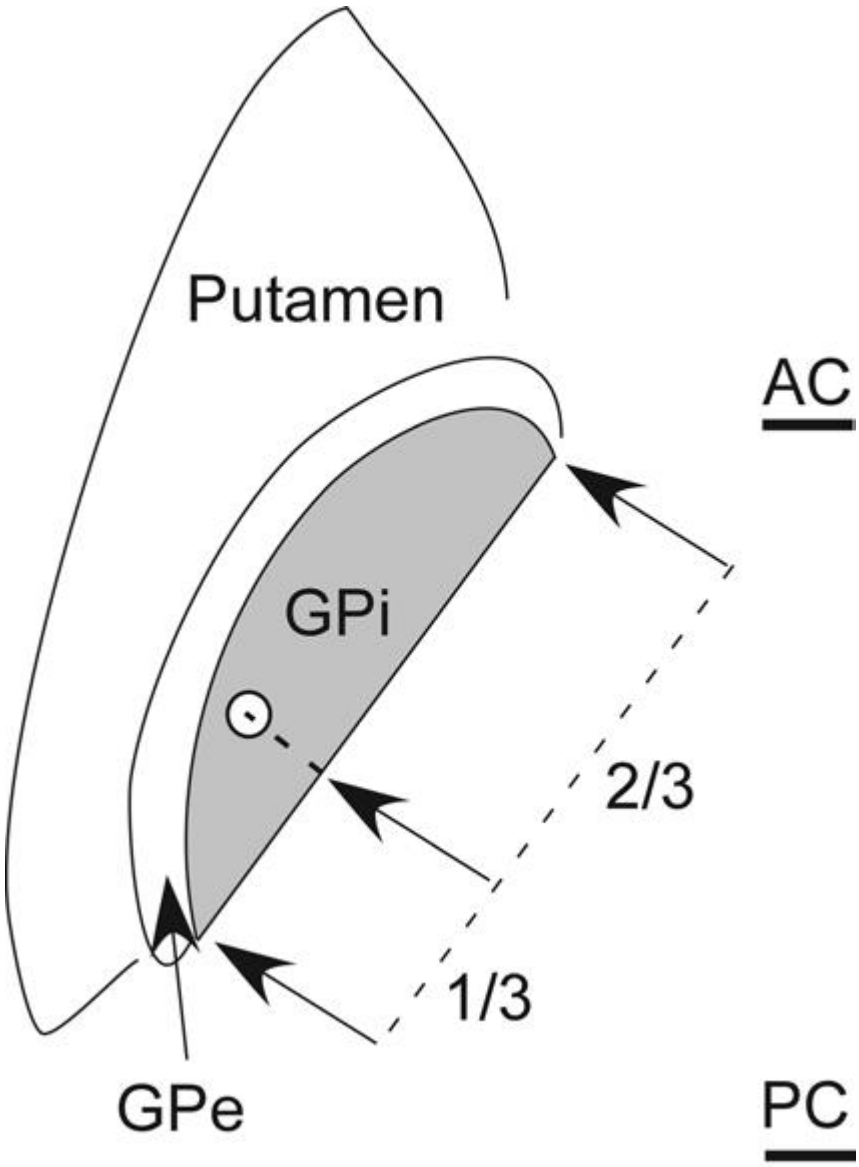
Putamen
AC
GPi
2/3
1/3
GPe
PC


Coronal
S
L
5.4 deg From Mid Sagittal Plane

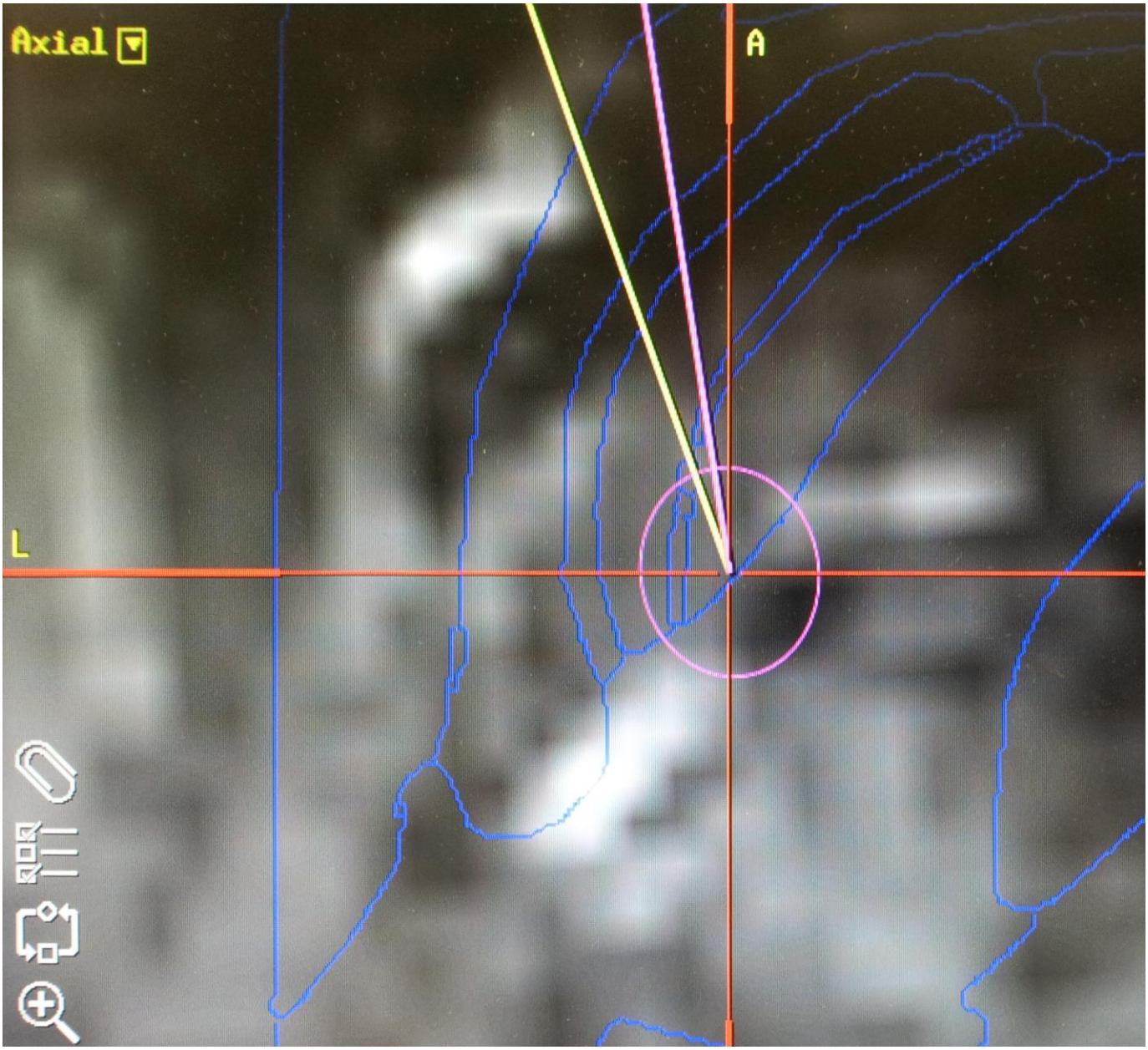
Axial
L
A

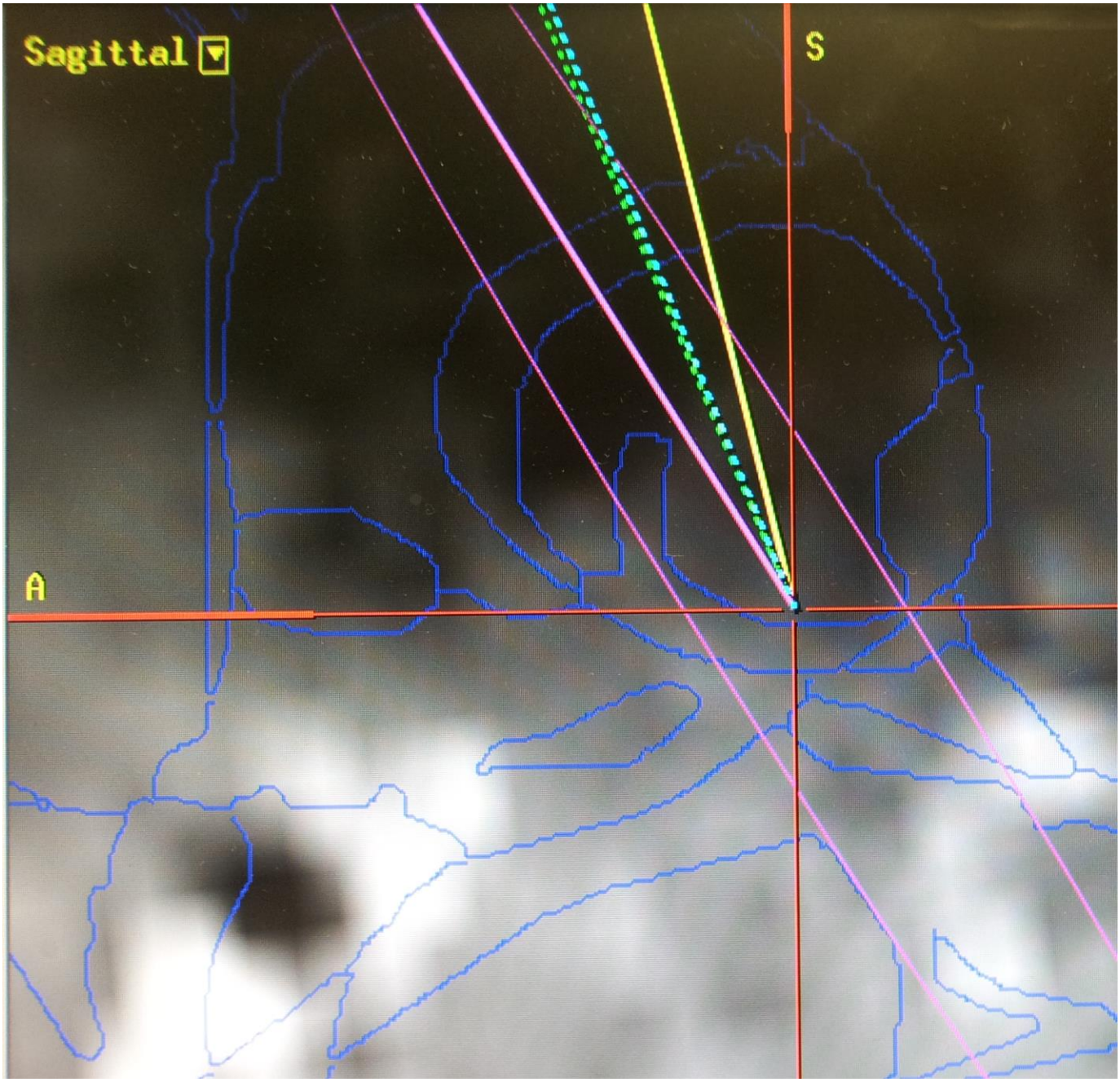

Source of picture: Viktoras Palys, MD >>

ELECTROPHYSIOLOGY

Striatal cells - mainly slow firing (< 10 Hz) and have a relatively long duration action potential. These units are distinctly activated with movement of the electrode and quickly decrease in firing rate once the electrode excursion stops.

GPe activity is characterized by mostly higher frequency (about 60 Hz in PD) short-duration units.

Pausers (most of GPe neurons): fire in a fairly regular fashion, interrupted irregularly by brief pauses.

Bursters (10–15% of GPe neurons) fire in a burst fashion, with infrequent spikes between bursts.

Border (lamina) cells (thought to be cholinergic embryological extensions of nucleus basalis of Meynert):

- identified in the transition between GPe and GPi.
- fire at low frequency in the 20 Hz range
- regular rhythm on an otherwise quiet background ("rain drops on tin roof")

GPi: constant firing like "railroad train".

- entrance to the GPi is marked by a distinct increase in background activity.
- GPi is very dense with irregular and high frequency activity (> 70 Hz in PD) without the distinct pauses of GPe neurons.
- motor (posterolateral) territory of the GPi (*shown in purple*) - cell activity that is altered by passive limb movements.

Optic tract: silent; can stimulate with visual stimulus (brief burst of fiber activity in response to flashes of light); alternatively microstimulation causes phosphenes.

- the neuronal activity decreases precipitously as the microelectrode exits GPi, but border cells may be encountered immediately below GPi, particularly with more anterior penetrations, which pass into the Nucleus Basalis of Meynert.
- in most penetrations passing through the longer central extent of GPi, the optic tract can be identified by turning off the operating room lights and listening for an audible modulation of multiunit axonal activity in response to brief on/off flashes directed into the patient's contralateral visual hemifield (alternatively, microstimulation may cause phosphenes).

Internal capsule: silent.

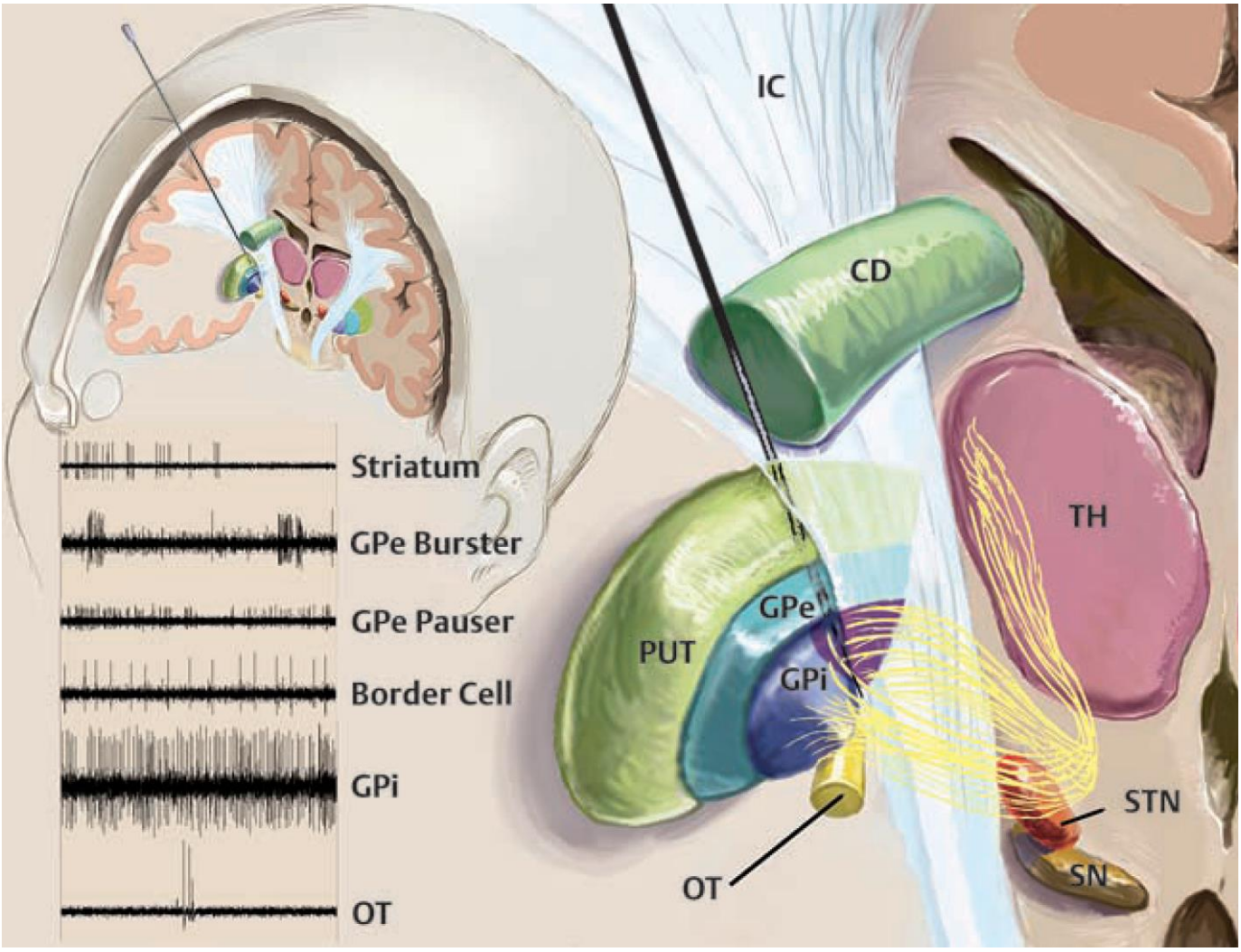

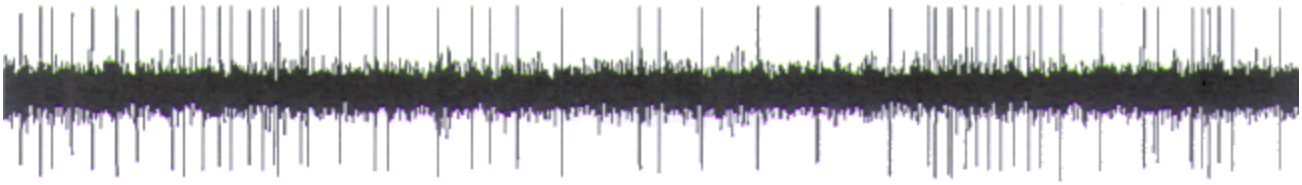

Gpi Border Cell

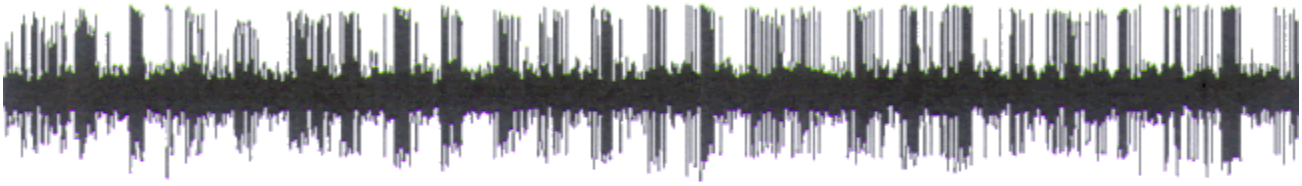

GPi Tremor Cell

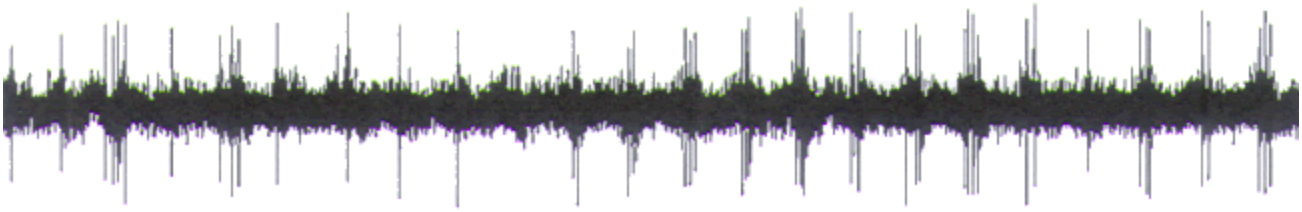

STN Tremor Cell

- Dr. Holloway starts with microelectrode cannula 10 mm above the target (historically – 20 mm); advancing microelectrode travels down to target while recording; when MER reaches target, retract microelectrode into its cannula and use its collar for monopolar stimulation (thus, stimulation starts 10 or 3 mm above the target – depending on electrode model used); once new final target depth is established, O-arm image (high-def, low MAS mode) is obtained, microelectrode cannula is removed (if were using two parallel microelectrode tracks, the other cannula is left in place to stabilize brain ["like a fork"] and prevent DBS lead sliding into wrong track) and replaced* with DBS cannula ("at target" length).

  *not if using Alpha-Omega - ME reducing cannulas are inside DBS cannula from the beginning
- MER activity is recorded on appropriately scaled grid sheets that can be superimposed on transparent parasagittal maps constructed from the Schaltenbrand-Wahren Atlas:

MICROSTIMULATION

- after completing an initial MER tract, the tip of the microelectrode is withdrawn into the microcannula.
- collar of microcannula is used for microstimulation - configuration is set to ***distal array***: 0 +, 1 –, 2 and 3 off.
- testing consists of a subselection of UPDRS III parameters* at 2 mm intervals along each track.

  *rigidity, finger tap, open and close of the hand, heeltap, and observation of tremor and voice; side effects are also noted.
- the most common <u>side effect</u> of stimulation in the GPi region is increased tone in the arm or facial contraction caused by stimulation of the internal capsule.
- stimulation inferior to the GPi can elicit a perception of flashing light (phosphenes).

- at target depth, the voltage is progressively increased to the screener limit of 6-10 V (plus, also wide array), to discover and record any side effects of stimulation.
- second track is chosen if the first track was not optimal; the next track should be at least 2 mm away from the first or the electrode will likely traverse into the path created by the first tract.
- once a track is identified with an adequate length of GPi, containing motor responsive cells, efficacy is demonstrated with microstimulation, and no side effects at 6-10 V, the microelectrode is replaced with the DBS lead.

Microelectrode recording-macrostimulation map provides a summary of the anatomic and physiologic information from a single track. The entrance and exit of the electrode from GPe and GPi and location of the optic tract are plotted by depth along the x-axis. The depths of neurons responding to passive manipulation of the arms and legs are marked as well. The patient's total UPDRS subscore (plotted on the y-axis) is recorded at baseline and then with macrostimulation starting at +4 mm from the targeted bottom of GPi, generally in GPe, and continuing downward at 2 mm intervals through GPi to a level just above the optic tract. The illustrated case showed a progressive response to macrostimulation as the electrode was advanced through GPi, with a 70% improvement from baseline at the bottom of GPi:

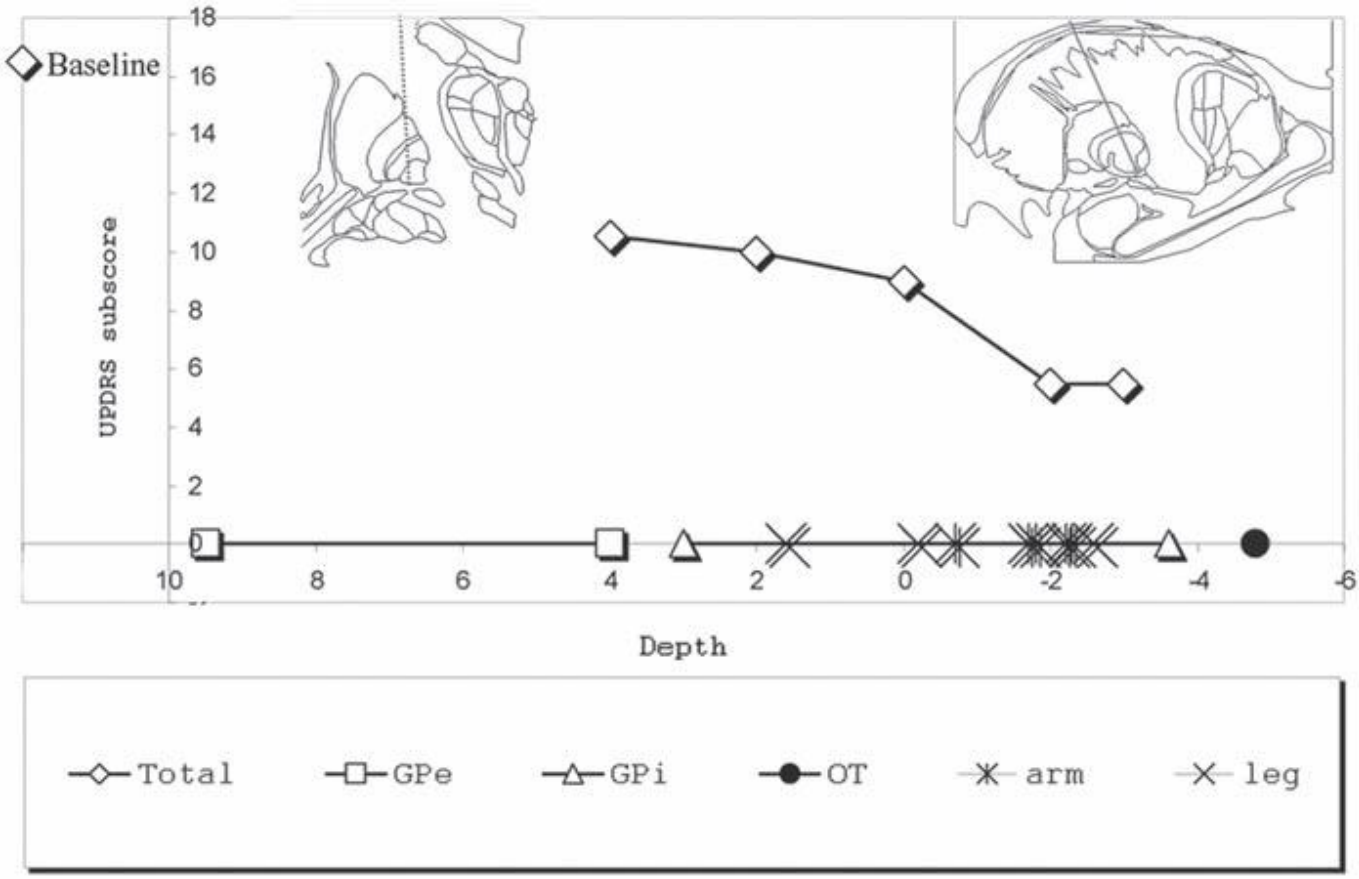

NUCLEUS TOPOGRAPHY

posterolateral motor territory!

- substantial number of neurons in the motor territory of GPi modulate their firing rate in response to proximal movement of the contralateral extremities.
- neuron may only respond to movement in a specific direction - it is important for the examiner to move the joints sequentially in multiple planes.

- often tremor-related cells can be delineated by their audible rhythm, which is synchronous with the patient's tremor.

Somatotopy

- there may be overlap between the distributions of arm- and leg-related cells, but leg cells tend to be more dorsal and medial to arm cells.

Upper and lower limb territories of the GPi are overlapping as shown in this primate map of the GPi and STN (green dots and red squares denote the location of neurons responding to the passive manipulation of the forelimb and hindlimb, respectively):

Source of picture: Starr, Barbaro, Larson "Neurosurgical Operative Atlas - Functional Neurosurgery" 2nd ed (2009); Publisher: Thieme (1899); ASIN: B01FJ0ZZN2 >>

LESIONING SURGERY

DRAWBACKS

1) when lesion is well placed but too small, effects may not last and reoperation is required.
2) when lesion is too large and involves nearby structures (particularly internal capsule), side effects could occur, such as motor deficits (not always reversible).

RF allows stimulation before lesioning (vs. SRS – no ways to stimulate; LITT – patient under anesthesia)

RF

- Cosman principles:
  1) temperature
  2) time
  3) tissue impedance – unknown!
- done with patient awake – stimulate before lesioning.
- stop 1 cm above target.
- *impedance* is confirmed to be neither 0 nor off scale (indicating cable or electrode breaks).
- *thermistor* should indicate body temperature.
- lesioning:
  temporary lesion: 60° to 60 sec (examine patient during and after lesion)
  permanent lesion: 80° to 60 seconds.
- each lesion has 4 mm diameter.
- electrode raised for successive lesions to create desired height of lesion (based on prior mapping, usually 6-8 mm)

THALAMOTOMY

MACROSTIMULATION MAPPING with low-amplitude stimulation (constant 0.1 mA current or changing voltage) - side-extruding component of electrode is slowly advanced in 1-mm increments:

1) **sensory testing**: side-extruding component (stimulating at 50-60 Hz, 1 msec duration, 1-3 V) is advanced ***posteriorly*** - toward somatosensory ***nucleus ventralis posterior (VP)*** - contralateral PARESTHESIAS at < 1 V identify **VL-VP junction**.
   - this **junction** should be 3 mm* posterior to main shaft of electrode.
   - distal hand (esp. thumb) and face responses indicate optimal laterality
     Target is just anterior to thumb area!
   - leg responses indicate too lateral position → move medial.
   - facial paresthesia only or respiratory inhibition suggest placement is too medial.

2) **motor testing**: side-extruding electrode (stimulating at 2-5 Hz, 1 msec duration, 1-2 V) is advanced ***laterally*** – toward ***internal capsule*** - CLONIC CONTRACTIONS of contralateral limbs at < 1 V identify **thalamo-capsular border** (junction of lateral border of thalamus and posterior limb of internal capsule)
   - this **border** should be at least 3 mm* lateral to main shaft of electrode.
   *for 6-mm lesion.

With proper placing:
tremor arrest should occur at 50 Hz, 1 msec duration, 1-3 V
tremor driving should occur at 2 Hz, 1 msec duration, 1-2 V

LESIONING (THALAMOTOMY)

Examine patient during and after lesion:

1) **"test" (reversible) lesion** - by heating probe to 42-44°C for 60 sec
2) if no unwanted side effects (contralateral paresis or sensory deficit) occur → **complete lesion** by heating probe to 60-80°C for 60 sec – lesion must be 4-6 mm in diameter (lesion size is proportionate to temperature and dimensions of uninsulated electrode tip);
   - raise electrode 3 mm and make second lesion;
   - raise electrode 3 mm and make third lesion.

This is effective in 90% TREMOR cases (parkinsonian, essential, intention tremors).

- **larger lesions** are necessary to control ***high-amplitude tremors*** (e.g. cerebellar intention tremor) or any involuntary movements affecting ***proximal muscles***.
  small lesions are indicated for ***low-amplitude*** primarily ***distal*** tremors (e.g. younger hemiparkinsonian patients).
- more medial lesions are used for UPPER EXTREMITY, and more lateral lesions - for LOWER EXTREMITY.

For RIGIDITY, second lesion in **anterior VL nucleus** is required.

- electrode is withdrawn from initial position and repositioned at **junction of anterior and middle thirds of VL nucleus** (several millimeters medial to target for tremors).
- low-frequency stimulation verifies proper electrode position - ELEMENTS OF MOVEMENT DISORDER must be reproduced.
- often, it is necessary to destroy majority of VL nucleus to correct such movement disorders.

BILATERAL THALAMOTOMY

N.B. bilateral VL lesions can cause permanent ***cognitive & verbal deficits*** (even unilateral large thalamotomies on language-dominant side may cause verbal deficits).

- perform ***initial lesion*** on non-language-dominant side.
- ***second-stage contralateral lesion*** is less likely to result in permanent neurological sequelae if it is:
  - smaller
  - in different area (e.g. globus pallidus)
  - performed ≥ 6 months later.

PALLIDOTOMY

MACROELECTRODE STIMULATION

1) **motor testing**: 5-6 Hz, 1 msec, 2-3 V; for GPi - contralateral synchronous motor twitches at < 2 V indicate proximity to internal capsule → move more lateral or anterior.
2) **induction of tremor / dyskinesia** (sign of good localization): 50 Hz, 1 msec, 1-2 V higher voltages can induce hypertonicity and speech arrest (dominant side)
3) ***visual scotomata*** indicate proximity to optic nerve → raise electrode.
4) **impedance measurements**:

- leaving white matter and entering pallidum - impedance as for gray matter;
- impedance drops when entering ambient cistern, indicating electrode too deep (GPi).

SRS

- only use 1 isocenter* with a maximum dose of 180 Gy and nothing larger than a 4 mm collimator.
  *can use 2 if widely separated
- 120 Gy is reliably ablative – but may not make as large a lesion or as quickly as higher doses.
- first F/U MRI – 3 mos post SRS.

Not safe pallidotomy – GPi has different radiosusceptibility.
Thalamotomy – 130 Gy through 4 mm collimator – takes 5-6 months for tremor reduction.

FOCUSED ULTRASOUND

See p. Rx15 >>

Targeting Platforms

STEREOTACTIC FRAME

See p. Rx11 >>

STARFIX SYSTEM

Manual >>
Brochure >>

CLEARPOINT® SYSTEM

ClearPoint® (MRI Interventions, Inc., Irvine, California, USA, http://www.mriinterventions.com)

http://www.mriinterventions.com/clearpoint/clearpoint-overview

PROCEDURE DETAILS

Flexible headcoil is a must (esp. for kids)

ROSA robot

See p. Op40 >>

MAZOR robot

- skull mounted = frameless approach.
- expert – Dr. C. Halpern.

Frame Link

PLANNING

MANAGING EXAMS

- **load exams** from CD:
  VA: CT, axial T1 with contrast, axial T1 without, sagittal CUBE FLAIR, hybrid exam (if using DTI fibers).
  VCU: CT, sagittal T1 with contrast, axial T2
- if need to **remove exams**: END → Remove exam – shows exam numbers and preview
- **select patient** (if exams come under different names, use "Manage Series" to rename) → will automatically show available images (uncheck undesired ones).
- will need CT (as REFERENCE exam), axial T1 with contrast (axial T1 without is usually not needed), sagittal CUBE FLAIR, hybrid exam (if using DTI fibers).
- just click "Verify Orientation" (there is no way to really verify it).
- click "Auto Merge" (may use on all images at the same time)
  "Point Merge" – click on corresponding points on the scan and then "+" sign. Once 4 points are added it starts showing accuracy. Once happy, click "Verify"
- "Verify merge" (axial, coronal, sagittal planes – look for sella) → NEXT (we don't care about 3D model) → NEXT (make sure it says NEXFRAME as software automatically detects **frameless** when no frame is on CT).

How to achieve best levels on CT – move both sliders to the left → move "L" (top slider) to the right until brain shows "salt & pepper" granularity → move "W" (bottom slider) to the right until see perfect parenchymal view.

StealthViz exports/saves 3D objects in Mach rainbow color map – objects can be colored on FrameLink:

- ***To change the colormap of the fiber tract exam to rainbow and set the level/width to 127/255:***

1. Click the **2D/3D View Options** in the Mach Cranial or FrameLink™ software.
2. Click the **Obj** tab.
3. Select the Fiber Tract series only.
4. Change the **Contrast** setting to **Rainbow**.
5. Set the **Level** slider to 127.
6. Set the **Width** slider to 255.
7. Set **Blend Setting** to 50% or other desired value.

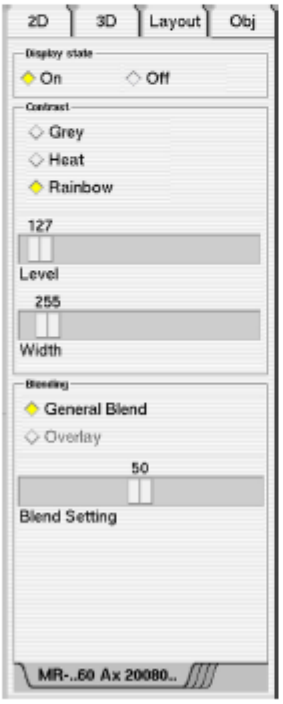

Figure 6-13. *Obj tab*

PLANNING

Reformatting:

- select AC and PC (at ventricular surfaces – imitates historical ventriculogram landmarks), select 3 midline spots (interhemispheric fissure, aqueduct)
- apply SW atlas and Talairach grids; stretch grids to conform with patient's anatomical exam (best to use CUBE FLAIR); mostly work on basal nuclei because impossible to achieve perfect match (SW atlas was created on cadavers with slightly deformed brains)

Setting trajectory:

- choose "Plan 1", rename it (use "Edit" button), then click "Sample" button to get suggestion from software

  N.B. software uses only AC-PC coordinates to suggest target at standard location (SW only serves for visual control)
- (adjust and) "Set Target"

- (adjust and) "Set Entry"
  - play with trajectory by adjusting entry point
  - alternate between "Anatomical" and "Trajectory" views
  - ideally, trajectory stretches 5-6 mm of target nucleus,
  - ideally, entry point is on or 1-2 anterior to coronal suture (not too far anterior - to stay behind hairline), and 2-4 cm from midline.
  - entry point must avoid:
    1) cortical vessels
    2) deep vessels in sulci (i.e. entry should be on gyrus top)
  - trajectory must avoid:
    1) deep vessels
    2) ventricle
    3) caudate nucleus
- then choose "Plan 2" for the other side.
- at the end may create copies of each plan (in case plan is by accident modified; H: may try "undo" button in lower right button row)

CALCULATE BUR HOLE POSITION

- look in sagittal plane (how much in front to coronal suture on CT):

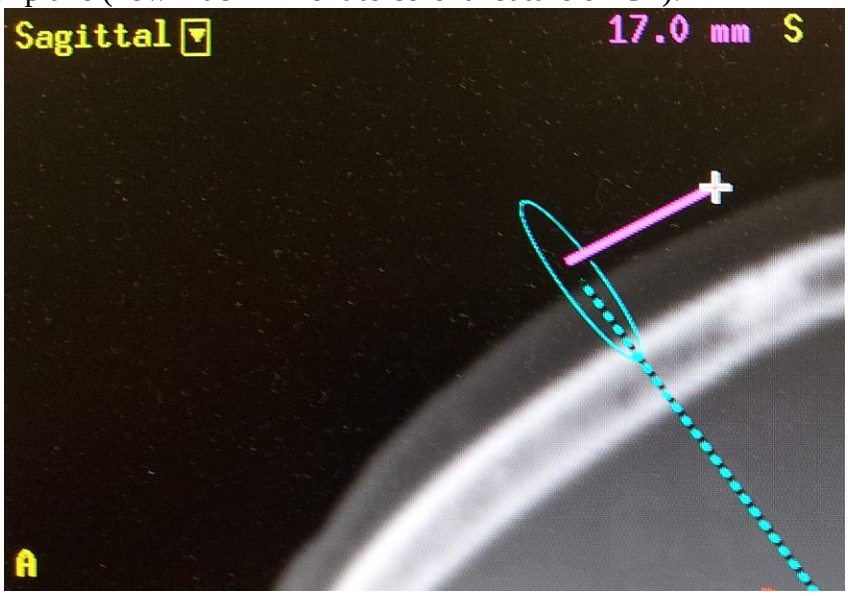

- look in coronal plane (how much lateral to midline):

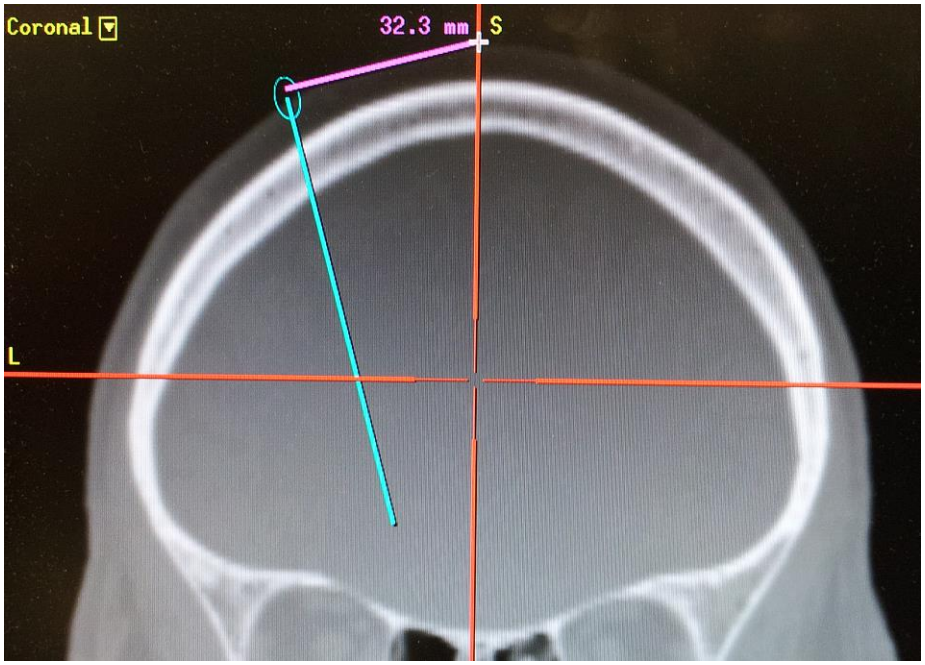

BURNING CD / USB

- <u>look what exam types are needed</u>:
  Go back to very first PREP step (where merging exams) – note series # of each exam that is used
  END → Remove Exams – you will see exam series#, long radiology numbers and previews; locate necessary exams by series #, then note long radiology number.
- <u>burn CD</u>: END → Archive → Insert blank CD → Choose "Stealth Archive" type* → Add exams by selecting long radiology numbers (usually only one CT fits into CD, but multiple MRIs) → Select (burning starts) → "Archiving successful. Would you like to remove exam from hard drive" - do NOT remove exams from hard drive!
  N.B. plans are included with every exam!
  N.B. snapshots / screenshots are automatically included in the folder of first burnt series.
  *step not shown when burning DVDs

INTRAOPERATIVELY

Load CDs.
Merge exams again.
N.B. sometimes postcontrast T1 does not merge properly – OK to leave out.

O-ARM

See general features – see >>
Connect O-arm to Stealth station via ethernet cable.
Go to "Prep" tab → back to "Manage series" (very first step)
O-arm scan → In O-arm screen click "Export to Stealth". Wait until it finishes transferring to Stealth.
Open Patient series – you should see the new CT (as "Axial CT 1") – use it as new **registration series**.
Merge all exams to new reference scan.

N.B. change **registration series** only once (i.e. first CT with bone fiducials); later scans (with microelectrodes in, DBS in) will be automatically renamed to new "Axial CT 1" but do not make them as new registration series (i.e. always stay with original bone fiducial CT as your registration series)

FIDUCIALS

Identify landmarks on image (reference points).

1) Click on fiducial on 3D (easiest way to see)
2) Visualize fiducials best by adjusting contrast: "Window" all the way to the right, "Level" all the way to the left
3) Roughly adjust to fiducial center in orthogonal windows on new CT (and click "Store"); run roughly through all 6 fiducials
4) Then come back to first fiducial and do fine tuning in magnified view (zoom until red scale bar crosses midline)

If working on two sides, rename set to "Right", then copy it to new set and name it "Left"

REGISTRATION

Adjust audio to ≈ 50.
Check frame and Nexprobe geometry on toolkit (adjust camera, clean balls as needed).
Verify Nexprobe.
Touch all bone fiducials clockwise (may "Clear" if it says "Marginal" and check if it improves accuracy).

N.B. software always will label one worst fiducial as "Marginal" but that doesn't mean it is bad per se.

Goal of navigation accuracy is ≤ **0.2 mm (acceptable minimum 0.5 mm)**
Next → "Step" to check accuracy (on registration series) by operator touching several fiducials.

SETTING TRAJECTORY

Go to appropriate plan, turn all scans off, check geometry on toolkit (after it gets close to target; may loosen screw and rotate NexProbe if geometry is unacceptable)

- brain pushes hardware posteriorly and medially so cheat (if unable to perfectly align to target) laterally and anteriorly (unless expect to use posterior track)

After hardware secured to target → Next → Click "Set entry"
Next → check distance to target (length of trajectory) – set Nexdrive Z-stage to that distance:

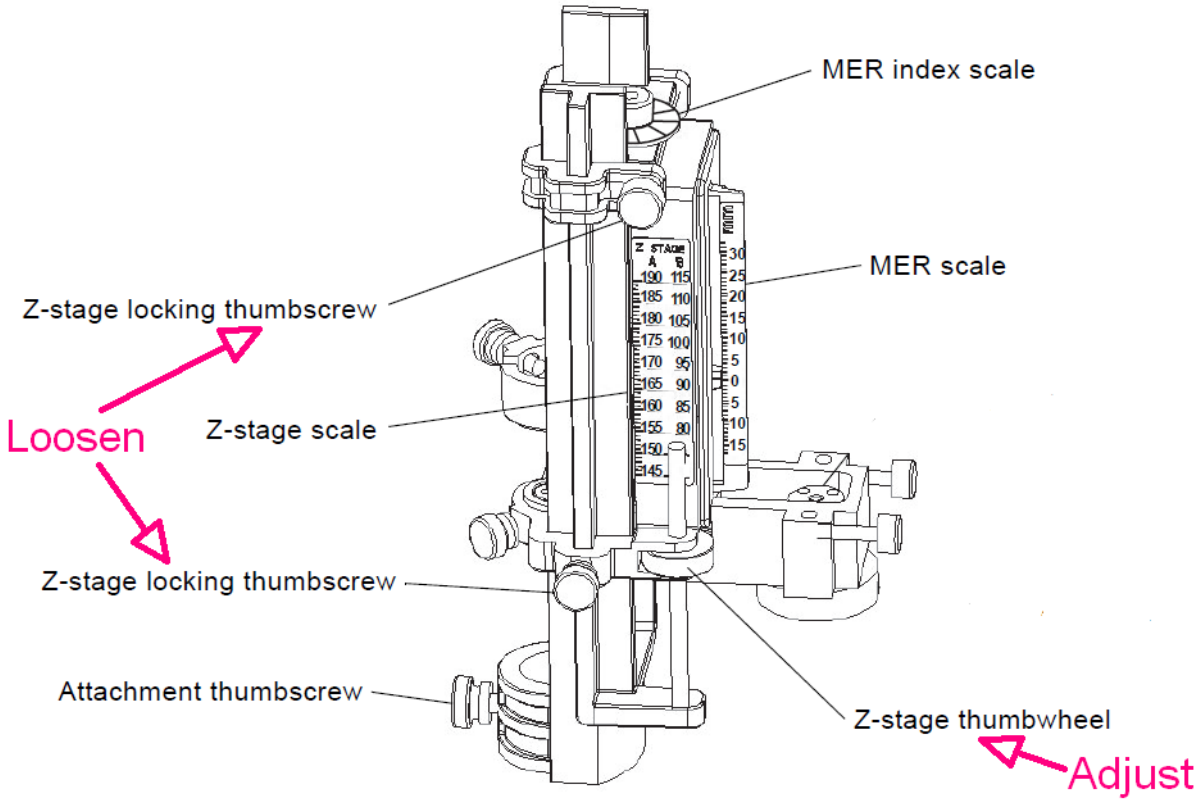

Go to "Plan 10": operator points to A → step → "Set entry"; operator points to E → step →"Set target"; check on axial window (turn crosspin on with F4) deviation from midline → operator adjusts by rotating dial.
Go to **Plan: Planning**: turn on MRI and SW atlas → move 6 mm (for VIM) or 10 mm (for STN, GPi) above target on trajectory.

[If don't hear beep when clicking "step" – means it is on "continuous update" (vs. "foot switch update")]

[If you don't see study image once you turned it on – might be out of window; H: click "<" or ">" to get back on trajectory]

MICROELECTRODES IN

After CT is done, create plan for each microelectrode (e.g. Plan 10 → rename to "R ctr"; Plan 9 → rename to "R post") – check how they look on CUBE FLAIR.

O-ARM

Specificities for FrameLink – see >>

Standard mode – for registration.
High-definition mode – to analyze position of inserted ME or DBS; more radiation so some experts use Standard mode even for electrode position analysis.

Enhanced mode – at the end (to look for bleed).

- always use preop stereotactic CT as a reference study; merge both – MRI and O-arm scan – to preop stereotactic CT (best chances for most accurate merge).
- for most accurate merge result, O-arm must include skull base.
- check for perfect merge result using zoom (e.g. check IAC contours).

"NEXFRAME O-ARM" MODE (FIDUCIAL-LESS)

- automatic fiducial-less registration

- O-arm gantry cannot be tilted more than 15 degrees (in general, keep as vertical as can unless need to tilt).
- O-arm won't let to scan if Stealth camera cannot see passive spinal frame (can leave even unattached to patient but within camera range).

DBS HARDWARE

DBS PULSE GENERATORS (IPG)

Replacement indications >>

	Medtronic	St. Jude	Boston Sci
Rechargeable	yes	-	yes

MEDTRONIC

ACTIVA® PC (MODEL 37601), KINETRA (MODEL 7428)

- multi-program dual-port neurostimulator

Old (discontinued) version – **Kinetra**; old leads need adaptor for Activa PC.

Activa PC (PC = primary cell) FDA Approval Date Apr 2009

Height	2.6 in (65 mm)
Width	1.9 in (49 mm)
Thickness	0.6 in (15 mm)
Volume	39 cc
Battery type	Non-Rechargeable
Expected Battery life	Depends on settings and use
Maximum Electrodes	8
Amplitude	0 - 10.5 V (voltage mode) 0 - 25.5 mA (current mode)
Rate	2 - 250 Hz (voltage mode) 30 - 250 Hz (current mode)
Pulse Width	60 - 450 μsec
Groups	4
Programs	16 (up to 4 per group)
Implant Depth	≤ 4 cm

ACTIVA® RC (MODEL 37612)

- multi-program rechargeable neurostimulator
RC = rechargeable cell
FDA Approval Date Mar 2009

Expected Battery life recently upgraded to 15 years.

Height	2.1 in (54 mm)
Width	2.1 in (54 mm)
Thickness	0.4 in (9 mm)
Volume	22 cc
Battery type	Rechargeable
Expected Battery life	9 years
Maximum Electrodes	8
Amplitude	0 - 10.5 V (voltage mode) 0 - 25.5 mA (current mode)
Rate	2 - 250 Hz (voltage mode) 30 - 250 Hz (current mode)
Pulse Width	60 - 450 µsec
Groups	4
Programs	16 (up to 4 per group)
Implant Depth	≤ 1 cm

ACTIVA® SC (MODELS 37602, 37603), SOLETRA (MODEL 7426)

- multi-program single-port neurostimulator

Old (discontinued) version – **Soletra**

Activa SC (SC = single channel) FDA Approval Date Jan 2011

Height	2.2 in (55 mm)
Width	2.4 in (60 mm)
Thickness	0.4 in (11 mm)
Volume	28 cc (Model 37602) 27 cc (Model 37603)
Battery type	Non-Rechargeable
Expected Battery life	Depends on settings and use
Maximum Electrodes	4
Amplitude	0 - 10.5 V (voltage mode) 0 - 25.5 mA (current mode)
Rate	2 - 250 Hz (voltage mode) 30 - 250 Hz (current mode)
Pulse Width	60 - 450 µsec
Groups	4
Programs	8 (up to 2 per group)
Implant Depth	≤ 4 cm

Medtronic – Closed-Loop s. Adaptive DBS (aDBS)

Activa PC+S – no longer available
RC+S "Olympus" – powerful but complex, limited availability

- "S" stands for sensing – implant strip electrode via burhole over motor cortex.
- aDBS (vs. continuous cDBS) saves battery but also gives better outcomes.

PERCEPT® (MODEL B35200)

See p. E27 >>

- sensing only (adaptive capabilities not yet released)

BOSTON SCIENTIFIC

VERCISE

- rechargeable IPG.
- independent amplifiers – can stimulate several contacts independently and simultaneously

INTREPID study

- Boston Sci DBS for STN

ST. JUDE

INFINITY

- non-rechargeable IPG.

"POCKET" ADAPTORS

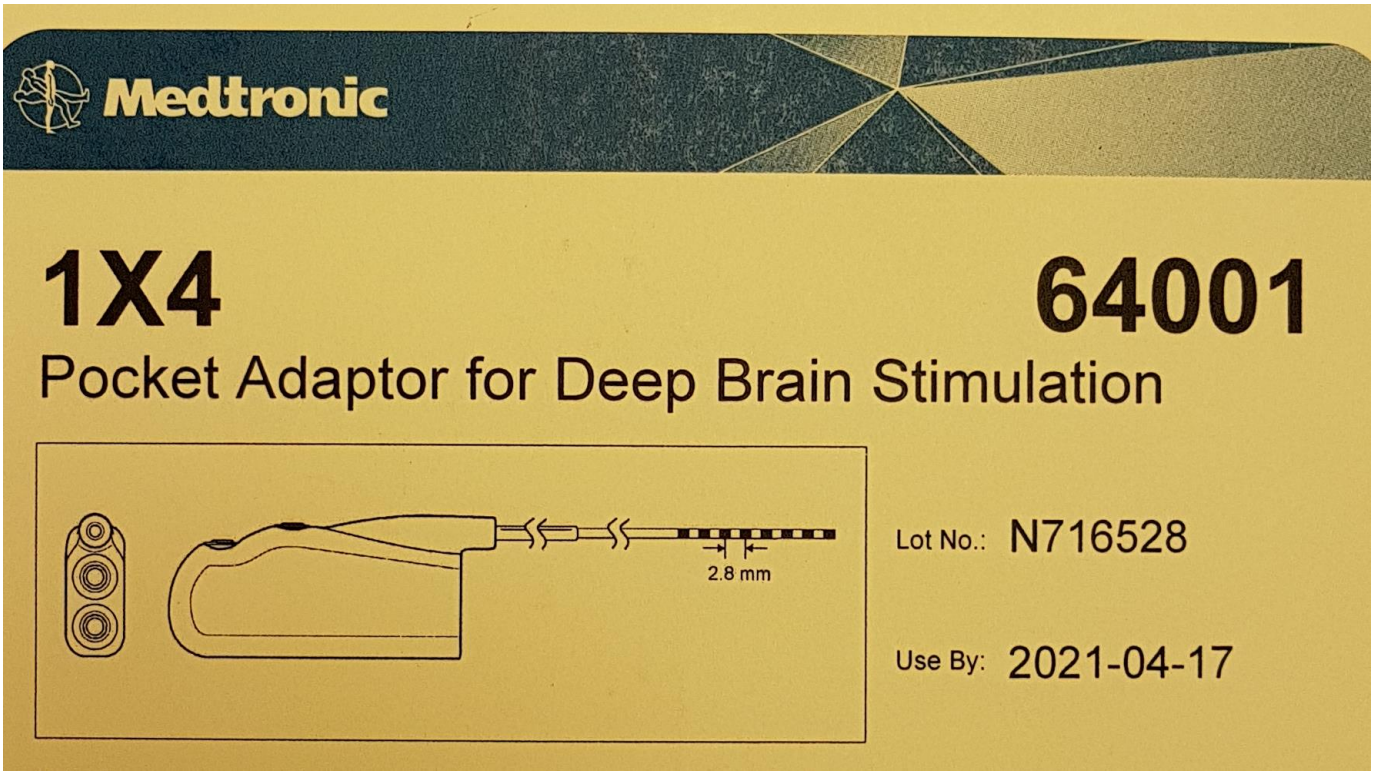

DBS ELECTRODE LEADS

Manufacturer	Model	# Contacts	Contact Spacing	Omnidirectional/ Segmented
Medtronic	3389 3387 3391	4 4 4	2 3 7	O O O
Boston Scientific	Vercise Vercise Cartesia	8 8	2 2	O S
Abbott/St. Jude Medical	Active Tip 6146-6149 Active Tip 6142-6145 Infinity Directional 6172 Infinity Directional 6173	4 4 8 8	2 3 2 2	O O S S
PINS Medical	L301 L302 L303	4 4 4	2 3 6	O O O

MEDTRONIC

1.27 mm diameter quadripolar DBS electrode models with four platinum iridium cylindrical surfaces:

Model	Contact length	Electrode spacing (edge to edge)	Uses	Comments
3389	1.5 mm	0.5 mm	All targets	FDA approved 1999
3387	1.5 mm	1.5 mm	VIM	FDA approved 2002 not used practically

Contact numbering: from tip and up (0, 1, 2, 3); numbering is continued on the other side (e.g., 8, 9, 10, 11).

- if electrodes are ***bilateral***, lowest numbers (0, 1, 2, 3) are assigned to left side.
- why first contact is named "0"? – because original lead designs had a tiny loop at the tip that also served as the most distal contact:

Model Number	**3389**	
Lead		
Length (cm)	40	
Diameter (mm)	1.27	
Electrode		
Number	4	
Shape	Cylindrical	
Length (mm)	1.5	
Individual Surface Area (mm^2)	6.0	
Inter-Electrode Spacing: Edge to Edge (mm)	0.5	
Array Length (mm)	7.5	

Model Number	3387
Lead	
Length (cm)	40
Diameter (mm)	1.27
Electrode	
Number	4
Shape	Cylindrical
Length (mm)	1.5
Individual Surface Area (mm^2)	6.0
Inter-Electrode Spacing: Edge to Edge (mm)	1.5
Array Length (mm)	10.5

ABBOTT / ST. JUDE - INFINITY

- FDA approved for PD on 1/28/2020.
- current steering technology – directional stimulation.
- two leads - both 40 cm long.
- same spacing as the Medtronic 3387 and 3389:
  - 6172 (8 Channel Directional Lead) has the 1-3-3-1 design with each contact separated by 0.5 mm.
  - 6173 (8 Channel Directional Lead) has the 1-3-3-1 design with each contact separated by 1.5 mm.

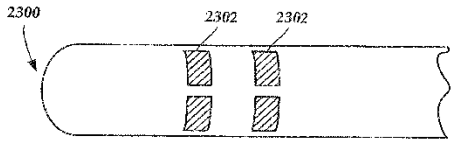

FIG. 23

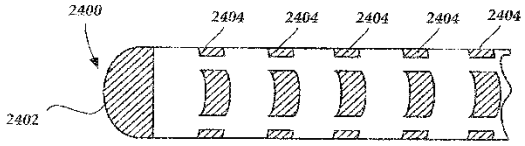

FIG. 24

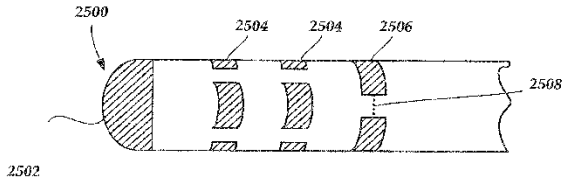

FIG. 25

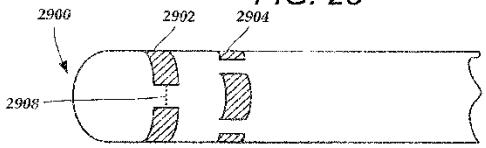

FIG. 29

- marker dot marks contact A ("tip of pyramid") – for VIM direct it posteriorly; for GPi and STN – posterolaterally.
- to current data – directional leads have only theoretical advantage.
- directional lead can save malpositions ≤ 3 mm.

DBS ELECTRODE LEAD CANNULAS

ALPHA OMEGA

<u>Cannula "Zero mm Above Target":</u>

- single use only.
- above target distance 0 [mm]
- length 192 [mm]
- outer diameter 1.8 [mm] – each cannula slot on the bengun also has a diameter of 1.8 mm
- inner diameter 1.4 [mm]
- stylet: length 203 [mm], outer diameter 1.3 [mm]

DBS EXTENSION LEADS

MEDTRONIC (MODEL 37086)

- wires made of steel (vs. DBS electrode leads – platinum) – tolerate mechanical stresses better.

Device Name	Stretch-Coil® DBS Extension	
Length (cm)	40, 40, 95	
Distal End Compatibility	3387, 3389, or 3391 DBS lead	
Distal End Set Screws	4	
Proximal End INS Compatibility	Activa® RC, Activa PC, or Activa SC 37603	

DBS ELECTRODE IMPLANTATION

PREOP

- no PD meds after 21:00 – to have good tremor to work with (caution: some patients experience significant hypertension due to this).
  for ET, avoid beta-blockers; if tachycardia in OR, then give short acting IV
  for PD, ***modern trend is to give meds*** (in worse case, do image-guided under general anesthesia and EMG) – still can do MER but cannot do clinical testing
- enlist **neurologist / clinical neurophysiologist** - for intraoperative testing (optional but very helpful).
- enlist **neuro(electro)physiologist** - for intraoperative microelectrode recording.

ANESTHESIA

- anesthesia on left, neuro nurse on right.
- local anesthesia with IV sedation (e.g. PROPOFOL 35-70 + PRECEDEX* 0.4-0.7)
  *minimize PRECEDEX as it reduces tremor
- A-line (SBP must be < 155 mmHg – use NIPRIDE IV drip PRN)
- Foley catheter
- have FACTOR 7 ready in the room.

Antibiotics

- VANCOMYCIN, 1 g IV (continue 24 hrs postop) + GENTAMICIN* 80 mg IV (just 1 dose preop)
  *now replaced with CEFAZOLIN due to emergence of vancomycin-resistant MSSA

Sedation

- *patient must be awake* for CT and for intraoperative testing (use short-acting or reversible anesthetic [propofol, midazolam, fentanyl, Precedex] during burr-hole procedure).
- sedation must be stopped:
    1) after local anesthetic injection → "back to sleep" after CT (to prepare for bur hole)
    2) after bur hole is done → stop sedation ASAP
    3) "back to sleep" for wound closure.

POSITIONING

- patient ***supine*** with reflex – head of bed and legs* up (just as during scan - to prevent any shifting of target) or ***sitting up*** with strap to avoid downward slip.

*to prevent air embolism

- make sure that hands and feet are free and visible for testing; drapes placed to keep face exposed.
- radiolucent head holder with collar.
- <u>O-arm is brought in</u> (usually arm support is biggest obstacle – move caudad as far as possible and adjust soft arm support) → ***park***, ***intermediate***, and ***scan*** positions are established and saved into O-arm memory:

  - extend O-arm all the way out of unit (will prevent any collision zones).
  - lift-and-shift O-arm on the patient (O-arm at upper arm level) and wag forward to establish ***park*** position; come out of lift-and-shift.
  - translate straight out (watch if enough space will be for tower) – set ***intermediate*** position
  - go up and wag slightly forward; do AP and lateral XR (make sure enough space for frontal fiducials) – set ***scan*** position.
  - repeat all positions make sure everything moves smoothly.
- hairs are clipped (a must for revision surgery as must see hardware; optional for de novo DBS – but hair must be short so to keep all in operative field by combing up).

<u>If patient wants to keep the hair</u>:
- mark anatomical landmarks, fiducial sites, incision site without cutting a single hair as all markings are provisional only.
- prep with Betadine.
- cut the hole in the drape which is smaller diameter than patient's crown; this way the drape stretches and fits snuggly over the head exposing the incision site but fiducial sites remain covered with the drape.

BONE FIDUCIALS

- mark midline and coronal suture (depressed, not ridge, portion of skull – but may verify on CT how coronal suture looks).
- mark approximate bur hole point(s), bone fiducial points (don't go too posterior).

FIDUCIAL-LESS

- place FESS frame on the forehead (after scalp was cleaned with chlorhexidine sponge and alcohol)
- standard mode O-arm scan
- use Stealth probe to mark bur hole site on scalp; also mark midline and connector site incision on scalp.

APPROACH

- prep whole head with Chlorhexidine while assistant holds head elevated → place sterile towel under head.
- place special transparent drape: first Ioban part on patient's head (first place on occiput as far as you can reach) → plastic draped on O-arm.

BONE FIDUCIALS

- infiltrate with local anesthetic (≈ 2 mL at each site) 6 bone fiducial sites (2 frontal + along eyebrows to block supraorbital nerve, 2 temporal, 2 occipital) → stab wounds with Colorado Bovie → screw in fiducials with electric driver → tighten with regular driver → staples on both sides for hemostasis → protective plastic caps (improve CT quality at air-metal interface).

Importance of larger number of fiducials along with fiducials to be placed circumferentially around target volume (in order to decrease errors):

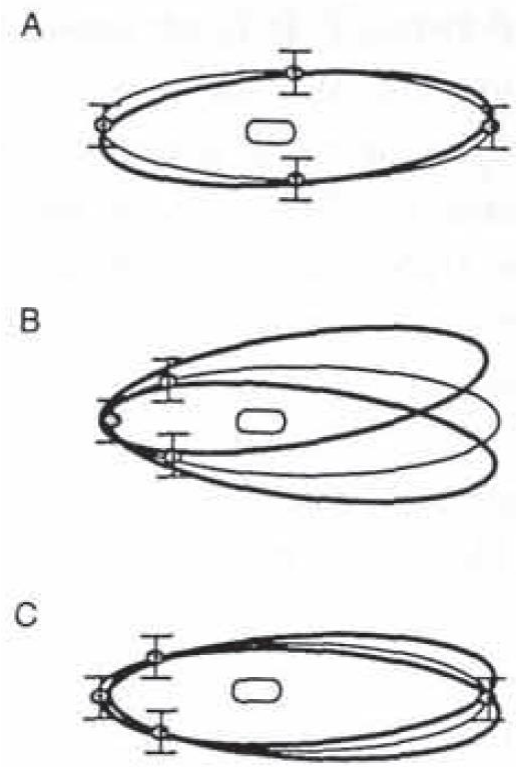

Source of picture: Kitchen et al. (1993) [1]

- approximate bur hole site is marked with a taped bone fiducial (fiducial head at entry point, the rest of fiducial sagittal pointing posteriorly).
- enhanced mode CT scan with O-arm (lessen sedation so patient stops snoring – better quality scan; N.B. too light sedation will increase tremor – poor scan).
- match stereotactic space on Stealth → calculate exact entry point

INCISION

- stab (no side-to-side cutting – preserves pericranium) all the way down with Colorado tip / #15 blade → needle drill to mark exact entry point on the skull (if doing bilateral targets, both sites are marked at the beginning as scalp will shift doing first site).
- **coronal** / sagittal <u>incision</u> with #15 knife blade (approx. 6.0 cm – depends on scalp thickness) under local anesthesia (in fan fashion, plus, across forehead to block supraorbitalis if not done yet).
  - incision only through galea (use cricket retractor; switch to Weitlaner after galea is cut).
  - if patient had one side done earlier, match incision with contralateral side.
- (Betadine irrigation →) vancomycin irrigation.
- undermine subgaleal space in all directions → create pericranial flap (#15 blade) with base anteriorly, reflect it anteriorly (with Penfield #1).

BUR HOLE

- mark crosspin on skull bone → bur hole (continuously irrigate out bone dust – will prevent premature drill stopping).

- mark 2 mm edge around bur hole with pen → enlarge bur hole (by 2 mm) with matchstick drill circumferentially superficial edge of bur hole (just to make sure clip at end of case will sit properly) → undermine bur hole on one side* with drill ± Kerrison punch.
  *e.g. laterally for GPi; for VIM, STN no need to undercut bur hole
- secure STIMLOC BASE with 2 screws (groove for lead points posteriorly; align inner medial edge of plastic ring with medial edge of burr hole – so more space remains on lateral side for GPi; do not overtighten – will warp plastic – clip at the end won't lock).
- secure NEXFRAME BASE with 3 screws (1 screw posteriorly, 2 screws anteriorly) and silicon gasket (only for GPi - on lateral side, thus place additional fourth screw on gasket side).
- attach passive frame holder (reference arc) on the medial side of NEXFRAME base.
- attach blue butterfly passive frame (try to be not in the same plane as NEXFRAME base).
- register into stereotactic space (before opening the dura!; lately Dr. Holloway opens dura first) – touch all bone fiducials clockwise (starting from right forehead), then bone fiducials in front and back of particular bur hole again to check for accuracy.

FIDUCIAL-LESS

- do another standard mode O-arm scan for automatic registration.

DURA OPENING

(later it will be difficult to do through the small tower base lateral window)

- cauterize dura with bipolar → open in stellate fashion with # 11 blade → coagulate dura edges with bipolar → insert small patty → open dura completely with Bovie (on cut, not coagulate; depress and protect underlying brain with small patty).
- bipolar coagulate cortical surface spot → stab with # 11 blade (corticotomy); try to preserve larger vessels; may push them away by bipolaring pia – pia shrinks and retracts the vessel away.
  - for VIM, entry site is usually the middle of bur hole.
  - for GPi, entry site is at the projection of the lateral side of inner ring of Stimloc.
- Gelfoam and DuraSeal (to minimize egress of CSF).

INSERTION

See Nexframe manual >>

- tower base attached.
- set trajectory to target using Nexprobe.
  - if hitting limit, then use *offset* Ben gun (also *offset* Nexprobe)
- set tower to distance measured on Stealth; start at 30 mm above target, connect to electronic potentiometer (that shows advancement in numbers), then dial down to 10 mm
  N.B. start at 10 mm above target!
  For VIM – start at 6 mm above target
- two cannulas placed - 1 in center and 1 in additional (e.g. posterior or posterolateral*) track.
  *for that need to place bengun in X configuration
  - when placing second cannula, try to diverge them (as brain has natural tendency to converge them).
- alternatively, only one cannula is placed and then high-def O-arm mode shows exact location – operator can decide where to place the second cannula.

DRIVES

A. Nexdrive
B. Alpha Omega headstage drive – see p. Op40 >>

MICROELECTRODE RECORDING (MER)

Only for GPi, STN (not for VIM)

Electrophysiologist (Dr. Mark Baron) uses SW atlas sagittal templates (17-22 mm from midline). He uses color coding: GPi, GPe, border cells

STN

- microelectrode recording was carried out on both of these. It was robust, subthalamic nucleus with many motor responsive cells on the center tract with relatively quiet anterior track, although nigra was encountered at 8.2 on the anterior track and 8.9 on the center track. Test stimulation of these 2 tracks revealed no efficacy and particularly no efficacy on his tremor. Testing for side effects at 120, pulse within 10 volts revealed no side effects at 2 above. At target depth, which was below MER STN, stimulation caused transient foot tingling on the center track and it seemed to drive the tremor on the anterior track. Based on the lack of efficacy a CT scan was obtained and this revealed that the center track was well placed in the intended location with coordinates of 11.4, -3.6 and -5.7. The anterior track was at 12.1, -2.2 and -7.2. It was felt that the anterior track was clearly not in STN, and so a more posterior track might be more efficacious and get better tremor reduction. Therefore, a microelectrode recording was carried out on the posterior track and here again we had robust STN with many motor responsive cells. This was also a much longer track with STN from about 4 to either 10 or there was a transition zone between about 10.5 to 12 with cells that could have been nigra or STN. Test stimulation along this track did show a reduction in symptoms at baseline from 12 to 9 and then with stimulation it reduced further to 7. However, there was very minimal effect on the tremor. At target there was some transient tingling at 7 volts, 120 pulse width and at -2 at 6 volts there was tingling at 120 pulse width. That is despite having 2 tracks strongly in the motor sensory subthalamic nucleus we still did not have good efficacy in terms of tremor. Therefore, the decision was made to make a move that was lateral to the posterior track as it was felt that tremor control was more likely laterally. This required the off set ben gun, however, the patient had shown no intracranial air on the prior CT and so it was felt that removing the cannulas would not result in any brain shift. Therefore the offset piece was put in place and a cannula was introduced 2 mm posterior and 2 mm lateral to the center track. This was a relatively quiet microelectrode track which proved on test stimulation to be in the internal capsule and with clear motor side effects with test stimulation, although there was some transient reduction in the tremor with activation of the device, it just did not persist, and so at this point another CT was obtained and this showed the lead to be at lateral 14, -5, -4.7. Based on this, it was felt that we needed to go more posterior and less lateral as we were getting internal capsular effects. Therefore the more medial posterior channel of the ben gun was utilized and this put the cannula at 3.5 posterior and 0.7 lateral to the original track. This channel was not microelectrode recorded in the interest of patient fatigue. Test stimulation immediately revealed efficacy with actually a micro effect such that the tremor was down to a 4 and immediately with stimulation at 6 above the tremor dropped to 1 and was 0 at 4 above, 2 above and target at very low voltage. There was just transient tingling and no motor side effects with this. A CT was obtained with the microcannula at target. The micro cannula was then replaced with a lead and this was placed at 2 above. That showed that with the distal 2 contacts, the middle 2 contacts and the most proximal 2 contacts there was no

tremor. However, there was some dysarthria at 6 volts at the most distal 2, therefore the DBS was implanted at 4 above on this final track.

- when best track (best beneficial effects, least side effects, largest security margin between threshold for improvement and side effects) has been identified, corresponding microelectrode is removed and replaced with final lead (e.g. DBS 3389, 1.5-mm contact length, 0.5-mm spacing, 1.27-mm diameter).
    - final lead in plastic holder – lead tip protrudes that plastic-metal interface aligns with plastic holder end.

STIMULATION

VTA (VOLUME OF TISSUE ACTIVATED)

With stimulation configuration of: pulse width= 90 microsecond, impedance = 1000 Ohm, the spread of VTA is following (these spreads are from the center of electrode contact):

-1V: Horizontal spread = 1.97 mm; vertical spread = 1.81 mm; VTA = 29 mm cube.
-2V: Horizontal spread ~ 2.25 mm; vertical spread ~ 2.4 mm; VTA ~ 57 mm cube.
-3V: Horizontal spread = 3.32 mm; vertical spread = 3.21 mm; VTA = 148 mm cube.

i.e. roughly 2 mm radius ball (center is center of electrode)

If you increase the pulse width to ~120 msec, the VTA spread will increase:
-1 V: Horizontal spread ~ 2.13 mm; Vertical spread ~1.96 mm; total VTA ~ 35 mm cube.
-2 V: Horizontal spread ~ 2.52 mm; Vertical spread ~ 2.7 mm; total VTA ~ 80 mm cube.
-3 V: Horizontal spread = 3.63 mm; Vertical spread = 3.53 mm; total VTA = 195 mm cube.

BENEFICIAL EFFECTS

- improvement of symptoms

- all symptoms, including simulated gait, could be tested;
    1) **wrist rigidity** - most convenient because it does not require active patient participation and can be scored in operating room with semiquantitative scale.
    2) **speech and akinesia** are difficult to test consistently.
    3) **tremor** is excellent symptom to use but is often absent in patients with advanced akinetic-rigid stages.
- symptoms may improve when electrode enters target.

"microelectrode" effect (local effects due to electrode pass before lesion):
- may make it impossible to do stimulation "on" testing because patient is already improved! (however, it is also a good sign that the electrode is on target).
- spontaneously abates in 2 weeks.

SIDE EFFECTS

(limiting factors for efficient stimulation)

- side effects depend on structures, mainly fiber tracts, surrounding target that are reached by spread of current.

- placing final electrode in these places would limit possibilities of efficient stimulation.

MICRELECTRODE STIMULATION

Performed with microelectrode that has been used to record neuronal activity

- through MR collar (so retract electrode back – distance number on potentiometer must be read as if pulled back 10 mm)
- stim at 6 V (for efficacy) and 10 V (for side effects).

MACROSTIMULATION

- for all nuclei – for effect + side effects
- radius of tissue volume effectively stimulated with DBS is hard to estimate
- Kuncel et al. - using a combination of modeling and clinical responses to DBS of thalamus – effective radius of 3.9 mm at DBS voltage of 3.5 V.
- 2 V is optimal stimulation voltage; but test at 3 V (for efficacy) and 6 V (for side effects).
- reposition if side effects at ≤ 3 mA (90 pw).

DBS LEAD INSERTION

- take out ME cannula (leave other ME cannula in – holds brain like spear).
- insert DBS cannula.
- place DBS lead in holder-distance calibration plastic device.
- place DBS lead.

END

- patient is allowed to have additional sedation.
- unscrew canula holder → pull ME cannula out → partially pull DBS canula out (almost to the top) to expose DBS lead → remove Gelfoam and DuraSeal → DBS lead is secured in place with plastic clip (smooth side up, metal holder tip; close clip with plastic holder tip – check if secure enough by attempting to open it) → dry lead surface and mark lead exit point with new marker → unscrew yellow lead holding screw → remove DBS lead stylet → remove canula (while watching marking on DBS lead) → pull DBS lead down (with bayoneted pick up) to the base of Nexframe → remove tower → place plastic clip* while directing DBS lead with bayonet into Stimloc groove → Nexframe tower base removed.

  *historically - sutured to rim of bur hole (made with small oblique twist drill) and embedded in dental cement to prevent leakage of CSF
- DBS lead is tunneled (plastic straw with metal stylet in but without sharp tip!) to posterior bone fiducial incision (which was extended to longer length and full depth to bone).
- place clear boot* and clear protective cap ("torpedo") on lead tip; secure clear boot over torpedo with 2-0 silk tie → tuck torpedo under scalp facing back towards bur hole incision (i.e. into tunneling canal)

*if doing bilateral DBS, torpedoes go on both leads but clear boot is placed on Right side (or VIM) only

- lead is coiled within bur hole wound → 3-4 cranial plating system screws to fix pericranial flap over bur hole (1 screw posteriorly, 2 screws on sides at just below incision level)
- irrigate with Bacitracin / vancomycin
- DuraSeal on whole plastic to prevent CSF leak.
- bur hole incision: close with 4-0 Vicryls for galea → staples → Aquacel Ag dressing (historically: Mepilex Ag→ Tegaderm).
- connector incision: 1-2 full thickness vertical mattress 2-0 nylons → staples → Aquacel Ag dressing
- bone fiducials removed and irrigated out with vancomycin → (Dermabond →) staples (Monocryl for frontal ones) → bacitracin
- stockinette.
- take to CT scanner (check for bleeding, lead placement, pneumocephalus) / do enhanced mode scan with O-arm.

POSTOP (IN HOUSE)

- resume *Parkinsonian medications* immediately postoperatively (also will help a little bit with HTN BP; Dr. Baron says that Sinemet does not affect BP much); if frozen, OK to give extra dose of Sinemet.
- keep SBP < 155 for overnight or 24 hours (if requires PRN meds for BP, keep in ICU overnight), then relax parameters.
- NR mask for 24 hrs if large pneumocephalus.
- mupirocin ointment to bone fiducial sites TID.
- home after 24 hours if no problem.

SPECIAL SITUATIONS

Bilateral surgery

- may be difficult with demented, frail patients.
- strongly consider doing awake – *second side accuracy may be compromised due to pneumocephalus*, so desirable to verify effects with patient awake.

GPi under general anesthesia without MER

- general anesthesia without muscle paralysis.
- still on radiolucent headrest, egg crate (to prevent pressure sores), but no C-collar
- EMG monitoring in contralateral orbicularis oculi, orbicularis oris, arm, ± leg – i.e. internal capsule side effects: implant to target depth and increase voltage until EMG shows response, then try different contacts and wide array.

Revision of DBS due to lack of efficacy

Only with patient **awake**!

PEDIATRIC PATIENT

- place DBS electrode slightly deeper – as brain grows, electrode gets pulled out.

PLACEMENT OF DBS EXTENSIONS AND GENERATOR

Rule: no Bovie if good generator is in the patient! (bipolar is OK).

Use PlasmaBlade* when working over leads

*settings 6 and 6

ANESTHESIA

- general.
- VANCOMYCIN 1 g IV + CEFAZOLIN 1 g IV (vs. just CEFAZOLIN for routine DBS battery replacement).

CHOOSING SIDE

- patients with spasmodic torticollis (cervical dystonia) get bilateral GPi DBS - implant extensions on the side away from which the head deviates
    - IPG is turned at 2 weeks after surgery + the benefits in dystonia take weeks to accrue - this may allow the scar to contract to a greater degree in the foreshortened cervical region, leading to greater discomfort and protrusion when the dystonia ameliorated and the head returned to midline.

POSITION

- supine position (HOB slightly up)
- head rotated to opposite side, on gel donut*

*Dr. Holloway likes flipped gel donut (inside pillow case)

- arm tucked at side.

INCISION

- linear incision on anterior-superior chest infraclavicularly.
- direction from superomedial to inferolateral (i.e. perpendicular to clavicle) – easier later battery replacements.

- 2-3 fingerbreadths from humeral head – to prevent irritation during shoulder internal rotation (or closer to midline where enough subcutaneous tissue exists to protect battery; make sure there is no bulging rib underneath).

DETAILS

- chest: create subcutaneous suprafascial pocket – straight down with Bovie (max. skin-subQ flap thickness 2 cm – if more, may not communicate with programmer properly), then with Metz scissors create pocket.
- open connector incision and irrigate.
  - Dr. Holloway historically used to send protective DBS lead caps to microbiology for cultures (if battery is placed another day than DBS leads – will have early abx sensitivities in case infection develops)
- use Metz and bend tunneler into "S" shape to create path (from head to chest) to pull up lead extensions from chest to head; if there are two extensions, intentionally make one interim skin incision at or just below the mastoid process level - from there the two DBS extensions take a divergent course – one is tunneled more anteriorly while the other – more posteriorly – to minimize "bowstring" development; eventually, the leads converge back at the IPG pocket site.
  - historically, we covered leads with Stimulan paste (do not apply paste to screw heads – impossible to remove!) – not anymore!
- **right** side DBS lead is covered with ***clear plastic sleeve*** in addition to torpedo (**left** side has only torpedo) – remove all those
- slide Silastic sleeves* over leads → connect extensions to leads (each screw box must be held tightly between thumb and forefinger while the torque wrench is applied so that the screw box does not turn within the plastic casing and cut the electrode filaments)
- slide Silastic sleeves over connectors → connect other ends of extensions to the battery and run system diagnostics → secure at either end with 2-0 silk ties.

  *white sleeve on Right-side (or VIM) "white is right or VIM"; clear – on left side or GPi
- secure connectors itself with silk stitch under the pericranium (connector aligned along incision).
- connect extensions to generator (left side DBS goes on top / anterior connector slot [receptacle # 1], right side – on bottom / posterior), tighten with special screw until you hear 2-3 clicks.
- check impedances to be within normal limits.
- coil excess of extensions underneath generator.
- copiously irrigate multiple times with vancomycin solution;

  historically, we would irrigate with Betadine, then bacitracin and then fill all incisions with Stimulan granules.
- slip generator into its pocket (side with printed label up).
- secure generator to underlying pectoralis fascia with silk anchor stitch (1 or 2).

CLOSURE

- chest incision: bulk of tissues is approximated over generator with 2-0 Vicryl in interrupted fashion → subcuticular interrupted 4-0 Vicryl with inverted knots → Dermabond → two baby Tegaderms.
- connector scalp incision:

  temporary closure (between cranial and IPG stages on the same day): only staples.

  temporary closure (when cranial and IPG stages are separated by several days): one full thickness vertical mattress 2-0 nylon and then staples.

permanent closure: 4-0 Vicryl for galea, then staples → Aquacel or Silverlon dressing (no dressing for bur hole incisions unless they were opened during procedure).

- neck incision: 4-0 Vicryl stitch, then staples → small Tegaderm

POSTOP

- home same day.
- initial postop clinic visit – at 2 weeks postop: head CT, IPG tuned on at low settings (usually 1.0-1.5 V).

REPLACEMENT OF DBS GENERATOR

INDICATIONS

see >>

PREOPERATIVELY

Only test needed – UA
Cannot test impedances preop if battery is dead.
Normal impedances are < 2000.

ANESTHESIA

- local, plus, IV sedation.
- CEFAZOLIN, 1 g IV (vs. all other DBS procedures – VANCOMYCIN + CEFAZOLIN)

POSITION

- supine position with arm tucked at side.
- head rotated slightly to opposite side.
- place any mask on patient so does not breathe on operative field while prepping.

OPERATIVE DETAILS

Rule: no Bovie if good generator is in the patient! (bipolar is OK).

- incise old scar.
- dissection with PlasmaBlade* (does not damage lead insulation) gradually exposes DBS generator and its leads.

*settings 6 and 6

- hemostasis with bipolar electrocautery or PlasmaBlade.
- cut anchoring silk suture.

- leads are disconnected and reconnected to new generator (± with help of new adapters).
  N.B. work with one lead at the time!
  Mark lead flush to battery case with marker while still in old battery; then will know how far to push lead into new battery (old leads are fragile and may break if pushed unnecessarily; if lead is too soft – may stiffen it in the cold saline).
- place new generator into previous subcutaneous pocket with leads coiled underneath → interrogate generator → anchoring silk suture.
- irrigate with vancomycin solution.
- bulk of tissues approximated over generator with 2-0 Vicryl in interrupted fashion → 4-0 Vicryl in interrupted fashion with inverted knots → Dermabond → Tegaderm.

POSTOP (IN HOUSE)

- if old battery was completely depleted, when turning new battery on, may need lower voltages.
- make take shower on POD1; remove Tegaderms on POD3.

EXPLANTATION OF DBS LEADS

- if patient is on anticoagulants / antiaggregants, try to avoid DBS electrode removal from brain (if not very sick, remove battery and extensions, take cultures, start antibiotics, and take to OR several days later again for DBS electrode removal).
- make incisions over old scars.
- dissect with PlasmaBlade DBS lead loops.
- undo Stimloc screws.
- pull Stimloc-lead complex – do not touch skin with DBS contacts → cut with fresh scissors DBS tips and send for cultures.
- postop: sit up 45 degrees to prevent CSF leak.

POSTOPERATIVELY

WOUND CARE

Keep head dressings on for 3-5 days (or until second stage surgery);
- when taking shower, use shower cap (to avoid water pounding on incisions).
- if hair was preserved (so no dressings), patient has to apply antibiotic ointment to incisions TID for 5 days.

ELECTROSURGERY

- electrocoagulation:
  PlasmaBlade – OK without restrictions
  Bovie – turn stimulator off, use lower current settings, place grounding pad away from DBS site (e.g. on the opposite leg than IPG).

Rule: no Bovie if good generator is in the patient! (bipolar is OK).

- transcranial magnetic stimulation (TMS) is contraindicated.
- diathermy (e.g., shortwave diathermy, microwave diathermy or therapeutic ultrasound diathermy) is contraindicated.

MRI

- MRI is safe as long as DBS ***lead is connected to battery*** and all ***impedances are WNL****; if DBS lead is not connected (e.g. intraoperatively), current FDA approval is up to 1.5 T.

  Larson PS, Richardson RM, Starr PA, Martin AJ: Magnetic resonance imaging of implanted deep brain stimulators: experience in a large series. Stereotact Funct Neurosurg 2008; 86: 92–100.
  Fraix V, Chabardes S, Krainik A, Seigneuret E, Grand S, Le Bas JF, Krack P, Benabid AL, Pollak P: Effects of magnetic resonance imaging in patients with implanted deep brain stimulation systems. J Neurosurg 2010; 113: 1242–1245.

  *250-2000 Ohm in monopolar configuration, 250-4000 in bipolar configuration
- Percept PC has full-body 3T MRI eligibility (1.5T with Activa PC).

Blending of the DBS electrode between the O-arm and MRI images in the oblique Trajectory2 view. **A**, only the O-arm image (blend 0%), **B** blend 25%, **C** blend 50%, and **D** only the postoperative MRI appearance of the 3389 DBS electrode (blend 100%). Note that the bloom artifact is dumbbell shaped on the MRI. The dimensions of the artifact extend below the position of the electrode, as seen on the blended CT and MRI images:

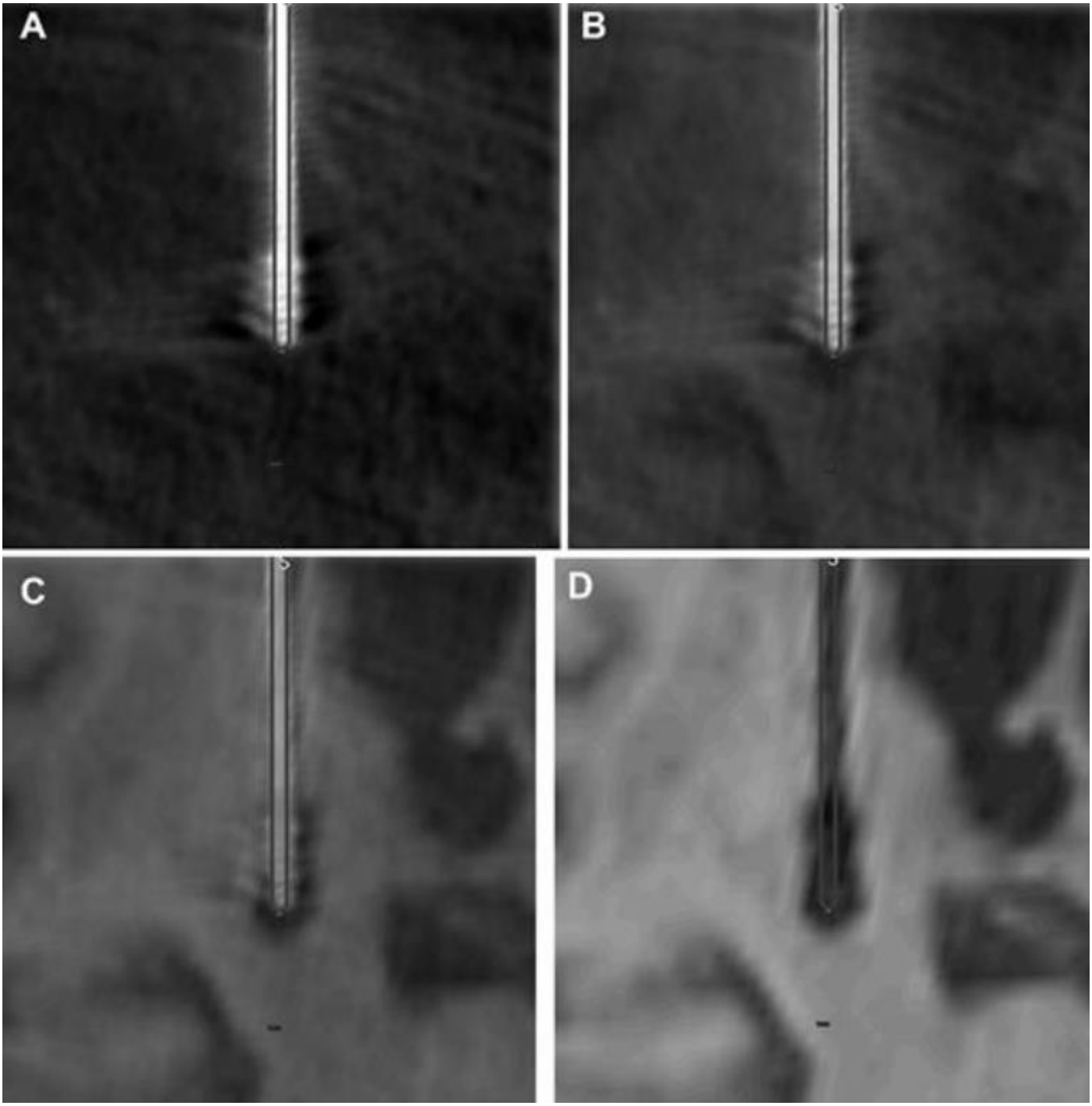

Source of picture: Stereotactic Accuracy and Surgical Utility of the O-Arm in Deep Brain Stimulation Surgery. Jonathan Dennis Carlson et al. Oper Neurosurg (Hagerstown) (2017) 13 (1): 96-107.

- in trajectory view, the center of the dumbbell is clicked → extend a new point along the long axis of the DBS electrode 5.25 mm distal from its center (based on the geometric distance from the center of the 3389 DBS electrode from the center to the tip of the electrode):



FOLLOW-UPS

After DBS implantation:

at 2 weeks – taking staples out, routine 0.6 mm head CT, turning stimulator on low settings (e.g. unipolar mode contact 2-, 2.0 V, 60 msec pw, 185 Hz); if patient gets excellent benefit, warn that it might be due to combination with microeffect and it may get slightly worse later.

at 6 weeks – contact mapping and finding the best stim parameters (may need several visits to find that, up to 1 year). *see below >>*

yearly ("at anniversary of DBS surgery") – on-off meds UPDRS, neuropsych evaluation.

FOLLOW UP, PROGRAMMING

DBS is turned on at low settings at 2-week postop visit (and head CT is obtained with 0.6 mm cuts – for lead position analysis as pneumocephalus is now gone).

↓ 4-6 weeks

DBS contact mapping

↓

Annual (at surgery anniversary for the rest of life) follow ups with medication off-on exams and neuropsych evaluations.

- **cycling** – turning stimulation off at night (may do for any target nucleus).
- no official recommendations how high to go on pulse width, frequency.
- **bipolar stimulation** (vs. monopolar) – limits current spread to surrounding tissues.
- shorter pulse width = larger therapeutic window (can use higher voltages).

Low frequencies *stimulate*, high frequencies *inhibit*

- ***high frequency stimulation*** (100–180 Hz) inhibits pathologically synchronized low frequency network oscillations ("informational lesion", disrupting errant signals from being propagated downstream in a neural network as a result of upstream disease processes).
- ***low frequency stimulation*** (5–40 Hz) has the opposite effect and can excite neural elements.
- DBS cannot be simply classified as inhibitory/excitatory as stimulation of any kind has differential effects on different neural tissues (e.g. inhibiting soma and exciting axons) and the overall network effect is a key.
- **axons** have a lower threshold for activation by electrical stimulation than **cell bodies** and usually respond to high frequency stimulation.

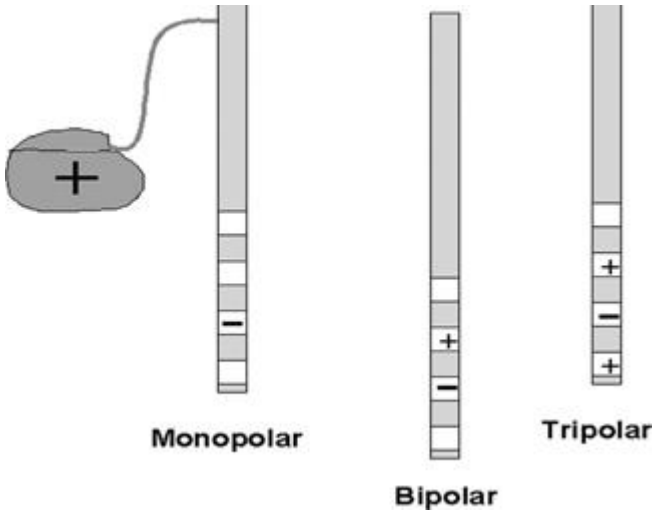

GPi

N.B. with GPi, some symptoms may respond quickly to stimulation; there may also be a significant delay of hours to day in therapeutic response (same after turning GPi DBS off – long washout period).

VIM

- for **bilateral VIM implants** – activation in stepwise fashion:
  1) activate one side
  2) map that side and activate another side (tell patient to watch for dysarthria, ataxia, dysmetria – if that happens, turn the new side off or decrease voltage)
  3) map another side

BATTERY CAPACITY

ERI = elective replacement indicated (needs replacement in 6-8 weeks)

- if old battery was completely depleted, when turning new battery on, may need lower voltages (as patient might have been ramping up voltages to compensate for dying battery).
- **Activa RC** life has been extended to 15 years.

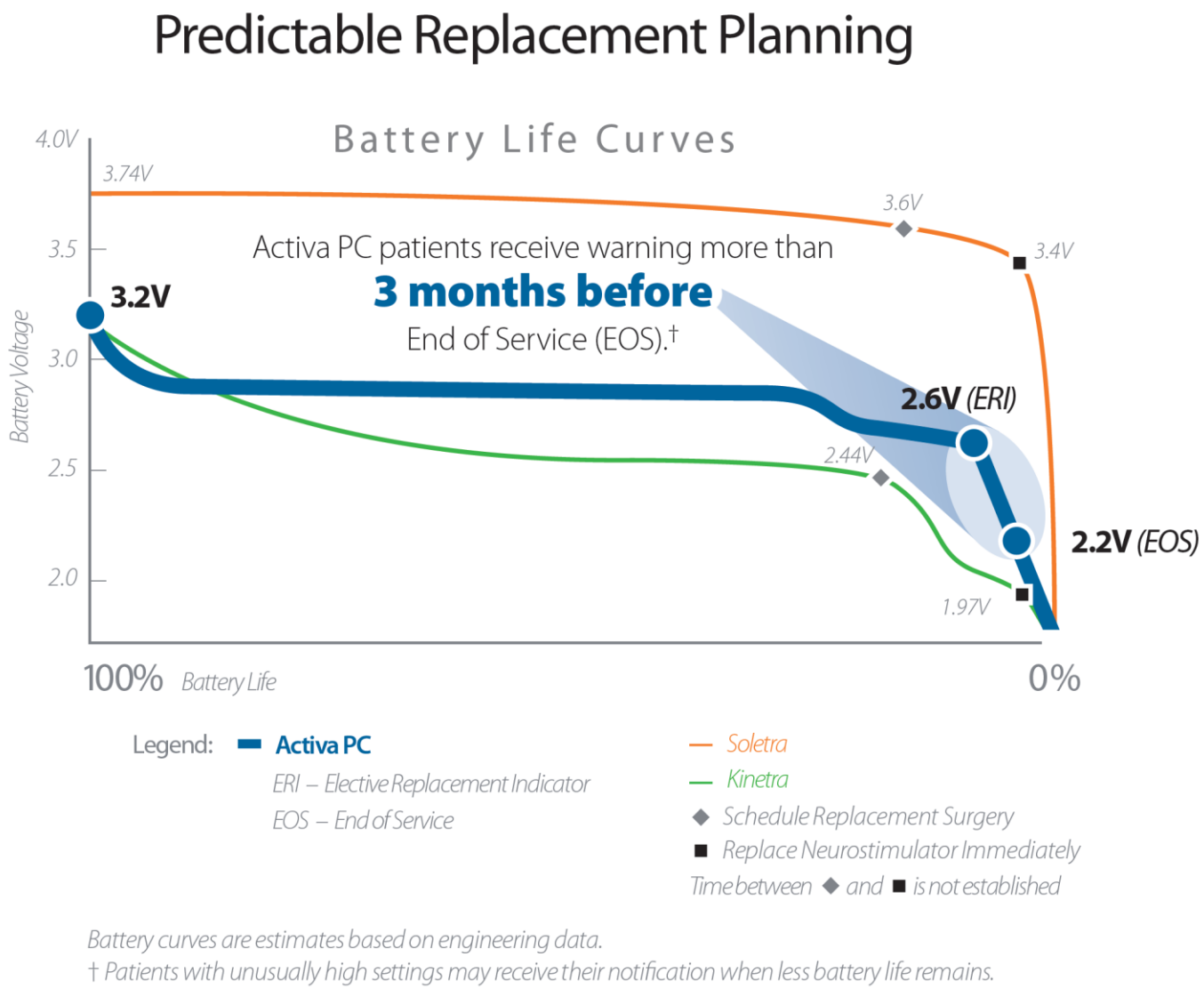

COMPLICATIONS

BLEEDING

1-3% risk of **bleeding** with significant morbidity and mortality – most feared complication!

Reported rates in the literature:

all hemorrhages 0-34.4% (Patel et al. 2007; Chhabra et al. 2010).

symptomatic hemorrhages 0-6.9% (Gill et al. 2007).

Risks for hemorrhage - history of hypertension - rate of hemorrhage 2.5 times higher for hypertensive patients compared with normotensive patients (Xiaowu et al. 2010).

- mostly at entry point or subcortically, rarely in target (some studies have more common with VIM, least common with GPi, other studies – the opposite).
- 93.2% asymptomatic or transiently symptomatic; 6.8% - permanent deficits.

INFECTION

(1-15% of all patients)

- most develop within 8 months after surgery, most often at IPG
- causative organisms most often implicated in DBS hardware infections: staphylococcus (epidermidis and aureus), Enterobacter, streptococcus, pseudomonas and rarely mycobacterium or candida.
- infections can be divided into two types.
  1) **external infections** - begin as erythema or healing problems; does not give rise to fever or meningitis. Causative bacteria are usually from the patient's skin flora.
  2) **internal infections** (rare) - due to hematogenous spread of bacteria to the hardware; may cause meningitis or intracranial abscess
- role of ***incision*** (Constantoyannis et al., 2005): patients with straight incisions were 6 times ($P<0.03$) more likely to develop an infection; vs. curvilinear incision - designed to avoid placing the hardware directly beneath the incision (as in VP shunt surgery).

Treatment:

- unless it is just stitch superficial abscess, *entire system must likely will need to come out*; rationale:
  - if it is still in cerebritis stage, DBS can be reimplanted later;
  - if it progressed to abscess – any subsequent reimplantations will become infected again.
- preop **ESR and CRP** (to follow progress later) and **CT w IV contrast** (look for abscess, esp. if patient presents with new neurologic manifestations).
- some authors sterilize explanted IPGs and reimplant in different location (usually the opposite side).

Table 4: Attempted non surgical treatment of infection following DBS surgery

Series	Cases of Infection	Success with antibiotics alone
Oh et al[15]	6	1 (17%)
Kumar et al[21]	4	3 (75%)
DBS study group[17]	4	2 (50%)
Levy et al[4]	23	1 (4%)
Koller et al[3]	2	2 (100%)
Present study	9	3 (33%)

Incision infections after DBS surgery have occasionally been successfully treated without explantation of the device.

Constantoyannis et al. (2005)

Further course

a) just **cerebritis** – may reimplant DBS again.
b) **brain abscess** – reimplantations end up infected again.

ISCHEMIC STROKE

0.8%

VENOUS AIR EMBOLISM

≈ 1% risk

ADVERSE EFFECTS

- vary according to anatomic location of stimulated neuronal structure.

- dysarthria or hypophonia, dysphagia, motor contraction, paresthesias, gaze deviation, visual flashes, nausea, dizziness, sweating, flushes, imbalance, dyskinesias, and termination of effect of levodopa with resultant worsening of akinesia.
- loss of coordination (e.g. inability of swim in otherwise successful DBS therapy).
- stimulation-induced dyskinesias can be good sign of accurate placement and are reversible by decreasing voltage or drug dosage, or both.

BEHAVIOR AND NEUROPSYCHIATRIC COMPLICATIONS

- most frequently observed change is **decline in word fluency**.

- no short-term global cognitive deterioration in *nondemented* patients.
- patients who are **depressed** after surgery are already depressed before it.
  - depression is frequent finding in patient population seeking surgery
  - transient depressive episodes are observed in 17% patients with longer follow-up.
  - reports of suicide are rare (after STN - 1.3% attempted suicide but only 0.2% committed suicide).
- transient **apathy** is observed in 5% of patients and responds to medication in 88%.
  - apathy is part of PD
  - severe apathy can occur as result of postoperative withdrawal of dopaminergic medication, especially in patients addicted to levodopa, and responds to resumption of dopaminergic medication.
- transient postoperative **confusion** reported in 1-36% of patients
  - rare in long term.
  - data suggest that bilateral trauma to caudate nucleus by exploring tracks during microrecording might cause ***postoperative confusion***.

HARDWARE-RELATED POSTOPERATIVE COMPLICATIONS

Table 5: Reported rates of DBS hardware related complications

Study	Patients/ electrodes	Infection per electrode %	Erosion per electrode %	Migration per electrode %	Electrode fracture-malfunction %	Overall adverse events per patient %	Additional procedures %
Levy[4]	141 / 304	7.5	3.3	6.6	6.6	24	na
Kumar[21]	68 / 74	5.4	na	na	5.8	13.2	8.8
Bendok**[9]	649 / na	3.3 – 13.3	1.8	2 – 9.9	5 – 13.3	na	na
Limousin[8]	110 / 135	1.5	0.7	4.5	na	9	8
Benabid[10]	197 / 316	0.9	1.6	na	1.3	7.7	na
Schuurman[16]	34 / 51	2	na	na	na	6	na
Beric[11]	86 / 149	0.7	na	na	2	11.6	9.3
DBS study group[17]	134 / 268	2.7	0.4	3.7	2.2	11.9	na
Koller[12]	49 / 49	2	6.1	2	18	28.5	14.3
Lyons[14]	206 / 275	5.5	na	na	na	65*	na
Joint[24]	39 / 79	0	1.2	0	5 – 10	20	15.8
Kondziolka[13]	66 / 66	10.6	3	1.5	15	27	33.3
Oh[15]	79 / 124	9.7	na	5.1	5.1	25	36.7
Pollak[5]	300 / 515	1.9 (and erosion)		na	1.4	7.3	7.3
Vingerhoets[19]	50 / 100	1	1	na	8	na	na
Present study	144 / 204	4.4	1	0	1.4	9	7

Reported rates of complications in the literature. na = not available, *not clear if it is only hardware related complications, **meta-analysis with eight studies including complications rate

Constantoyannis (2005)

LEAD FRACTURES

5.0% (0.8-13.3% of the leads implanted);

- most commonly reported time frame is 6–24 months.
- most commonly if connector is implanted at mastoid level.
- diagnosis:
  1) X-rays (patient may need to rotate head to increase sensitivity of Xray).
  2) > 2000 Ohm impedance of the electrodes (with current < 7 µAmp).
- treatment: lead replacement.

EROSION

- hardware must not be crossed or overlaid by incisions; it must be placed under periosteum or aponeuroses to prevent **erosion** (risk 1.3%, range 0.4-6.5%)
- in 20% of erosions the system can be salvaged with antibiotic and rotational scalp flap without hardware removal, even in cases where infection is identified.

Surgical Management of Deep Brain Stimulator Scalp Erosion without Hardware Removal. Michael D Staudt, Navid Pourtaheri, Gregory E Lakin, Hooman T Soltanian, Jonathan P Miller. Stereotactic and Functional Neurosurgery 2017 December 13, 95 (6): 385-391

"BOWSTRINGING" OR "WIRE TETHERING"

- - the prominence of an unsightly long tense subcutaneous cord as it passes through the lower neck and over the clavicle to the generator; risk factors – dual extensions on the same side, cervical dystonia, infection; prevention – divergent technique, aiming towards sternal notch; treatment – transection of scar tissue at least in 5 places with extensions in situ.

LEAD MIGRATION

- 5.1% (4.4% of the leads implanted).
- most commonly detected between 6 months and 3 years after surgery as loss of clinical efficacy; diagnosis confirmed with imaging.

FOREIGN BODY REACTION

- manifesting as inflammation and local pain around the operative site
- reported in 1-1.6% / electrode; removal of the DBS equipment was necessary in almost all patients; in the past, the use of cyanoacrylate glue to fix the electrode to the burr hole ring may have been partly responsible for the formation of granulomas

OUTCOMES

TREMOR

- DBS for tremor: 75-80% reduction in 80% patients.
- tremor control remains improved but lessens over time.

TABLE 4: Long-term results of VIM DBS for ET in the literature

Authors & Year	N	f/u (mos)	% Improvement
Koller et al., 2001	25	40	78.5 (overall tremor)
Rehncrona et al., 2003	13	78	47.1 (overall tremor)
Kumar et al., 2003	5/4	12/60	68/62 (arm tremor)
Sydow et al., 2003	19	78	40.0 (overall tremor)
Putzke et al., 2004	52	20	87.0 (UE tremor)
Pahwa et al., 2006	22	60	75 (UE tremor)
Lee et al., 2005	8/11	27/51	75.8/78.8 (tremor)
Blomstedt et al., 2007	19	13/86	82.4/60.3 (UE tremor)
Pilitsis et al., 2008	26	40	75.3 (tremor)
Zhang et al., 2010	34	57	80.4 (tremor)

Zhang K et al. "Long-term results of thalamic deep brain stimulation for essential tremor". J Neurosurg (2010 Jun) 112(6):1271-6

TABLE 1: Fahn-Tolosa-Marin TRS and PDQ-39 QOL scores before and after unilateral thalamic DBS surgery*

Factor	1-Yr FU		2- to 7-Yr FU		>7- to 12-Yr FU	
	Preop Score	FU Score	Preop Score	FU Score	Preop Score	FU Score
no. of patients	78	78	42	42	22	22
TRS						
total score	56.8 ± 12.7	25.5 ± 9.9†	55.8 ± 12.7	31.1 ± 11.7†	52.9 ± 12.0	36.4 ± 12.0†
targeted tremor	6.0 ± 1.7	0.9 ± 1.0†	5.9 ± 1.6	1.7 ± 1.5†	5.9 ± 1.6	1.9 ± 1.9†
ADL	17.4 ± 3.4	4.7 ± 4.0†	17.6 ± 3.7	8.4 ± 5.1†	16.8 ± 4.0	10.6 ± 5.8†
PDQ-39‡						
mobility	24.7 ± 21.0	21.0 ± 25.4	27.0 ± 23.4	27.0 ± 26.0	20.0 ± 23.3	35.2 ± 27.9§
ADL	52.5 ± 15.0	25.3 ± 23.9†	56.4 ± 19.0	33.4 ± 20.5†	51.3 ± 19.0	43.7 ± 23.5
stigma	43.3 ± 28.8	17.3 ± 20.7†	55.2 ± 31.1	22.6 ± 24.6†	48.3 ± 31.5	29.3 ± 26.9§
communication	18.6 ± 21.7	15.1 ± 19.1	22.2 ± 21.9	18.7 ± 24.7	25.4 ± 26.7	29.5 ± 27.2
total score	28.1 ± 12.4	18.2 ± 15.0†	32.1 ± 14.8	21.8 ± 14.5†	28.6 ± 15.9	29.4 ± 19.6

Jules M. Nazzaro et al. "Long-term benefits in quality of life after unilateral thalamic deep brain stimulation for essential tremor" J Neurosurg 117:156–161, 2012

DYSTONIA

After 3 months of follow-up:

	Stimulation group	Sham group	Statistical significance
Improvement in motor scores	39.3%	4.9%	$p < 0.001$
Improvement in disability scores	37.5%	8.3%	$p < 0.001$
Percentage of patients with a positive response to treatment (>25% improvement in motor score)	75%	15%	$p < 0.001$
Improvement in physical component of SF-36	29.8%	3.8%	$p = 0.02$

Kupsch A et al; Deep-Brain Stimulation for Dystonia Study Group. Pallidal deep-brain stimulation in primary generalized or segmental dystonia. N Engl J Med 2006; 355: 1978 – 1990.

Disease stabilization of DYT1-positive primary generalized dystonia with DBS of the GPi: A 15-yr follow-up:

Derrick A. Dupre et al. Disease Stabilization of DYT1-Positive Primary Generalized Dystonia With Deep Brain Stimulation of the Globus Pallidus Interna: A 15-yr Follow-up. Operative Neurosurgery, opx137, https://doi.org/10.1093/ons/opx137 Published: 06 June 2017.

- case report suggesting that stimulation is efficacious and can potentially prevent disease progression - reaffirms previous reports that recommend early surgical intervention before the onset of permanent musculoskeletal deficits.

FUTURE PERSPECTIVES

IMPROVEMENTS

New Hardware

Hardware is currently at first generation and far from being optimal. There is an urgent need for miniaturized stimulators to be implanted on head. Rechargeable batteries are being developed to decrease need for replacement and reduce cost.
New electrode designs that allow better targeting are being expected from development of nanotechnology.

New Paradigms

There is no reason that current waveform might be best one. New waveforms and paradigms of stimulation must be tested.

Additional Targets

The lower morbidity associated with HFS of brain structures has allowed investigation of effects of its application to targets suggested by results of basic research. This was case of STN for PD, for the accumbens nucleus for psychosurgery, for posterior hypothalamus for cluster headaches, and for the PPN for freezing of gait.[55,176,195] The preliminary results tend to support basic science assumptions. Improvement in gait dysfunction and postural instability has been reported in both “on” and “off “ medication states.[57,58,196] The effects on gait improve benefits obtained by STN-DBS but cannot replace them. The exact anatomic structure to be stimulated is still debated,[197],[198] and determination of target might benefit from new imaging procedures.

ALTERNATIVES

Levodopa without Dyskinesias

Levodopa remains miracle drug during honeymoon of its use. However, pharmaceutical companies are working intensely on designing dopaminergic agonists that would have beneficial effects of levodopa without its major complication, dyskinesias.

Gene Therapy

There are encouraging but very preliminary data, either experimental, with use of adeno-associated virus glutamic acid decarboxylase (AAV GAD) gene therapy in rats,[201] or clinical, with reports of clinical improvement, as well as PET-based evidence of metabolic improvement, after AAV GAD gene therapy in human STN[202] or after administration of neurturin in human striatum.[203]

Infusion Therapy

Continuous infusion of dopamine agonists such as apomorphine[204] or lisuride[205] produces more stable and regular dopamine concentration in brain and clearly decreases dyskinesias, but it induces local complications such as cutaneous nodules at site of injection on abdominal wall, which restricts the use of this method. In same spirit, another route of continuous administration is being tested. Intraduodenal administration of levodopa (Duodopa) with an intragastric catheter through a duodenogastrostomy has been attempted, and satisfactory results are being reported despite the invasiveness and discomfort of this method.[

Infusion of Growth Factors

Chronic infusion of glial-derived nerve factor into striatum has been performed in several patients, and highly significant improvement was reported.[207-209] Such improvement, however, was not confirmed by an international multicenter double-blind controlled study.[210]

Cortical Stimulation

The results reported thus far for cortical stimulation have been disappointing, depending on indications, [211],[212] although experimental chronic cortical stimulation of motor area in monkeys had demonstrated

encouraging data.[213]

Grafting Methods (e.g., Mesencephalic Fetal Cells, Stem Cells, Retinal Epithelial Pigmented Cells, Encapsulated Cells)

For several decades, an impressive amount of work in basic science and in animal models has been performed in highly expert laboratories around world, as well as several transfers of method to parkinsonian patients in controlled trials of grafting. Various types of cells have been used (adrenal gland, mesencephalic fetal grafts, and more recently, epithelial retinal cells). Stem cells are also being investigated as potential material that would be much more immunologically tolerated, but it raises its own (oncologic) problems. This approach is ultimately most elegant but is still experimental and cannot be part of a therapeutic panel.[214]

Special mention must be made about teams involved in this approach, particularly Swedish team led by Anders Björklund. This team has performed astounding work by combining excellent scientific ideas and skills, rigorous evaluation of their results, and careful, ethically based report of current status of their research. This is an outstanding level of scientific and medical professionalism, and their merits should be acknowledged.