

Lumbar Puncture (s. Spinal Tap)

Updated: October 23, 2009

INDICATIONS	1
CONTRAINDICATIONS	1
STUDIES BEFORE LP	1
PROCEDURE DETAILS	1
ANATOMY	1
EQUIPMENT	2
PATIENT POSITIONING	2
TECHNIQUE	2
OPENING PRESSURE	3
CSF COLLECTION	4
PROCEDURE END	4
POSTPROCEDURE	4
COMPLICATIONS	4

When possible, CT is advised prior to lumbar puncture!

INDICATIONS

- CSF collection for **analysis**:
 - infection** (meningitis, meningoencephalitis)* – absolute indication overriding any other considerations!
 - *exceptions – brain abscess, parameningeal process
 - examples: neonatal sepsis (25% will have meningitis, infection with no apparent source)
 - subarachnoid hemorrhage** (CT-negative cases)
 - carcinomatous meningitis
 - inflammatory diseases (esp. Guillain-Barré syndrome, vasculitis, multiple sclerosis)
 - LP is no longer important in diagnosis of intracranial mass lesions (replaced by CT & MRI!)
- Opening pressure** measurement (but correlation with ICP is not always good) - **pseudotumor cerebri** diagnosis.
- Therapeutic CSF drainage**.
- Intrathecal administration** of **medications** (e.g. for meningeal malignancies, fungal meningitis), **contrast** (e.g. for myelography), **radioisotopes** (e.g. for CSF leak).
- Preliminary step for **spinal drain insertion**.

CONTRAINDICATIONS

- INTRACRANIAL MASS** (known or suspected)

PAPILLEDEMA (ICP) should not be used as sole criteria to determine if LP is safe

 - **papilledema absence** does not ensure normal ICP (papilledema takes 6-24 hours to develop).
 - **papilledema presence** (ICP↑) is not absolute contraindication to LP, because ICP↑ may be due to diffuse process, not mass lesion (e.g. pseudotumor cerebri) – **do CT before LP!**

N.B. **absolute contraindication is HEAD TRAUMA** (LP adds no pertinent information + LP is potentially lethal in case of intracranial hematoma)!

POSTERIOR FOSSA MASS is strong contraindication to lumbar puncture!
- NONCOMMUNICATING (s. OBSTRUCTIVE) hydrocephalus** (H: direct ventricular drainage of CSF); vs. in communicating hydrocephalus - LP may provide symptomatic relief.
- INFECTION** in LP region
- COAGULOPATHY** (risks of epidural hematoma or SAH)
 - platelet count should be > 20,000-50,000 (H: platelet transfusion).
 - PT / aPTT should be hemostatic.
 - patient should not be on HEPARIN or WARFARIN (H: protamine or vit. K + fresh frozen plasma).
 - ASPIRIN should be discontinued for 48 hours before LP.
- TETHERED spinal cord**
- COMPLETE spinal block** (relative contraindication) – most commonly due to spinal tumor – LP may cause shifts of nervous tissue.

Spinal tumor is relative contraindication to LP! (except suspected *leptomeningeal metastases* – CSF cytology is key diagnostic test)

Suspected meningitis overrides any contraindications - CSF examination is always indicated (imaging before LP is advisable); if pressure > 350 mmH₂O:

- use 24G needle.
- minimum required sample is obtained
- administer IV bolus of MANNITOL 1 g/kg (ideally 20 min before LP)
- DEXAMETHASONE (unless contraindicated).

STUDIES before LP

- Funduscopy** for papilledema (if present → **CT**)
- Blood studies**:
 - thrombocyte count, coagulation studies
 - glucose (to compare with CSF glucose)

PROCEDURE DETAILS

ANATOMY

Why lumbar spine:

- spinal column grows faster than spinal cord – **spinal cord (conus medullaris)** ends at L₁₋₂ disc, **thecal sac** ends at S₂ – needle displaces freely floating roots of cauda equina.
- horizontal **processus spinosi**, in addition patient flexes lumbar spine.

Puncture at L₃₋₄ or L₄₋₅ or L₅-S₁ interspace

Puncture above L₃ is absolutely contraindicated – in 1% people (esp. short) spinal cord ends at L₂₋₃ interspace!

- line between iliac crests** (INTERCRISTAL LINE) goes through L₃₋₄ or L₄₋₅ interspace.
- repeated taps are done at higher interspace.
- midline is avascular!

Structures that must be pierced:

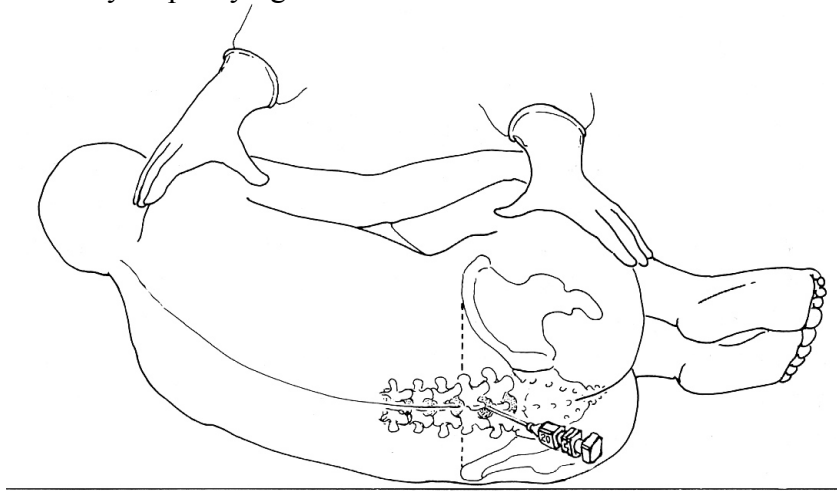1. **Three ligaments** (*supraspinal, interspinal, flavum**)
*lig. flavum is absent at midline? – not pierced during LP
2. **Dura mater**

EQUIPMENT

1. **Standard LP kit:**
 - 1) prep swab sticks, sterile (fenestrated) drapes
 - 2) 1% **LIDOCAINE** (20-50 ml) or 2% **PROCAINE**
 - 3) 10 ml syringe
 - 4) needles (25 and 22G)
 - 5) **spinal needle with stylet:**
 - 20G 3.5-in. – for adults;
 - 22G 2.5-in – for children;
 - 25G 1.5-in. – for infants.
 - 6) 60 cm **manometer** with 3-way stopcock
 - 7) numbered sterile centrifuge **tubes** with caps (minimum three; better four)
 - 8) gauze and Band-Aid.
2. Sterile **prep solution**
3. Sterile **gloves** (\pm cap, mask)

PATIENT POSITIONING

- LEFT LATERAL DECUBITUS FETAL position** (neck & knees brought to chest; craniospinal axis parallel to floor; posterior aspect of pelvis at edge of table and perpendicular to floor; pillow under neck for comfort) - this flexes lumbar spine and opens spaces between spinous processes; assistant helps maintain patient as flexed as possible.
 - avoid prolonged severe neck flexion in infant \rightarrow airway obstruction; airway should be checked if infant suddenly stops crying.



- SITTING with legs dangling** over bed side (head and arms rest on grasped pillow; patient leans forward as far as possible).
 - indications:
 - 1) obesity
 - 2) difficult anatomy (incl. scoliosis)
 - 3) large volumes of CSF are to be collected.
 - advantages:
 - 1) midline is much easier to determine
 - 2) more comfortable (than fetal position) for some patients
 - 3) gravity assists CSF flow.

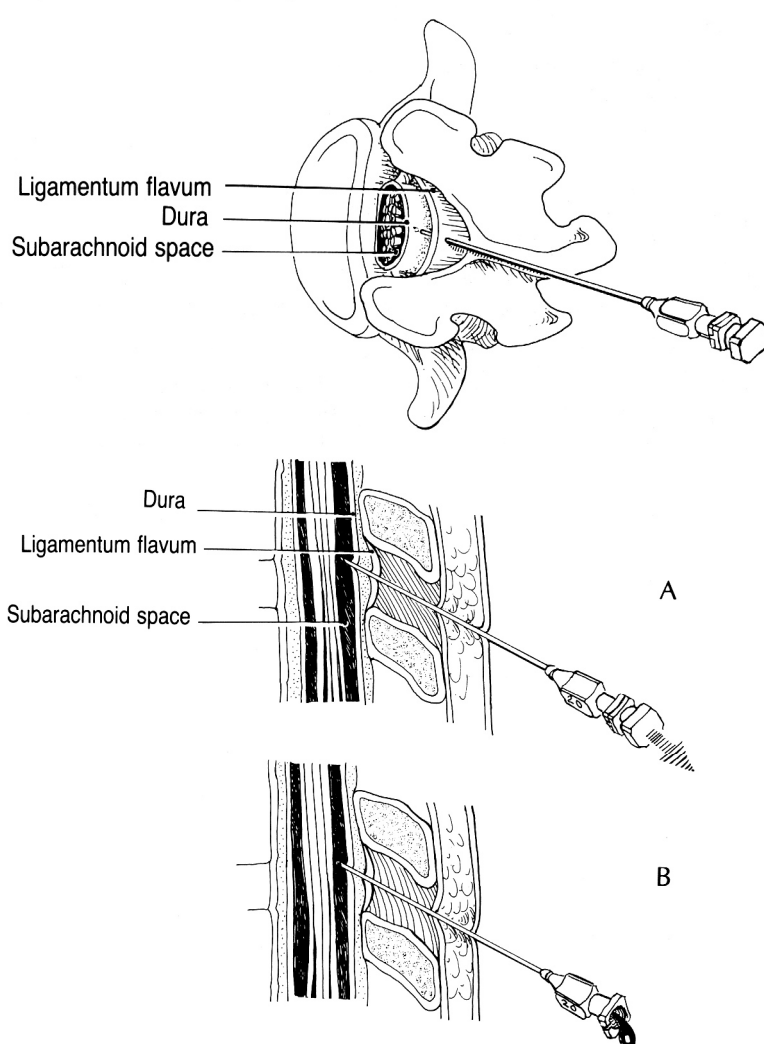
If severe anatomical restrictions preclude LP (e.g. severe spondylosis, previous spinal surgery, morbid obesity) \rightarrow obtain CSF under **fluoroscopic guidance**:

- a) **lumbar** puncture
- b) **cisternal** puncture see p. Op5 >>
- c) **lateral cervical** puncture see p. Op5 >>

TECHNIQUE

- first developed by Quincke in 1891.
- **sterile prep** (antiseptic solution is applied in circular motion - circumference of cleansed area should increase with each motion).
- **sterile towel** is placed between patient's hip and bed; drape lumbar back (drapes extend over iliac crests).
- identify **INTERCRISTAL LINE** and palpate in midline for spinous process (usually **L₄**) and L₄₋₅ interspace below it; mark puncture site by thumbnail indentation to skin.
- **anesthesia** (\approx 1 cm below spinous process) - 1% **LIDOCAINE**: **SC** (25G needle) \rightarrow into **lumbodorsal fascia, interspinous ligament** (22G needle).
 - some operators also apply local anesthesia in vertically fanning distribution on both sides of spinous processes near lamina (FIELD BLOCK for recurrent spinal nerves that innervate interspinous ligaments and muscles).
 - *as anesthetic is taking effect*, assemble manometer with stopcock and set up CSF collection tubes so they are easily accessible.
- **puncture anesthetized skin with spinal needle & stylet**
 - needle is always advanced with **stylet in place** (to avoid introducing epidermal cells \rightarrow iatrogenic epidermoid tumor).
 - needle is held between both thumbs and index fingers.
 - needle is aimed **slightly rostrally** (\approx 15°, with **umbilicus as target**) - path approximately parallel to spinous processes.
 - **needle bevel is turned parallel to length of spinal column** i.e. parallel to longitudinally running fibers of dura* (to minimize post-LP headaches); once in thecal sac, needle is **turned cranially** (to optimize CSF flow).
*e.g. in sitting position, needle is inserted with bevel facing laterally; in decubitus position - bevel facing up.
- **advance needle deeper**, carefully maintaining midline trajectory; needle will encounter slight resistance, then "pop" will be felt (thecal sac penetration – patient experiences twinge of pain*).
*must be felt strictly in midline posteriorly
- **if bone is encountered**, it is more often due to **deviation from midline** than to failure to aim correctly in rostral-caudal direction; needle direction cannot be changed - pull needle back to just beneath skin and redirect it:
 - a) if bone is struck at **shallow depth**, redirect needle more cephalad;
 - b) if at **deeper depth** – more caudally.
- **withdraw stylet** - check for CSF flow; allow patient to relax (to extend hips and knees).
 - **if no CSF is seen**, reinsert stylet and advance needle little farther;
 - **if still no CSF is seen**, withdraw needle to just below skin surface, reassess landmarks, and attempt another trajectory;
 - failure to enter subarachnoid space after 2-3 trials \rightarrow reposition patient to sitting position;

- **if blood is seen**, allow moment for blood to drain and see if it clears, because blood may represent traumatic tap; if it does not clear, withdraw needle and attempt another trajectory.



Source of picture: Paul W. Roberts "Useful Procedures in Medical Practice" (1986); Lea & Febiger; ISBN-13: 978-0812109856 >>

Causes of "dry tap":

- improperly placed needle** (most often)
- pathologic **obliteration of subarachnoid space** (compressive lesion of spinal cord or chronic adhesive arachnoiditis)

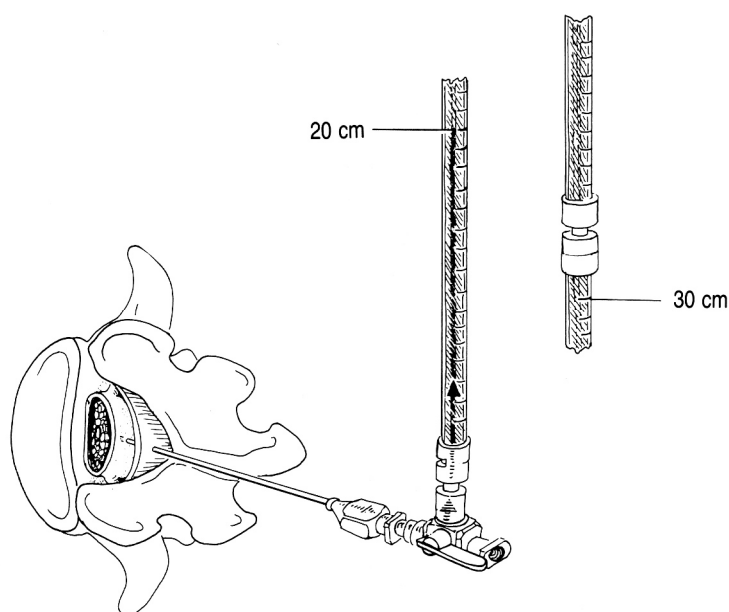
LATERAL APPROACH

- used if supraspinal ligament is calcified in older persons.
- needle is directed **slightly cephalad** to miss lamina (lower lamina rises upward from midline) and **slightly medially** to compensate for lateral approach.
- needle bypasses supraspinal and interspinal ligaments.

OPENING PRESSURE

about causes of elevated / lowered opening pressure → see p. D40 >>

- **once CSF flow is established** (lose as little CSF as possible – this spuriously lowers pressure), place stopcock and attached manometer on end of needle.
- keep "zero" mark at level of spinal needle.
- adjust stopcock to allow CSF to flow up manometer – wait for steady state – record **OPENING PRESSURE**.
 - **intermediate tubing** may be used to minimize movement of needle while manipulating manometer and collecting CSF.
 - patient should be lying down fully relaxed (not in forced fetal position)!!!
- look for normal pressure oscillations with pulse and respirations.



Source of picture: Paul W. Roberts "Useful Procedures in Medical Practice" (1986); Lea & Febiger; ISBN-13: 978-0812109856 >>

Norma: 65-200 mmH₂O* (5-15 mmHg) with patient lying down (or at level of foramen magnum in **sitting** position).
 *50 mmH₂O in neonates, 85 mmH₂O in young children, 250 mmH₂O in extremely obese subjects

Opening pressure is artificially elevated with patient in sitting position!

- opening pressure of 500 mmH₂O is normal for sitting position.
- if **anatomy precludes LP in lateral decubitus** but **opening pressure is critical**: spinal needle inserted in sitting position → needle withdrawn just out of thecal sac → patient placed in relaxed, lateral decubitus position → needle readvanced slightly into thecal sac.

If pressure is very high (esp. > 350 mmH₂O) – remove needle at once! (fluid in manometer is used for analysis!); although change in intracranial dynamics caused by LP has occurred already and premature needle removal changes nothing.

QUECKENSTEDT test (seldom performed today – replaced by myelography and MRI) - demonstrates **SPINAL BLOCK** (spinal subarachnoid space does not communicate with cranial subarachnoid space):

- patient in lateral recumbent position.
- **10-12 seconds of bilateral internal jugular vein compression** (by assistant) → decreased venous return to heart → distended cerebral veins → ICP rise → **CSF pressure**↑:
 - **NORMA:** **CSF pressure rises** 150 mmH₂O (or ≥ twice) over initial reading; **CSF pressure returns** to baseline in 10-12 seconds after **release**.
 - **SPINAL BLOCK:** **delayed** rise and fall (incomplete block) **or no change** (complete block) in CSF pressure at all.

N.B. inject Pantopaque before needle removal - to facilitate subsequent myelogram (because lumbar dural sac may collapse, making it impossible to reenter canal).

- **contraindications:** elevated opening pressure, suspected intracranial mass lesion.
- **modifications:**
 - a) suspected *cervical cord disease* - test repeated with neck in *neutral* position, *hyperextended*, and *flexed*.
 - b) suspected *lateral sinus obstruction* - *unilateral* jugular venous compression (**TOBEY-AYER test**).

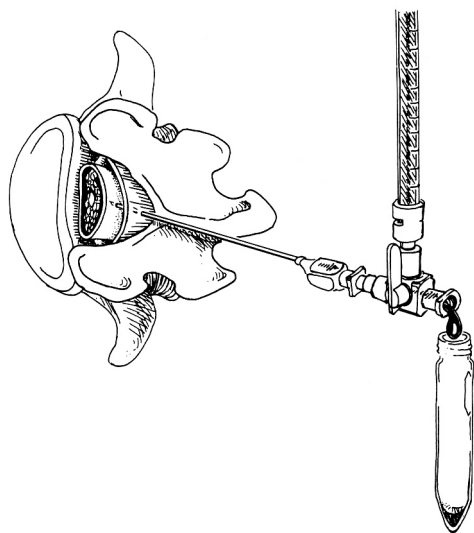
CSF COLLECTION

Collect four tubes (extra tubes may be required for additional studies if indicated, e.g. cytology) – 5 ml each:

- 1) **cell count**
- 2) **chemistries** (glucose & protein)
- 3) **bacteriologic studies** (Gram stain, culture, a/b sensitivities)
- 4) for **future use** (e.g. sample may be lost, unexpected chemistry value may require repeat determination, or new test may be wanted).

N.B. if **CSF is bloody**, cells are counted in both 1st and 4th (clearest) tubes. see p. D40 >>

- remove only **minimum volume of CSF needed** for diagnostic studies (e.g. in aneurysmal SAH, excessive CSF pressure lowering increases transmural pressure across aneurysm wall → rebleed).
 - 10-12 ml may be withdrawn from adult (3-5 ml from neonate);
 - identification of tumor cells, TB, some fungi depends on large CSF volume examined or cultured (as much as 30-50 cc of CSF from serial lumbar punctures may be required).
- if **CSF flow ceases** (nerve root abutted against needle aperture), rotate needle 180°.
- if **CSF pressure is too low** for collection → elevate patient's head, ask assistant to press on abdomen.



Source of picture: Paul W. Roberts "Useful Procedures in Medical Practice" (1986); Lea & Febiger; ISBN-13: 978-0812109856 >>

PROCEDURE END

- **reattach manometer** to record **CLOSING PRESSURE** if indicated (e.g. therapeutic LP for increased ICP).
- **replace stylet** and **withdraw needle**.
- **massage** puncture region for a moment to break up needle tract.
- small sterile **dressing** or adhesive on puncture site.
- routinely **observe** for cord / spinal nerve compression from developing hematoma after traumatic taps.

POSTPROCEDURE

Prone bed rest for 6-24 hrs, **hydration** – see post-LP headache prevention! *see below* >>

COMPLICATIONS

1. **Post-LP headache** (5-35%; risk is greater in young females) – due to CSF leakage through dural puncture site.
 - **onset** 15 minutes ÷ 4 days following LP.
 - usually **lasts** only few hours (untreated can last for 14 days). *see p. S58* >>
 - **prevention:**
 - 1) use **smaller-gauge** spinal needles (20 or 22G; 25G for small children).
 - 2) use **atraumatic** needle (vs. cutting type).
 - 3) orient needle **bevel** parallel to longitudinally running dura fibers.
 - 4) **avoid multiple** punctures.
 - 5) **remove as little** CSF as possible.
 - 6) turn patient **prone** (if LP is done in sitting position) before removing needle.
 - 7) **bed rest (better prone than supine) after procedure** for 6-24 hrs (no studies support usefulness of this!!!).
 - 8) post-lumbar puncture **hydration**.
 - **treatment** - autologous epidural **blood patch**.
2. **Herniation** (1.2-3%) – TRANSTENTORIAL or CEREBELLAR TONSILLAR: *see p. S54* >>
 - **withdraw needle immediately** → elevate head of bed → intubate & hyperventilate → mannitol, steroids.
 - most important **risk factor** - **signs of mass effect** (hemiparesis and anisocoria).
3. **Nerve-root injury** - sudden onset pain radiating down.
 - **withdraw needle immediately** → if pain persists → start short course of DEXAMETHASONE.
4. **Spinal epidural / subdural hematoma** (usually only with coagulopathy)
 - **heparin therapy** should not commence for at least 1 hour after bloody tap!
5. **Epidermoid tumor** - pain in back and lower extremities developing years after LP.
6. **Spinal meningitis** - leakage of blood containing bacteria into subarachnoid space. Suspected bacteremia is not contraindication for LP!
7. Intracranial **subdural hygroma** or **hematoma** (extremely rare)

BIBLIOGRAPHY for ch. "CSF sampling, Spinal-Epidural Anesthesia" → follow this [LINK >>](#)

Viktor's NotesSM for the Neurosurgery Resident
Please visit website at www.NeurosurgeryResident.net