Scoliosis

Last updated: April 22, 2019

PSO – pedicle subtraction osteotomy

Further reading - Canale 'Campbell's Operative Orthopaedics' 10th ed. (2002)

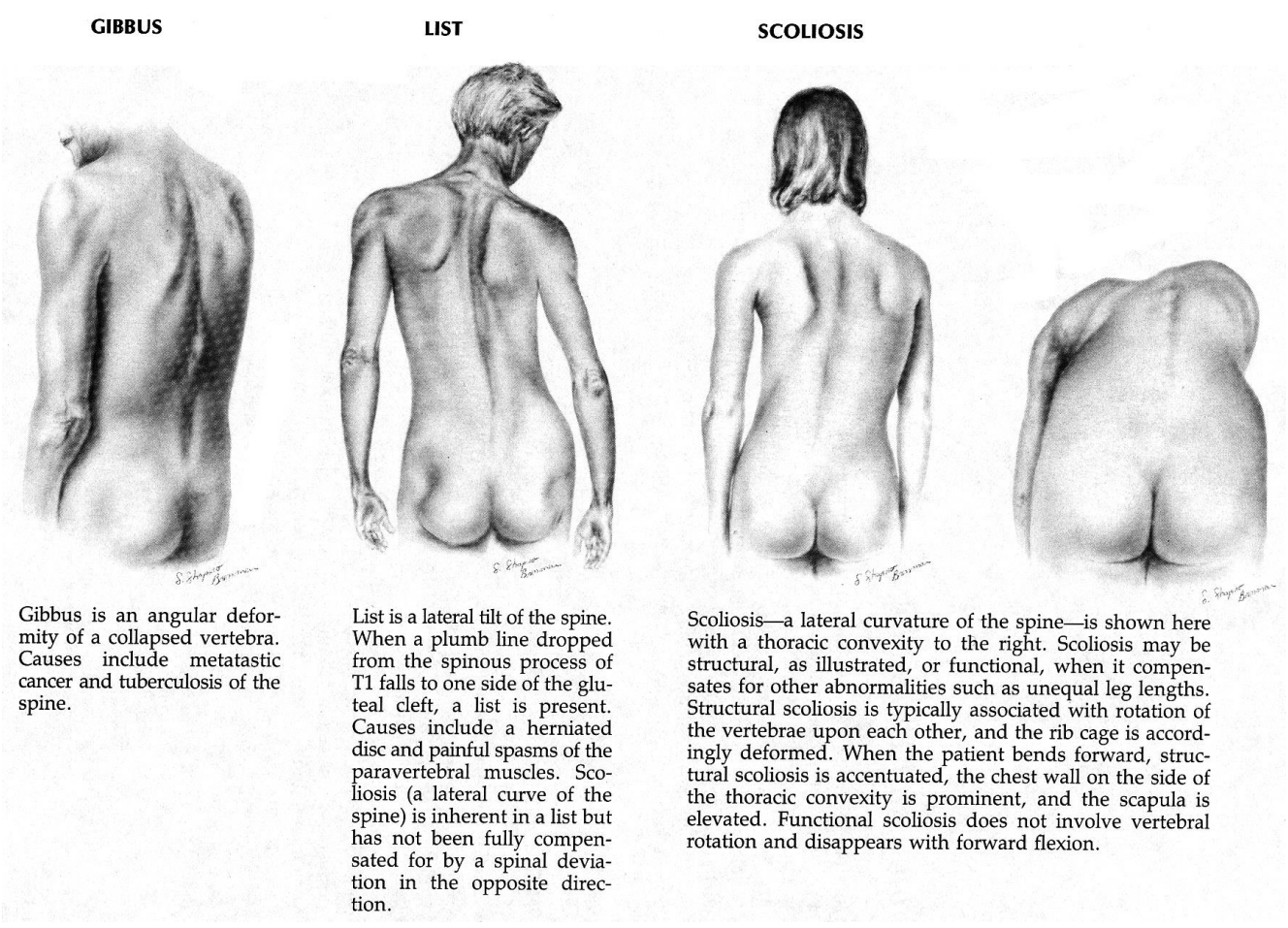

XRAY IN SCOLIOSIS

LEVOSCOLIOSIS is when spine curve apex is to the left, therefore spine is bending to the right.

- common in lumbar spine (L&L).
- rare occurrence in thoracic spine indicates higher probability that scoliosis may be secondary to a spinal cord tumor - order an MRI.

DEXTROSCOLIOSIS usually occurs in thoracic spine.

STATIC plain radiographs

Stagnara's *plan d'election* (s. oblique Stagnara) - view perpendicular to true coronal plane of apical vertebra - in setting of significant rotational deformities
Leeds lateral - true lateral at 90° to *plan d'election*.

- in lateral films look for sagittal imbalance – **dens of C2** should be in vertical line with **sacral promontory** (if not, describe how many cm shift is).

36-INCH STANDING SCOLIOSIS radiographs

- knees and hips must be fully extended
- should include iliac crests (to assess Risser status – bone maturation).

*instead of AP (to reduce radiation dose to breast tissue).

DYNAMIC plain radiographs

- lateral bending and flexion-extension radiographs:

1) **curve flexibility** – primary (pathologic) curves do not correct, secondary (compensatory) curves straighten
2) **instability**

Cobb angle - angle made by intersection of two lines parallel to most cranial and caudal endplate of respective end vertebrae of curve:

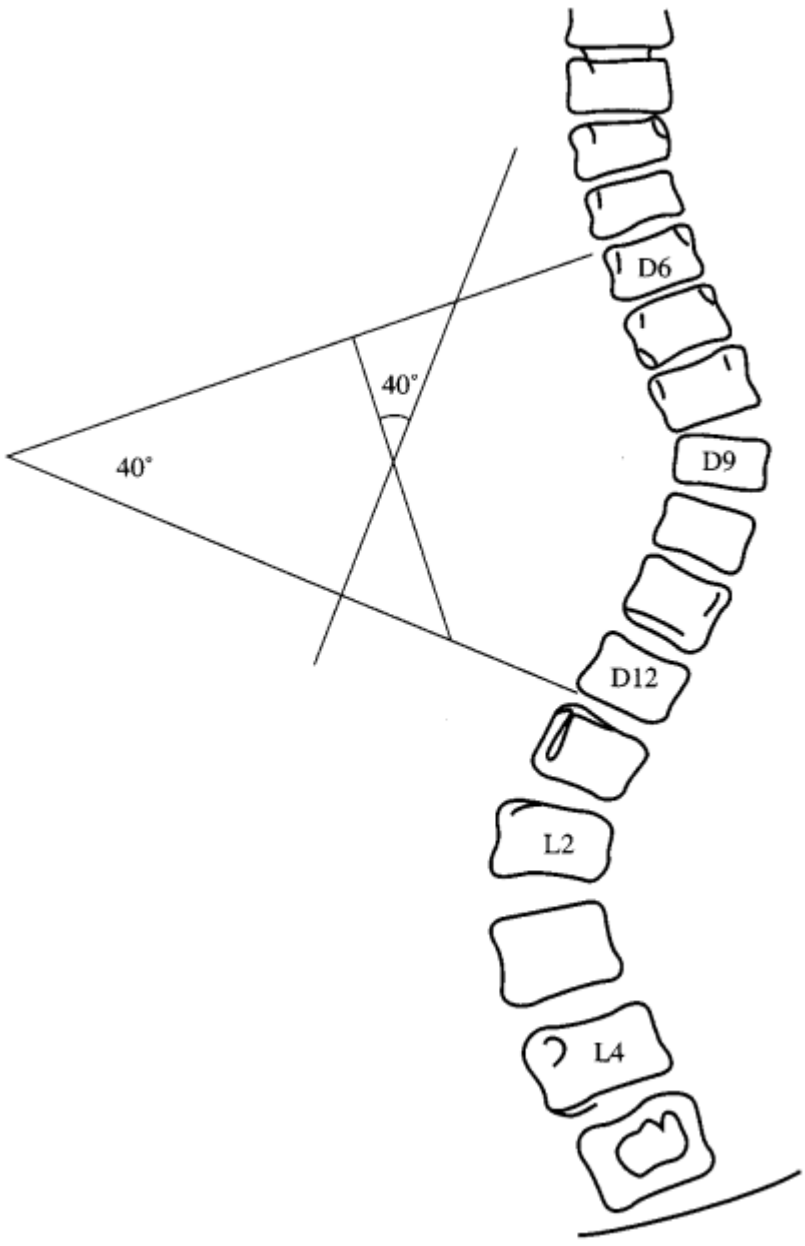

- scoliosis = Cobb angle > 10°; angle < 10° - spinal asymmetry.
- example: 60° thoracic curve convex to right with apex at T8.

ADOLESCENT SCOLIOSIS

Paauglius tirk dėl skoliozės, liepk pasilenkti į priekį:
- stebėk stuburo rotaciją ir kr. ląstos deformaciją (**RIB HUMP** - toje pusėje, į kurią iškrypęs stuburas);
- *sužymėk flomasteriu processus spinosi*; kai ligonis atsities, žiūrėk ar taškai vienoje linijoje.

SCOLIOSIS – structural lateral curvature of spine

EPIDEMIOLOGY
- serga ≈ 3% adolescents
- 80% sudaro mergaitės

ETIOLOGIJA
1. Idiopathic – dažniausiai (>75%)
2. Secondary : neuromuscular paralysis, painful lesions, musculodystrophies, cong. anomalies*, radiation, thoracic surgery, Marfan syndr., neurofibromatosis, spinal trauma, skiriningas kojų ilgis

*e.g. VACTERLS

KLINIKA
- dažn. thoracic with convexity to right – dež. petys stovi aukščiau
- dažnai diagnozuojama tik sveikatos patikrinimo metu:
  1) nevienodame aukštyje pečiai, kartais lips
  2) nelygiai krenta žiūrai
  3) pasilenkus į priekį, išryškėja stuburo rotacija (visada kyla skoliozę!) – kaip rib hump ← toje pusėje, kur yra convex

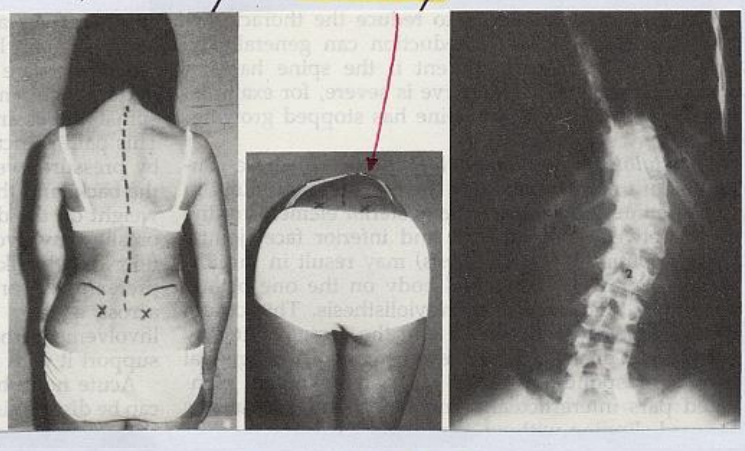

Figure 23–12 Scoliosis. The spine rotates as it curves, with the spinous processes moving toward the concavity. The severe curve of 46° seen by roentgenogram on the right is only partly recognizable when the patient stands upright. However, examination with the child's spine flexed shows the rotation on the right that indicates a structural scoliosis.

- kai kurie skundžiasi muscular backache in areas of strain
- nedidelė skoliozė – tik kosmetinė problema
- jei skoliozė >90° – sutrinka kardiopulmoninė f-ja → polycythemia, pulmonary hypertension, cor pulmonale zr. 2161-2162 p. (RESPIRATORY SYSTEM)

DIAGNOSTIKA remiasi spinal X-ray on standing

TREATMENT

GYDYMAS reikalingas < 10% ligonių

N.B. skoliozė ypač greitai progresuoja pubertal growth spurt metu – – gydytojo sekimas kas 3 mėn ;
net ir suaugusiam skoliozė gali lėtai progresuoti !

skoliozė < 20% → mankšta

skoliozė > 20% → braces (e.g. Milwaukee, Boston) – skoliozės nepamaitina, bet sustabdo progresavimą

sunki skoliozė → surgical treatment (e.g. rod fixation with bone grafts) – žmonoms žymi (although never complete !) korekcija
HARRINGTON procedure
• po operacijos kelis mėn. dėvimas gipsas
t.y. focal spinal fusion, panaudojant metal rods ir bone grafts

BRACING

Bracing in Adolescent Idiopathic Scoliosis Trial (BRAIST)

http://www.nejm.org/doi/full/10.1056/NEJMoa1307337?query=featured_home

Bracing in high-risk patients with **adolescent idiopathic scoliosis** (AIS) is associated with a significantly greater likelihood of reaching skeletal maturity with a curve of < 50 degrees (50 is degree at which surgery is normally indicated).

- longer children wore brace, better outcome. Those who had it on at least 13 hours a day had upwards of a 90% chance of avoiding surgery.

ADOLESCENT KYPHOSIS

KYPHOSIS – 95% esti dėl laikysenos netaisyklingumo (nuo structural causes diferencijuoja X-ray) wedge fractures, ankylosing spondylitis
• gyd – mankšta, standūs faldai su patogiais atlošais

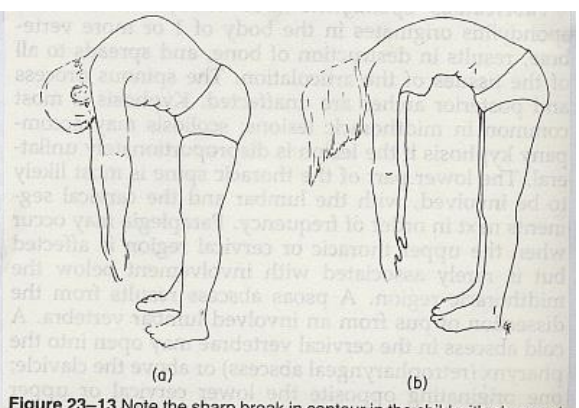

Figure 23–13 Note the sharp break in contour in the child with abnormal kyphosis *(a)* compared with the contour in the normal child *(b)*.

ADULT SCOLIOSIS

- any lateral spine curvature in **skeletally mature** individual with Cobb angle > 10° in coronal plane.

- thoracolumbar levels most often being affected.

CLASSIFICATION

TYPE 1 SCOLIOSIS - PRIMARY DEGENERATIVE (DE NOVO), S. "DISCOGENIC"

- curves develop de novo after skeletal maturity in previously straight spine.

Etiology:
1) iatrogenic
2) vertebral fractures
3) degenerative changes
4) osteoporosis

Pathogenesis - spondylotic process - asymmetrical degeneration of intervertebral disk, asymmetrical facet degeneration/hypertrophy.

- disk degeneration results in coronal deviation with subsequent rotation of vertebral body, which pivots on facet joint.
- apex (in descending order of frequency): L3-4, L2-3, L1-2.
- type 1 curves have less of coronal plane component than type 2 curves; sagittal imbalance predominates (→ back and radicular pain)
- **spinal stenosis** from disk degeneration and facet hypertrophy is more common than in type 2.

Standing 36-inch plain radiographs in type 1 scoliosis: less severe coronal plane malalignment; note lumbar hypolordosis causing significant sagittal plane imbalance.

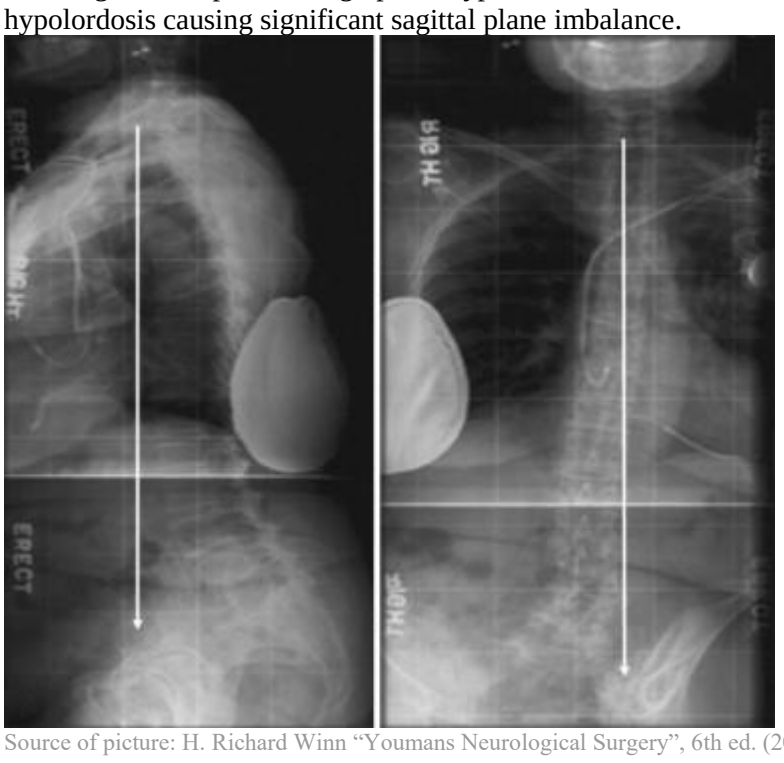

Source of picture: H. Richard Winn "Youmans Neurological Surgery", 6th ed. (2011); Saunders; ISBN-13: 978-1416053163 >>

TYPE 2 (PROGRESSIVE IDIOPATHIC SCOLIOSIS)

- curves that began before skeletal maturity (may have been asymptomatic in children):

1) idiopathic
2) congenital
3) paralytic

- continued curve progression causes symptoms.
- osteoporosis may hasten progression.

Preoperative radiographs of 55-year-old woman with pain from progressive idiopathic scoliosis. Postoperative radiographs show correction of curvature with combination of anterior lumbar cages and posterior spinal fixation from T3 to ileum.

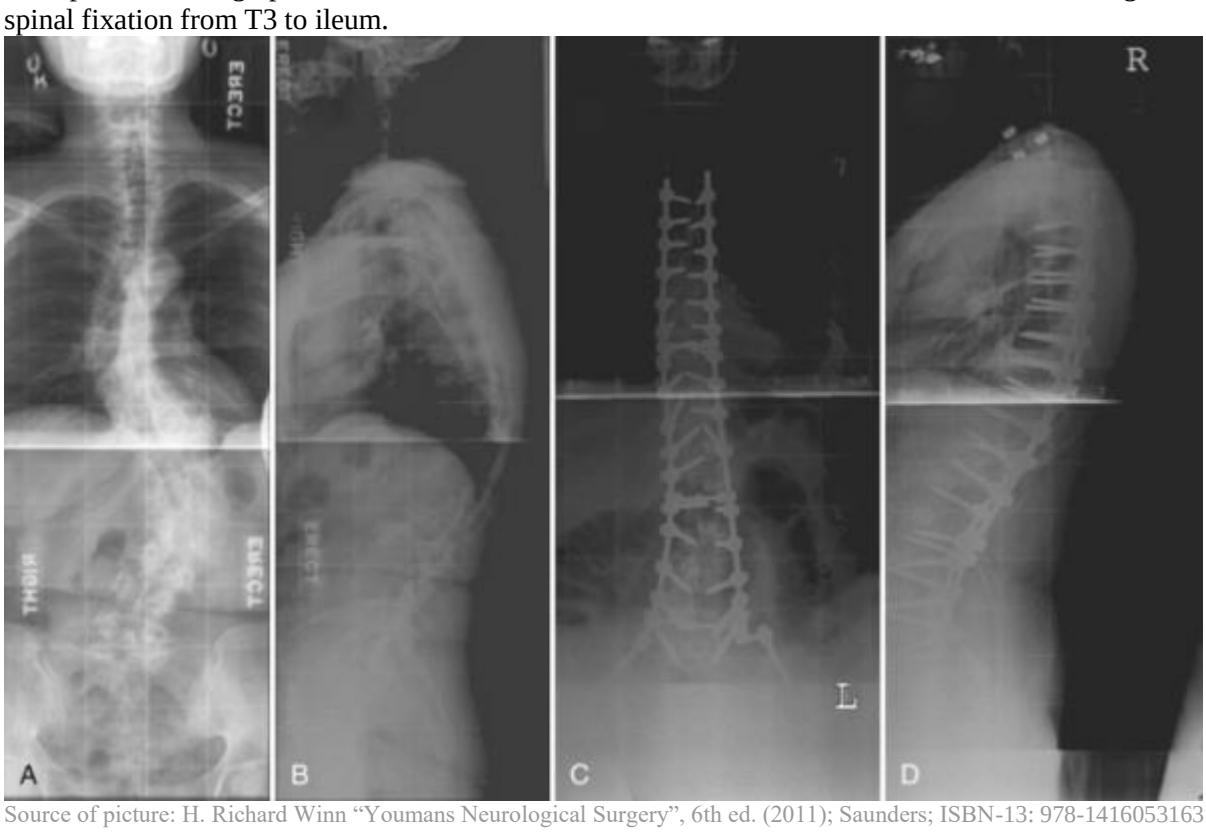

Source of picture: H. Richard Winn "Youmans Neurological Surgery", 6th ed. (2011); Saunders; ISBN-13: 978-1416053163 >>

CLINICAL FEATURES

1. <u>Pain</u>

a) **musculoskeletal pain**
   — most often associated with loss of normal lumbar lordosis
   — occurs at apex of curve or at its concavity (strain and fatigue on paravertebral muscles as they attempt to compensate), and areas above and below curve (excessive stress on facet joints)

b) **radicular pain** (frequent in de novo scoliosis) – 1)from neural foraminal compression as result of disk degeneration and facet hypertrophy (on concave side of curve), 2)traction of nerve roots (on convexity of curve)
   e.g. intercostal neuralgia secondary to rib cage deformity can be seen in patients with severe thoracic and thoracolumbar curves.

- pain is deciding factor for surgical intervention in approximately 85% cases
- pain may be diffuse and constant, or it may occur only with axial loading on standing (and relieved when recumbency)

2. <u>Neurogenic Claudication</u>
- secondary to lumbar stenosis at transition zones

3. <u>Neurological Deficit</u>
- relatively rare in adult scoliosis but can occur after acute insult or decompensation in already severely narrowed spinal canal or neural foramen.

4. <u>Curve Progression</u>
- manifested as changes in clothing size or height or frank alterations in body shape, such as rib hump.

- risk factors for lumbar curve progression: Cobb angle ≥ 30, significant apical rotation, lateral listhesis ≥ 6 mm, intercrest line through or below L4-5 disk space.

5. <u>Cosmesis</u>
- relatively infrequent complaint by adult patients > 40 years.

Loss of sagittal balance is evident (left) whereas coronal balance is relatively preserved (right). Pelvic obliquity is also evident.

Source of picture: H. Richard Winn "Youmans Neurological Surgery", 6th ed. (2011); Saunders; ISBN-13: 978-1416053163 >>

DIAGNOSIS

EXAMINE

1) in **standing** position with knees and hips fully extended – look for spinal curves, rib humps, sagittal and coronal balance, pelvic obliquity, curve flexibility, and any leg length discrepancies.
2) in **sitting** position - assess hip flexibility to rule out hip contracture as cause of sagittal imbalance (improvement in posture after sitting indicates hip flexion contracture).
3) in **supine** position - for improvement in sagittal and coronal alignment.

IMAGINGS

1. **Plain radiographs** see above >>

2. **MRI** - difficult to interpret given that scoliotic spine does not lie in anatomic sagittal or coronal alignment (CT myelography is preferred)

3. **CT myelography**

4. **Provocative diskography**, **facet blocks**, **epidural steroid injections** - to correlate symptoms with radiographic abnormalities, to identify disks and facets that should be included in fusion.

TREATMENT

NONOPERATIVE MANAGEMENT

- aimed at alleviating pain; does not prevent curve progression!

1) exercise (esp. swimming, low-impact aerobics, cycling)
2) NSAIDs, muscle relaxants
3) smoking cessation
4) weight loss
5) external bracing

BRACES

- efficacy in degenerative scoliosis is questionable.

MILWAUKEE brace - full-torso back brace (from pelvis to base of skull), designed by Blount and Schmidt in 1946 for prolonged post-operative immobilization; used to manage scoliosis or kyphosis; may need to wear it 23 hours/day for years

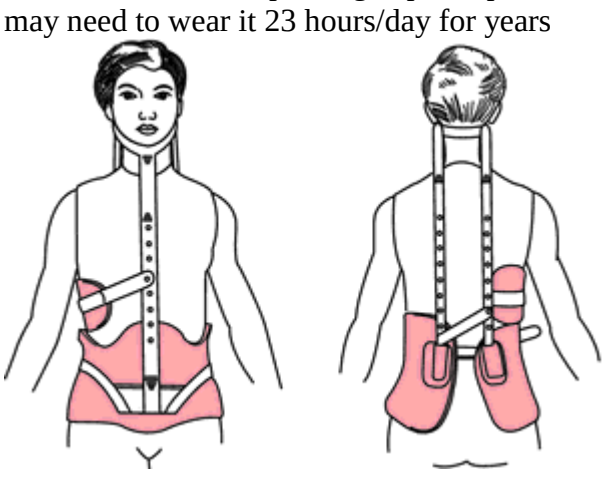

BOSTON brace - developed by Dr. John Hall and Dr. William Miller of The Boston Children's Hospital.

- extends from below breast to beginning of pelvic area in front and just below scapulae to middle of buttocks in back.
- designed to keep lumbar area in flexed position by pushing abdomen in and flattening posterior lumbar contour.

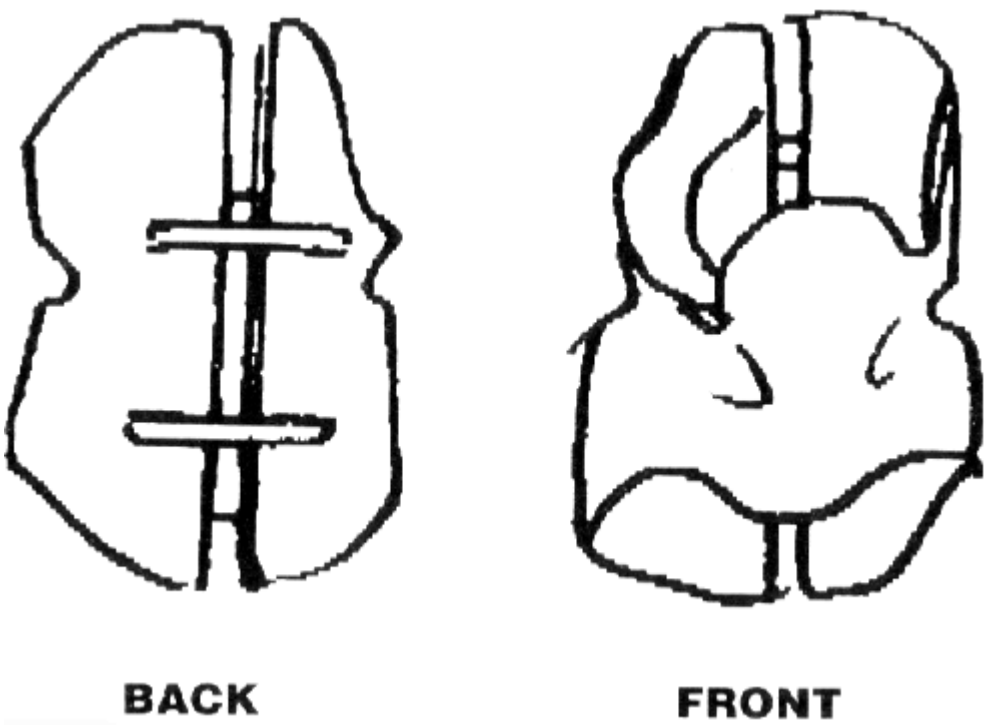

CHARLESTON nighttime bending brace – forces spine to one side and is held in place away from direction of spinal curve.

- designed to only be worn when at night.

- cannot be used in severe cases.

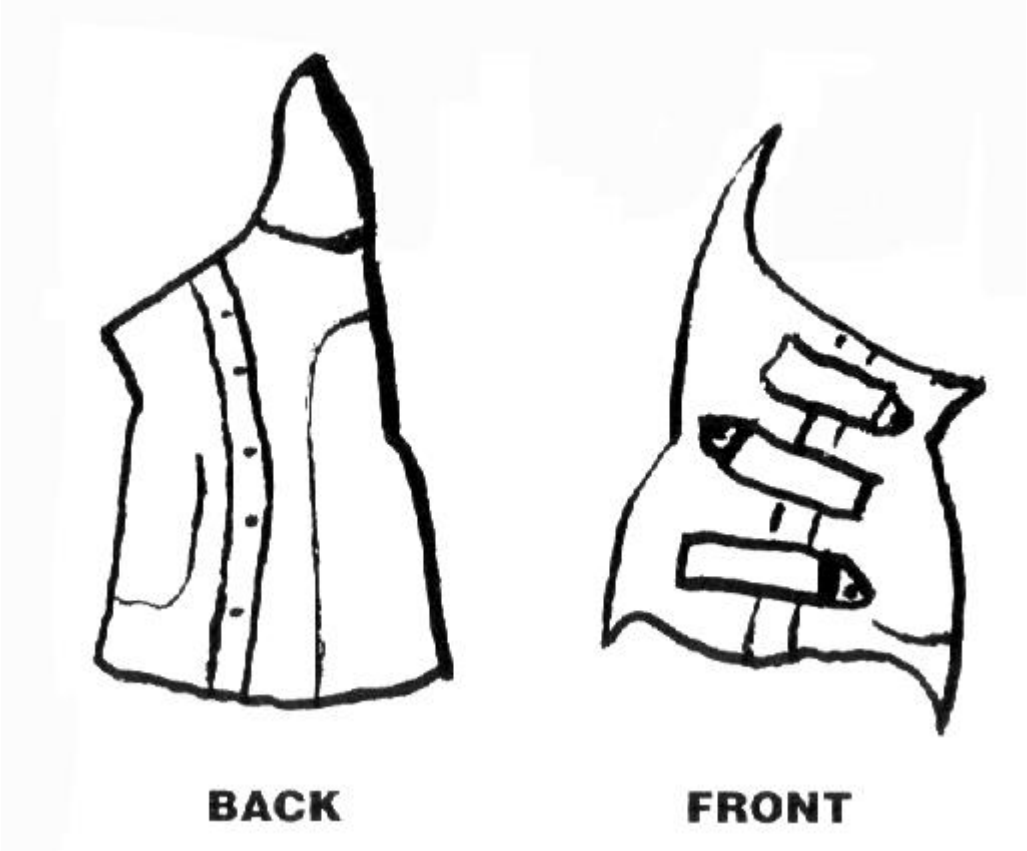

SURGICAL MANAGEMENT

- see below

SPINAL DEFORMITY SURGERY

INDICATIONS

Four general indications
(1) unrelieved **pain**
(2) progressive **deformity** (failure of bracing; Cobb angle > 20° - most likely will progress without surgery)
progressive curves > 50° in adults.
progressive curves > 40–45° in growing children
N.B. in *muscular dystrophy*, pulmonary function begins to decline rapidly when patients become wheelchair users and can quickly reach level where surgery is impossible - surgery is often performed when curves reach only 20–30° but forced vital capacity is still > 40%.
(3) **neurological deficit**
(4) **cosmesis**

AIMS OF SURGERY

- elimination of symptoms and restoration of spinal balance:
1) prevent progression of curve
2) maintain balance (more important than curve correction)
3) maintain respiratory function
4) reduce pain
5) preserve neurological status
6) provide good cosmesis (lowest surgical priority, but most important to patient).

GENERAL PRINCIPLES

1) restoration of lumbar lordosis
2) reestablishment of anatomic sagittal balance (can be accomplished only from posterior approach)
3) avoiding termination of construct at thoracolumbar junction or at apex of thoracic kyphosis
4) all segments involved in curve should be fused
N.B. correct only primary curves (do not touch secondary compensatory curves)
5) areas of significant stenosis should be decompressed during surgical intervention and before correction of deformity.
6) preoperatively look:
   i. **sagittal vertical alignment** (need long XR casette – scoliosis film) – final goal (must be < 5 cm)
   ii. **pelvic tilt** (SVA alone is not enough); normal 13±6° (i.e. goal of surgery is < 20°); larger pelvic tilt (sagittal compensation) – larger PSO needed
   iii. **T1 inclination** (T1-to-femoral head)
   iv. lumbar lordosis must be within 10° of **pelvic incidence**

Surgi Map (http://www.surgimapspine.com/) – surgical planning software (free download).

SURGICAL STRATEGIES

Surgical Strategies for Correction of Scoliotic Deformity in Adults

Approach	Patient age	Curve flexibility*	L5-S1 pathology	Correction of sagittal balance
Anterior only	< 40	Flexible	No	No
Posterior only	≥ 40	Flexible	Yes or no	Yes
Combined	Any	Rigid	Yes or no	Yes

*unlike adolescents, in whom flexible curves are common, adult curves are generally stiff

- procedures are complex and lengthy - physical stress on patient.
- Wilson frame only for L5-S1 fusion (all others – Jackson table; legs must be in extension on Jackson table!)
- patients requiring both *anterior* and *posterior* surgery may have fewer complications if both procedures are performed on same day (vs. separated by 1–2 week interval).
- significant blood loss and fluid shifts – pRBCs, FFP, platelets, and clotting factors should be administered in timely fashion, beginning when blood loss is estimated to approach 1000 mL.
- large volumes of cell-salvaged blood can induce coagulopathy.
- **intraoperative monitoring** (SSEP, MEP*, EMG) should be used in every procedure; pedicle screw stimulation can also be used to assess for proper screw placement.
**motor evoked potentials* are most sensitive for detecting cord injury resulting from correction of deformity.

- any ***rib prominence*** is surgically rectified by **partial thoracoplasty** - ribs involved in prominence are resected and used as bone graft for spinal fusion; periosteum of ribs is preserved to allow ribs to regrow in more acceptable position.
- **instrumentation**:
  a) Luque rods and wires
  b) Cottrel - Dubousset
  c) Harrington metal rods (now rarely used)

  N.B. for instrumentation, **Co-Cr (cobalt-chrome)** is used – stiffer (modulus of elasticity↑) than titanium; in other spinal surgeries **titanium** is used – better MRI compatibility!
- use ***temporary rods*** (one spine side while working on the other side)
- osteotomies can achieve 5-45° lordosis correction (Smith-Peterson – up to 10°)

ANTERIOR APPROACHES

- ideal for younger adults (20-40 years) with flexible curves, healthy L5-S1 disk space, and no significant kyphotic deformity.

- complete diskectomy → interbody graft placement* → segmental bicortical vertebral body screw-rod fixation.

  *asymmetrical placement of interbody graft in anterior interbody space prevents development of kyphosis during compression of curve convexity

Correction of deformity and fusion from T10 to L2 through anterior-only approach:

Source of picture: H. Richard Winn "Youmans Neurological Surgery", 6th ed. (2011); Saunders; ISBN-13: 978-1416053163 >>

POSTERIOR APPROACHES

- useful in older patients (≥ 40 years) with flexible curves with or without pathology of L5-S1 disk.

- pedicle screw fixation for maintenance of correction until solid arthrodesis occurs.
- degenerated or deformed L5-S1 disk space requires fusion to sacrum; high rates of pseudarthrosis (H: anterior interbody graft at L5-S1 to provide load-bearing interbody surface).

61-year-old man who had undergone two-level TLIF at L4-5 and L5-S1 3 years before evaluation.
AP (middle) and lateral (right) views show correction of curve and fusion from T10 to S1 from posterior-only approach.

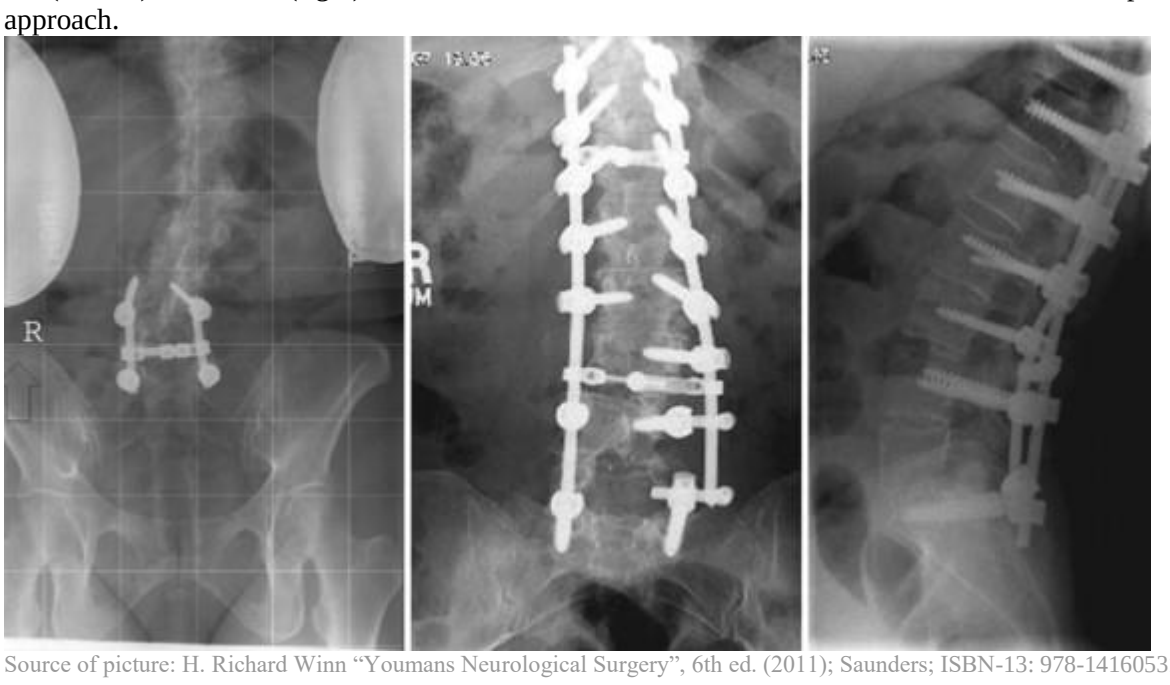

Source of picture: H. Richard Winn "Youmans Neurological Surgery", 6th ed. (2011); Saunders; ISBN-13: 978-1416053163 >>

COMBINED (ANTERIOR-POSTERIOR) APPROACHES

- for correction of **rigid curves**:
anterior release is performed, followed by staged or same-day posterior segmental instrumentation and fusion.
N.B. most of correction of deformity, including vertebral body derotation and restoration of sagittal alignment, is achieved during posterior instrumentation and fusion.

A. Preoperative radiograph of 67-year-old woman with symptomatic de novo scoliosis of lumbar spine.
B. After anterior release and interbody cage placement.
C-D. After posterior instrumentation and fusion from T9 to ileum (excellent correction of deformity).

Source of picture: H. Richard Winn "Youmans Neurological Surgery", 6th ed. (2011); Saunders; ISBN-13: 978-1416053163 >>

COMPLICATIONS

1. Residual curve, improper coronal or sagittal alignment; complete resolution of large curve is almost impossible without risking significant neurological injury.
2. Infection
3. Pseudarthrosis
4. Implant breakage; implants have finite life expectancy - can rapidly reach their fatigue limit and break if bone graft does not incorporate (bone graft in spine may take 36 months to mature).
5. Neurological injury
   - somatosensory-evoked potentials (SSEPs) monitoring is used with posterior surgery.
   - in anterior surgery, vertebral body is fully visualized to reduce risk of inadvertent injury by screws.

OUTCOMES

Operative vs. nonoperative treatment for adult spinal deformity

Outcomes of Operative and Nonoperative Treatment for Adult Spinal Deformity: A Prospective, Multicenter, Propensity-Matched Cohort Assessment With Minimum 2-Year Follow-up
International Spine Study Group Neurosurgery, Volume 78, Issue 6, 1 Jun 2016, Pages 851–861

Operative treatment for adult spinal deformity can provide significant improvement of HRQOL at a minimum 2-year follow-up; vs. nonoperative treatment - only maintains presenting levels of pain and disability. At the minimum 2-year follow-up, 71.5% of operative patients had ≥1 complications.

BIBLIOGRAPHY for ch. "Spinal Disorders" → follow this LINK >>