Skull Fractures

Last updated: January 7, 2022

ETIOPATHOPHYSIOLOGY

- **direct** impact to skull → inbending or outbending of skull beyond its elastic tolerance.

- skull fracture - indicator of severe blow to head (increased chance of intracranial abnormality).
  presence of fracture is not consistent with history of minor head injury!
- skull fracture does not necessarily mean that brain is injured (but in many cases it is).

With increasing severity of head injury, likelihood of skull fracture increases; presence of skull fracture increases likelihood of brain injury 4-fold.

  – skull fractures are detected in 5% mild head injuries.
  – skull fractures are detected in ≈ 30% of all head injuries.

N.B. prognosis depends more on *BRAIN* damage than on *SKULL* injury!

Generated forces:
  – walking into fixed obstruction (73 N force – enough to fracture skull!).
  – 4.5-kg adult head falling 1 m on hard surface (510 N).
  – falling from standing position (873 N).
  – running into obstruction (1020 N).

- 10 times more force is required to fracture skull with overlying scalp than to fracture one without scalp cover.
- *skull thickness is not uniform* - force required to cause fracture depends on site of impact:
  skull vault* is thinner than skull base (weakest parts of skull base → see *below*);
  skull vault diploë does not form (bone is thin) where skull is covered with muscles* (esp. squamous temporal and parietal bones);
  skull is thick - glabella, external occipital protuberance, mastoid processes, external angular process.

*prone to fracture.

CLASSIFICATION, CLINICAL FEATURES

Fracture type depends on **impact force** and **ratio of impact force to impact area**.

Communication with outside:
  A. **CLOSED**
  B. **OPEN** (**COMPOUND**) - torn pericranial tissues; patient is likely to have severe brain damage.
    – fracture that disrupts *paranasal sinuses* or *middle ear* is also considered open.

Location:
  A. **Vault**
  B. **Basilar**

Fracture form:
  A. **Linear** (incl. sutural diastasis)
  B. **Depressed**
  C. **Comminuted**

Underlying cerebral substance damage:
  A. **No injury** (UNCOMPLICATED FRACTURE)
  B. **Compression** (by *depressed* fractures)
  C. **Contusion**
  D. **Laceration** (by *depressed* fractures)

1. **Linear fracture** (80%) - ***single fracture line goes through entire skull thickness***; ***no displacement***.
   - etiology - low-energy blunt trauma over wide surface area of skull.
   - starts at point of maximum impact → extends toward skull base.
   - with multiple points of impact or repeated blows, fracture lines of subsequent injuries do not extend across prior fracture lines.
   - when individual falls while awake → occipital impact;
     fall that follows loss of consciousness → frontal impact.
   - clinically - just tender bump on head; skin may or may not be breached* (most patients are asymptomatic, without loss of consciousness - it is often difficult to predict presence of skull fracture by clinical examination).
     *scalp is mobile → possible nonalignment of fracture with scalp laceration
   - little significance (except when runs over arterial groove, venous sinus groove, or suture → epidural hematoma, venous sinus thrombosis, sutural diastasis). *see below (COMPLICATIONS)*

   SUTURAL DIASTASIS (S. DIASTATIC FRACTURE) - traumatic disruption of cranial suture.
   - usually occurs when linear fracture extends into suture line.
   - usually affect infants (suture fusion has not yet happened); rare after sutures have undergone bony fusion.
   - often involves *coronal* or *lambdoid* sutures.

2. **Basilar fracture** (19-21%) - ***linear fractures at skull base*** (often are extensions of adjacent convexity fractures).
   - basilar bones are thick – much more force required to fracture them!
   - most basilar fractures occur at specific locations:
     1) most commonly (75%) - temporal bone. *see below*
     2) occipital condylar region (foramen magnum). *see below*
     3) along inner parts of sphenoid wings, sphenoid sinus, toward sella turcica and cribriform plate, roof of orbits.
     4) areas between mastoid and dural sinuses in posterior cranial fossa.
     N.B. middle cranial fossa is weakest part (thinnest + multiple foramina)
   - etiology - impact to ***occiput*** or ***sides of head*** (rather than blow to vertex).
   - difficult to detect at postmortem examination (require careful removal of tightly adherent dura).

- often associated with dural tears.
- clinically: ecchymoses (periorbital / retroauricular) distant from point of impact, cranial nerve palsies, CSF leaks, pneumocephalus, cavernous-carotid fistula. *see below (COMPLICATIONS)*

ANTERIOR FOSSA:

1) ***periorbital ecchymosis*** limited at edge of orbit ("raccoon eyes") - blood dissecting from disrupted skull cortex into periorbital soft tissue:

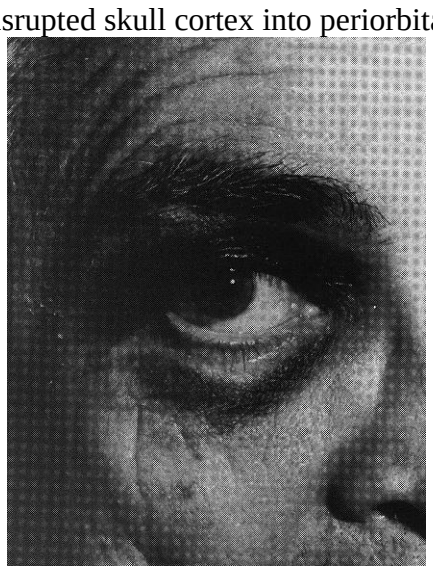

2) ***CSF rhinorrhea*** - CSF leak through cribriform plate or adjacent sinus.
3) ***CN 1-2 damage***.

MIDDLE FOSSA:

PETROUS PORTION OF TEMPORAL BONE:

1) ***retroauricular ecchymosis*** - delayed ecchymosis over mastoid process (Battle sign) - blood dissecting from disrupted skull cortex:

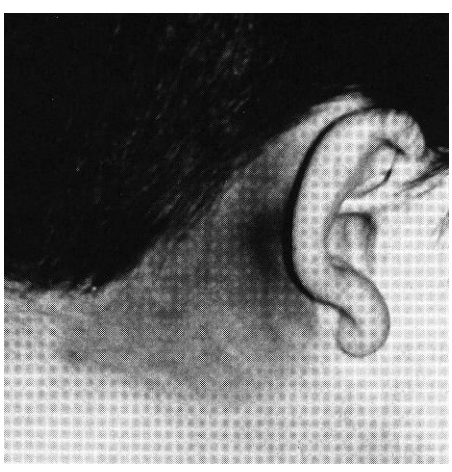

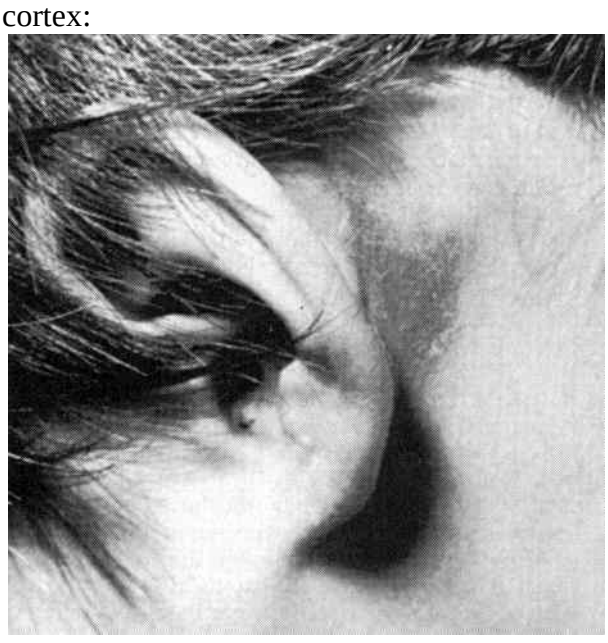

2) ***CSF otorrhea***.
3) ***blood in ear canal*** (more commonly due to local laceration of external canal)
4) ***hemotympanum*** (blood ± CSF behind tympanic membrane).
5) ***CN7 palsy***, ***hearing loss***, ***vertigo***. *see below (TEMPORAL BONE FRACTURES)*

SPHENOID, SELLAR FRACTURES:

1) ***air-fluid level*** in sphenoid sinus
2) ***CN2, 6-7 palsies***
3) ***neuroendocrine dysfunction***.
4) ***ICA pseudoaneurysms***, ***carotico-cavernous fistulas***.

POSTERIOR FOSSA:

CLIVUS FRACTURE – ***CN6 palsy***, ***ganglion trigeminale lesion***.
OCCIPITAL CONDYLAR FRACTURES – ***CN9-12 palsy***.
see below (OCCIPITAL CONDYLAR FRACTURES)

3. **Depressed fracture (s. impressed fracture)** - ***bony piece is driven*** by direct traumatic impact* ***below plane of skull***.

*usually small blunt objects (such as hammer or baseball bat)

- 75% frontoparietal (may involve frontal sinuses and orbits), ≈ 10% temporal, 5% occipital.
- most (75-90%) depressed fractures are open fractures.
- edges of depressed portion may become locked underneath adjacent intact bone and fail to rebound into previous position.
- in gunshot cases, bullet exit causes ***EXPRESSED FRACTURE***.
- clinically – ***depression*** under generalized swelling (avoid driving bone fragment deeper!), depressed area may be several centimeters away (due to scalp mobility); ***focal seizures*** (from contusion underlying fracture).

PING-PONG FRACTURES (akin to greenstick fracture of long bones)

- occur in first few months of life.
- etiology:
  1) fall when skull hits edge of hard blunt object.
  2) birth trauma (newborn head was impinged against mother's sacral promontory during uterine contractions).
  3) birth trauma with forceps (rare).
- clinically - skull appears deformed, with shallow trench on skull surface.

4. **Comminuted fracture** - ***multiple linear fractures*** that radiate from impact site (≥ 2 bone fragments).

- suggests more severe blow (than in single linear fracture).
- portion of bone may be depressed.

DIAGNOSIS

Indications for **skull X-ray** → see p. TrH1 >>

- plain radiographs *may miss basal skull (esp. temporal bone) fractures* – only clues may be fluid levels (bleeding or CSF leakage) in sphenoid, frontal sinus or petromastoid air cells.
- AIR within cranium:
  a) extradural - sharply defined, superficial, adjacent to midline or fractured sinus;
  b) subdural - very extensive;
  c) subarachnoid - diffuse air, in bubbles, or outlining brain;
  d) within damaged brain;
  e) intraventricular (can cause acute hydrocephalus).

X-ray differences between ***linear fractures***, ***normal sutures***, and ***normal vascular markings***:

FRACTURES	*SUTURES*	*VASCULAR MARKINGS*
– *WIDTH > 3 MM.* – *WIDEST AT CENTER AND NARROW AT ENDS.*	– *WIDTH < 2 MM.* – *SAME WIDTH THROUGHOUT.*	– *ENGRAVE **INNER TABLE ONLY**.*

– *RUNS THROUGH BOTH OUTER AND INNER LAMINA OF BONE, HENCE APPEARS DARKER.* – *USUALLY OVER TEMPOROPARIETAL AREA.* – *RUNS IN STRAIGHT LINE WITH ANGULAR TURNS (SUDDEN CHANGE IN DIRECTION).* – *TRANSLUCENT LINE WITH SHARP MARGINS.*	– *LIGHTER ON X-RAYS COMPARED WITH FRACTURE LINES.* – *AT SPECIFIC ANATOMIC SITES.* – *DOES NOT RUN IN STRAIGHT LINE.* – *CURVACEOUS (SERPIGINOUS).* – *SYMMETRICAL **WELL-CORTICATED SCLEROTIC MARGINS**.* – *SYMMETRIC SUTURE LINE ON OPPOSITE SIDE.*	– *LESS TRANSLUCENT THAN FRACTURES.* – *ILL-DEFINED MARGINS.* – *MENINGEAL GROOVES TAPER AS THEY RUN PERIPHERALLY.* – *SYMMETRICAL BRANCHING PATTERN.* – *DIPLOIC VENOUS MARKINGS ARE WIDE.*

Skull fracture is indication for **CT**!

Use 3D reconstruction to detect vault fractures easily!

- CT with wide windows (1000-4000 HU) are needed to evaluate skull injuries.
- degree of skull depression is easily measured on CT.
- CT may miss:
  1) *small vertex fractures* (often, small streak artifact caused by misaligned fracture may be clue).
  2) *basilar skull fractures* (clues – pneumocephalus, air-fluid level in sphenoid sinus).

MRI easily misses skull fractures (low sensitivity and specificity)!

Persistent metopic suture that has not yet fused; this is not fracture:

Importance of straight patient position for lateral imaging. Because patient is slightly malpositioned, both coronal sutures are seen as separate entities (also applies to lambdoid sutures); because they are separated - could be mistaken for fracture:

Bilateral vault fracture - fluid level in sphenoid sinus (open arrow); two fracture lines - more anterior (upper on this film) is better defined and is therefore on side nearer film; bone islands (small arrows) are typical:

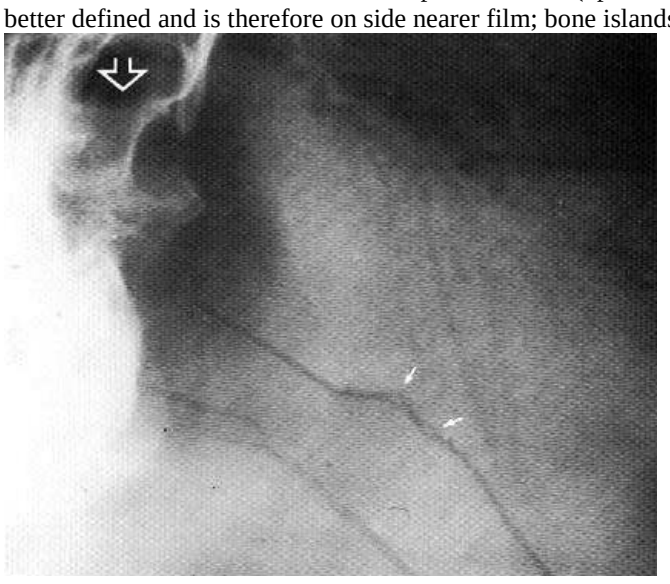

Lateral CT scanogram and axial bone-window CT - ping-pong ball temporal fracture - slight inward bulging of bone, but inner and outer tables are intact:

Depressed skull fracture:

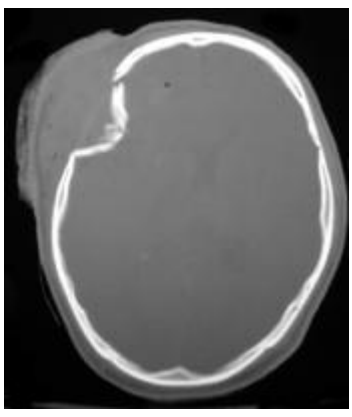

Depressed skull fracture with parenchymal contusion (CT 'brain and bone windows'):

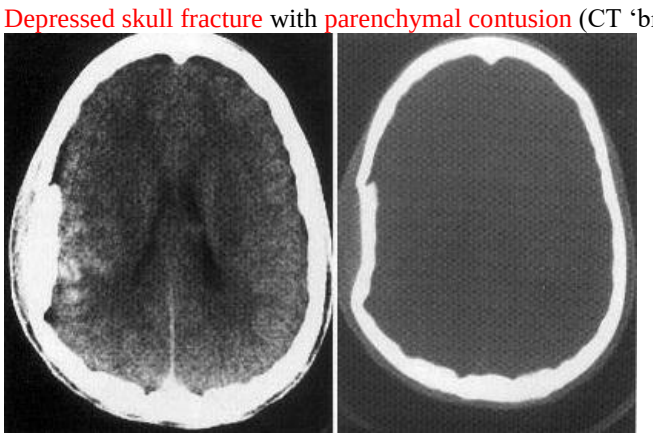

Stellate depressed fracture:
A. Lateral projection: typical appearance of dense flake deep to skull vault.
B. Half axial projection.

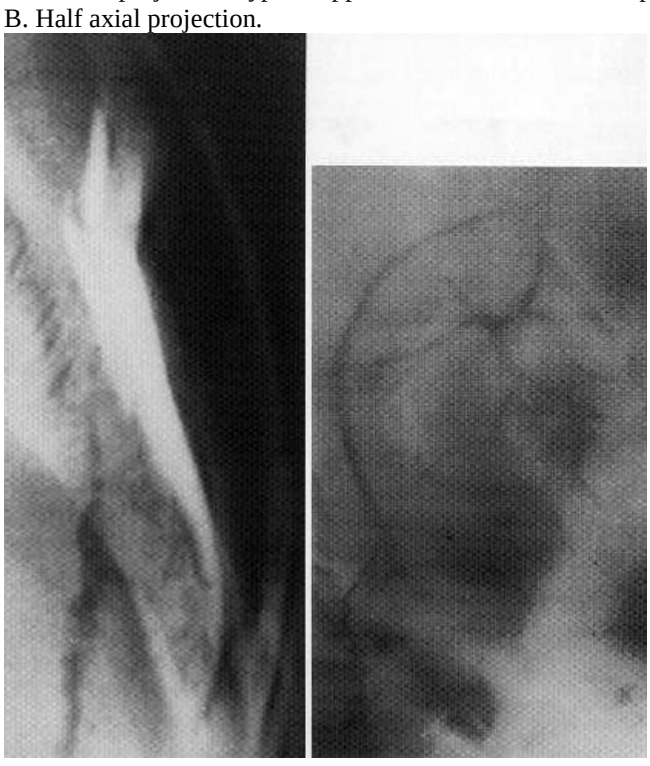

TREATMENT

Prehospital management → see p. TrH1 >>

N.B. 15% patients with skull fractures have concomitant cervical spine injury!

Linear fracture – no special therapy.
- in *children*, skull fractures heal within 3-6 months; in *adults*, complete healing may take up to 3 years.

Basilar fractures – treat only complications (CSF leak, etc).
- no benefit of prophylactic antibiotics for basilar skull fractures.
  Cochrane Database Syst Rev. 2006 Jan 25;(1):CD004884

Open (compound) fractures – treated conservatively:
1) **tetanus** toxoid vaccination
2) irrigation and **scalp debridement & repair**
3) **antibiotic** prophylaxis for 5-10 days (guidelines recommend for all open fractures; some experts use only for obviously contaminated cases), e.g.
   "TRIPLE ANTIBIOTIC" x 5 days:
   1) CEFTRIAXONE 2 g q12h or cefepime 2 g q8h **plus**
   2) NAFCILLIN 2 g q4h **plus**
   3) METRONIDAZOLE 500 mg q8h
4) **CT** few times over next 2-3 months (to check for abscess formation).

Some experts says: **open fractures** – just **standard periop abx prophylaxis** (even if enters sinus)!

Criteria for operative management of open fracture:
a) ***dural penetration / pneumocephalus***
b) ***gross contamination / wound infection***
c) ***frontal sinus involvement + intradural pneumocephalus + obstructed sinus drainage***
d) ***depressed greater than the thickness of the cranium***

By convention, **open depressed** cranial fractures are treated **surgically** (early debridement and elevation), primarily to decrease the incidence of infection.
However, at least a select group of patients with compound depressed cranial fractures will do well without surgery.

- open fractures have 10.6% incidence of infection (→ persistent neurological deficit, late epilepsy, and death); operative debridement reduces the incidence of infection to 4.6%, however, operative delay > 48 hours from injury dramatically increases the incidence to 36.5%.
  Jennett B, Miller J: Infection after depressed fracture of skull. Implications for management of nonmissile injuries. J Neurosurg 36:333–339, 1972

Depressed fractures
1. Prophylactic **anticonvulsants**.
2. Most depressed fractures heal well and smooth out with time, without elevation; indications for **surgical elevation**:
   a) ***depressed greater than the thickness of the cranium*** (i.e. > 10 mm inward displacement)
   b) ***focal neurologic deficit*** (but focal deficits are caused by brain parenchyma damage more than by continuing compression by bone fragments; i.e. compression relief does not guarantee deficit disappearance).
      depressed fracture over venous sinus: neurologically stable patient → observe (or primary wound debridement without elevation); neurologically unstable patient → urgent elevation.
   c) ***cosmetic deformity*** (FRONTAL BONE is most important esthetically + it forms roof and portions of medial and lateral walls of orbit).
   - no proof that elevation of depressed fragments decreases epilepsy risk.
     Jennett B, Miller J, Braakman R: Epilepsy after nonmissile depressed skull fracture. J Neurosurg 41:208–216, 1974

- elevation of small depressed fractures need not be performed immediately (but before discharge); indications for *immediate elevation*: gross contamination, dural tear with pneumocephalus, underlying hematoma.
- surgery details: see p. Op 320 >>

COMPLICATIONS

Skull fracture per se does not indicate trauma severity.

Skull fracture importance – risk of **intracranial infection and bleeding**!

Clinically significant skull fractures (prone to complications):

1) *extend into air sinuses* → CSF leaks (→ infection).
2) *basal* → CSF leaks (→ infection), cranial nerve / vascular injuries.
3) *open* → infection.
4) *depressed* below level of inner table → underlying brain injury → posttraumatic epilepsy.
5) *overlie major dural venous sinus / middle meningeal artery* → sinus thrombosis / bleeding (e.g. EDH).
6) linear fractures associated with *dural tear in young children* → leptomeningeal cyst.

N.B. basilar fractures are most serious - deserve closer monitoring than linear vault fractures!

Bleeding

- infants may bleed significantly intracranially from skull fractures (skull is very vascular – any fracture may cause venous epidural hematoma); check hematocrit q 12-24 h.
- *EPIDURAL HEMATOMA* is associated with skull fracture in ≈ 50% cases.
- *SUBDURAL HEMATOMA* is associated with skull fracture in ≈ 33% cases.

Pneumocephalus see p. TrH1 >>

CSF leaks - otorrhea and rhinorrhea (after *basilar skull fractures*). see p. S64 >>

Meningitis (via wound or CSF fistula); may extend into brain abscess.

Cranial nerve palsies (after *basilar skull fractures*). see p. TrH1 >>

Posttraumatic epilepsy (after *depressed skull fractures*) – risk factors: loss of consciousness for > 2 hours, associated dural tear, early seizures (within first week).

Carotid-cavernous fistula (after *sphenoid bone fracture*) see p. TrH9 >>

Traumatic aneurysms (e.g. after *sphenoid bone fracture*) see p. TrH1 >>

Superior sagittal sinus compression (by depressed vertex fractures) → thrombosis.

Leptomeningeal cyst (s. **growing fracture**) – extrusion (in form of cyst) of leptomeninges and brain tissue through dural defect.

- etiopathology: *skull fracture with separation of fracture edges* [depressed or diastatic skull fracture] *and dura laceration* → arachnoid and brain are caught between edges of fracture → brain pulsation forces CSF into cyst → skull erosion.
  N.B. seen almost exclusively in children < 1-3 yrs with fracture accompanied by dural tear – such children must be followed up closely for several months!!!
- most are located in calvarium (rare sites are basiocciput and orbital roof).
- underlying brain may herniate through skull defect.
- prominent porencephalic cyst or focal dilatation of lateral ventricle usually underlies fracture.
- types:
  Type I - leptomeningeal cyst herniating through skull defect into subgaleal space.
  Type II - damaged or gliotic brain.
  Type III - porencephalic cyst is seen.
- clinically (manifests several weeks ÷ months after fracture):
  1) ***growing subgaleal mass*** (slowly expanding pulsatile nontender swelling in area of previous skull fracture)
  2) convulsive ***seizures*** or ***focal neurologic deficit***
  3) ***mental retardation***
  4) ***mass effect*** with increased ICP.
- diagnosis: serial **X-ray** (sufficient for diagnosis*) – enlarging oval area of skull erosion (progressive separation of long edges of seemingly benign linear skull fracture).
  *but **CT** better defines exact pathology; intracranial hypoattenuating area may be encephalomalacia, arachnoid loculation, or cortical atrophy.
- tools for early diagnosis (→ early simpler surgical intervention → prevented long-term neurologic sequelae):
  1) **MRI** - depicts dural tears early.
  2) **ultrasound** (tool for assessing state of dura).
- treatment: **cyst excision → dural closure → cranioplasty**. See p. Op320 >>
  – occasionally, shunt surgery is performed to decompress cyst and treat localized dilatation of ventricles.

LATERAL SKULL RADIOGRAPH OF LEPTOMENINGEAL CYST:

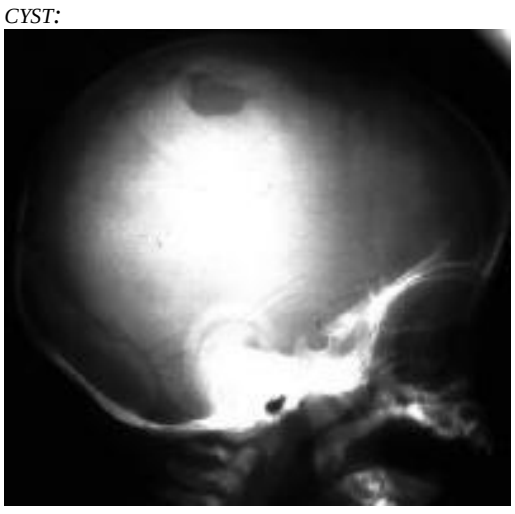

AXIAL CT OF LEPTOMENINGEAL CYST: WIDENED FRACTURE ON LEFT AND FLUID COLLECTION EXTENDING FROM INTRACRANIAL CAVITY INTO AND THROUGH FRACTURE SITE:

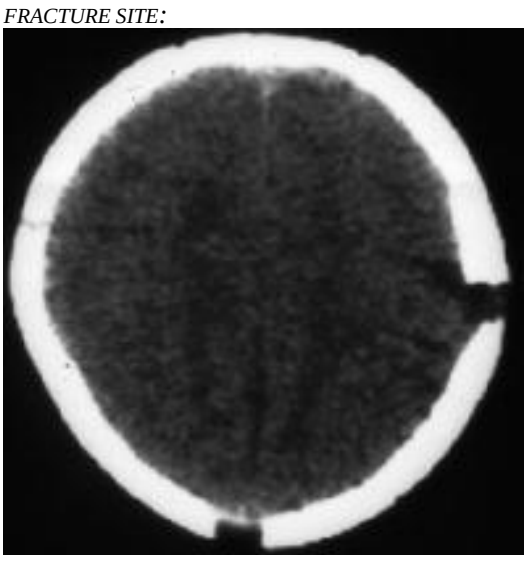

Dislocation of bones of auricular chain (after *temporal bone fracture*). *see below*

SPECIAL SITUATIONS

TEMPORAL BONE FRACTURES

- fractured in 15-48% of all skull fractures (75% of all skull base fractures).
- clinical features: Battle's sign, bleeding from ear (hemotympanum or from fracture line in ear canal), CN7 & 8 damage, ossicular chain & tympanic disruption, CSF otorrhea.

Subtypes (by Ulrich, 1926)

1. ***LONGITUDINAL*** *(70-90%)* - parallel to petrous pyramid:
   - pars squamosa, posterosuperior wall of external auditory canal, tegmen tympani → run either anterior or posterior to cochlea and labyrinthine capsule → end in middle cranial fossa near foramen spinosum or in mastoid air cells, respectively.
   - caused by direct lateral force over mastoid or squamous bone or blow to mandible.

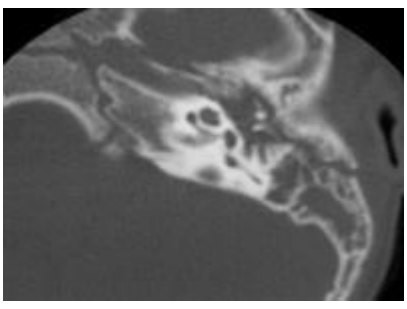

2. ***TRANSVERSE*** *(5-30%)* - perpendicular to petrous pyramid:
   - originate at foramen magnum → extend through cochlea and labyrinth (pneumolabyrinth) → end in middle cranial fossa.
   - caused by frontal or parietal blow but may result from occipital blow.

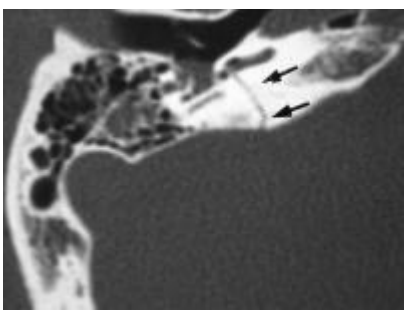

3. **MIXED** - components of both **LONGITUDINAL** and **TRANSVERSE** fractures.

Complications:

1) **facial nerve paralysis** (twice more common with transverse fracture):
   a) ***delayed-incomplete*** (progressive edema within nerve - good prognosis) – due to neurapraxia (10-20% longitudinal fractures); injury site is usually horizontal segment distal to geniculate ganglion; H: steroids - spontaneous recovery is usual.
   b) ***immediate-complete*** – due to nerve transection (50% transverse fractures); injury site is anywhere from internal auditory canal to horizontal segment distal to geniculate ganglion; decompression surgery is not always indicated (use electroneuronography [ENOG] in decision making).
2) **hearing loss** (hemotympanum and mucosal edema in middle ear may cause temporary deafness - resolves within ≈ 3 weeks):
   a) ***conductive*** **hearing loss** due to hemotympanum, ossicular dislocation / fracture or tympanic rupture (≈ 50% longitudinal fractures);
      – incus (relatively loose ligamentous attachments) is most frequently dislocated ossicle.
      – most tympanic membrane perforations and hemotympanum usually resolve in 3-4 weeks.
      – if conductive hearing loss is present at > 30 dB after 3 months → tympanoplasty with ossicular chain repair.
   b) ***sensory*** **hearing loss** (≈ 80% transverse fractures); H: cochlear implants.
3) **vertigo** due to:
   a) fracture extending into vestibular apparatus (e.g. with transverse fractures).
   b) labyrinth concussion (e.g. with longitudinal fractures).
   c) development of perilymphatic fistula (paroxysmal vertigo with fluctuating or progressive hearing loss); H: exploratory tympanotomy.
   d) posttraumatic benign paroxysmal positional vertigo.
4) **CSF otorrhea** (in any subtype of fracture).
5) **unusual complications**:
   - carotid injury.
   - CN6 paralysis (recovery within 6 months is usual).
   - CN5 damage.
   - sigmoid sinus thrombosis.
   - posttraumatic cholesteatoma (can grow undetected for years).
   - **EAGLE syndrome** (classically follows tonsillectomy; fracture of ossified styloid and stylohyoid ligament can cause pressure on ECA or ICA → atypical pain referred to cheek or eye; treatment is surgical).
   - sympathic cochleolabyrinthitis (autoimmune inner ear damage - autoantibodies against inner ear proteins [as in polyarteritis nodosa]; H: immunosuppression).

TRANSVERSE FRACTURES nearly always produce *facial paralysis*, permanent *hearing loss*, severe ablative *vertigo*.

Diagnosis - high-resolution **CT** axial and coronal images ("temporal bone CT") with 1-mm slices and magnified views; bone windows alone are necessary.

Longitudinal fracture of right temporal bone (axial CT) - fracture line follows long axis of temporal bone (medium arrowheads); incus is subluxed laterally (small arrowhead); mastoid air cells opacified with blood (large arrowhead):

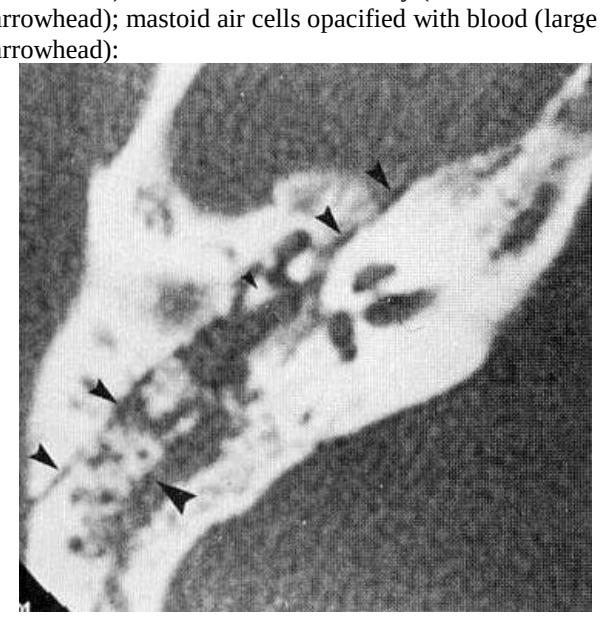

Longitudinal fracture of right temporal bone (axial CT) - fracture line follows long axis of temporal bone (small arrowheads); fracture line is seen to cross area of geniculate ganglion of CN7 (large arrowhead):

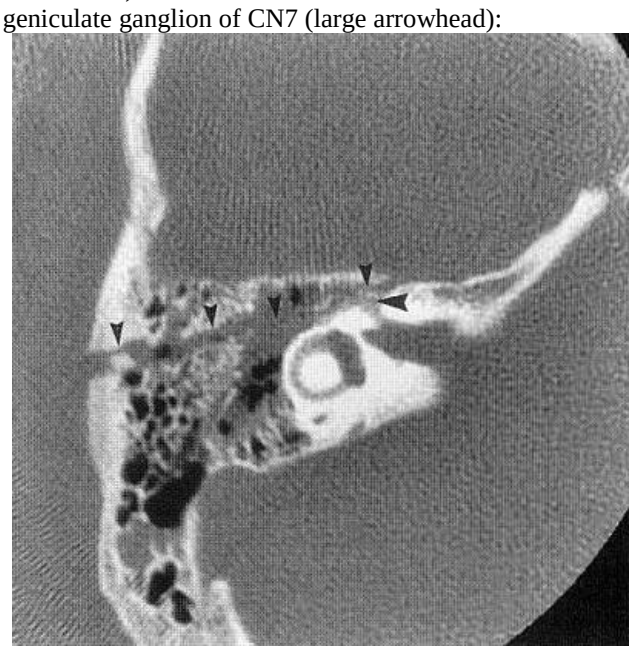

Transverse fracture of temporal bone (axial CT) - fracture line (arrowheads) crosses petrous pyramid at level of posterior semicircular canal and posterior genu of CN7 canal (arrow):

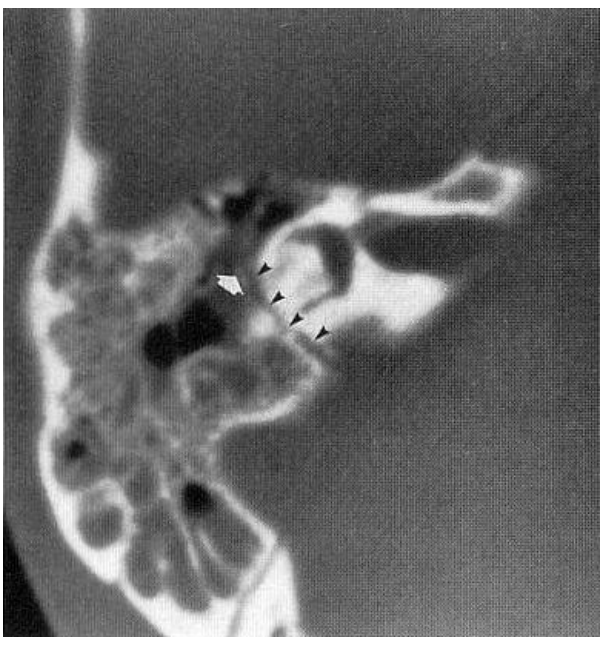

OCCIPITAL CONDYLAR FRACTURES

- very rare and serious injury.

ANDERSON AND MONTESANO TYPES

*preserved alar ligament and tectorial membrane

Type I fracture – stable* **comminuted** (**impacted**) fracture of occipital condyle - due to axial compression injury.

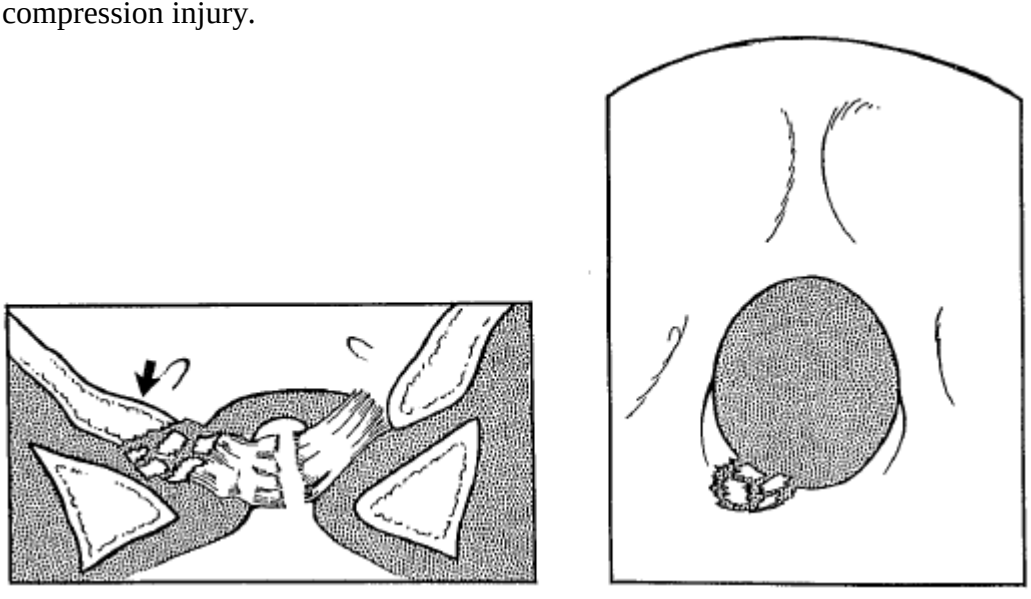

Type II fracture – stable* **extension of fracture of basioccipital region** - caused by direct blow.

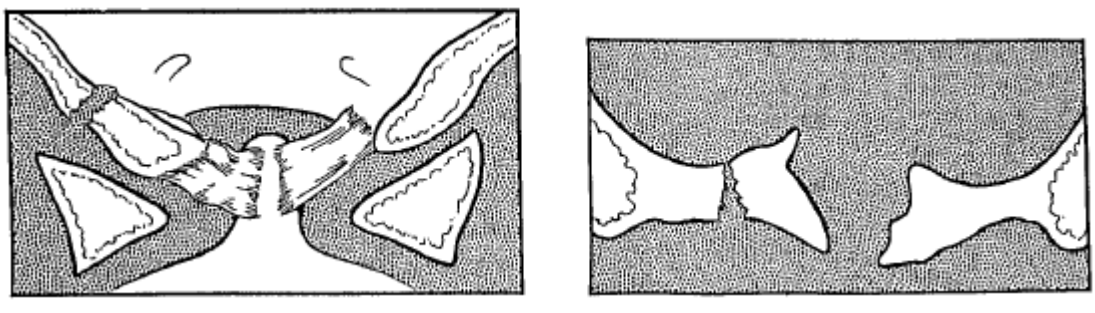

Type III fracture – unstable **avulsion** injury (alar ligament insertion avulsed from occipital bone), AO ligamentous injury - due to forced rotation and lateral bending.

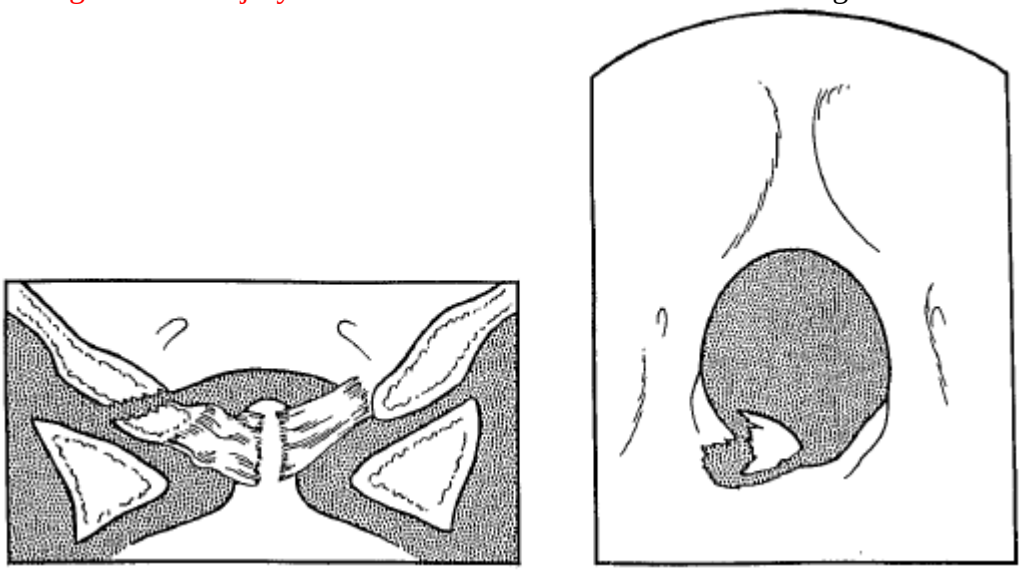

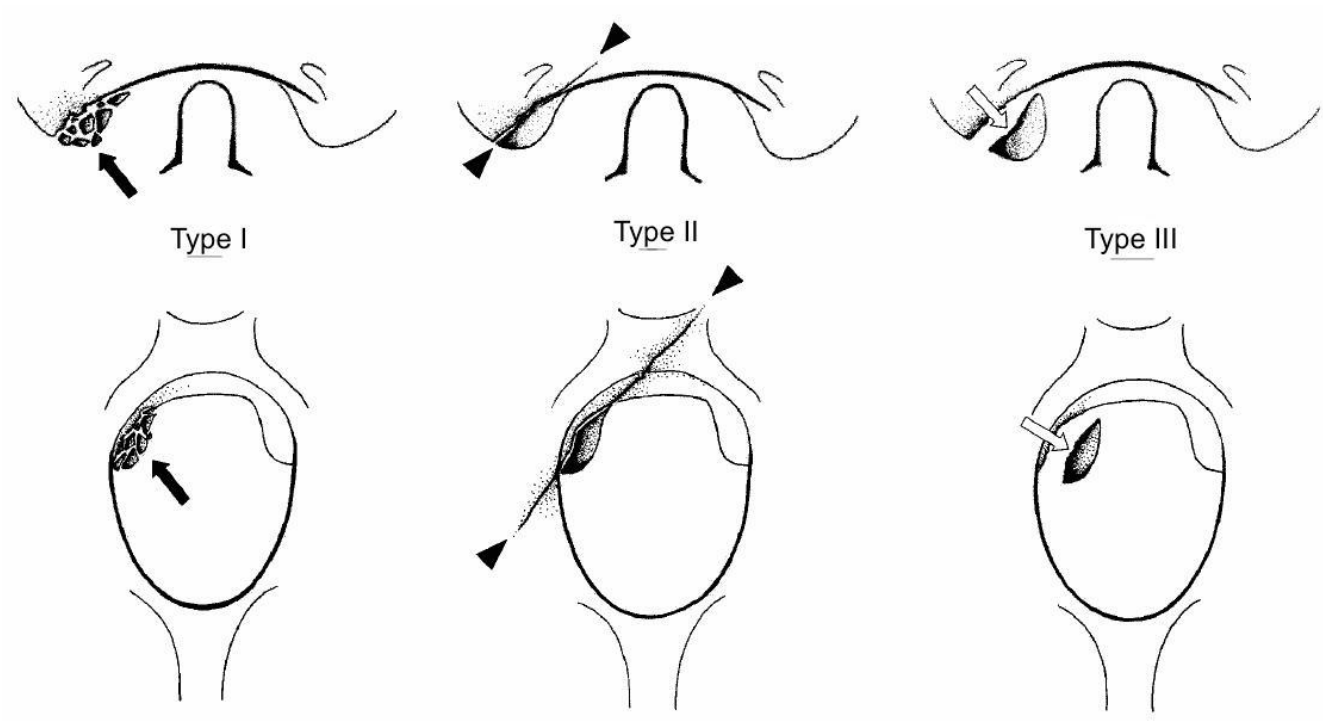

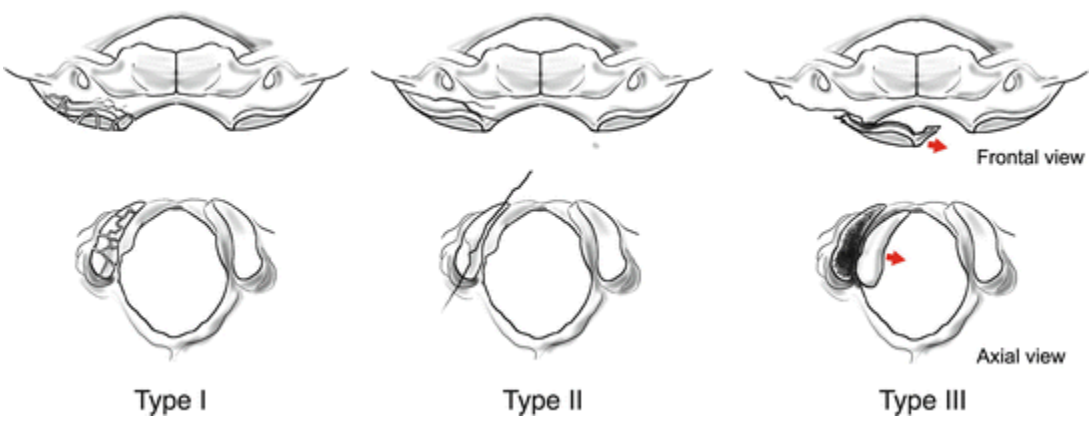

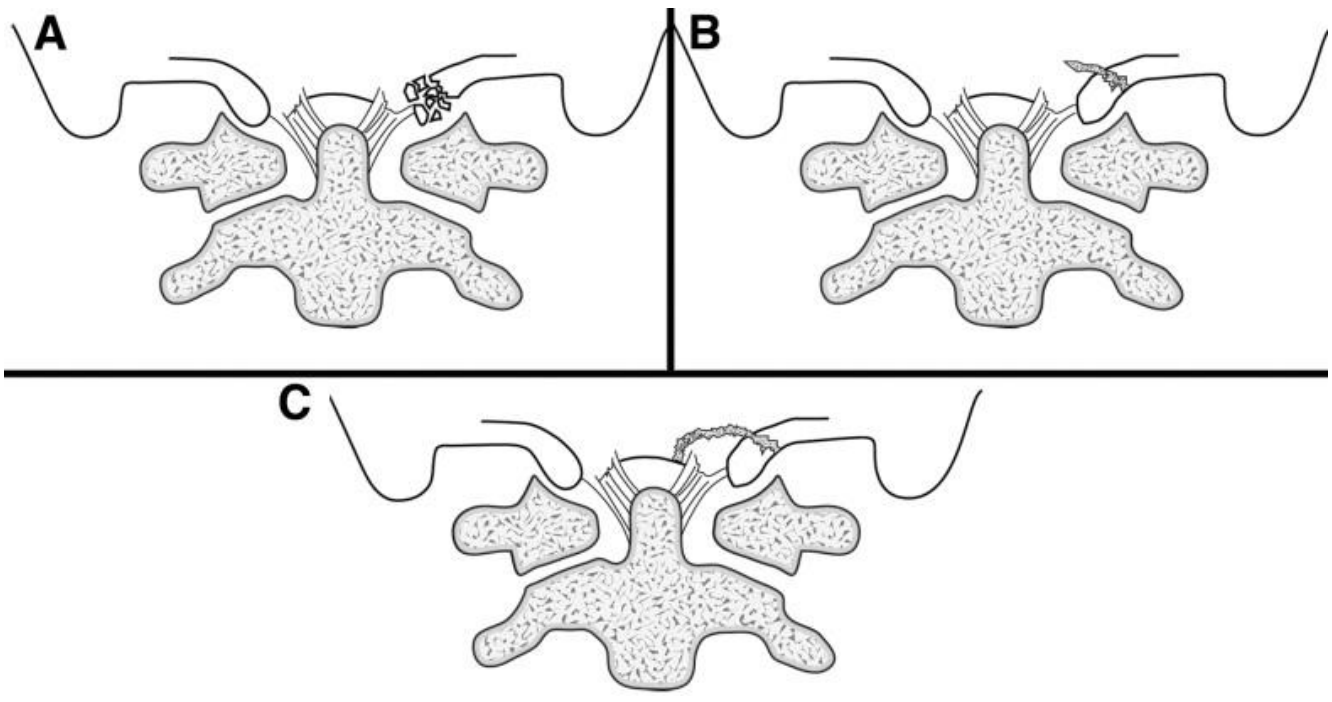

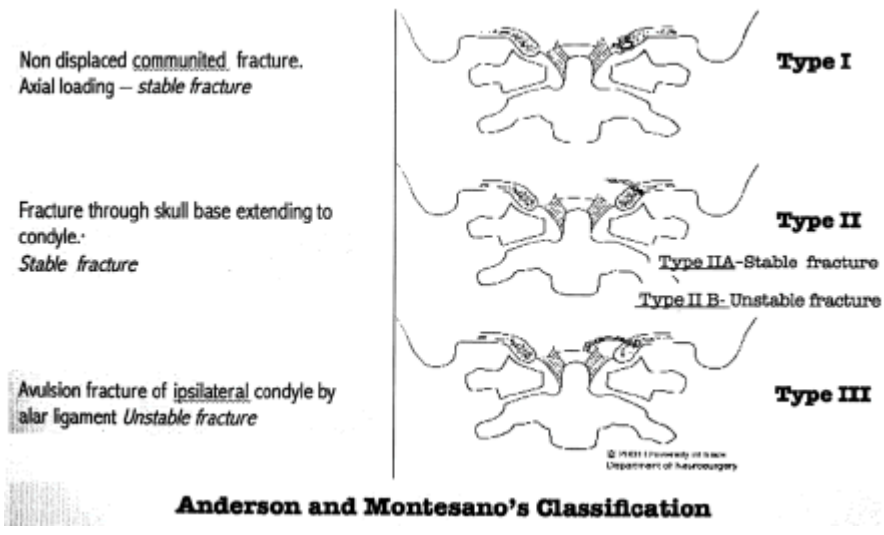

CLINICALLY

- 30% patients present comatose, 30% - neuro intact, 40% - with neuro deficits.
- occipitocervical tenderness, reduced craniocervical motion, lower cranial nerve abnormality, retropharyngeal soft tissue swelling.

Complications: **CN9-12 palsy** (***Collet-Sicard syndrome***), **CN9-11 palsy** (***Vernet syndrome***).

RADIOGRAPHIC

- difficult to delineate (**XR** has sensitivity only 1.4%); **CT** is recommended (sensitivity 100%; Level II recommendation); **MRI** is recommended to assess ligaments (Level III recommendation).

TREATMENT

(CNS/AANS Guidelines):
Types I-II - neck stabilization with hard collar or halo (for ***bilateral*** OCF).
Type III - halo or occipitocervical fusion; anecdotally, patients (esp. young ones) heal in hard collar.

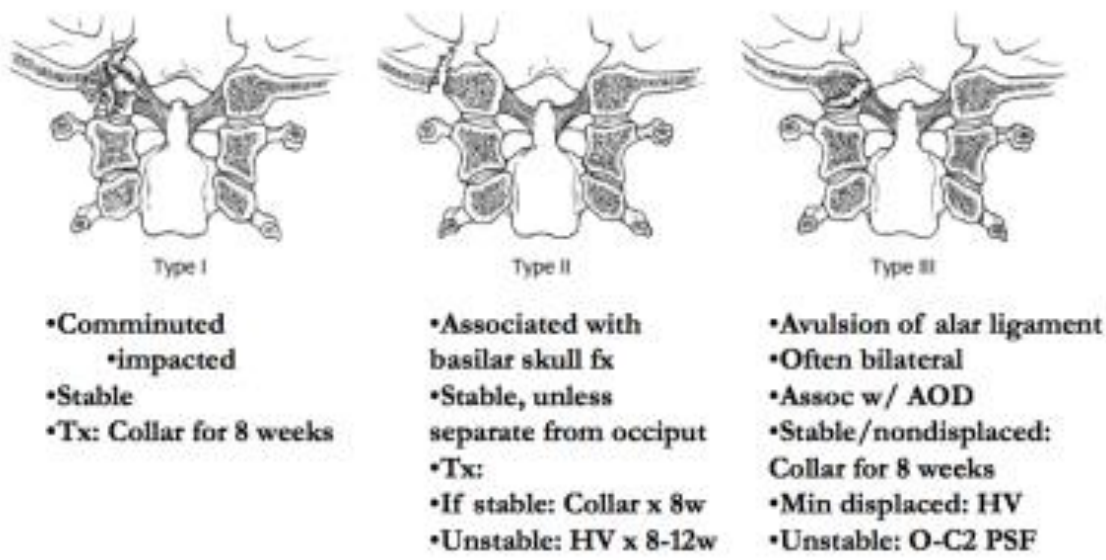

BIBLIOGRAPHY for ch. "Head Trauma" → follow this LINK >>